

Case Report

Prenatal Three Dimensional Ultrasonography and Expectant Management of Placental Chorioangioma: A Case Report

Piyamas Saksiriwuttho MD*,
Thawalwong Ratanasiri MD*, Chatuporn Doankum MD*,
Pilaiwan Kleebkaew MD**, Pakaphan Kiatchoosakun MD***

* Division of Fetal Diagnosis and Therapy, Department of Obstetrics and Gynaecology, Faculty of Medicine, Khon Kaen University, Khon Kaen, Thailand

** Division of Reproductive Pathology, Department of Obstetrics and Gynaecology, Faculty of Medicine, Khon Kaen University, Khon Kaen, Thailand

*** Department of Pediatrics, Faculty of Medicine, Khon Kaen University, Khon Kaen, Thailand

A 24-year-old Thai woman presented with large for date. Two dimensional (2D) and Doppler ultrasonography revealed a large placental mass with prominent vasculature suggestive of chorioangioma with polyhydramnios. Three-dimensional (3D) ultrasonography was used to demonstrate the better images for parental counseling. Close observation with serial ultrasonography was chosen with spontaneous decreasing of amniotic fluid. On the follow up, six months after birth, the baby had hepatic hemangioma, which responded to corticosteroid and propranolol.

Although, there are several invasive therapeutic treatments adopted in the management of chorioangioma. Such procedures can cause serious complications. Expectant management should be another option because large chorioangiomas may have spontaneous infarction that improve fetal hemodynamics and clinical outcomes.

Keywords: Chorioangioma, Three dimensional ultrasonography, Expectant management

J Med Assoc Thai 2013; 96 (4): 496-500

Full text. e-Journal: <http://jmat.mat.or.th>

Chorioangioma or placental hemangioma is the most common benign vascular tumor of the placenta originating from primitive chorionic mesenchyme. They were originally described by Clarke in 1798⁽¹⁾ with the estimated prevalence of approximately 0.5 to 1.0%⁽²⁾. The etiology and recurrent risk are unknown. Most of chorioangiomas are of no clinical importance. However, large (more than 4 cm) or multiple chorioangiomas, which occurred less frequently, are usually accompanied by a variety of complications affecting both the mother and the fetus.

As asymptomatic benign conditions, small tumors are usually treated with expectant management with serial ultrasonography every 6-8 weeks, whereas large tumors require serial ultrasonography every

1-2 weeks⁽³⁾ to early detection of fetal complications. In situations in which maternal or fetal complications necessitate intervention, there are several invasive possible treatments. However, limitation of experience in some regions and no consensus for the efficacy of these methods, expectant management becomes another option.

The presented case describes a pregnant woman with a large chorioangioma detected at 26 weeks' gestation. A 3D ultrasonography was used to demonstrate the better images for parental counseling. The pregnancy was uneventful in spite of such a large chorioangioma and led to a successful outcome with expectant management. The present study was approved by Khon Kaen Ethics Committee, No. HE541296.

Case Report

A 24-year-old Thai woman, primigravida, had an unremarkable prenatal course until 26 weeks' gestation. She started to have large for date. The height of her fundus was 32 cm with normal fetal heart rates.

Correspondence to:

Saksiriwuttho P, Division of Fetal Diagnosis and Therapy, Department of Obstetrics and Gynaecology, Faculty of Medicine, Khon Kaen University, Khon Kaen 40002, Thailand.

Phone: 043-363-030

E-mail: piyamassaksiriwuttho@yahoo.com

The rest of the clinical examination was normal. The 2D and 3D ultrasonography showed a 26 weeks single female viable fetus, weight 1,400 gm, with polyhydramnios (amniotic fluid index: AFI = 41 cm) and a 5x5x7 cm complex, round mass protruded into the amniotic cavity (Fig. 1, 2). Another part of the placenta showed normal morphological appearance. Doppler ultrasonography of the complex mass demonstrated prominent vasculature which suggestive of chorioangioma (Fig. 3). After parental counseling about the pathophysiology, risks for maternal and fetal complications, prognosis and possible choices of treatment, they chose expectant management. Subsequent ultrasonography was done every two weeks to follow fetal growth and other complications. The ultrasonography performed at 32 weeks revealed fetal scalp edema with fetal weight 2,804 gm without other signs of hydrops fetalis. Chorioangioma size was measured approximately 7x5.7x6.9 cm. Polyhydramnios (AFI = 35 cm) was still noted. At 36 weeks, the patient became complicated by preterm labor. Ultrasonography revealed decreasing of amniotic fluid (AFI = 25 cm). She delivered a female infant weighing 3,610 gm by cesarean section due to cephalopelvic disproportion. Apgar score were 6, 7, 8 at 1, 5, 10 minutes, respectively. The infant had generalized skin edema and hepatosplenomegaly. Her initial hematocrit was 40% volume. On the follow-up, six months later, the baby had hepatic hemangioma, which responded to corticosteroid and propranolol. Placenta was sent for histopathological examination. Gross examination of the placenta showed a 4.5x10x3 cm well circumscribed oval lesion, red in color and firm in consistency (Fig. 4). A cross section showed some necrotic areas (Fig. 5). Microscopic view exhibited an angiomatous proliferation similar to somatic capillary (Fig. 6). Histological features were consistent with placental chorioangioma.

Discussion

Chorioangioma can cause a variety of complications affecting both mother and fetus. The main fetal risks include non-immune hydrops fetalis, cardiomegaly, congestive cardiac failure, anemia, thrombocytopenia, consumptive coagulopathy, prematurity, and sudden infant death⁽⁴⁻⁶⁾. Maternal risks are mainly polyhydramnios and preterm delivery⁽⁷⁾.

Shafqat G et al⁽⁸⁾ reported an emergency primigravida case with complaints of decreased fetal movements. Her 2D ultrasonography revealed a single hydropic fetus with no fetal heart. A well-

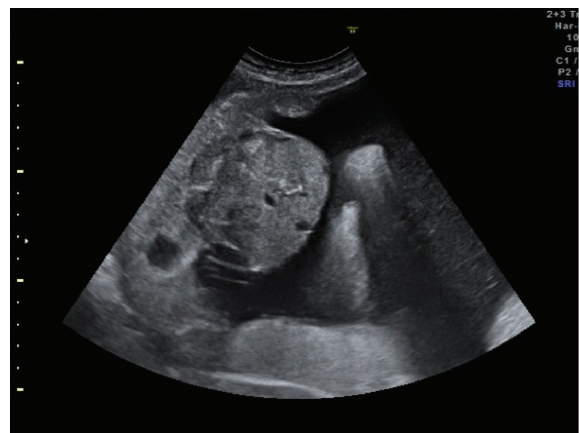

Fig. 1 The 2D ultrasonography at 26 weeks' gestation showed placental mass protruded into the amniotic cavity.

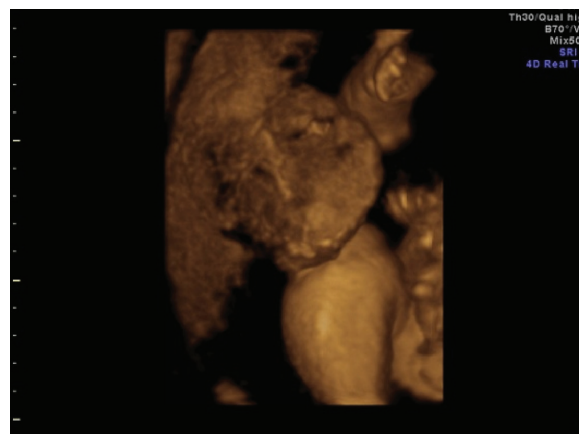


Fig. 2 The 3D ultrasonography at 26 weeks' gestation showed placental mass protruded into the amniotic cavity.

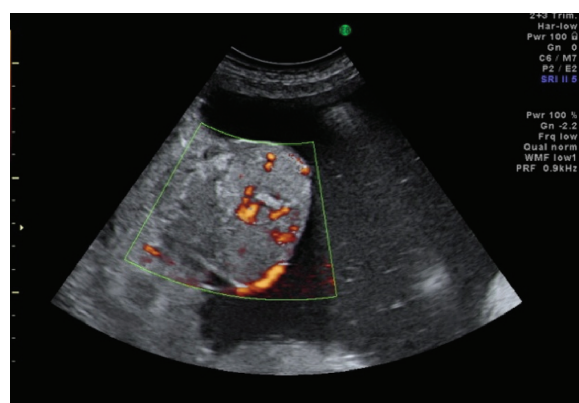


Fig. 3 Doppler ultrasonography at 26 weeks' gestation demonstrated prominent vasculature suggestive of chorioangioma.

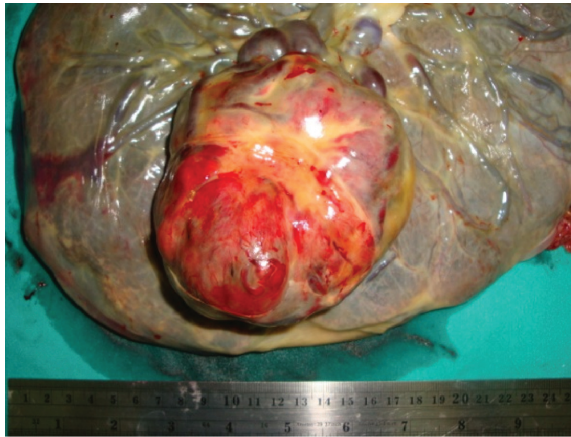


Fig. 4 Gross examination of the placenta showed a well circumscribed oval lesion.

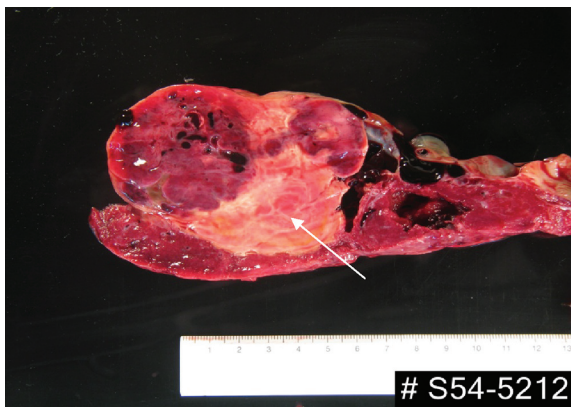

Fig. 5 The cross section of the placenta showed some necrotic areas (arrow).

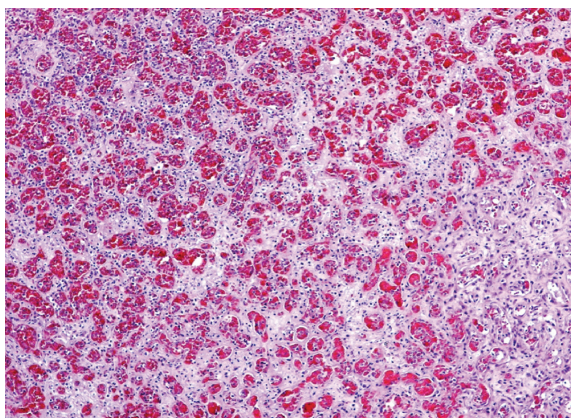


Fig. 6 Microscopic view exhibited an angiomatous proliferation.

circumscribed huge hypoechoic vasculature mass was seen at the lower end of the placenta. After induction of labor, she delivered a male hydropic fetus. Placenta was sent for histopathological examination. Histological features were consistent with placental chorioangioma.

Kusum DJ et al⁽⁹⁾ reported a full term case with absent fetal movements. Ultrasonography revealed a single hydropic intrauterine fetus with no cardiac activity. The patient underwent labor and the placenta was sent for histopathological examination. Microscopic examination showed a tumor mass composed of capillary and cavernous sized blood vessels. Thus, a final diagnosis was placental chorioangiomas leading to hydrops fetalis and intrauterine fetal death.

In the presented case, the patient suffered from massive polyhydramnios. A 2D ultrasonography showed evidence of chorioangioma. A 3D ultrasonography, as in this case, was used to get the better images of the chorioangioma. The quality of these images allowed the parents to get more understanding about the abnormal placental morphology. Serial ultrasound examinations surprisingly revealed decreasing of amniotic fluid. This finding can be explained by the necrosis of some parts of the chorioangioma demonstrated by microscopic examination.

This case was diagnosed late, 26 weeks gestation, due to lack of awareness of placental abnormality. Thorough ultrasonography of the placenta might help to improve the early diagnosis.

There are several prenatal therapeutic treatments adopted in the management of chorioangioma, for example, ultrasound guided interstitial laser therapy⁽¹⁰⁾, in-utero endoscopic devascularization with use of suture ligation or bipolar cautery via fetoscopy⁽¹¹⁾, microcoil embolisation⁽¹²⁾, and alcohol injection⁽¹³⁾. However, such procedures are mostly invasive and can cause serious complications such as intrauterine infection, preterm labor, preterm birth, or even fetal death. There is no consensus for the true efficacy and successful rate of these methods. Follow-up with regular ultrasonography for amniotic fluid index, color Doppler waveform of the middle cerebral artery for fetal anemia and pre-hydropic signs should be another option because large chorioangiomas may have spontaneous infarction which decrease in tumor volume, blood flow and, finally, amniotic fluid. Such situations improve fetal hemodynamics and clinical outcomes. Chazotte C et al⁽¹⁴⁾ reported a case of a large chorioangioma diagnosed prenatally with hydrops

fetalis in the second trimester. Spontaneous regression of the tumor occurred, associated with some resolution of the fetal hydrops and delivery at near term with good neonatal outcome.

Conclusion

The quality of 3D ultrasonography images allow the parents to get more understanding about the abnormal morphology of chorioangioma. Several therapeutic treatments adopted in the management of chorioangioma. However, these procedures can cause serious complications. Regular ultrasonography should be one of the options because large chorioangiomas may have spontaneous infarction that improve fetal hemodynamics and clinical outcomes.

Potential conflicts of interest

None.

References

1. Clarke J. Account of a tumor found in the substance of the human placenta. *Phil Trans R Soc* 1798; 88: 361.
2. Jauniaux E, Campbell S. Ultrasonographic assessment of placental abnormalities. *Am J Obstet Gynecol* 1990; 163 (5 Pt 1): 1650-8.
3. Harris RD, Cho C, Wells WA. Sonography of the placenta with emphasis on pathological correlation. *Semin Ultrasound CT MR* 1996; 17: 66-89.
4. Demiriz M, Tunca Y, Ozcan A, Celasun B, Finci R. Placental chorioangioma associated with fetal cardiac complication. *Acta Obstet Gynecol Scand* 1997; 76: 708-9.
5. Zoppini C, Acaia B, Lucci G, Pagni L, Tassis B, Nicolini U. Varying clinical course of large placental chorioangiomas. Report of 3 cases. *Fetal Diagn Ther* 1997; 12: 61-4.
6. Batukan C, Holzgreve W, Danzer E, Bruder E, Hosli I, Tercanli S. Large placental chorioangioma as a cause of sudden intrauterine fetal death. A case report. *Fetal Diagn Ther* 2001; 16: 394-7.
7. Bashiri A, Furman B, Erez O, Wiznitzer A, Holcberg G, Mazor M. Twelve cases of placental chorioangioma. Pregnancy outcome and clinical significance. *Arch Gynecol Obstet* 2002; 266: 53-5.
8. Shafqat G, Iqbal F, Rizvi F. Chorioangioma of the placenta with hydrops foetalis. *J Pak Med Assoc* 2009; 59: 411-2.
9. Kusum DJ, Jigna BD, Jyoti DR. Placental chorioangioma: a cause of hydrops fetalis and intrauterine fetal death. *Bombay Hosp J [Internet]* 2000 [cited 2011 Dec 10]. Available from: http://www.bhj.org/journal/2000_4202_apr00/case_411.htm
10. Bhide A, Prefumo F, Sairam S, Carvalho J, Thilaganathan B. Ultrasound-guided interstitial laser therapy for the treatment of placental chorioangioma. *Obstet Gynecol* 2003; 102: 1189-91.
11. Quintero RA, Reich H, Romero R, Johnson MP, Goncalves L, Evans MI. In utero endoscopic devascularization of a large chorioangioma. *Ultrasound Obstet Gynecol* 1996; 8: 48-52.
12. Lau TK, Leung TY, Yu SC, To KF, Leung TN. Prenatal treatment of chorioangioma by microcoil embolisation. *BJOG* 2003; 110: 70-3.
13. Nicolini U, Zuliani G, Caravelli E, Fogliani R, Poblete A, Roberts A. Alcohol injection: a new method of treating placental chorioangiomas. *Lancet* 1999; 353: 1674-5.
14. Chazotte C, Girz B, Koenigsberg M, Cohen WR. Spontaneous infarction of placental chorioangioma and associated regression of hydrops fetalis. *Am J Obstet Gynecol* 1990; 163: 1180-1.

ภาพคลื่นเสียงความถี่สูง 3 มิติ ก่อนคลอดและการรักษาแบบประคับประคองของเนื้องอกรกชนิดโคลิโอแองจิโอมา:
รายงานผู้ป่วย 1 ราย

ปิยะมาส ศักดิ์ศิริอุดมไพ, ถวัลย์วงศ์ รัตนสิริ, จตุพร ดวงกำ, พิไลวรรณ กลีบแก้ว, ผกาพรรณ เกียรติชูสกุล

สตรีตั้งครรภ์อายุ 24 ปี ตรวจพบว่ามีขนาดมดลูกโตกว่าอายุครรภ์ ตรวจคลื่นเสียงความถี่สูงชนิด 2 มิติ พร้อมดอปเปลอร์ พบก้อนขนาดใหญ่ที่มีหลอดเลือดแดงจำนวนมากบริเวณรก ร่วมกับภาวะปริมาณน้ำคร่ำมาก ก้อนดังกล่าวเข้าได้กับเนื้องอกรกชนิดโคลิโอแองจิโอมา การตรวจคลื่นเสียงความถี่สูงชนิด 3 มิติทำให้ได้ภาพเนื้องอกรกที่ชัดเจนมากขึ้นซึ่งเป็นประโยชน์ในการให้คำปรึกษาแก่คู่สมรสหลังจากติดตามโดยการใช้อัลตราซาวด์สูง พบว่าปริมาณน้ำคร่ำลดลง การตรวจติดตามทารกหลังคลอด 3 เดือน พบว่า ทารกแข็งแรงดี

แม้ว่าปัจจุบันมีแนวทางการรักษาเนื้องอกรกหลายวิธี แต่วิธีการดังกล่าวอาจทำให้เกิดภาวะแทรกซ้อนที่รุนแรง การรักษาแบบประคับประคองจึงเป็นทางเลือกหนึ่งเนื่องจากเนื้องอกรกที่มีขนาดใหญ่อาจมีบางตำแหน่งที่เลือดไปเลี้ยงไม่ทั่วถึง ทำให้บางส่วนของเนื้องอกตาย ซึ่งทำให้การไหลเวียนโลหิตรวมถึงผลลัพธ์ของการตั้งครรภ์ดีขึ้น
