

# Vascular Access Stenosis and Central Vein Obstruction Interventions: Five Years of Experience in Ramathibodi Hospital

Jiemjit Tapaneeyakorn MD\*,  
Thanipa Inman MD\*, Tanapong Panpikul MD\*,  
Banjongsak Wedsart MD\*, Jesada Suvikrom MD\*

\* Division of Body Intervention, Department of Radiology, Ramathibodi Hospital, Mahidol University Bangkok, Thailand

**Objective:** To evaluate initial post-treatment and six months outcome of patients sent to the intervention radiology unit with vascular access malfunctions.

**Material and Method:** A retrospective study of venoplasty, venoplasty with stenting, and venoplasty with thrombolysis for vascular access failure patients, included 53 patients with 67 interventional radiology procedures at the intervention radiology unit of Ramathibodi Hospital between January 2004 and June 2009.

**Results:** Sixty-seven intervention procedures were performed in 53 patients. Two patients had severe stenosis of AVF anastomosis with a resulting in failure to perform venoplasty. There were 34 lesions of central venous obstruction. The lesions were usually short and 79% shorter than 4.0 cm. In the group of central venous obstruction that performed venoplasty alone, the degree of stenosis was  $58.7 \pm 18.6\%$  (mean  $\pm$  SD) with 69.2% technical success and 84.6% clinical successes. However, the technical success was increased to 71.4% and clinical success was increased to 100% in the stent placement group. At the six-month follow-up, there was no significant clinical re-obstruction. Fair to good outcomes of interventional procedures of vascular access and peripheral venous stenosis were achieved. Within the group of 14 lesions of patients who underwent AVBG, the degree of stenosis was  $64.4 \pm 14.4\%$  with 57.1% technical success and 100% clinical successes. In the other group of 19 lesions that underwent native AVF, the degree of stenosis was  $61 \pm 9.4\%$  with 52.6% technical success and 89% clinical successes. Two patients had re-stenosis and thrombosis in AVBG six months after treatment procedure.

**Conclusion:** Percutaneous interventional radiology procedure continues to play a beneficial role in treatment, and remains the first treatment of choice in vascular access malfunction and corollary complications of central venous obstruction. The technical success rate of treatments is determined by morphologic features of each lesion, with the identification of these features helping in proper planning and the use of appropriate instruments.

**Keywords:** Interventional radiology, Vascular access stenosis, Central venous obstruction, Venoplasty, Stenting, Thrombolysis

*J Med Assoc Thai* 2012; 95 (9): 1211-8

Full text. e-Journal: <http://jmat.mat.or.th>

End-stage renal disease is one of the main health problems worldwide<sup>(1)</sup> including tertiary care hospitals in Thailand. Vascular access for hemodialysis is one of the definitive surgical solutions for patients with end-stage renal disease (ESRD) who are not suitable for peritoneal dialysis<sup>(1)</sup>. Spontaneous thrombosis, development of flow-reducing stenosis in the afferent artery or efferent vein, central vein stenosis, and central vein occlusion are the most

common events after vascular access, all of which cause dialysis failure<sup>(2-4)</sup>.

For years, the standard treatment for failing hemodialysis access has been surgical revision. In recent years, percutaneous intervention in venous stenosis or central venous obstruction treatment has consisted of either balloon venoplasty alone, or additional stent placement, and has become a mainstay in the treatment of hemodialysis-related obstruction<sup>(5,6)</sup>.

Data correction and the study of intervention treatments and techniques for vascular access dysfunction, and the corollary complications of central venous obstruction, are both of growing interest and necessary in improving treatment results.

**Correspondence to:**

Tapaneeyakorn J, Division of Body Intervention, Department of Radiology, Ramathibodi Hospital, Mahidol University, Bangkok 10400, Thailand.

Phone: 081-810-5032

E-mails: [rajtp@mahidol.ac.th](mailto:rajtp@mahidol.ac.th)

## Material and Method

### Patient

A retrospective study, approved by the authors' institutional research ethics committee, we reviewed the angiographic data of patients who underwent vascular access for hemodialysis and who had problems of malfunction of vascular access. Patients were sent to intervention radiology unit for evaluation and treatment during a five-year period, between January 2004 and June 2009. These data were derived from a search of databases at the intervention unit of the Department of Radiology, Ramathibodi Hospital.

The inclusion criteria consisted of those patients who underwent vascular access for hemodialysis and who had problems of malfunction of vascular access, such as vascular access stenosis, symptoms of central vein stenosis or occlusion, and those sent for intervention. Patients with missing or inadequate data were excluded.

Before intervention procedure, informed consent was obtained from all patients.

Data on patient demographics and clinical assessment with three and six month outcomes were obtained from medical records.

This study included 53 patients (male 33, female 20, age 34 to 84 years) with 67 intervention procedures (Table 1). Twenty-two patients had a polytetrafluoroethylene implant graft (Gore-Tex; W.L. Gore and associates, Elkton, Md). Thirty-one patients had native arteriovenous fistula. No patient had venous transposition fistula.

### Diagnostic venography and intervention technique

Before venoplasty or stent deployment, subtraction angiography was performed to study the anatomic and pathologic characteristics of the vessel after retrograde or antegrade venous puncture of fistula vein or graft with Jelco No 20 G.

Non-ionic contrast media used in the procedure was Ioxaglate 320 (Hexabrix<sup>®</sup>, Guerbet, Paris, France). Total dose of contrast media was 1 to 2 ml/kg body weight. The angiogram machine used was Infinic VC-I flat panel detector DSA (Toshiba, Japan).

Intervention treatment techniques included balloon venoplasty, balloon venoplasty with catheter direct thrombolysis, and stent placement after balloon venoplasty.

The use of balloon venoplasty and self-expanding stents using varying sizes of sheaths, guided wires, catheters, balloon catheters, and stents depended on the adjacent normal size of native vessel or graft near the stenotic segment.

The stents used in intervention are of two types; Sentinol<sup>®</sup> Self-Expanding Nitinol Biliary Stent System (Boston Scientific Corporation, USA) and S.M.A.R.T<sup>®</sup> Transhepatic Biliary Stents (Cordis Corporation, USA). Sentinol stent sizes are 5 x 40, 6 x 40, 7 x 3.9 mm and Smart stent sizes are 7 x 40, 8 x 40, 8 x 80, 10 x 40, 10 x 80, 12 x 40, 12 x 80, 14 x 60, 14 x 80 mm. The balloon catheter sizes are 5 x 40, 6 x 20, 6 x 40, 7 x 40, 7 x 80, 8 x 20, 8 x 40, 8 x 80, 9 x 40, 10 x 20, 10 x 40, 10 x 60, 10 x 80, 12 x 40, 12 x 60, 14 x 60, 15 x 40, 15 x 50 mm.

For angioplasty and stent placement, the approach to the lesion depended on its anatomic location. In forearm veins, the draining shunt vein was always punctured in a proximal section in a retrograde manner. In upper-arm veins, puncture was performed in a distal portion of the shunt vein or within the graft loop. For central venous lesions, an attempt was always made to traverse the lesion by a brachial or transfemoral venous approach. In lesions of the brachiocephalic vein, sometimes, both a femoral and brachial punctures were performed to monitor stent deployment from a second approach to facilitate exact placement.

Stent placement itself was performed by a transbrachial or transfemoral venous approach depending on the size of the stent used, the final location of the stent, and anatomic considerations (e.g. orifices of important collateral veins).

Data analysis was performed using Stata version 10. The patient results were presented in frequency, percentage, mean, and standard deviation. Scatter plot distribution was also presented.

## Results

Sixty-seven interventions were performed in 53 patients with malfunctions of vascular accesses or symptomatic central venous obstruction. Three patients

**Table 1.** Patient characteristics (n = 53)

Characteristic	Number	%
Demographics		
Age (year)	34-84	-
Male	33	62.2
Female	20	37.8
Type of access		
Prosthetic graft	22	41.5
Simple native fistula	31	58.5
Venous transposition fistula	0	0

**Table 2.** Success rate (%) (n = 53)

	Technical success	Clinical success
Central venous obstruction: angioplasty alone	69.2	84.6
Central venous obstruction: angioplasty with stent placement	71.4	100
Vascular access and peripheral vein stenosis: AVBG group	57.1	100
Vascular access and peripheral vein stenosis: native AVF group	52.6	89.5

**Table 3.** Central venous obstruction sites (31 patients, 34 lesions)

Central venous obstruction			Right		Left	
Site	Number	%	Number	%	Number	%
Brachiocephalic vein	15	44	6	40	9	60
Subclavian vein	13	38	6	46	7	54
Brachiocephalic vein-SVC	3	8	2	67	1	33
Axillary vein	2	6	0	0	2	100
Subclavian vein-Brachiocephalic vein-SVC	1	4	1	100	0	0

(6%) had both central venous obstruction and stenosis of vascular access or upper extremity vein. Twelve patients (23.5%) also had individual multiple lesions, which were divided into two groups of lesion location.

Treatment outcomes were evaluated on both technical and clinical successes (Table 2).

Technical success was defined as less than 30% of residual stenosis and clinical success was defined as no dialysis access failure within one week after the procedure.

**Central venous obstruction**

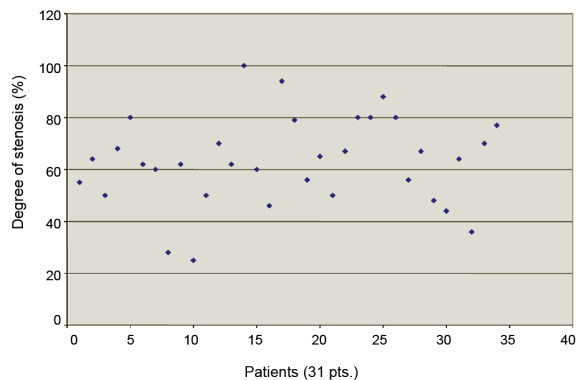
Thirty-one patients had central venous obstruction (34 lesions). The patients mostly presented with swelling of the effected arm or shoulder and pain or impaired function of dialysis. Venography demonstrated venous obstruction localized at the

brachiocephalic vein (15 lesions), subclavian vein (13 lesions), brachiocephalic vein-SVC (3 lesions), subclavian vein-brachiocephalic-SVC (1 lesion), and axillary vein (2 lesions) (Table 3).

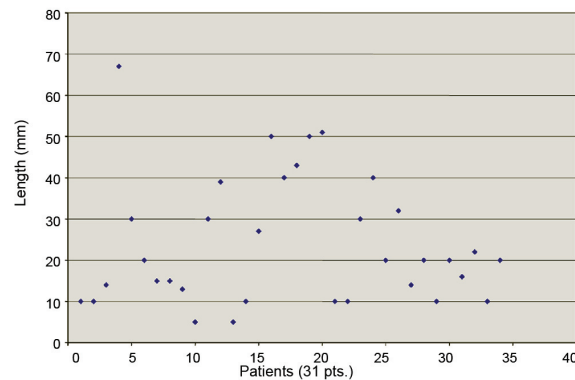
Degree of central vein stenosis is measured from 25% stenosis to 100% (complete obstruction). The most degree of stenosis was in a range of 40 to 80% (Fig. 1); (average degree of stenosis is 73%).

The stenosis lesions were usually short (mean length ± SD is 2.0 cm ± 1.5 cm), with lengths ranging from 0.5 cm to 6.7 cm. Twenty-seven lesions (79%) were shorter than 4.0 cm, six lesions (18%) were 4.0-6.0 cm long, and only one lesion (3%) was longer than 6.0 cm (Fig. 2).

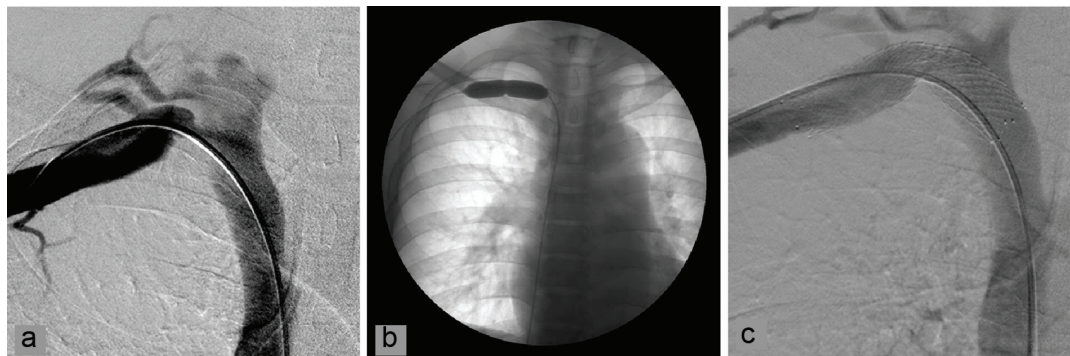
In the 13 central venous obstructive lesions where PTA alone was performed, the degree of stenosis was 27 to 80%, 58.7 ± 18.6% (mean ± SD). The degree



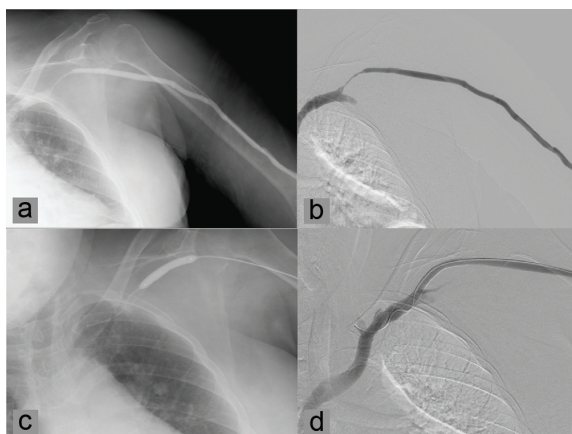
**Fig. 1** Degree of central venous stenosis



**Fig. 2** Length of stenotic segment



**Fig. 3** (a) Digital subtraction angiogram demonstrates an area of high-grade stenosis at right subclavian vein (b) Balloon venoplasty (balloon size 12 x 40 mm) at stenotic segment, show residual focal stenosis of this lesion (c) After deployment of a 12 x 40 mm SMART stent, improved stenosis with minimal residual kinking stenosis can be seen



**Fig. 4** (a, b) Angiogram, subtraction angiogram show a high-grade stenosis at the venous anastomosis of AVF (c) A 6 x 40 mm balloon venoplasty (d) Post venoplasty with stent placement shows 100% recanalization with no residual stenosis

of residual stenosis post PTA was 3 to 46%,  $27 \pm 11.2\%$  represents 69.2% technical success. We found that two patients, who had venoplasty at brachiocephalic vein, presented with stenosis at their AVBG within one-week post-procedure represents 84.6% clinical success.

The 21 patients (21 lesions) who received PTA with stent placement, showed the degree of stenosis 36 to 100%,  $67 \pm 15.9\%$ . The degree of residual stenosis post stent placement was 0 to 44%,  $21.4 \pm 13.2\%$ . The technical success was 71.4% and clinical success was 100%. Follow-up of one week after intervention showed decreased swelling of the effected arm and shoulder or back. There was no re-stenosis at six-month follow-up.

The stents were located in the brachiocephalic veins (12 lesions), subclavian veins (7 lesions), subclavian-brachiocephalic-SVC (1 lesion), and axillary vein (1 lesion).

#### ***Vascular access and peripheral vein stenosis***

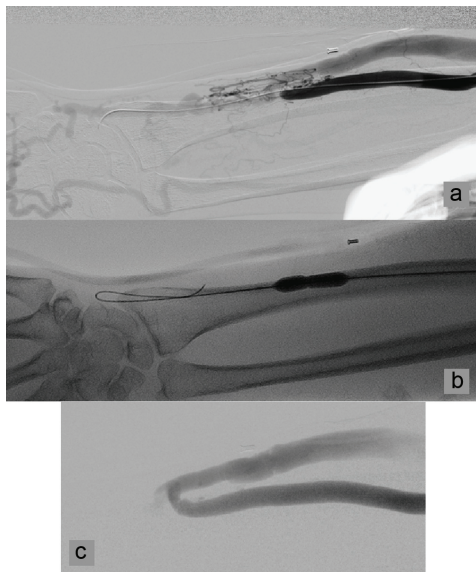
The patients' symptoms were found in physical examinations (absent thrill, abnormal bruit, or distal edema); with abnormalities identified during dialysis sessions (prolonged bleeding from needle puncture sites or difficulty in cannulation). All of the lesions were treated by balloon venoplasty except one lesion that had stenosis in AVBG with in-graft thrombosis. It was treated by direct catheter thrombolysis with balloon venoplasty.

The 33 peripheral venous stenosis lesions were divided into two main groups by the type of vascular access; 14 lesions of patients who underwent AVBG and 19 lesions of patients who underwent native AVF.

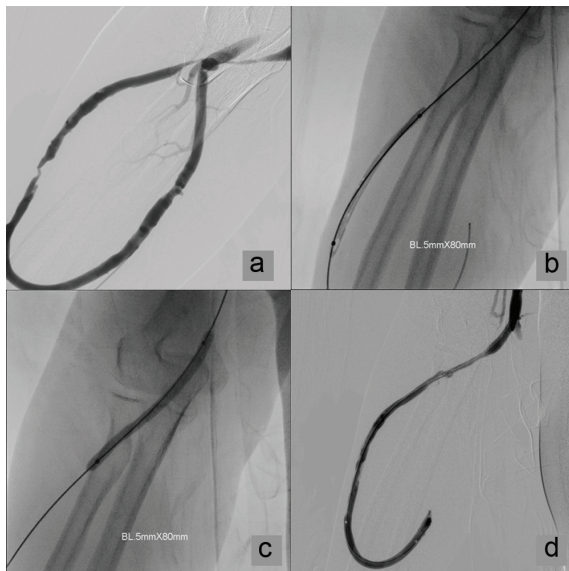
1) The 14 lesions of AVBG patients had shown eight lesions in graft (57%), five lesions at venous anastomosis (36%), and one lesion at proximal cephalic vein (7%). The degree of stenosis was 35 to 85%,  $64.4 \pm 14.4\%$ . The degree of residual stenosis post venoplasty and thrombolysis was 0 to 55%,  $25 \pm 17.3\%$ .

The authors achieved 57.1% technical success with 100% clinical success for this group.

2) Nineteen lesions of the patients who underwent native AVF had stenosis at venous side, within 2.0 cm distally to the anastomosis or stenosis at the anastomosis itself. The degree of stenosis was 45 to 80%,  $61 \pm 9.4\%$ . The degree of residual stenosis post PTA was 0 to 55%,  $30.3 \pm 16\%$ .



**Fig. 5** (a) Angiogram shows a high-grade stenosis with collateral vessels at the venous anastomosis of AVF (radial artery-cephalic vein) at right forearm (b) A 6-mm venoplasty balloon across the stenosis (c) Post venoplasty angiogram shows 70% recanalization with residual 30% stenosis



**Fig. 6** (a) Angiogram shows two sites of severe stenosis at the venous anastomosis, venous outflow and venous limb of PTFE graft at right forearm (b, c) A 5 x 80 mm venoplasty balloon across the both sites of stenosis (d) Post venoplasty angiogram shows 50-60% recanalization without complication

For this group of lesions, there was 52.6% technical success with 89.5% clinical success. Two patients (also 2 lesions) who had severe fistula stenosis at left cubital region (brachial artery anastomosis with antecubital vein) and at left wrist (radial artery anastomosis with cephalic vein), percutaneous venoplasty was unsuccessful due to the inability to pass the safety guide wire through the stenotic segments. These two patients were referred to surgical treatment.

In follow-up, the overall clinical outcomes were fair to good for dialysis. However, two patients who underwent AVBG had recurrent stenosis and occlusion of the graft within six months post venoplasty of the graft. Further surgical treatment to create a new vascular access was performed sequentially.

## Discussion

### Central venous obstruction

In the present study the most frequent stenosis locations of central venous obstruction are the brachiocephalic and subclavian veins, and are usually of short lesions lengths (mean length  $\pm$  SD, 2.0 cm  $\pm$  1.5 cm, and 79% shorter than 4.0 cm). The overall results of intervention with venoplasty with stent placement in central venous obstruction were encouraging. The degree of residual stenosis was  $21.4 \pm 13.2\%$ , technical success was 71.4%, and clinical success was 100% with immediate outcomes slightly better than the other group of venous obstructive lesions where venoplasty alone was performed. The degree of residual stenosis of this latter group was  $27 \pm 11.2\%$ , 69.2% technical success, and 84.6% clinical success. However, within 6-month post intervention follow-up, no significant clinical re-obstruction was found in either group of patients.

The technical and clinical successes in the present study corresponded to results from other research and published papers<sup>(7-13)</sup>. The authors have shown that the technical success of PTA is determined by the morphologic features of each lesion and that some types of lesions are suitable for percutaneous venoplasty alone or combined with percutaneous venoplasty with stent placement. The various types of lesions include highly rigid stenosis, severe stenosis, kinking stenosis, the recoil type of stenosis, as well as re-stenosis post primary venoplasty that opening sufficiently during balloon inflation and collapses immediately after balloon deflation necessitating stent implantation. Indeed, stents can improve the technical success in the treatment of some types of lesions. They

are helpful particularly for sealing dissections or circumscribed perforations, and for establishing patency of chronic venous occlusions. Results after angioplasty or venoplasty of highly resistant stenosis can be improved by stent implantation<sup>(9,11,13,14)</sup>. In the case of mild stenosis without recoil, percutaneous venoplasty alone remains a first choice in treatment.

### **Vascular access stenosis**

A majority of graft failures is due to thrombosis, and the thrombosed grafts usually have an underlying stenosis at the venous anastomosis or in the draining vein<sup>(2-4)</sup>. Percutaneous venoplasty and thrombolysis are beneficial treatments in these situations. The present study shows fair to good outcomes in the interventions of vascular access and peripheral vein stenosis in patients who underwent AVBG and AVF. The degree of residual stenosis was  $25 \pm 17.3\%$  and  $30.3 \pm 16\%$ , respectively. The technical success was 57.1% and 52.6%, respectively and the clinical success was 100% and 89.5%, respectively.

The present study also illustrated the limitations of technical processes for more severe degrees of the stenotic segment, as was seen in the examples of two patients who had severe stenosis at the anastomoses of AVF, and where the failure to pass safety guide wires through the stenotic segment occurred.

With respect to short outcomes, two patients (14.3%) experienced re-stenosis and thrombosis within the graft at six-month post venoplasty.

Recent studies present many techniques for the treatment of graft thrombosis. They are cutting balloon, clot extraction, stent implantation, and high-pressure balloon venoplasty, including graft observation programs. In addition, experimental research surrounding adventitial delivery of a platelet-derived endothelial cell growth factor gene to prevent intimal hyperplasia of vein graft, has been shown to help to decrease re-clot and help increase the successful rate of intervention in patients who underwent AVBG and AVF as well<sup>(4,9,11-13)</sup>.

### **Conclusion**

Percutaneous intervention continues to play a beneficial role in treatment and remains the first treatment of choice in vascular access for hemodialysis malfunction and its complications such as central venous obstruction. The technical success rate of venoplasty is determined by the morphologic features of each lesion and the accurate assessment of these

features are essential for proper treatment planning and for the use of appropriate instruments.

### **Potential conflicts of interest**

None.

### **References**

1. Punal J, Lema LV, Sanchez-Guisande D, Ruano-Ravina A. Clinical effectiveness and quality of life of conventional haemodialysis versus short daily haemodialysis: a systematic review. *Nephrol Dial Transplant* 2008; 23: 2634-46.
2. Criado E, Marston WA, Jaques PF, Mauro MA, Keagy BA. Proximal venous outflow obstruction in patients with upper extremity arteriovenous dialysis access. *Ann Vasc Surg* 1994; 8: 530-5.
3. De Marchi S, Falletti E, Giacomello R, Stel G, Cecchin E, Sepiacci G, et al. Risk factors for vascular disease and arteriovenous fistula dysfunction in hemodialysis patients. *J Am Soc Nephrol* 1996; 7: 1169-77.
4. Allon M. Current management of vascular access. *Clin J Am Soc Nephrol* 2007; 2: 786-800.
5. Sofocleous CT, Cerveira J, Cooper SG. Dialysis fistulas [Internet]. Updated 2011 [cited 2012 Jul 16]. Available from: <http://emedicine.medscape.com/article/419393-overview>
6. Carrafiello G, Lagana D, Mangini M, Recaldini C, Lumia D, Giorgianni A, et al. Cutting balloon angioplasty for the treatment of stenosis in hemodialysis arteriovenous fistulas. *Vascular Disease Management* 2005; 2: 55-9.
7. Saeed M, Newman GE, McCann RL, Sussman SK, Braun SD, Dunnick NR. Stenoses in dialysis fistulas: treatment with percutaneous angioplasty. *Radiology* 1987; 164: 693-7.
8. Smith TP, Hunter DW, Darcy MD, Castaneda-Zuniga WR, Amplatz K. Thrombosed synthetic hemodialysis access fistulas: the success of combined thrombectomy and angioplasty (technical note). *AJR Am J Roentgenol* 1986; 147: 161-3.
9. Vorwerk D, Guenther RW, Mann H, Bohndorf K, Keulers P, Alzen G, et al. Venous stenosis and occlusion in hemodialysis shunts: follow-up results of stent placement in 65 patients. *Radiology* 1995; 195: 140-6.
10. Glanz S, Gordon DH, Butt KM, Hong J, Lipkowitz GS. The role of percutaneous angioplasty in the management of chronic hemodialysis fistulas. *Ann Surg* 1987; 206: 777-81.

11. Dammers R, de Haan MW, Planken NR, van der Sande FM, Tordior JH. Central vein obstruction in hemodialysis patients: Results of radiological and surgical Intervention Eur J Vasc Endovasc Surg 2003; 26: 317-21.
12. Trerotola SO, Stavropoulos SW, Shlansky-Goldberg R, Tuite CM, Kobrin S, Rudnick MR. Hemodialysis-related venous stenosis: treatment with ultrahigh-pressure angioplasty balloons. Radiology 2004; 231: 259-62.
13. Nikolic B. Hemodialysis fistula interventions: diagnostic and treatment challenges and technical considerations. Tech Vasc Interv Radiol 2008; 11: 167-74.
14. Vorwerk D, Gunther RW, Bohndorf K, Kistler D, Gladziwa U, Sieberth HG. Follow-up results after stent placement in failing arteriovenous shunts: a three-year experience. Cardiovasc Intervent Radiol 1991; 14: 285-9.
15. Kahn D, Pontin AR, Jacobson JE, Matley P, Beningfield S, Zyl-Smit R. Arteriovenous fistula in the presence of subclavian vein thrombosis: a serious complication. Br J Surg 1990; 77: 682.
16. Trerotola SO, Turmel-Rodrigues LA. Off the beaten path: transbrachial approach for native fistula interventions. Radiology 2001; 218: 617-9.
17. Rajan DK, Bunston S, Misra S, Pinto R, Lok CE. Dysfunctional autogenous hemodialysis fistulas: outcomes after angioplasty—are there clinical predictors of patency? Radiology 2004; 232: 508-15.
18. Handa M, Li W, Morioka K, Takamori A, Yamada N, Ihaya A. Adventitial delivery of platelet-derived endothelial cell growth factor gene prevented intimal hyperplasia of vein graft. J Vasc Surg 2008; 48: 1566-74.

---

## ประสบการณ์ 5 ปี ในการรักษาการตีบตันของหลอดเลือดดำใหญ่และหลอดเลือดตัดต่อเพื่อฟอกไต โดยใช้วิธีทางรังสีร่วมรักษา

เจียมจิตร ตปนิยากร, ฐานิภา อินมั้น, ธนพงศ์ พันธุ์พิบูล, บรรจงศักดิ์ เวชศาสตร์, เจษฎา สุวิกรม

**วัตถุประสงค์:** เพื่อประเมินผลการรักษาโดยวิธีทางรังสีร่วมรักษา ของการตีบตันของหลอดเลือดตัดต่อเพื่อฟอกไต ด้วยวิธีการถ่างขยายหลอดเลือดด้วยบอลูนและการวางลวดตาข่าย ในทันทีหลังทำการหัตถการและติดตามผลในระยะเวลา 6 เดือนหลังการรักษา

**วัสดุและวิธีการ:** เป็นการศึกษาข้อมูลย้อนหลังที่ได้รับการอนุมัติจากคณะกรรมการจริยธรรมการวิจัยในคนของโรงพยาบาลรามธิบดีแล้ว โดยศึกษาการถ่างขยายหลอดเลือดด้วยบอลูน การถ่างขยายหลอดเลือดร่วมกับการวางลวดตาข่าย และการถ่างขยายหลอดเลือดร่วมกับการละลายลิ่มเลือด ในผู้ป่วยจำนวน 53 ราย (เป็นชาย 33 ราย และ หญิง 20 ราย อายุระหว่าง 34 ถึง 84 ปี) ที่มาทำการรักษาโดยวิธีทางรังสีร่วมรักษา จำนวน 67 หัตถการ ที่หน่วยรังสีร่วมรักษา โรงพยาบาลรามธิบดี ในช่วงระยะเวลา 5 ปี ระหว่าง มกราคม พ.ศ. 2547 ถึง มิถุนายน พ.ศ. 2552

**ผลการศึกษา:** ผู้ป่วย 53 ราย ได้รับการรักษาโดยวิธีทางรังสีร่วมรักษาทั้งหมด 67 หัตถการ พบการตีบบริเวณหลอดเลือดดำใหญ่จำนวน 34 รอยโรค มักจะเป็นการตีบสั้นๆ (ประมาณ 2 ซม.  $\pm$  1.5 ซม.) และมากกว่า 79 เปอร์เซ็นต์ มีการตีบที่สั้นกว่า 4 ซม. ในผู้ป่วยกลุ่มที่ได้รับการรักษาด้วยการถ่างขยายด้วยบอลูนอย่างเดียว มีระดับการตีบของหลอดเลือดก่อนรักษา  $58.7 \pm 18.6$  เปอร์เซ็นต์ การรักษาประสบความสำเร็จในด้านเทคนิค 69.2 เปอร์เซ็นต์ และในด้านคลินิก 84.6 เปอร์เซ็นต์ อย่างไรก็ตามความสำเร็จในด้านเทคนิคเพิ่มขึ้นเป็น 71.4 เปอร์เซ็นต์ และในด้านคลินิกเพิ่มขึ้นเป็น 100 เปอร์เซ็นต์ ในกลุ่มที่ทำการถ่างขยายด้วยบอลูน และวางลวดตาข่ายไปในคราวเดียวกัน ซึ่งถือเป็นผลการรักษาที่น่าพอใจ นอกจากนั้น การติดตามผลการรักษาที่ระยะเวลา 6 เดือนก็ไม่พบว่ามีการตีบซ้ำของหลอดเลือดที่ทำการรักษาไปแล้ว

ส่วนในกลุ่มที่มีปัญหาการตีบของหลอดเลือดดำตัดต่อเพื่อฟอกไต หรือ หลอดเลือดดำส่วนปลาย จะแบ่งออกเป็น 2 กลุ่มคือ กลุ่มที่ใช้หลอดเลือดเทียม (AVBG) กับกลุ่มที่ใช้การเชื่อมต่อหลอดเลือดธรรมชาติ ในกลุ่มที่ใช้หลอดเลือดเทียมมี 14 รอยโรค ระดับการตีบก่อนรักษาประมาณ  $64.41 \pm 14.41$  เปอร์เซ็นต์ หลังการรักษาด้วยการถ่างขยายหลอดเลือดและการใช้ยาละลายลิ่มเลือด พบว่าประสบความสำเร็จในด้านเทคนิค 57.1 เปอร์เซ็นต์ และในด้านคลินิก 100 เปอร์เซ็นต์

ในกลุ่มที่ใช้การเชื่อมต่อหลอดเลือดธรรมชาติ นั้น มี 19 รอยโรค ระดับการตีบของหลอดเลือดก่อนการรักษาประมาณ  $61 \pm 9.4$  เปอร์เซ็นต์ หลังการรักษาด้วยการถ่างขยายหลอดเลือด พบว่าประสบความสำเร็จในด้านเทคนิค 52.9 เปอร์เซ็นต์ และในด้านคลินิก 89.0 เปอร์เซ็นต์ มีผู้ป่วย 2 รายในกลุ่มนี้ มีการตีบบริเวณที่เชื่อมต่ออย่างมากทำให้ไม่สามารถใส่อุปกรณ์ผ่านจุดตีบได้ จึงไม่สามารถรักษาโดยวิธีทางรังสีร่วมรักษาได้

โดยรวมในกลุ่มที่มีปัญหาการตีบของหลอดเลือดดำตัดต่อเพื่อฟอกไต หรือ หลอดเลือดดำส่วนปลายนี้ การติดตามผลการรักษาภายในระยะเวลา 6 เดือน พบว่ามีผู้ป่วย 2 ราย เกิดการตีบซ้ำและมีลิ่มเลือดในหลอดเลือดเทียม

**สรุป:** ควรเลือกการรักษาผู้ป่วยที่มีปัญหาการตีบตันของหลอดเลือดตัดต่อเพื่อฟอกไต หรือ หลอดเลือดดำใหญ่ ด้วยวิธีการของรังสีร่วมรักษา ซึ่งเป็นวิธีรักษาที่มีประสิทธิภาพ ส่วนประสิทธิผลของการรักษานั้นสามารถประเมินได้โดยอาศัยคุณลักษณะทางกายภาพของแต่ละรอยโรคซึ่งลักษณะดังกล่าวจะช่วยในการวางแผนการรักษา และการเลือกใช้อุปกรณ์ได้อย่างเหมาะสม

---