



Resolution of Eosinophilia after Treatment of Cutaneous Gnathostomiasis

Kanyarat Kraivichian MD*,
Surang Nuchprayoon MD, PhD*, Padet Siriyasatien MD, PhD*,
Wilai Saksirisamphan MSc*, Issarang Nuchprayoon MD, PhD**

* Department of Parasitology, Faculty of Medicine, Chulalongkorn University

** Department of Pediatrics, Faculty of Medicine, Chulalongkorn University

The present study was to investigate the dynamics of eosinophil in peripheral blood of patients with cutaneous gnathostomiasis before and after worm removal. The total of 28 proven cases of cutaneous gnathostomiasis treated by albendazole were included in the present study. The absolute eosinophil count (AEC) was higher than 500/ul during infestation in almost all the patients, the positive rate was 89%, and significantly decreased to normal level after receiving albendazole and worm removal within 3 months in 96%. In conclusion, an increase of AEC is another important hallmark of cutaneous gnathostomiasis and this parameter could be the earlier indicator for responsiveness to treatment.

Keywords: Gnathostomiasis, Eosinophilia, Albendazole

J Med Assoc Thai 2005; 88(Suppl 4): S163-6

Full text. e-Journal: <http://www.medassothai.org/journal>

Cutaneous Gnathostomiasis is more common in Southeast Asia, especially in Japan, China and Thailand⁽¹⁻³⁾. The most common skin manifestation is characterized by intermittent migratory swelling. There have been reports of the worm migration to other organs (eye, lung, intestine and brain) that causes serious complications and death⁽⁴⁻⁷⁾. To date, the definitive diagnosis of cutaneous gnathostomiasis still requires the demonstration of the worm from the skin lesion or biopsy material. The presumptive diagnosis is made by the history of consuming raw or undercooked flesh of second intermediate or paratenic hosts containing encysted L3 infective larvae, eosinophilia and presence of antibodies against a specific 24-kDa antigen for *Gnathostoma spinigerum* by Western blot analysis. One of the problems in disease treatment is the monitoring of the patient during the follow-up period. Although the immunodiagnosis has been given 100% sensitivity and 100% specificity for the disease, it could not differentiate between current and past infection⁽⁸⁾.

In addition to the increase in the number of circulating eosinophils in the patient with suspected and proven cases of cutaneous gnathostomiasis, a massive eosinophil infiltration can be noted either at the site of the parasite invasion or migration, suggesting that eosinophil may play a pivotal role in the host defense during current infection with this parasite⁽⁹⁾. Unfortunately, the correlation between clinical features of the disease and eosinophilia has not yet been studied. Absolute eosinophil count in the peripheral blood might be used as the indicator that relates to screening, effect of treatment and follow-up in cutaneous gnathostomiasis. The aim of the study was to investigate the dynamics of eosinophil before and after treatment with albendazole and worm removal.

Material and Method

The study populations were recruited from the previous studies^(10,11). All of the selected 28 patients were diagnosed with cutaneous gnathostomiasis based on 1) clinical manifestation, that is, a history of subcutaneous migratory swelling; 2) stool examination results negative for other parasites; 3) a history of eating raw freshwater fish, crab, snake, bird or chicken and 4) worm discovery during the follow up period. The following

Correspondence to : Kraivichian K, Department of Parasitology, Faculty of Medicine, Chulalongkorn University, Bangkok 10330, Thailand.



information was extracted from each medical record: demographic information including gender and age, domicile and previous medical treatment. Clinical assessment and blood examination for absolute eosinophil count were evaluated before and after treatment and following treatment once a month for 12 months or until AEC<500/ul. Eosinophilia (AEC>500/ul) was classified as mild eosinophilia (AEC between 500 and 1500/ul), moderate (AEC between 1500 and 5000/ul), or severe (AEC>5000/ul). The date of worm discovery was also recorded. All patients were treated with 400-800 mg. of albendazole per day for 21 days. Patients who had a history of allergic conditions were excluded from the present study.

Statistical analysis

The data were recorded and analyzed by using SPSS 10.0. Numerical data were summarized using descriptive statistics. Time to resolution of eosinophilia was analysed by Kaplan-Meier analysis.

Results

There were 28 patients included in the present study; 7 males and 21 females, with a mean age of 30.1 ±9.8 years (range 15-57 years). The skin involvement site and the severity of eosinophilia at the time of diagnosis are shown in Table 1. Among all the 28 patients with gnathostomiasis, the AEC ranged from 255 to 12,800 /ul, with a geometric mean of 989 /ul. Eosinophilia (AEC>500/ul) was present in 25 of 28 patients thus the positive rate of eosinophilia in cutaneous gnathostomiasis was 89%. 21 of the 28 patients (75%) had mild eosinophilia and only one patient had severe eosinophilia. After treatment with albendazole, the worm migrated superficially toward the epidermis and could be manually or surgically extracted and removed from all the patients. The parasitic worms were removed

between 4 and 45 days (average 14.0± 9.9 days, median 10.5 days) after treatment. Around 2 weeks after parasite removal, 3 of 25 patients had a transient rise in eosinophil count, from 525-1910/ul to 634-2050/ul, followed later by resolution of eosinophilia. Of 25 patients with eosinophilia, 15 patients (60%) had resolution of eosinophilia (AEC<500/ul) by day 32, and 7 patients (28%) resolved between day 32 – day 53, 2 patients (8%) resolved between day 54-day 95 and only one patient had persistent eosinophilia for more than 6 months before resolution after worm removal. Of all 28 patients who had serial blood counts for 6-9 months after initial treatment, it was observed that the AEC became <200/ul in 23 patients, and below 100/ul in 18 patients. Around half of the patients had normal eosinophil count (AEC<200/ul) by 3 months (day 83), and AEC <100/ul by 6 months (day 193) after parasite removal. Most (75 %) had normal AEC (<200/ul) around 6 months (between day 180 and 194, Fig. 1) after parasite removal. Among all 3 patients who had normal range of AEC before initial treatment, after the worms were removed, the AEC reached a minimal level (range from 46.5-87/ul), which was approximately an 80% decrease within 3 months.

Discussion

Eosinophilia is commonly associated with gnathostomiasis^(12,13). The authors found that the positive rate of eosinophilia in a proven case of cutaneous gnathostomiasis was 89%. Treatment with albendazole may immediately kill the parasite and is likely to induce the migration toward the upper epidermis. at present, there are 3 parameters for practical use to evaluate the

Table 1. The skin involvement site and the severity of eosinophilia at the time of diagnosis

Total Patients	28
Site of skin involvement	
Head and neck	5 (17.8%)
Upper extremities	15 (53.4%)
Trunk	2 (7.1%)
Lower extremities	6 (21.2%)
Blood eosinophilia: No. (range)	
Normal	3 (255-380/ul)
Mild eosinophilia	21 (525-1430/ul)
Moderate eosinophilia	3 (1910-2424/ul)
Severe eosinophilia	1 (12,800/ul)

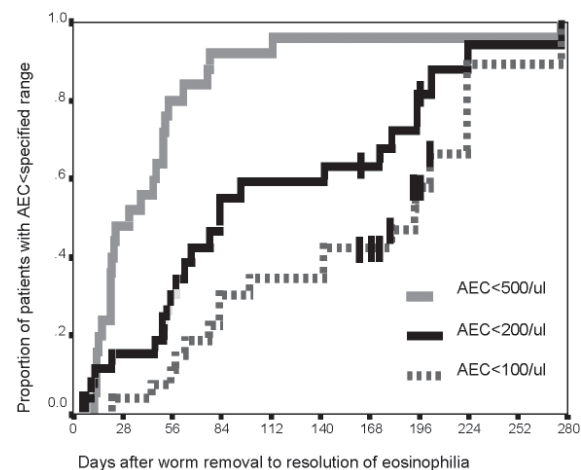


Fig. 1 Resolution of eosinophilia after albendazole and worm removal



response to treatment, Firstly, the disappearance of cutaneous swelling, it may occur as the worm migrates deeper into the human tissue; or when the worm is killed and destroyed. Thus, absence of skin lesions does not essentially imply that the worm has been eradicated or the patient cured. Secondly, Gnathostoma-specific antibody titer measured by ELISA^(14,15), the decreasing of titer can predict the result of treatment but this parameter is not appropriate for short-term follow-up as test results take over 6 months^(10,11,16). Finally, disappearance of eosinophilia, from the present study, the decreasing AEC <500/ul could be obtained in a timelier manner and is a highly appropriate indicator for responsiveness to treatment in cutaneous gnathostomiasis. After the worm removal, 24 from 25 patients (96%) had resolution of eosinophilia within 3 months. The eosinophilia persisted for more than 3 months in only one patient; possibly due to the residuals of the worm inside the body that still induced the production of eosinophil. The resolution of eosinophil levels after treatment was gradual, ranging from several weeks to months after initial treatment. The AEC>500/ul has been customarily defined as eosinophilia, and is useful for clinical diagnosis. The true baseline AEC in uninfected patient is very low. Because AEC<200 /ul, but not <100/ul, is achieved in most subjects in this study, we used AEC <200/ul as a cut-off level for 'normal' eosinophil count. In case of patients with normal AEC, after treatment, the level of AEC should decrease to lower than 80% from the baseline of each patient. Our study suggests that the dynamics of AEC in the proven case of cutaneous gnathostomiasis before and after treatment should be useful as follow-up guidelines in patients that parasites were never recovered. The AEC would be a practical parameter diagnosis and follow-up patients with gnathostomiasis, especially in remote areas where Western blot analysis or ELISA to detect specific antibodies are not widely available. In conclusion, eosinophilia is an important hallmark of cutaneous gnathostomiasis and its resolution could be the earlier indicator for responsiveness to treatment.

Acknowledgments

The authors wish to thank Associate Professor Phisai Kraivichian, Mr. Paisai Yingyourd, Miss Savitree Chandraprasert and Mr. Poonpat Lohachitranont for their kind advice and revising the manuscript.

References

1. Dangsvang S. Gnathostomiasis in Southeast

- Asia. Southeast Asian J Trop Med Public Health 1981; 12: 319-32.
2. Nawa Y. Historical review and current status of gnathostomiasis in Asia. Southeast Asian J Trop Med Public Health 1991; 22(Suppl): 217-9.
3. Daengsvang S, Pecharanond K, Phrukoudom B, Youngyi P. Gnathostomiasis in Thailand. Annual Progress Report SEATO Medical Research Laboratory Clinical Research Center, 1967: 251-71.
4. Bravo F, Sanchez MR. New and re-emerging cutaneous infectious diseases in latin America and other geographic areas. Dermatol Clin 2003; 21: 655-68.
5. Rusnak JM, Lucey DR. Clinical gnathostomiasis: case report and review of the English-language literature. Clin Infect Dis 1993; 16: 5011-33.
6. Hale DC, Blumberg L, Frean J. Case report: gnathostomiasis in two travelers to Zambia. Am J Trop Med Hyg 2003; 68: 707-9.
7. Camacho S, Romus M, Torrecillas E. Clinical manifestations and immunodiagnosis of Gnathostomiasis in Culiacan, Mexico. Am J Trop Med Hgy 1998; 59: 908-15.
8. Nopparatana C, Setasubun P, Chaicumpa W, Tapchaisri P. Purification of Gnathostomiasis spinigerum specific antigen and immunology of human gnathostomiasis. Int J Parasitol 1991; 21: 677-87.
9. Magana M, Messina M, Bustamante, Cazarin J. Gnathostomiasis: Clinicalpathologic study. Am J Dermatopathol 2004; 26: 91-5.
10. Kraivichian P, Kulkemthorn M, Yingyourd P, Akarabovorn P, Paireepai C. Albendazole for the treatment of human gnathostomiasis. Trans R Soc Trop Med Hgy 1992; 86: 418-21.
11. Kraivichian K, Nuchprayoon S, Sitichalerchai P, Chaicunpa W, Yentakam S. Treatment of cutaneous gnathostomiasis with Ivermectin. Am J Trop Med Hgy 2004; 71: 623-8.
12. Crowley JJ, Youn HK. Cutaneous gnathostomiasis. J Am Acad Dermatol 1995; 33: 825-8.
13. Rushak JM, Lucey DR. Clinic gnathostomiasis: case report and review of the English language literature. Clin Infect Dis 1993; 16: 33-50.
14. Saksirisampant W, Chawengkiattikul R, Kraivichian K, Nuchprayoon S. Specific IgE Antibody Responses to Somatic and Excretore-Secretory Antigens of Third Stage *G. spinigerum* Larvae in Human Gnathostomiasis. J Med Assoc Thai 2001; 84(Suppl1): S173-81.
15. Nuchprayoon S, Sanprasert V, Suntravat M, Kraivichian K, Saksirisampant W, Nuchprayoon I.



Study of specific IgG subclass antibodies for diagnosis of *Gnathostomiasis spinigerum*. Parasitol Res 2003; 91: 137-43.

16. Nontasut P, Bussaratid V, Chullawichit S,

Charoensook N, Visetsuk K. Comparison of Ivermectin and albendazole treatment for gnathostomiasis. Southeast Asian J Trop Med Public Health 2000; 31: 374-7.

การหายของภาวะที่มีจำนวนเม็ดเลือดขาวชนิดอีโอสิโนฟิลสูงในโรคพยาธิตัวจืดที่ผิวหนังหลังการรักษา

กัญญรัตน์ กรัยวิเชียร, สุรางค์ นุชประยูร, เผด็จ สิริยะเสถียร, วิไล ศักดิ์ศิริสัมพันธ์, อิศรางค์ นุชประยูร

ศึกษาการเปลี่ยนแปลงของเม็ดขาวเลือดชนิดอีโอสิโนฟิลในกระแสเลือดก่อนและหลังนำตัวพยาธิออกจากร่างกายผู้ป่วยโรคพยาธิตัวจืด ทั้งหมด 28 ราย ซึ่งได้รับการรักษาด้วยยาอัลเบนดาโซล จากการศึกษพบว่าในระหว่างที่มีพยาธิอยู่ในร่างกายร้อยละ 86 ของผู้ป่วยมีจำนวนเม็ดขาวเลือดชนิดอีโอสิโนฟิลสูงขึ้นมากกว่า 500/ul และหลังให้การรักษาด้วยยาอัลเบนดาโซลและนำตัวพยาธิออกจากร่างกายแล้วพบว่าร้อยละ 96 ของผู้ป่วยมีจำนวนเม็ดเลือดขาวชนิดอีโอสิโนฟิลลดลงสู่ระดับปกติภายใน 3 เดือน โดยสรุปการที่มีจำนวนเม็ดเลือดขาวชนิดอีโอสิโนฟิลสูงขึ้นมากกว่าปกติเป็นสิ่งที่มีความสำคัญอันหนึ่งในโรคพยาธิตัวจืดที่ผิวหนังและเป็นตัวบ่งชี้ถึงผลการตอบสนองต่อการรักษาโรคที่เร็ว
