



# Hashimoto's Thyroiditis in a Patient with Non-Hodgkin's Thyroid Lymphoma of B Cell Type and Originated from Mucosa-Associated Lymphoid Tissue (MALT): A Case Report

Somlak Chuengsamarn, MD\*

\* Department of Medicine, Faculty of Medicine, Srinakharinwirot University, Nakhon-Nayok

*This is a rare case report of Hashimoto's thyroiditis in a patient with MALT thyroid lymphomas. The patient presented with an enlarged neck mass over the past 10 years and had rapidly enlarged neck mass with compressive symptoms for about 2 months. Examination by an endocrinologist found that the size of the thyroid gland was 120 gm with firm consistency and with no tenderness. She had clinical hypothyroidism and no abnormality of neither lymphadenopathy nor any masses. She was diagnosed with Hashimoto's thyroiditis because her thyroids function test showed primary hypothyroidism [FT4 = 0.76 ng/dl (0.93-1.71), FT3 = 1.76 pg/ml (1.8-4.6), TSH = 8.24 mIU/L (0.27-4.21)] with antimicrosomal antibody positive titers ( $\geq 1:409,600$ ). Diagnosis of primary thyroid lymphoma was diagnosed by FNA and total thyroidectomy was performed. About 1 day after total thyroidectomy, she developed clinical hypocalcemia and the laboratory showed that calcium was = 6.2 ng/dl (8.5-10.1), phosphorus = 6.4 mg/dl (2.5-4.9). After 10% calcium gluconate replacement, her hypocalcemic symptoms didn't appear and she received oral replacement of calcium carbonate and vitamin D before discharge. During OPD follow up, her pathological report from Maha Chakri Sirinthorn Medical Center was a diagnosis of Non Hodgkin's lymphoma, low grade and the latter 1 week immunohistochemically staining of tumor markers indicated B-cell type (CD20) with MALT (AE1/AE3) lymphoma. Staging of the disease was stage IE and she received one course of CHOP (Cyclophosphamide, doxorubicin, vincristin and prednisolone). After one course of CHOP regimen, she was healthy and the hematologist ordered two courses of CHOP and external radiation.*

**Keywords:** Thyroid lymphoma / Hashimoto's thyroiditis

**J Med Assoc Thai 2005; 88(Suppl 1): S73-8**

**Full text. e-Journal:** <http://www.medassoc.thai.org/journal>

Primary thyroid lymphoma (PTL) is a neoplasm of the immune system and is an uncommon tumor that has contributed approximately 5% of thyroid neoplasm<sup>(1)</sup> and 2.5% to 7% of all extra nodal lymphoma<sup>(2-4)</sup>. Most thyroid lymphomas are non-Hodgkin's lymphoma of B cell origin, although Hodgkin's disease and T cell lymphomas of the thyroid have been described<sup>(5-9)</sup>. With advances in the histopathologic interpretation, up to 69% these

lymphomas demonstrate tumor origin from mucosa-associated lymphoid tissue (MALT)<sup>(10)</sup>. This has been shown to be prognostically significant, with MALT lymphomas displaying a lower distant recurrence rate. Associated Hashimoto's thyroiditis has been found in more than 85% of thyroid lymphomas<sup>(10-14)</sup>.

The relationship between Hashimoto's disease and thyroid lymphomas remains obscure. Whether the presence of lymphocytes in the thyroid provides the tissue in which the lymphoma can develop or chronic stimulation of the lymphocytes predisposes the cells to develop malignant clones has not been defined. Follow-up studies have estimated

Correspondence to : Chuengsamarn S, Division of Endocrinology, Department of Medicine, Faculty of Medicine, Srinakharinwirot University, Maha Chakri Sirinthorn Medical Center, Nakhon-Nayok 26120, Thailand.

the relative risk of thyroid lymphoma in patients with chronic lymphocytic thyroiditis to be 70 to 80 times higher than in controls<sup>(11)</sup>. This significant association with chronic thyroiditis can become a diagnostic challenge to the surgeon, such that FNA of the gland without the use of immunohistochemical stains and DNA flow cytology may be misleading.

Although PLT is a rare tumor thyroid lymphoma with non-Hodgkin's lymphoma of B-cell origin that is called MALT type also has good prognosis of treatment. The presented patient had one predisposing factor of Hashimoto's thyroiditis that developed to PLT. Because Hashimoto's thyroiditis in preexisting PLT is rare, the author would like to report a case of Hashimoto's thyroiditis in a patient with primary marginal zone B-cell lymphoma of mucosa-associated lymphoid tissue (MALT lymphoma).

#### Case Report

A 75-year-old woman presented with an enlarging neck mass over the past 10 years. About 1 year previously, she also observed that the neck mass was more enlarged and she complained about symptoms of hoarseness of voice, dysphagia, anorexia and weight loss. She denied any symptoms of hyperthyroidism.

At the thyroid clinic in Maha Chakri Sirinthon Medical Center, she was examined and FNA (fine needle aspiration) was performed by an endocrinologist. Her vital signs were normal limit of temperature 37°C, blood pressure 110/70 mmHg, pulse rate 80/min. and respiratory rate 20/min. She was conscious, not pale and had no dyspnea. Her thyroid gland was generally enlarged about 120 gm in size with firm consistency. She had clinical hypothyroidism but not pain at the thyroid gland. There was no lymphadenopathy at the neck, supraclavicular, axillary or inguinal region. She had neither hepatosplenomegaly nor a palpable abdominal mass. The neurological examination was normal.

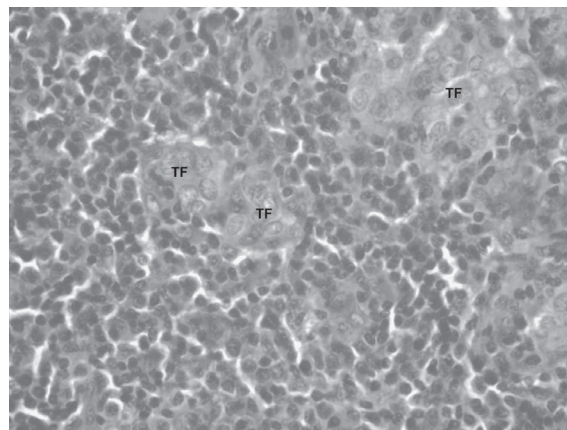
Complete blood count, serum electrolytes, BUN, creatinine, calcium, phosphorus, liver function test, calcitonin and CEA level were normal. Thyroid function test showed  $FT_4 = 0.76$  ng/dl (0.93-1.71),  $FT_3 = 1.76$  pg/ml (1.80-4.60), TSH = 8.24 mIU/L (0.270-4.210). Antithyroglobulin and antimicrosomal antibody were negative and positive titers ( $\geq 1:409,600$ ) respectively. Anti-HIV antibody was negative. She received eltroxin about 100 ug per day for Hashimoto's thyroiditis therapy.

Cytopathological report by FNA revealed atypical cells with large pleomorphic and hyperchromatic nuclei and scant cytoplasm with small mature lymphocytes. The cytopathological result favored malignancy and proved by tissue diagnosis of histopathology and immunohistochemical staining.

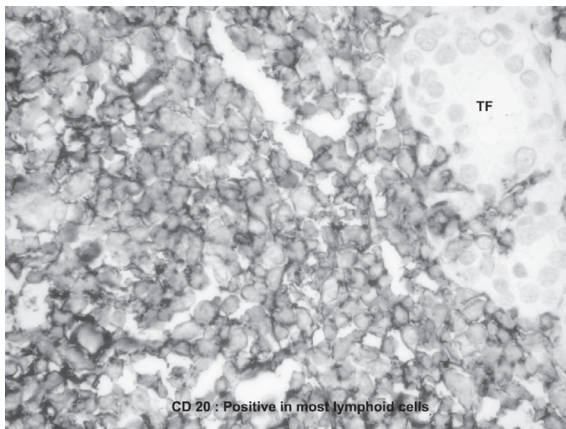
She was admitted and thyroidectomy was performed by a surgeon. About 1 day after thyroidectomy, she had clinical hypocalcemic symptoms and laboratory tests showed calcium 6.2 mg/dl (8.5-10.1) phosphorus 6.4 mg/dl (2.5-4.9) and magnesium 1.4 mg/dl (1.8-2.4). She received intravenous replacement of 10% calcium gluconate and 50% magnesium sulfate solution. With the latter, her hypocalcemic symptoms did not appear and she received oral replacement of calcium carbonate and vitamin D.

The pathological report from Maha Chakri Sirinthon Medical Center was a diagnosis of non Hodgkin's lymphoma, low grade (Follicular and diffuse, small lymphocytic, well differentiated). Microscopically, thyroid gland was replaced by diffuse infiltrate of small round cells, cleaved or round lymphocytes with occasional mitoses, and apoptosis (Fig. 1). Immunohistochemically, tumor cells expressed B-cells markers (CD20) with distinct cytoplasmic membrane pattern, indicating B-cell lymphoma (Fig. 2) and mucosa-associated lymphoid tissue markers (AE1/AE3) with focal lymphoepithelial lesions, indicating MALT lymphoma (Fig. 3).

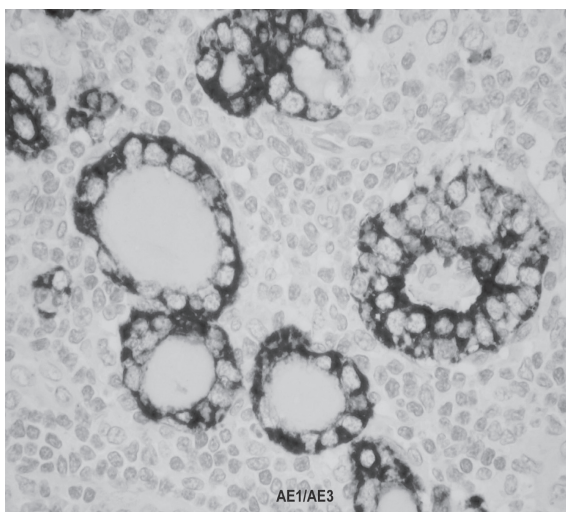
Staging process including CT scan of neck, chest and abdomen, bone marrow biopsy, were within normal limits. The patient had stage IE disease



**Fig. 1** Microscopic examination of the thyroid gland represented non- Hodgkin's lymphoma



**Fig. 2** Immunohistochemically, tumor cells expressed B-cell markers (CD20)



**Fig. 3** Immunohistochemically, tumor cells expressed mucosa-associated lymphoid tissue markers (AE1/AE3)

and subsequently received one course of CHOP (cyclophosphamide, doxorubicin, vincristin and prednisolone). After one course of CHOP regimen, she was healthy and had no side effects of this regimen. The hematologist planned to give another two courses of CHOP followed by external radiation to the neck and mediastinum.

### Discussion

Hashimoto's disease which is a disease of the thyroid goiter as a result of transformation of thyroid tissue to lymphoid tissue (Struma lympho-

matosa) is characterized histologically by diffuse lymphocytic infiltration, occasional germinal centers, sparse colloid and fibrosis<sup>(15,16)</sup>. The diagnosis of Hashimoto's disease, when suspected clinically, is confirmed by the presence of elevated thyroid-specific autoantibodies in the serum. Kasagi et al compared antibody titers with histologic findings from patients with diffuse goiter. The detection rates of anti-thyroglobulin and anti-peroxidase antibodies in the serum of histologically proven Hashimoto's disease were 96% and 74% respectively<sup>(17)</sup>.

The natural history of Hashimoto's disease is slow progression to the hypothyroid state at a rate of 5% per year. High initial titers of thyroid antibodies at presentation predict high rates of progression to the hypothyroid state<sup>(16)</sup>. Observational studies in Japan have estimated the relative risk of developing thyroid lymphoma in patients with chronic thyroiditis to be 70 to 80 times higher than expected<sup>(11)</sup>.

Clinically, primary lymphoma poses a diagnostic and therapeutic challenge, as it can present in a fashion similar to that of anaplastic carcinoma<sup>(18,19)</sup>. Thyroid lymphomas tend to present in women during their seventh decade of life, usually with a long-standing history of Hashimoto's disease. Patients usually present with a several-week history of a rapidly enlarging painless goiter, with some degree of dysphonia and dysphagia<sup>(14,20)</sup>. Approximately 30% of patients present with tracheal compression, dyspnea, and respiratory obstruction<sup>(5,14)</sup>. Most of the patients are euthyroid. On palpitation, the thyroid is firm with unilateral or bilateral involvement. The gland may be fixed to adjacent soft tissues of the neck.

Thyroid lymphoma is distinguished from inflammatory conditions by confirming the presence a monoclonal population of lymphocytes. Immunohistochemical staining with CD20 indicates B-cell linkage of the lymphocytes<sup>(10,21,22)</sup>. Immunoglobulins in B-cell tumors have characteristic clonality, such as excess expression of either lambda or kappa light chains (light chain restriction)<sup>(12,13,23,24)</sup>. Immunohistochemical staining of MALT lymphoma consists of Ae1/Ae3 markers. When the diagnosis of lymphoma cannot be confirmed on FNA, open surgical biopsy is necessary. The FNA was unable to diagnosis thyroid lymphoma accurately, so surgical biopsy was undertaken. By injecting the dye into the module, a sentinel node in the central compartment was identified and removed; it was confirmed on frozen section to be metastatic thyroid lymphoma.





The hypocalcemic problem in the presented patient after total thyroidectomy was an error in the process of the authors' management because she didn't need total removal of the thyroid gland. The presented patient had indirect evidence of thyroid lymphoma due to thyroid autoantibodies positive in Hashimoto's disease and the author is awaiting the thyroid biopsy by the surgeon after the FNA report. Due to good prognosis of MALT lymphoma, total thyroidectomy wasn't performed in the presented patient and she could only receive either chemotherapy or radiotherapy to avoid the complication of hypocalcemia.

After diagnosis of thyroid lymphoma, it is necessary for staging of this disease because its disease especially MALT lymphoma has a good prognosis and treatment. Stage IE is confined to the thyroid. Stage IIE is a disease confined to the thyroid and regional lymph nodes. Stage IIIE involves disease on both sides of the diaphragm, and stage IVE is disseminated disease. The 5-year survival for each stage is as follows: stage IE 80%, stage IIE 50%, stage IIIE and IVE less than 36%<sup>(7)</sup>. With the increased use of multimodality therapies for all stages of the tumor these figures appear to be improving.

Mucosa-associated lymphoid tissue has been postulated to be the origin of most non-Hodgkin's lymphomas of the thyroid. In Laing et al's retrospective series, 69% of the thyroid lymphomas were demonstrated to originate from MALT<sup>(10)</sup>. They found that the use of radiotherapy alone in MALT thyroid lymphomas resulted in 96% complete response, a relapse rate of 30% with a high salvage rate resulting in an overall cause-specific survival of 90% at 5 and 10 years. Non-MALT lymphoma had a lower rate of complete response to radiotherapy and higher relapse rate with little chance of salvage, resulting in an overall survival of 55% at 5 years<sup>(10)</sup>. This finding suggests that stage IE and IIE MALT lymphoma may be treated with radiotherapy alone, recognizing that there is a 30% chance of relapse within the first few years.

With the high relapse rate after irradiation alone for local disease, Dorla et al<sup>(25)</sup> reviewed the literature for the treatment of stage IE and IIE thyroid lymphomas. A total of 211 patients from 11 reported series were extracted from the literature. They found an overall 30% relapse rate for stage IE and IIE lymphomas. Distant and overall relapse rates were significantly lower in the group that underwent combination irradiation and chemotherapy (5.1%

and 7.7% respectively) compared to patients who underwent irradiation alone (30.8% and 37%, respectively). Local relapse was 2.6% for the combined therapy group and 12.6% for the irradiation alone group, but it failed to reach statistical significance. Although this was a retrospective review from multiple centers, the data suggest that combination therapy for local stage IE and IIE disease decreased the relapse rate and therefore improved overall survival.

The combination of locoregional irradiation and chemotherapy consisting of CHOP (cyclophosphamide, doxorubicin, vinorelbine, and prednisone), with or without the additions of methotrexate or adriamycin (or both), is now utilized in many centers for all stages of thyroid lymphoma<sup>(26-28)</sup>.

## Conclusion

The author presented a rare case of Hashimoto's thyroiditis in a patient with MALT thyroid lymphomas. The endocrine surgeon must be aware of the pitfalls of FNA of a thyroid nodule or a background of Hashimoto's disease. When presented with a patient who has a rapidly expanding thyroid and possible airway compromise, the surgeon may be the first line physician responsible for directing the case. Today the surgeon's role with thyroid lymphoma is limited to surgical biopsy for diagnosis when FNA is not possible and possibly treating the disease localized to the thyroid alone. MALT thyroid lymphomas with stage IE to IIE have a good prognosis of treatment and can be treated with a combination of irradiation and chemotherapy which reduces locoregional recurrence.

## References

1. Pasioka JL. Unusual thyroid cancers, lymphoma, and metastases to the thyroid. In: Clark OH, Duh QY, eds. *Textbook of Endocrine Surgery*. Philadelphia: WB Saunders Company, 1997: 133-9.
2. Aozasa K, Tsugimoto M, Sakurai M. Non-Hodgkin's lymphomas in Osaka, Japan. *Eur J Cancer Clin Oncol* 1985; 21: 487-92.
3. Freeman C, Berg JW, Cutler SJ. Occurrence and prognosis of extranodal lymphomas. *Cancer* 1972; 29: 252-60.
4. Pedersen RK, Pedersen NT. Primary non-Hodgkin's lymphoma of the thyroid gland: a population based study. *Histopathology* 1996; 28: 25-32.
5. Compagno J, Oertel JE. Malignant lymphoma





- and other lymphoproliferative disorders of the thyroid gland a clinicopathologic study of 245 cases. *Am J Clin Pathol* 1980; 74: 1.
6. Kapadia SB, Dekker A, Cheng VS, Desai U, Watson CG. Malignant lymphoma of the thyroid gland a clinicopathologic study. *Head Neck Surg* 1982; 2: 270.
  7. Pyke CM, Grant CS, Habermann TM, Kurtin PJ, Van Heerden JA, Bergstralh EJ, Kunselman A, Hay ID. Non-Hodgkin's lymphoma of the thyroid is more than biopsy necessary *World J Surg* 1992; 16: 604. PMID 1413831, UI93033513.
  8. Abdul-Rahman ZH, Gogas HJ, Tooze JA, Anderson B, Mansi J, Sacks NP, Finlayson CJ. T-cell lymphoma in Hashimoto's thyroiditis. *Histopathology* 1996; 29: 455. PMID 8951491, UI 97109211.
  9. Yamaguchi M, Ohno T, Kita K. T-cell lymphoma of the thyroid gland. *N Engl J Med* 1997; 19: 1391.
  10. Laing RW, Hoskin P, Vaughan Hudson B, Hudson GV, Harmer C, Bennett MH, MacLennan KA. The significance of MALT histology in thyroid lymphoma: a review of patients from the BNLI and Royal Marden Hospital Royal Marden Hospital. *Clin Oncol* 1994; 6: 300. PMID 7826922, UI95127532.
  11. Holm LE, Blomgren H, Lowhagen T. Cancer risks in patients with chronic lymphocytic thyroiditis. *N Engl J Med* 1985; 312: 601.
  12. Aozasa K, Ueda T, Katagiri S, Matsuzuka F, Kuma K, Yonezawa T. Immunologic and immunohistologic analysis of 27 cases with thyroid lymphomas. *Cancer* 1987; 60: 969.
  13. Sobrinho-Simoes M, Nesland JM, Johannessen JV. Columnar cell carcinoma another variant of poorly differentiated carcinoma of the thyroid. *Am J Clin Pathol* 1988; 89: 264.
  14. Hamburger JI, Miller JM, Kini SR. Lymphoma of the thyroid. *Ann Intern Med* 1983; 99: 685.
  15. Hashimoto Z. Zur Kenntniss der lymphomatosen veränderung der schilddrüse (Struma Lymphomatosa). *Arch Klin Chir* 1912; 97: 219.
  16. Dayan CM, Daniels GH. Chronic autoimmune thyroiditis. *N Engl J Med* 1996; 335: 99.
  17. Kasagi K, Kousaka T, Higuchi K, Iida Y, Misaki T, Alam MS, Miyamoto S, Yamabe H, Konishi J. Clinical significance of measurements of antithyroid antibodies in the diagnosis of Hashimoto's thyroiditis: comparison with histological findings. *Thyroid* 1996; 6: 445. PMID: 8936669. UI: 97090782.
  18. Holting T, Moller P, Tschahargane C, Meybier H, Buhr H. Immunohistochemical reclassification of anaplastic carcinoma reveals small and giant cell lymphoma. *World J Surg* 1990; 14: 291.
  19. Tobler A, Maurer R, Hedinger CE. Undifferentiated thyroid tumors of diffuse small cell type. *Virchows Arch A Pathol Anat* 1984; 404: 117.
  20. Samaan NA, Ordonez NG. Uncommon types of thyroid cancer. *Endocrinol Metab Clin North Am* 1990; 19: 637.
  21. Detweiler RE, Katz RL, Alapat C, El-Naggar A, Ordonez N. Malignant lymphoma of the thyroid a report of two cases diagnosed by fine-needle aspiration. *Diagn Cytopathol* 1991; 7: 163.
  22. Mason DY, Comans-Bitter WM, Cordell J. Antibody L26 recognises an intracellular epitope on the B-cell associated CD20 antigen. *Am J Pathol* 1990; 136: 1215.
  23. Tennvall J, Cavallin-Stahl E, Akerman M. Primary localized non-Hodgkin's lymphoma of the thyroid: a retrospective clinicopathological review. *Eur J Surg Oncol* 1987; 13: 297.
  24. Matsuzuka F, Fukata S, Kuma K, Miyauchi A, Kakudo K, Sugawara M. Gene rearrangement of immunoglobulin as a marker of thyroid lymphoma. *World J Surg* 1998; 22: 558.
  25. Doria R, Jekel JF, Cooper DL. Thyroid lymphoma: the case for combined modality therapy. *Cancer* 1994; 73: 200.
  26. Tsang RW, Gospodarowicz MK, Sutcliffe SB, Sturgeon JFG, Pansarella T, Patterson BJ. Non-Hodgkin's lymphoma of the thyroid gland prognostic factors and treatment outcomes. *Int J Radiat Oncol Biol Phys* 1993; 27: 599.
  27. Skarsgard ED, Connors JM, Robins RE. A current analysis of primary lymphoma of the thyroid. *Arch Surg* 1991; 126: 1199.
  28. Matsuzuka F, Miyauchi A, Katayama S, Narabayashi I, Ikeda H, Kuma K, Sugawara M. Clinical aspects of primary thyroid lymphoma diagnosis and treatment based on our experience of 119 cases. *Thyroid* 1993; 32: 93. PMID 8369658, UI93379481.



## โรคมะเร็งต่อมธัยรอยด์ ชนิด Mucosa-Associated Lymphoid Tissue (MALT) ในผู้ป่วย Hashimoto's thyroiditis: รายงานผู้ป่วย 1 ราย

### สมลักษณ์ จิงสมาน

ได้รายงานผู้ป่วย 1 รายที่มีภาวะ Hashimoto's thyroiditis ร่วมกับมะเร็งของธัยรอยด์ (non-Hodgkin's lymphoma) ชนิด Mucosa-Associated lymphoid Tissue (MALT) ผู้ป่วยมีอาการคอโตมานานประมาณ 10 ปี ในช่วง 2 เดือนก่อนมาโรงพยาบาลสังเกตคอโตเร็ว และมีอาการเสียงแหบ การตรวจร่างกายแรกพบขนาดต่อมธัยรอยด์โตประมาณ 120 กรัม แข็ง กดไม่เจ็บ และมีอาการแสดงภาวะต่อมธัยรอยด์ทำงานต่ำ การตรวจอื่น ๆ ปกติไม่พบต่อมน้ำเหลืองโต หรือก้อนอื่น ๆ ตามร่างกาย

ผลการตรวจค้นทางห้องปฏิบัติการทางธัยรอยด์ให้การวินิจฉัยโรค Hashimoto's thyroiditis [(FT4 = 0.76 นก./ดล. (0.93-1.71), FT3 = 1.76 พก./มล. (1.8-4.6), TSH = 8.24 มิลลิยูนิต/ลิตร (0.27-4.21)] ร่วมกับ antimicrosomal antibody ได้ค่าไทเตอร์ > 1:409,600 ผลการตรวจ FNA สงสัยภาวะมะเร็งของต่อมธัยรอยด์ และได้ทำการผ่าตัดต่อมธัยรอยด์ออก หลังการผ่าตัด 1 วัน ผู้ป่วยมีอาการแสดงภาวะแคลเซียมในเลือดต่ำร่วมกับผลทางห้องปฏิบัติการพบว่า ระดับแคลเซียม = 6.2 มก./ดล. (8.5-10.1), ฟอสฟอรัส = 6.4 มก./ดล. (2.5-4.9) แพทย์ได้ทำการรักษาโดยให้ 10% แคลเซียมกลูโคเนต ทางเส้นเลือด หลังจากนั้นได้ให้การทดแทนระดับแคลเซียมโดยรับประทานแคลเซียมคาร์บอเนต และวิตามินดี ผู้ป่วยสามารถกลับบ้านได้โดยปกติ ผลการตรวจทางพยาธิวิทยา และการย้อมเฉพาะทางพยาธิวิทยา จากชิ้นเนื้อที่ได้จากการผ่าตัดต่อมธัยรอยด์ ให้การวินิจฉัยเป็นมะเร็งต่อมธัยรอยด์ non-Hodgkin's lymphoma (บีเซลล์) ชนิด MALT lymphoma ผู้ป่วยมีระยะแสดงของโรคในระยะ IE และได้รับการให้เคมีบำบัด 1 ครั้ง โดยได้รับยา ไซโคลฟอสฟลาไมด์, ดอกโซรูบิซิน, วินคริสติน และเฟรดนิโซโลน แพทย์ทางด้าน มะเร็งโลหิตวิทยา วางแผนจะให้เคมีบำบัดผู้ป่วยอีก 2 ครั้ง ร่วมกับการฉายแสงรักษาโรคนี้อีก