

# The Relative Dural Sac Cross-Sectional Area and Morphological Grading Does They Correlate with the Patient Outcomes after Biportal Endoscopic Decompression Surgery

Yingyong Torudom, MD<sup>1</sup>, Supphawit Phatchana, MD<sup>1</sup>

<sup>1</sup> Department of Orthopaedics, Faculty of Medicine, Srinakharinwirot University, Nakhon Nayok, Thailand

**Objective:** To study the relationship between the relative dural sac cross-sectional area (RDCA) and shape of the dural sac in the lumbar spinal stenosis patients and outcomes after biportal endoscopic spine surgery (BESS).

**Materials and Methods:** This was a retrospective cohort study which included the population of patients diagnosed with lumbar spinal stenosis whom underwent BESS at HRH MSMC from the period of May 2014 to April 2019. RDCA and shape of the dural sac were evaluated with pre-operative MRI. RDCA and morphological grade were reported as percentage and Schizas scale (A, B, C, D) respectively. The Oswestry Disability Index (ODI) and visual analog score (VAS) in leg pain were our primary outcome on the present study and the data were collected before the operation and one year after the procedure.

**Results:** A total of 128 patients (160 levels of surgery) underwent BESS for lumbar spinal stenosis. There were an association between RDCA and morphological grading. Severe morphological grading was associated with decreased in RDCA measured from the MRI. There were improvement of ODI and VAS in the all groups of radiographic grading. And clinical improvement was increased but not significantly in the person who had RDCA less than 50% (p-value >0.05).

**Conclusion:** The MRI-based morphological grading and RDCA were associated with good surgical results after BESS regarding their association with baseline and 12-month follow-up. There are numerous patients who achieved greater surgical outcome of the reduction of ODI and VAS especially in RDCA less than 50%. RDCA <75% and Schizas B, C, D. RDCA represented the preferred method for assessing the extent of spinal stenosis. This evidence was difference from the former reports that morphologic classification grade B had likelihood of a positive outcome after BESS.

**Keywords:** Dural sac cross-sectional area; Morphological grading; Spinal stenosis; Endoscope; Biportal endoscope; Relative

J Med Assoc Thai 2022;105(Suppl.1): S94-9

Website: <http://www.jmatonline.com>

Lumbar spinal stenosis is a common condition found in the ageing population; it is one of the main causes for surgical treatment in elderly patients<sup>(1)</sup>. The pathology of this condition is from degenerative changes causing the enlargement of the surrounding structures that results in narrowing of the spinal canal and the compression of neural structures. Problems such as back pain, radicular pain, weakness and abnormal gait affected normal daily activities in the person who has severe condition. Some of these patients can be managed with conservative treatment, but many require

surgical intervention to relieve the symptoms for example open spinal laminectomy, mini-open spinal surgery, or minimally invasive surgery such as microscope assisted operation or full endoscopic decompression procedure<sup>(2-4)</sup>.

Endoscopic assisted spine surgery has risen in popularity in the recent years. For patients without dynamic instability on x-rays, the endoscopic decompression alone created less damage to the surrounding paraspinal muscle as well as bone and facet joints were preserved during the procedure compared to conventional surgery. According to the result of minimized soft tissue injury, the procedure had lower effects to spinal stability<sup>(5,6)</sup>.

There is no consensus of preoperative radiographic parameters that indicate the requirement for surgical decompression. From previous studies, findings from MRI together with the clinical symptom of the patients<sup>(7)</sup> had been used for evaluation and planning for the operative management. These findings had significantly seen better results for surgery when the compression area was less than 75 mm<sup>2</sup> or had a Schizas scale of C or more<sup>(8)</sup>. However many reports showed a smaller compression area related with significant better outcomes after spinal decompression<sup>(9)</sup>. Therefore absolute area of the dural sac might not correspond with the clinical outcome after surgery. There were many

## Correspondence to:

Yingyong T.

Department of Orthopaedics, Faculty of Medicine, Srinakharinwirot University, 62 Moo 7 Ongkharak, Nakhon Nayok 26120, Thailand

Phone: +66-37-395085 ext 11408

Email: [torudom@hotmail.com](mailto:torudom@hotmail.com)

## How to cite this article:

Torudom Y, Phatchana S. The Relative Dural Sac Cross-Sectional Area and Morphological Grading Does They Correlate with the Patient Outcomes after Biportal Endoscopic Decompression Surgery. J Med Assoc Thai 2022;105 (Suppl.1): S94-9.

[doi.org/10.35755/jmedassocthai.2022.S01.00029](https://doi.org/10.35755/jmedassocthai.2022.S01.00029)

reasons for this finding. Firstly, size of the patient, the person who were tall and overweight would have spinal canal cross sectional area more than the smaller one. In addition, anatomical variation of the spine bone plays the major role on spinal canal space. The patients who had congenital canal stenosis, a few increase space occupying lesion in the spinal canal could cause detrimental effect to the symptom of the patients. Lastly, for assessment the area of dural sac on MRI, results depended on the calibration of the measurement scale before the procedure.

In the past, the use of the relative parameter could get rid out the effect of aforementioned parameters. For example Pavlov ratio, the x-ray that calculated the ratio between cervical spinal canal AP diameter and the vertebral body could reduce the effect of the skeletal size and magnification of the plain radiograph. In order to use the dural cross-section area that were measured exactly from MRI, the authors utilized the proportion between the narrowest extent of the dural space and the nearest normal spinal canal space instead. This parameter was recorded as relative dural sac cross-section area (RDCA).

The purpose of the present study were to identify the relationship between the RDCA along with morphology of the dural sac in the lumbar spinal stenosis patients and results after bipotal endoscopic spine surgery (BESS).

## Materials and Methods

The study was approved by the institutional board committee (SWUEC/E-139/2563). This was a retrospective study which included the population of patients diagnosed with lumbar spinal stenosis whom underwent bipotal endoscopic decompression surgery at Her Royal Highness Maha Chakri Sirindhorn Medical Center from the period of May 2014 to April 2019. A total of 128 patients were identified. The inclusion criteria were 1) the patients who had clinical spinal stenosis and MRI examinations show neural element compression classified as central spinal canal stenosis or lateral recess stenosis. 2) They were unsuccessfully treated conservatively for at least 3 months. The conservative measurements included: activity modification, non-steroidal anti-inflammation medications and physical therapy. Pre-operative and 12 months post-operative history, physical examination and questionnaire data were collected in all of the patients.

The patients who had more than grade 1 of spondylolisthesis according to Meyerding classification, coronal plane deformity more than 10 degree or translation difference more than 4 mm in dynamic radiographs, and prior history of lumbar spinal surgery or any evidence of upper neurological pathology were excluded.

Measurement severity of lumbar spinal stenosis was evaluated on pre-operative T2 axial MRIs. The relative dural sac cross-sectional area (RDCA) was the parameter that calculated from the area of narrowest dural space seen on MRI divided by area of normal dural sac adjacent to the pathologic level. The measurement was determined using program ImageJ and reported in square millimeter. The sample

was shown in Figure 1.

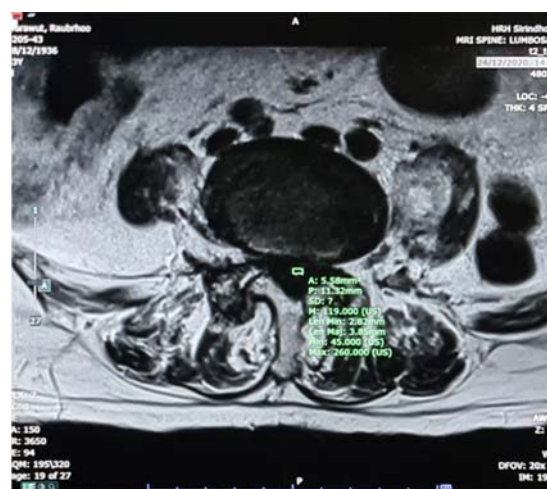The narrowest canal level was also evaluated and categorized into 4 morphological grading groups A, B, C or D according to the method of Schizas et al. Both RDCA and morphology of dural sac were done by 2 investigators and each of them evaluated the MRI two times in the one-month interval. Both of the investigators were evaluated with Cohen's Kappa coefficient. The inter-rater reliability was 0.794 (95% CI = 0.692 to 0.896) and intra-rater reliability was 0.71 (95% CI = 0.652 to 0.796). The Oswestry disability index (ODI) questionnaire and visual analog scale (VAS) for leg pain were the outcome of this study and the data were collected preoperative and 12 months after the procedure.

## Statistical analysis

Due to size of the data, Spearman rank correlation coefficients were used to examine the relationship between the morphological grade of lumbar spinal stenosis and RDCA, and the VAS and ODI scores from preoperative to 12-months after the operation. One-way repeated measures analysis of variance was used to examine the difference among the mean ODI scores and VAS scores for the four morphological grades and RDCA category in response time. The statistical tests were two-sided, and a p-value less than 5% was estimated to indicate statistically significant. Statistical analyses were performed using the STATA version 14 (StataCorp, College Station, TX).

## Results

A total of 150 patients underwent BESS for lumbar spinal stenosis. Twenty two patients were loss of follow-up or data were missing thus 128 subjects were collected. Single level procedure was performed in 96 of the patients and the



**Figure 1.** Cross section of the magnetic resonance imaging at the spinal stenosis level, measurement of relative dural sac crosssection area was shown in green line.

remaining 32 patients received 2 levels endoscopic surgery. Overall, 160 levels of surgery were performed with more than half of the amount at L4/L5 level. Demographics and severity distribution data were shown in the corresponding Table 1.

There was an association between RDCA and morphological grading. The patients with more severe morphological grading resulted with decreased RDCA

measured from the MRI. As shown in Table 2, 85.71% of morphologic grade D cases had RDCA less than 25% when compared to the lower percentage of morphologic grade B at zero percent whose area are less than 25%. Further relationship of morphologic grading and RDCA are shown in Table 2 and Figure 2.

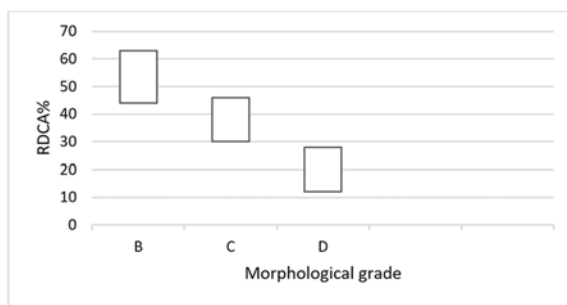
A one-way repeated measures ANOVA was conducted on 128 individuals to examine the effect that three

**Table 1.** Descriptive baseline demographic data

	Number of patient (n=128)	Percentage
Age (mean), (SD)	55.19 (13.52)	
Min	32	
Max	82	
Sex		
Male	56	43.75
Female	72	56.25
BMI (kg/sq.m)		
<20	5	3.91
20 to 25	72	56.25
26 to 30	44	34.38
31 to 35	5	3.91
>35	2	1.56
ASA classification		
I	22	17.19
II	72	56.25
III	34	26.56
IV	0	0.00
Number of operated level		
1	96	75.00
2	32	25.00
Operated level		
L1/L2	2	1.25
L2/L3	10	6.25
L3/L4	29	18.13
L4/L5	87	54.37
L5/S1	32	20.00
Morphological grading		
A	0	0
B	48	37.50
C	56	43.75
D	24	18.75
Relative dural sac cross-sectional area (RDCA) (%)		
76 to 100	0	0
51 to 75	41	32.03
26 to 50	34	26.56
<25	53	41.41

**Table 2.** Association between the morphological grading and relative dural sac cross-sectional area (RDCA)

Morphological grade	RDCA (%)			n (160)
	51 to 75	26 to 50	<25	
B	30 (50.85)	29 (49.15)	0	59
C	1 (1.25)	40 (50.0)	39 (48.75)	80
D	0 (0.00)	3 (14.29)	18 (85.71)	21



**Figure 2.** Median of relative dural sac cross-sectional area (RDCA) according to morphological grade.

different morphological grades and the results after surgery. Our results showed that there was difference but not statistically significant among the mean ODI scores and VAS scores for the morphological grades B and the RDCA more than 51 percents from the patients who had morphological grade C, D and RDCA 50 percent and less at 12 month after procedure (Figure 3, 4).

## Discussion

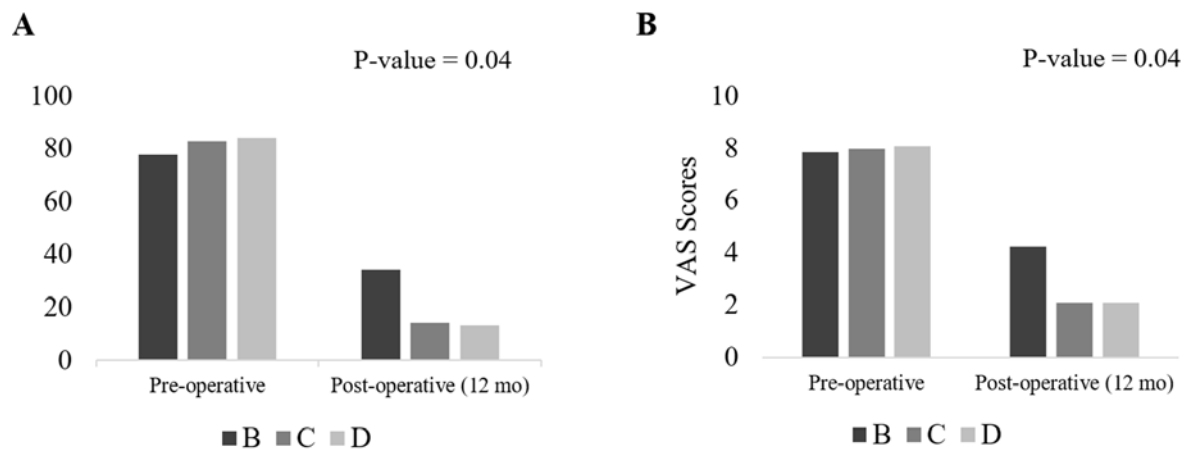
Lumbar spinal stenosis patients suffering from back pain and radiculopathy leads to abnormal gait and impaired activities of daily life<sup>(10)</sup>. The people who have this condition usually require surgical intervention in the current paradigm. Multiple previous studies have tried to predict the prognosis after surgical intervention by using radiologic parameters especially from MRI<sup>(13-15)</sup>. Kuittinin et al<sup>(15)</sup> found that the patients who received spinal decompression surgery were satisfied with their treatment correlated with MRI finding, the criteria that evaluated were ODI, VAS and Schizas classification. Similar to Mannion et al, patients who underwent the standard open surgery and the Schizas grade D or dural sac cross-section area less than 75 sq.mm., they had good outcomes assessed by core outcome measurement index score (preoperative and 12 months postoperative). But in patients with lower degree of compression such as dural sac cross-section area more than 75 square millimeters did not have a positive response to open surgery. The reason may be the open surgery caused more invasive soft tissue destruction so the biological and biomechanical change after surgery affected the results more than positive outcome of neural

decompression. In such manner the persons with less severe radiographs in less satisfaction when compared to groups with more severe radiologic compression groups.

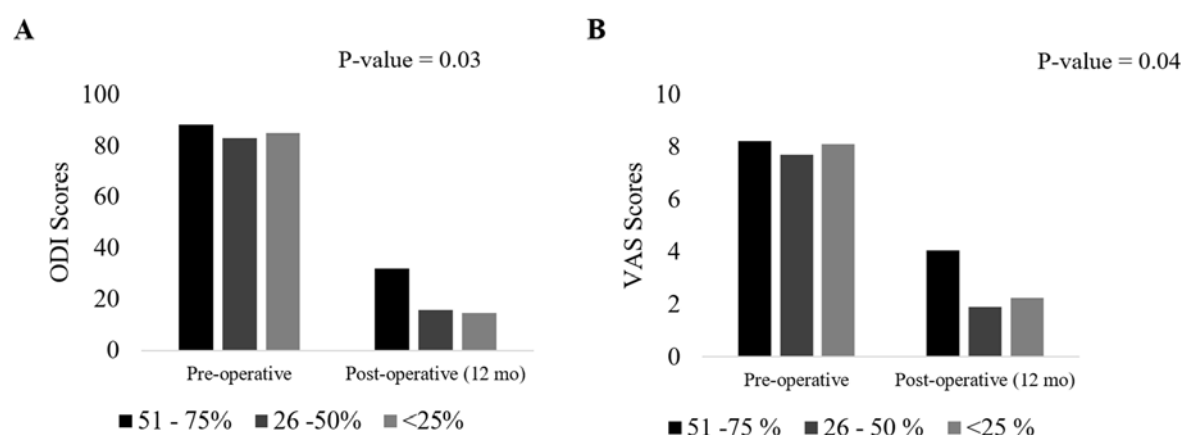
Endoscopic decompression surgery is an emerging novel treatment. The main benefit of BESS were less paraspinal soft tissue injury and minimal bony removal so the advantage of this procedure may overcome the restriction of classic surgery in clinical results especially in the radiographic evaluation which showed mild neural compression. The authors conducted the present study in order to find out the relationship between qualitative (morphologic grading) and quantitative (RDCA) parameters on MRI and the surgical outcomes (ODI, VAS) in patients who were treated with BESS. The results showed that there were statistically significant differences between the aforementioned MRI parameters and one year post-operative outcomes of the patients who received BESS. Subgroup analysis showed that the patients who had RDCA less than 50% and morphological grading C and D had much more improvement clinical function after the operation.

The results of this study showed that all patients, regardless of the severity of stenosis (morphological grading and RDCA), had improved 12 months post-operative surgical outcomes. Less severe cases with morphological grading of B and RDCA of 51 to 75% had achieved favorable outcome but the results were inferior to more severe stenosis people. The benefits of minimal soft tissue injury in endoscopic decompression surgery were believed to be a big factor<sup>(11,12)</sup> for post-operative recovery and clinical picture. Many reports<sup>(16-19)</sup> found that BESS resulted with less soft tissue injury compared to conventional open surgery. This current investigation also demonstrated the improvement after BESS were significant in all radiographic category and much better in the MRI finding that showed severe compression, RDCA less than 50% and Schizas grade C, D. In contrast, open surgery has clinical improvement significantly in Schizas C, D. The explanation might be greater soft tissue destruction and bony removal in classic surgery resulting in biomechanical change in spinal column, longer recovery time, greater pain and poor functional outcome.

There were several limitations in the present study. Firstly, this is a descriptive retrospective study allowing no room for randomization and permitting selection bias such as some patients who had minimal compression on MRI findings might satisfy with conservative treatments are not included in the study. Because the data showed that there were not



**Figure 3.** The differences between morphological grade and A) mean (SD) ODI scores, B) mean (SD) VAS at baseline and 12 months.



**Figure 4.** The differences between RDCA and A) mean (SD) ODI scores, B) mean (SD) VAS at baseline and 12 months.

any patients in Schizas A or RDCA more than 76%. Secondly, the authors used new parameter, RDCA, for quantitative radiographic evaluation of neural tissue compression thus this parameter could not be compared with absolute dural compression of previous study. Thirdly, the present study also had short term follow-up period which inhibits the detection of complications such as reoperation principally in the individual who had severe neural compression finding in MRI. These patients might need more soft tissue dissection and facet joint removal therefore they could have spinal instability many years after endoscopic surgery. Lastly, although the total sample size in this study was adequate, subgroup analysis of some groups was also small which resulted in less magnitude in detecting differences. Since this is a novel surgical intervention performed in a single center by a single surgeon, a larger team will be needed

to further evolve. Potential increase in cases, prospective and longer study period is expected with emerging facilities improvement and team. BESS is a viable option for surgical intervention of lumbar spinal stenosis as a minimal invasive surgery. The patients with clinical symptom and radiographic evaluation showed RDSA less than 75% and Schizas grade B, C and D would improve clinical picture after surgery.

### Conclusion

MRI based morphological grading and RDCA in lumbar spinal stenosis were related with post-operative surgical outcomes after BESS. The person who had RDCA fewer than 50 percent and morphological grade C, D were much more clinical improvement than the group with fewer compression. BESS is one of a preferable surgical choice in treating lumbar spinal stenosis regardless of the radiographic



severity visible in the MRI.

### What is already known on this topic?

Schizas's morphological grading more than C and dural sac area less than 75 square millimeters corresponded with the good clinical result after open spinal decompression surgery.

### What this study adds?

RDCA less than 75 percent and Schizas grade B and more correlated with post-operative surgical results even though RDCA less than 50% and morphological grading C, D correlated with post-operative improvement more than RDCA 51 to 75% and Schizas grade B.

### Potential conflicts of interest

The authors declare no conflict of interest.

### References

1. Kalichman L, Cole R, Kim DH, Li L, Suri P, Guermazi A, et al. Spinal stenosis prevalence and association with symptoms: the Framingham Study. *Spine J* 2009; 9:545-50.
2. Ishimoto Y, Yoshimura N, Muraki S, Yamada H, Nagata K, Hashizume H, et al. Associations between radiographic lumbar spinal stenosis and clinical symptoms in the general population: the Wakayama Spine Study. *Osteoarthritis Cartilage* 2013; 21:783-8.
3. Deyo RA, Mirza SK, Martin BI, Kreuter W, Goodman DC, Jarvik JG. Trends, major medical complications, and charges associated with surgery for lumbar spinal stenosis in older adults. *JAMA* 2010; 303:1259-65.
4. Dewannan NK, Yadav YR, Parihar VS, Ratre S, Kher Y, Bhatele P. Extent of decompression of lumbar spinal canal after endoscopic surgery. *J Neurol Surg A Cent Eur Neurosurg* 2017; 78:541-7.
5. Haro H, Maekawa S, Hamada Y. Prospective analysis of clinical evaluation and self-assessment by patients after decompression surgery for degenerative lumbar canal stenosis. *Spine J* 2008; 8:380-4.
6. Enyo Y, Yamada H, Kim JH, Yoshida M, Hutton WC. Microendoscopic lateral decompression for lumbar foraminal stenosis: a biomechanical study. *J Spinal Disord Tech* 2014; 27:257-62.
7. Alsaleh K, Ho D, Rosas-Arellano MP, Stewart TC, Gurr KR, Bailey CS. Radiographic assessment of degenerative lumbar spinal stenosis: is MRI superior to CT? *Eur Spine J* 2017; 26:362-7.
8. Schizas C, Theumann N, Burn A, Tansey R, Wardlaw D, Smith FW, et al. Qualitative grading of severity of lumbar spinal stenosis based on the morphology of the dural sac on magnetic resonance images. *Spine (Phila Pa 1976)* 2010; 35:1919-24.
9. Mannion AF, Fekete TF, Pacifico D, O'Riordan D, Nauer S, von Buren M, et al. Dural sac cross-sectional area and morphological grade show significant associations with patient-rated outcome of surgery for lumbar central spinal stenosis. *Eur Spine J* 2017; 26:2552-64.
10. Markwalder TM. Surgical management of neurogenic claudication in 100 patients with lumbar spinal stenosis due to degenerative spondylolisthesis. *Acta Neurochir (Wien)* 1993; 120:136-42.
11. Abumi K, Panjabi MM, Kramer KM, Duranceau J, Oxland T, Crisco JJ. Biomechanical evaluation of lumbar spinal stability after graded facetectomies. *Spine (Phila Pa 1976)* 1990; 15:1142-7.
12. Fortin M, Lazary A, Varga PP, Battie MC. Association between paraspinal muscle morphology, clinical symptoms and functional status in patients with lumbar spinal stenosis. *Eur Spine J* 2017; 26:2543-51.
13. Kitab S, Lee BS, Benzel EC. Redefining lumbar spinal stenosis as a developmental syndrome: an MRI-based multivariate analysis of findings in 709 patients throughout the 16- to 82-year age spectrum. *J Neurosurg Spine* 2018; 29:654-60.
14. Azimi P. Outcomes of patients diagnosed with lumbar spinal stenosis undergoing laminectomy based on the morphology of the dural sac on MRI. *Pejouhesh Dar Pezeshki* 2012; 36:7-13.
15. Kuittinen P, Sipola P, Leinonen V, Saari T, Sinikallio S, Savolainen S, et al. Preoperative MRI findings predict two-year postoperative clinical outcome in lumbar spinal stenosis. *PLoS One* 2014; 9:e106404.
16. Kim HS, Paudel B, Jang JS, Oh SH, Lee S, Park JE, et al. Percutaneous full endoscopic bilateral lumbar decompression of spinal stenosis through uniportal-contralateral approach: Techniques and preliminary results. *World Neurosurg* 2017; 103:201-9.
17. Khalsa SS, Kim HS, Singh R, Kashlan ON. Radiographic outcomes of endoscopic decompression for lumbar spinal stenosis. *Neurosurg Focus* 2019; 46:E10.
18. Torudom Y, Dilokhuttakarn T. Two portal percutaneous endoscopic decompression for lumbar spinal stenosis: preliminary study. *Asian Spine J* 2016; 10:335-42.
19. Torudom Y, Jundamrongkul J. Biportal percutaneous endoscopic discectomy for recurrent lumbar disc herniation: preliminary report. *J Med Assoc Thai* 2017; 100:179-84.