

# False Negative Rate of the Highest Radioactive Count of Sentinel Lymph Node in Early Stage Breast Cancer Patients

Prakasit Chirappapha MD\*, Rujira Panawattanakul MD\*, Watoo Vassanasiri MD\*,  
Youwanush Kongdan MD\*, Panuwat Lertsithichai MD, MSc\*, Thongchai Sukarayothin MD\*,  
Monchai Leesombatpaiboon MD\*, Yodying Wasuthit MD\*, Ronnarat Suvikapakornkul MD\*

\* Department of Surgery, Faculty of Medicine Ramathibodi Hospital, Mahidol University, Bangkok, Thailand

**Background:** Axillary staging in women with breast cancer had changed drastically since the concept of sentinel lymph node was introduced. Sentinel lymph node biopsy caused significantly less morbidity than axillary lymph node dissection. The number of nodes removed are variable. However, removing more nodes results in a higher complication rate. If the lymph node with the highest radiologic count could be used to represent the entire group of sentinel nodes then we might be able to limit the number of nodes removed.

**Objective:** The present study was conducted to find the false negative rate of the sentinel lymph node with various radiologic count in early breast cancer patients.

**Material and Method:** Women with early stage breast cancer and clinically node negative who had undergone sentinel lymph node biopsy in the breast and endocrine surgery unit of Ramathibodi Hospital between July 1, 2014 and January 31, 2015 were recruited. Radiologic count of each sentinel nodes was documented and the false negative rate of the sentinel node with the highest radiologic count was calculated. False negative rate is defined as the rate of nodal metastasis in lymph nodes other than the node with the highest radiologic count.

**Results:** One hundred thirty sentinel lymph node biopsies were performed. Of this, 39 women had sentinel lymph node metastasis. The false negative rate of the node with the highest radiologic count is 17.9%. The false negative rate was reduced to 7.7% if we included the second and third highest nodes.

**Conclusion:** Removal of only the sentinel node with the highest radiologic count has an unacceptably high false negative rate. This can be improved by removing the second and third highest nodes.

**Keywords:** Sentinel lymph node, Sentinel lymph node biopsy, Early breast cancer, Highest radiologic count

*J Med Assoc Thai 2017; 100 (Suppl. 9): S86-S93*

**Full text. e-Journal:** <http://www.jmatonline.com>

Axillary lymph node surgery has been an integral component of breast cancer staging and the treatment of invasive breast cancer because axillary status is the most important prognostic factor for overall survival. Surgical paradigm has changed since the concept of lymphatic mapping of the breast has been introduced.

In early stage breast cancer, sentinel lymph node biopsy had become the standard method for the diagnosis of axillary lymph node status and had replaced axillary lymph node dissection. It associates with reduced arm morbidity and better

quality of life<sup>(1-4)</sup>.

Sentinel lymph node is the first echelon node draining from the primary tumor to an afferent lymphatic channel. The first node metastasis then spreads to other lymph nodes in the lymphatic basin. This order of progression almost always occurs for tumors in the breast. Tumor status of the sentinel lymph node reflects the status of the nodal basin. Patients who had positive sentinel lymph node metastasis were submitted to complete axillary clearance. In contrast, those who had negative results were spared from undergoing axillary lymph node dissection.

Identification of sentinel lymph nodes is performed by radioactive injection followed by lymphoscintigraphy, or blue dye injection or both. Detection rate of 65.4 to 99.1%, false negative rate of 0 to 14.3%, and overall accuracy of 95.5 to 97.1% were observed<sup>(5-20)</sup>.

There is a discrepancy between the number

## Correspondence to:

Vassanasiri W, Department of Surgery, Faculty of Medicine Ramathibodi Hospital, Mahidol University, Bangkok 10400, Thailand.

Phone: +66-2-2011527 ext. 245, Fax: +66-2-2011527 ext. 214

E-mail: [wvassanasiri@yahoo.com](mailto:wvassanasiri@yahoo.com)

of sentinel lymph nodes identified with lymphoscintigraphy and surgery. Operative sentinel lymph node procedure is usually more sensitive than preoperative detection<sup>(8)</sup>. In most patients, one to two nodes are removed during sentinel lymph node biopsy. However, a wide range of the number of sentinel lymph nodes had been described. This may be a result of instances in which the surgeon was not able to distinguish between the first node stained and other nodes that had become stained subsequently. Multiple radioactive and blue stained lymph nodes are often removed in order to avoid missing a metastatic node. Although some of the radioactive lymph nodes are the second echelon nodes, not true sentinel lymph node, removing too many nodes might lead to more complication after axillary surgery.

The pathologic status of the axilla was independently determined by removal the first or the first and second sentinel lymph node in 99% of the cases<sup>(15)</sup>. Removal of more than three sentinel lymph nodes did not increase accuracy of finding a positive node.

However, practical guideline for optimal nodal staging supports that all blue nodes and all nodes with 10% or more of the ex vivo count of the hottest sentinel lymph node be removed. When these rules are followed, the false negative rate is 5.8%<sup>(7)</sup>. The purpose of this study is to determine the false negative rate of the sentinel lymph node with the highest radioactive count in early stage breast cancer patients.

## Material and Method

Data from the breast and endocrine surgical unit of Ramathibodi hospital, Mahidol University was collected. The eligible criteria for this study are women with invasive ductal carcinoma of the breast with tumor no larger than 5 centimeters (cT1-2) and clinically uninvolved regional nodes diagnosed between July 1, 2014 and January 31, 2015. Patients who had contraindication for sentinel lymph node dissection, clinical nodal involvement, history of neoadjuvant therapy or failure of sentinel lymph node identification were excluded.

The project had been reviewed and approved by the Committee on Human Rights Related to Research Involving Human Subjects, based on the Declaration of Helsinki, protocol number ID 08-57-08.

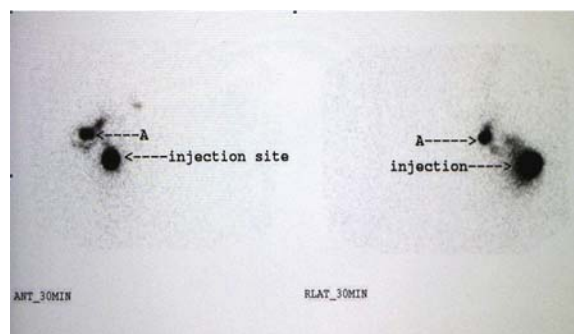
## Procedures

After informed consent was obtained, all selected patients underwent sentinel lymph node

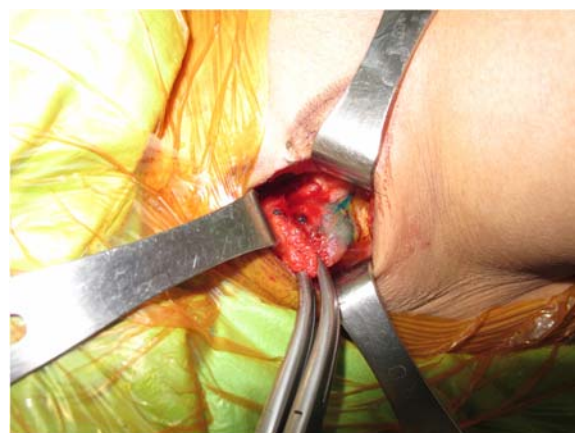biopsy with a combined radioactive tracer and blue dye technique.

Preoperative lymphoscintigraphy was performed at the Department of Nuclear Medicine by an intradermal injection of 0.4 mCi of technetium 99m-labeled dextran in 0.1 ml normal saline at the subareolar area. Then, dynamic and static planar images were obtained in the anterior and lateral chest wall projections (Fig. 1). After lymphoscintigraphy, the patient was moved to the operating room and put under general anesthesia. 1% isosulfan blue dye 1 ml was injected via intradermal route at subareolar area in the operating room.

A handheld gamma-detection probe (Gamma Finder® II) was used to detect the intensity of the gamma radiation and it gave an acoustic signal and a numerical indication. Sentinel lymph nodes identified by the gamma probe and the blue dye staining were classified as followed: blue nodes are blue dye stained nodes (Fig. 2), hottest node is the highest radioactive node



**Fig. 1** Preoperative lymphoscintigraphy of anterior and lateral upper chest view.



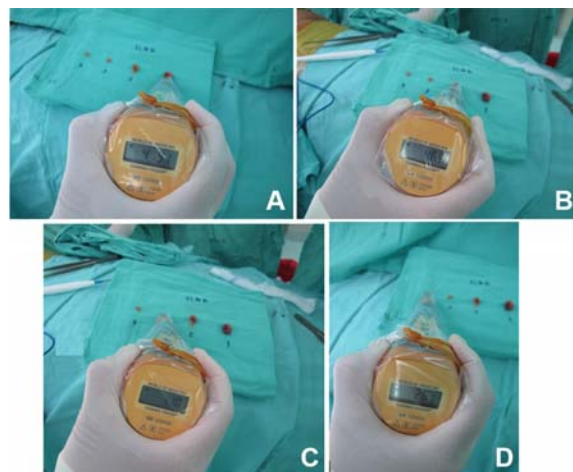
**Fig. 2** Blue dye stained lymph node.

(Fig. 3A), hot nodes are the radioactive nodes (Fig. 3B to Fig. 3D) and suspicious nodes are palpable nodes but neither radioactive nor blue dye stained.

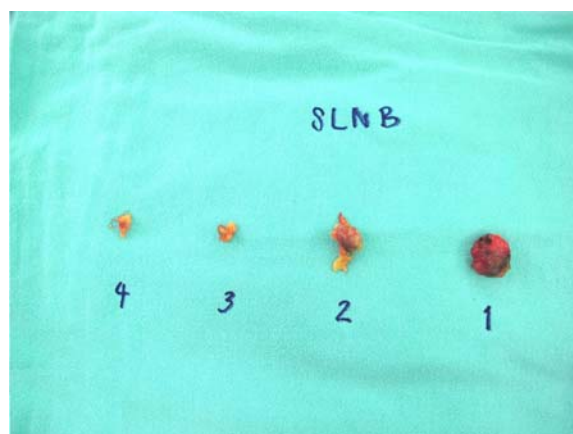
All detected sentinel lymph nodes were sent for frozen section (Fig. 4). In case of positive results, (level I, II) axillary lymph node dissection was performed.

#### Statistical analysis

Data analysis and statistics was processed by SAS statistical software. Quantitative data were calculated into median, mean, range and standard



**Fig. 3** Presentation of 4 radioactive nodes. A) Intra-operative view showing the highest radioactive node (the first sentinel lymph node). B) Presentation of the second radioactive node. C) Presentation of the third radioactive node. D) Presentation of the fourth radioactive node.



**Fig. 4** Specimen of 4 radioactive nodes.

deviation. Furthermore, qualitative data were summarized as percentage. When the highest radioactive sentinel node was pathologically negative but one of the other sentinel or non-sentinel nodes was positive, we defined that as false negative rate of the hottest node.

#### Results

Between July 1, 2014 and January 31, 2015, 130 sentinel lymph node biopsy operations were performed in 129 early stage breast cancer patients. One patient had bilateral breast cancer. The average age of the patients was  $54.5 \pm 11.8$  years old (range 30 to 88 years old). Thirty-eight-point-five percent were premenopausal and 61.5% were postmenopausal women (Table 1).

Amongst the 129 patients with early stage breast cancer, 80 patients (62%) had lesions on left side and 53.9% of all tumors were located in the upper outer quadrant. Ninety-two of the operations (70.8%) were mastectomy and 38 (29.2%) were breast conserving surgery (Table 1). Immediate breast reconstruction with transverse rectus abdominis or latissimus dorsi myocutaneous flap was performed in eight patients (6.2%). The most common histological subtype was invasive ductal carcinoma, found in 113 patients (87%)

**Table 1.** Patient characteristics of 129 patients who underwent combine

| Patient characteristics   | Number (%) |
|---------------------------|------------|
| Age                       |            |
| <50                       | 44 (33.8)  |
| 50 to 70                  | 76 (58.5)  |
| >70                       | 10 (7.7)   |
| Status                    |            |
| Premenopausal             | 50 (38.5)  |
| Postmenopausal            | 80 (61.5)  |
| Side                      |            |
| Left                      | 80 (62)    |
| Right                     | 48 (37.2)  |
| Bilateral                 | 1 (0.8)    |
| Location                  |            |
| Upper outer               | 70 (53.9)  |
| Upper inner               | 30 (23.1)  |
| Lower outer               | 12 (9.2)   |
| Lower inner               | 9 (6.9)    |
| Central                   | 9 (6.9)    |
| Breast operation          |            |
| Mastectomy                | 92 (70.8)  |
| Breast conserving surgery | 38 (29.2)  |

and 52.5% of all tumors are moderately differentiated.

Average tumor size was  $2.1 \pm 1.0$  centimeters (range 0.1 to 5.0 centimeters). Estrogen and progesterone receptor expression, negative hormonal receptor expression, and HER2 over-expression were found in 97 (74.6%), 24 (18.4%), and 12 patients (9.2%), respectively (Table 2). Sentinel lymph nodes were identified in all 130 operations (100%), 107 patients (82.3%) had several sentinel lymph nodes with a median of three (range 1 to 16 nodes). Thirty-nine patients (30%) had nodal metastasis. Of this number, 29 patients had macrometastasis and a complete level I, II axillary lymph node dissection. Eight patients had only micrometastasis, and the axillary lymph node dissection was omitted. Only two patients had intramammary lymph node metastasis found postoperatively. One was scheduled for a complete axillary dissection at another hospital. The other had no further axillary clearance.

Seven of 39 patients with histologically positive lymph nodes (axillary or intramammary) had no evidence of metastasis in the hottest sentinel lymph node (17.9%). When the second and third highest radioactive lymph nodes were also removed, four and three of the 39 patients with histologically positive axillary lymph nodes still had no evidence of metastasis in the hottest sentinel lymph nodes respectively (10.2% and 7.7%). Lastly, when up to the fifth node was included, all of the patients with positive axillary nodes from sentinel lymph node biopsy were identified. Only the two cases with intramammary lymph node metastasis were missed. The correlation between the number of positive sentinel lymph nodes and the histological tumor involved lymph node was demonstrated in Table 3. Surprisingly, the two patients with intramammary lymph node metastasis had no sentinel lymph node metastasis. Further axillary lymph node dissection in one of the two patients also revealed no other node metastasis. The other patient did not receive further axillary lymph node dissection, so the true axillary status is unknown.

## Discussion

Our study showed 100% sentinel lymph node detection rate. The identification rate is higher than the previous study that used isosulfan blue dye alone (91%)<sup>(10)</sup>. Surgeon experience that may have increased with time and the combined method might explain this higher identification rate. A review indicated that the mapping of sentinel lymph nodes in the combination technique have a higher identification rate and lower false negative rate compared to using one method

alone<sup>(19,20)</sup>. Furthermore, another recent meta-analysis of 9,306 patients suggested that using radioactive tracer technique in conjunction with blue dye injection can

**Table 2.** Tumor characteristics of 130 breasts that underwent combine technique sentinel lymph node biopsy

| Tumor characteristics     | Number (%) |
|---------------------------|------------|
| Histology                 |            |
| Ductal                    | 113 (87)   |
| Lobular                   | 5 (3.8)    |
| Mucinous                  | 5 (3.8)    |
| Metaplastic               | 2 (1.5)    |
| Micropapillary            | 2 (1.5)    |
| Solid papillary           | 1 (0.8)    |
| Glycogen rich clear cell  | 1 (0.8)    |
| No special type           | 1 (0.8)    |
| Tumor stage               |            |
| T1mi                      | 4 (3.1)    |
| T1a                       | 4 (3.1)    |
| T1b                       | 15 (11.5)  |
| T1c                       | 40 (30.8)  |
| T2                        | 67 (51.5)  |
| Grade                     |            |
| Well differentiated       | 19 (15.8)  |
| Moderately differentiated | 63 (52.5)  |
| Poorly differentiated     | 38 (31.7)  |
| Hormonal receptor         |            |
| ER+ PR+                   | 97 (67.5)  |
| ER+ PR-                   | 8 (13.7)   |
| ER- PR+                   | 1 (0.9)    |
| ER- PR-                   | 24 (17.9)  |
| Her-2 status by IHC       |            |
| Negative                  | 98 (75.4)  |
| Equivocal                 | 20 (15.4)  |
| Positive                  | 12 (9.2)   |
| Ki-67                     |            |
| <20%                      | 41 (31.8)  |
| >20%                      | 88 (68.2)  |

**Table 3.** Correlation between the number of positive sentinel lymph node and the node that contained tumor metastasis in all 37 patients

| No. of SLNs metastasis | Node that contained the metastasis |                 |                 |                 |                 |
|------------------------|------------------------------------|-----------------|-----------------|-----------------|-----------------|
|                        | 1 <sup>st</sup>                    | 2 <sup>nd</sup> | 3 <sup>rd</sup> | 4 <sup>th</sup> | 5 <sup>th</sup> |
| 1 (n = 24)             | 21                                 | 2               | -               | -               | 1               |
| 2 (n = 8)              | 6                                  | 7               | 2               | 1               | -               |
| 3 (n = 4)              | 4                                  | 4               | 4               | -               | -               |
| 4 (n = 1)              | 1                                  | 1               | 1               | 1               | -               |



achieve a significantly lower false negative rate<sup>(18)</sup>.

Our results found that the number of sentinel nodes removed varied from 1 to 16 nodes. In previous reports, only 1 to 5 nodes were identified<sup>(15)</sup>. This higher number could be due to the type of mapping agent, timing of injection, and definition of sentinel lymph node.

Although particle size of colloids employed for detection is not well studied, many radiotracers have been used for sentinel node mapping with acceptable result<sup>(21)</sup>. Label colloids with most of the particles in the 100 to 200 nm size range would be ideal for sentinel node biopsy in breast cancer. There are numerous types of colloid used. The original studies conducted in United States used sulfur colloid. Albumin is the most commonly use colloid in Europe and antimony trisulfide is the popular choice in Australia. In Ramathibodi hospital, we use technetium 99 m-labeled dextran. It is small enough to migrate rapidly, hence, remarkably influence nodal uptake and the number of nodes identified in this study.

In addition, radioactive tracer injection can be performed either intraoperatively or preoperatively. One of the main advantages of preoperative injection is the ability to obtain images to show the number of sentinel lymph nodes. However, intraoperative injection under anesthesia can decrease patient's anxiety, pain, and operative schedule delay. Current study found that the sentinel node identification rate and number of removed sentinel nodes and overall rates of positive sentinel nodes are similar with either technique<sup>(22)</sup>.

To decrease the risk of axillary understaging, all detected radioactive nodes, not only the 10% or more of *ex vivo* highest count, were removed. This resulted in the maximum number of dissected sentinel lymph nodes to 16 in this study. Therefore, we assumed that some less radioactive nodes were not true sentinel lymph nodes. These nodes removal did not affect the accuracy of axillary staging.

According to previous studies, removal of only the highest radioactive node have a false negative rate of 13.9 to 17.7% versus 2.8 to 4.3% for multiple sentinel lymph nodes removed and the rate is decreased to 1% if five or more nodes were removed<sup>(15,23)</sup>. The positive nodes were identified within the first three nodes examined. Our study did not perform axillary lymph node dissection in every patient (it was omitted if sentinel node was negative for metastasis), so, the true false negative rate cannot be calculated. Our data can only calculate the rate of histologically positive lymph nodes that had no evidence of metastasis in the

hottest sentinel lymph node (termed as false negative rate in our study). This study agrees with the previous studies in confirming that removing only the most radioactive node is not very accurate. The false negative rate can be decreased from 17.9 to 7.7% when node removal includes the second and third nodes. Only one case showed fifth node metastasis without metastasis to the first four nodes. These data supported the policy that all blue nodes and all nodes with 10% or more of *ex vivo* count of highest radioactivity count should be harvested, in order to not miss any metastasis.

Although, all sentinel lymph nodes were removed, the accuracy of axillary staging may not reach 100%. Five-point-one percent of patients with negative sentinel lymph node result had intramammary lymph node metastasis, which is very hard to predict. Previous studies showed that pathological intramammary lymph node metastasis range from 2.6 to 28% of all cases<sup>(24-26)</sup>, however, isolated involvement of the intramammary lymph node without axillary metastases was documented at 5 to 9%<sup>(24,25)</sup>.

The argument lies in whether a positive intramammary node warrants a complete axillary lymph node dissection or whether it can be spared. Due to the limited number of cases reported, there is no standard treatment for metastatic intramammary node with no sentinel lymph node metastasis. Currently, there are contradicting data. The use of a nomogram demonstrated that the risk of axillary metastasis was less than 10% and another study showed only 6.25%<sup>(26)</sup>. Interestingly, in a review of database, all negative axillary sentinel lymph node biopsy accurately represented the disease status of the axilla. Therefore, complete axillary clearance could be avoided in the setting of a positive intramammary lymph node<sup>(27)</sup>. In contrast, other studies demonstrated 21 to 81% of intramammary lymph node metastasis also had axillary metastasis, further axillary dissection should be performed<sup>(24-26,28)</sup>.

## Conclusion

Removal of the sentinel lymph node with the highest radioactivity alone can misinterpret the patient's axillary nodal status. By including at least the third node, the accuracy of predicting nodal metastasis is increased.

## What is already known on this topic?

According to the American Society of Breast Surgeons guideline, one should aim to remove the

“hottest” sentinel lymph node (SLN). Many surgeons also use the “10% rule” and remove all nodes whose counts are 10% or more of the hottest node.

#### What this study adds?

This study confirms that removing only the “hottest” node is inadequate due to high false negative rate. The false negative rate decreases to an acceptable value when at least three lymph nodes are removed. We used 0.4 mCi of technetium 99 m-labeled dextran in 0.1 ml volume instead of 0.5 mCi of filtered technetium 99 m-labeled sulfur colloid in 6 ml volume in the original study referenced by the guideline.

#### Potential conflicts of interest

None.

#### References

- De Gournay E, Guyomard A, Coutant C, Boulet S, Arveux P, Causeret S, et al. Impact of sentinel node biopsy on long-term quality of life in breast cancer patients. *Br J Cancer* 2013; 109: 2783-91.
- Di Sipio T, Rye S, Newman B, Hayes S. Incidence of unilateral arm lymphoedema after breast cancer: a systematic review and meta-analysis. *Lancet Oncol* 2013; 14: 500-15.
- Monleon S, Murta-Nascimento C, Bascuas I, Macia F, Duarte E, Belmonte R. Lymphedema predictor factors after breast cancer surgery: A survival analysis. *Lymphat Res Biol* 2015; 13: 268-74.
- Bergmann A, Mendes VV, de Almeida DR, do Amaral E Silva, da Costa Leite Ferreira MG, Fabro EA. Incidence and risk factors for axillary web syndrome after breast cancer surgery. *Breast Cancer Res Treat* 2012; 131: 987-92.
- Canavese G, Gipponi M, Catturich A, Di Somma C, Vecchio C, Rosato F, et al. Sentinel lymph node mapping in early-stage breast cancer: technical issues and results with vital blue dye mapping and radioguided surgery. *J Surg Oncol* 2000; 74: 61-8.
- Gipponi M, Bassetti C, Canavese G, Catturich A, Di Somma C, Vecchio C, et al. Sentinel lymph node as a new marker for therapeutic planning in breast cancer patients. *J Surg Oncol* 2004; 85: 102-11.
- Martin RC 2nd, Edwards MJ, Wong SL, Tuttle TM, Carlson DJ, Brown CM, et al. Practical guidelines for optimal gamma probe detection of sentinel lymph nodes in breast cancer: results of a multi-institutional study. For the University of Louisville Breast Cancer Study Group. *Surgery* 2000; 128: 139-44.
- Volders JH, van la Parra RF, Bavelaar-Croon CD, Barneveld PC, Ernst MF, Bosscha K, et al. Discordance between number of scintigraphic and perioperatively identified sentinel lymph nodes and axillary tumour recurrence. *Breast* 2014; 23: 159-64.
- Khalifa K, Pereira B, Thomas VA, Mokbel K. The accuracy of intraoperative frozen section analysis of the sentinel lymph nodes during breast cancer surgery. *Int J Fertil Womens Med* 2004; 49: 208-11.
- Kantaraksa N, Kongdan Y, Suvikapakornkul R, Wasutit Y, Chirappapha P, Lertsithichai P. The relative false negative rate of isosulfan blue in detecting sentinel lymph nodes in early breast cancer. *J Med Assoc Thai* 2012; 95: 181-5.
- Kern KA, Rosenberg RJ. Preoperative lymphoscintigraphy during lymphatic mapping for breast cancer: improved sentinel node imaging using subareolar injection of technetium 99m sulfur colloid. *J Am Coll Surg* 2000; 191: 479-89.
- Kern KA. Concordance and validation study of sentinel lymph node biopsy for breast cancer using subareolar injection of blue dye and technetium 99m sulfur colloid. *J Am Coll Surg* 2002; 195: 467-75.
- Giuliano AE, Kirgan DM, Guenther JM, Morton DL. Lymphatic mapping and sentinel lymphadenectomy for breast cancer. *Ann Surg* 1994; 220: 391-8.
- Acuna SA, Angarita FA, Escallon J. Assessing patterns of practice of sentinel lymph node biopsy for breast cancer in Latin America. *World J Surg* 2014; 38: 1077-83.
- Schrenk P, Rehberger W, Shamiyeh A, Wayand W. Sentinel node biopsy for breast cancer: does the number of sentinel nodes removed have an impact on the accuracy of finding a positive node? *J Surg Oncol* 2002; 80: 130-6.
- Krag DN, Anderson SJ, Julian TB, Brown AM, Harlow SP, Ashikaga T, et al. Technical outcomes of sentinel-lymph-node resection and conventional axillary-lymph-node dissection in patients with clinically node-negative breast cancer: results from the NSABP B-32 randomised phase III trial. *Lancet Oncol* 2007; 8: 881-8.
- Krag DN, Ashikaga T, Harlow SP, Skelly JM, Julian TB, Brown AM, et al. Surgeon training, protocol compliance, and technical outcomes from breast cancer sentinel lymph node randomized trial. *J Natl Cancer Inst* 2009; 101: 1356-62.
- Pesek S, Ashikaga T, Krag LE, Krag D. The false-

- negative rate of sentinel node biopsy in patients with breast cancer: a meta-analysis. *World J Surg* 2012; 36: 2239-51.
19. Cody HS 3rd. Clinical aspects of sentinel node biopsy. *Breast Cancer Res* 2001; 3: 104-8.
  20. Somasundaram SK, Chicken DW, Keshtgar MR. Detection of the sentinel lymph node in breast cancer. *Br Med Bull* 2007; 84: 117-31.
  21. Nunez EG, Faintuch BL, Teodoro R, Wiecek DP, Martinelli JR, da Silva NG, et al. Influence of colloid particle profile on sentinel lymph node uptake. *Nucl Med Biol* 2009; 36: 741-7.
  22. Dambros Gabbi MC, Masiero PR, Uchoa D, Moraes IV, Biazus JV, Edelweiss MI. Comparison between preoperative and intraoperative injection of (99m)Tc Dextran-500 for sentinel lymph node localization in breast cancer. *Am J Nucl Med Mol Imaging* 2014; 4: 602-10.
  23. Wong SL, Edwards MJ, Chao C, Tuttle TM, Noyes RD, Carlson DJ, et al. Sentinel lymph node biopsy for breast cancer: impact of the number of sentinel nodes removed on the false-negative rate. *J Am Coll Surg* 2001; 192: 684-9.
  24. Cox CE, Cox JM, Ramos D, Meade TL. Intramammary sentinel lymph nodes: what is the clinical significance? *Ann Surg Oncol* 2008; 15: 1273-4.
  25. Shen J, Hunt KK, Mirza NQ, Krishnamurthy S, Singletary SE, Kuerer HM, et al. Intramammary lymph node metastases are an independent predictor of poor outcome in patients with breast carcinoma. *Cancer* 2004; 101: 1330-7.
  26. Vieira RA, Viviani DN, Ferreira SS, Bailao A Jr, Kerr LM, Matthes AG, et al. Intramammary lymph node sentinel metastasis without metastasis in axilla. Axillary lymph node dissection or conservative surgery? *Rev Bras Ginecol Obstet* 2012; 34: 478-82.
  27. Diaz R, Degnim AC, Boughey JC, Nassar A, Jakub JW. A positive intramammary lymph node does not mandate a complete axillary node dissection. *Am J Surg* 2012; 203: 151-5.
  28. Guth AA, Mercado C, Roses DF, Hiotis K, Skinner K, Diflo T, et al. Intramammary lymph nodes and breast cancer: a marker for disease severity, or just another lymph node? *Am J Surg* 2006; 192: 502-5.

ค่าผลลบของต่อน้ำเหลืองเซนต์เนลที่มีค่ากัมมันตรังสีสูงที่สุดในกลุ่มผู้ป่วยมะเร็งเต้านมระยะต้น

ประกาศิต จิรปภา, รุจิรา พนาวัฒน์กุล, วฐิ วาสนสิริ, เขาวนุช คงคาน, ภาณุวัฒน์ เลิศสิทธิชัย, ธงชัย สุกรโยธิน, มนต์ชัย ลีสมบัติไพบูลย์,  
ยอดยิ่ง วาสถิตย, ธรณ์รัฐ สวัสดิ์ปรกรณ์กุล

ภูมิหลัง: การผ่าตัดตอมัน্ন์เหลืองในผู้ป่วยมะเร็งเต้านมได้เปลี่ยนแปลงไปมากตั้งแต่มีการค้นพบทฤษฎีของตอมัน্ন์เหลืองเซนทิเนล การเลาะตอมัน্ন์เหลืองเซนทิเนลเกิดภาวะแทรกซ้อนน้อยกว่าการเลาะตอมัน্ন์เหลืองทั้งหมดมาก แต่การเลาะตอมัน্ন์เหลืองเซนทิเนลเองก็อาจได้ตอมัน্ন์เหลืองเพียงสองถึงสามต่อมหรือมากเกินสิบต่อมได้ ซึ่งการเอาตอมัน্ন์เหลืองออกปริมาณมากก็เพิ่มโอกาสเกิดภาวะแทรกซ้อน คณะผู้นิพนธ์จึงต้องการศึกษาความแม่นยำของการตรวจตอมัน্ন์เหลืองเซนทิเนลต่อมที่มีค่ากำมันตรังสีสูงที่สุดเพียงต่อมเดียว

**วัตถุประสงค์:** เพื่อศึกษาความแม่นยำของการตรวจค่อน้ำเหลืองเซนทิเนลในต่อมที่มีค่ากัมมันตรังสีสูงที่สุดและต่อมที่ค่ากัมมันตรังสีสูงลดหลั่นลงมา

**วัสดุและวิธีการ:** ประชากรการศึกษาคือผู้ป่วยหญิงที่เป็นมะเร็งเต้านมขนาดน้อยกว่า 5 เซนติเมตร และตรวจร่างกายไม่พบค่อน้ำเหลืองโต ที่เข้ารับการรักษาด้วยการผ่าตัดค่อน้ำเหลืองเซนทิเนลในหน่วยศัลยศาสตร์เต้านมและต่อมไร้ท่อ โรงพยาบาลรามาธิบดีระหว่างวันที่ 1 กรกฎาคม พ.ศ. 2557 ถึง วันที่ 31 มกราคม พ.ศ. 2558 ค่ากัมมันตรังสีของค่อน้ำเหลืองเซนทิเนลเม็ดต่างๆ จะถูกบันทึกและนำมาเรียงลำดับจากมากไปน้อย และนำมาคำนวณค่าผลลบลง ค่าผลลบลงคืออัตราของการกระจายไปค่อน้ำเหลืองที่รักแร้เม็ดอื่นๆ โดยที่ค่อน้ำเหลืองที่มีค่ากัมมันตรังสีสูงที่สุดให้ผลเป็นลบ

ผลการศึกษา: มีการผ่าตัดต่อน้ำเหลืองเซนทิเนลทั้งสิ้น 130 ครั้งในช่วงระยะเวลาที่ศึกษา ในจำนวนนี้มีผู้ป่วย 39 ราย ที่พบมะเร็งกระจายไปต่อน้ำเหลืองเซนทิเนล ค่าผลลบลงเมื่อผ่าตัดแค่ต่อน้ำที่ค่ากัมมันตรังสีสูงสุดเพียงต่อน้ำเดียวคือร้อยละ 17.9 แต่เมื่อนำต่อน้ำที่ค่ากัมมันตรังสีต่ำลงมาคือต่อน้ำที่สองและสามจะสามารถลดค่าผลลบลงลงได้เป็นร้อยละ 7.7

สรุป: การผ่าตัดคอตมน้ำเหลืองเซนทิเนลโดยเจาะเฉพาะคอตมน้ำเหลืองที่มีค่ากัมมันตรังสีสูงที่สุดเพียงคอตมน้ำเดียว ยังมีโอกาสบอกถึงระยะของโรคที่คอตมน้ำเหลืองได้คลาดเคลื่อนอยู่มาก การเจาะคอตมน้ำเหลืองเซนทิเนลให้ครอบคลุมไปถึงคอตมน้ำที่กัมมันตรังสีมากเป็นอันดับ 2 และ 3 จะช่วยลดข้อผิดพลาดลงได้