

Case Report

High Dose Rate Endobronchial Brachytherapy (HDR-EB) in Recurrent Benign Complex Tracheobronchial Stenosis: Experience in Two Cases

Jamsak Tscheikuna MD*,
Supparerk Disayabutr MD*, Chumpot Kakanaporn MSc**,
Lalida Tuntipumi-amorn MSc**, Yaowalak Chansilpa MD**

* Division of Respiratory Disease and Tuberculosis, Department of Internal Medicine, Faculty of Medicine, Siriraj Hospital, Mahidol University, Bangkok, Thailand

** Department of Radiology, Faculty of Medicine, Siriraj Hospital, Mahidol University, Bangkok, Thailand

Benign complex tracheobronchial stenosis (BCTS) is a tracheobronchial stenosis that is longer than 1 cm or has more than one site of stenotic area. The most common etiology of the stenosis is endobronchial tuberculosis. BCTS causes challenge in diagnosis and management because of nonspecific presentation and usually precluded surgical treatment. Available interventional bronchoscopic techniques fail to manage BCTS because of high rate of restenosis. Experience in using HDR brachytherapy to prevent restenosis in two cases of BCTS is reported.

Cases Report: There were two cases of BCTS who received HDR brachytherapy in order to prevent restenosis. First case was a 39 year-old female who had 5 cms tracheal and 2 cms left main bronchial stenosis from previous endobronchial tuberculosis. After 36 procedures of tracheobronchial dilatation by rigid bronchoscopy and two tracheal stents placement, her trachea became restenosis in an average time of 1 month. She also developed anaphylactic reaction with lidocaine. She received HDR brachytherapy with the dose of 10 Gy and no restenosis was found after 5 months follow-up.

The second case was a 18 year-old male who had 4 cms tracheal stenosis result from post intubation. He was done dilatation and stenting of the trachea by rigid bronchoscopy because he refused surgery. After 1 year, the tracheal stent was removed and rapid restenosis of the trachea resulted in respiratory failure occurred in 7 days. The tracheal stent was re-implanted and 1 year later 7.0 Gy HDR brachytherapy was done after stent removal. He was doing well 4 months after with 50% tracheal stenosis and occasional stridor.

Conclusion: Failure of intervention bronchoscopic techniques in management of BCTS was significantly shown by the restenosis even after endobronchial stent placement. HDR brachytherapy had a beneficial role in preventing granulation tissue formation and delay or prevent restenosis after bronchoscopic dilatation in selected case of BCTS patients. The case selection and long term outcome were needed before introduced HDR brachytherapy to be the standard care of BCTS patients.

Keywords: High dose rate endobronchial brachytherapy, Benign complex tracheobronchial stenosis

J Med Assoc Thai 2013; 96 (Suppl. 2): S252-S256

Full text. e-Journal: <http://jmat.mat.or.th>

Benign complex tracheobronchial stenosis (BCTS) is a tracheobronchial stenosis that is longer than 1 cm or has more than one site of stenotic area⁽¹⁾. The most common etiology of the stenosis is endobronchial tuberculosis. BCTS causes challenge in diagnosis and management because of nonspecific presentation and usually precluded surgical treatment. Available interventional bronchoscopic techniques fail to manage BCTS because of high rate of restenosis.

Correspondence to:

Tscheikuna J, Division of Respiratory Disease and Tuberculosis, Faculty of Medicine Siriraj Hospital, Mahidol University, Bangkok 10700, Thailand.
Phone: 0-2419-7757
E-mail: tscheikuna@gmail.com

High dose rate endobronchial brachytherapy (HDR-EB) is a method which applies the radiation source into the airway. The rapid dose fall off makes this technique more favorable than external beam radiation in limiting the radiation effect to the bronchial wall. HDR-EB has long been used to palliate malignant airway obstruction. The use of radiation therapy in the treatment of benign disease such as keloids, coronary artery stenosis, peripheral vascular restenosis are known^(2,3). Experience in using HDR-EB to prevent restenosis in two cases of BCTS is reported.

Cases Report

Retrospective analyses of data from medical records of BCTS patients who received HDR-EB to

prevent restenosis were done. The indication, sites, length, etiology, number of interventional bronchoscopic procedures and time interval before the brachytherapy were reported. Outcomes after HDR-EB were shown.

There were two cases of BCTS who received HDR-EB in order to prevent restenosis. The first case was a 39 year-old female who had 5 cms tracheal and 2 cms left main bronchial stenosis from previous endobronchial tuberculosis. After 36 procedures of tracheobronchial dilatation by rigid bronchoscopy and two tracheal stents placement, her trachea underwent restenosis at an average time of once per month. She also developed anaphylactic reaction with lidocaine. She was scheduled for rigid bronchoscopy under intravenous sedation and endobronchial treatment include electrocautery, mechanical debulking and mechanical dilatation with re-implant of tracheal stent (Fig. 1A). After a patent airway was established (Fig. 1B), the rigid bronchoscope was removed and flexible bronchoscope was passed to the trachea via the nose. A blind-ended flexible brachytherapy catheter was placed into her trachea and right main bronchus. The catheter was secured over her nose by the plaster and radiopaque-dummy seeds were inserted (Fig. 1C). She was transferred from the operating room to the radiation department before fully woke up. All procedure was done without local lidocaine anesthesia. She received HDR-EB with the dose of 10 Gy and no restenosis was found after 5 months follow-up.

The second case was 18 year-old male who had 4 cms tracheal stenosis resulting from post intubation. He underwent dilatation and stenting of the trachea under rigid bronchoscopy because he refused surgery. After 1 year, the silicone tracheal stent was removed and rapid restenosis of the trachea resulted in respiratory failure occurred in 7 days. The silicone tracheal stent was re-implanted. One year later, he was scheduled for silicone stent removal. His airway was around 80% patency with some granulation tissue at the proximal and distal end of the previous stent area after the stent had been removed (Fig. 2A). One day later, at the radiation department, the flexible bronchoscopy was done via the nose and the markers were placed on the skin at the proximal and distal end of the lesion under fluoroscopic guidance (Fig. 2B); after that a blind-ended flexible brachytherapy catheter was placed into the trachea passed the stenotic site. The bronchoscope was removed and the catheter was secured to his nose by the plaster. A radio-paque-dummy seed was inserted into the catheter and after the dose

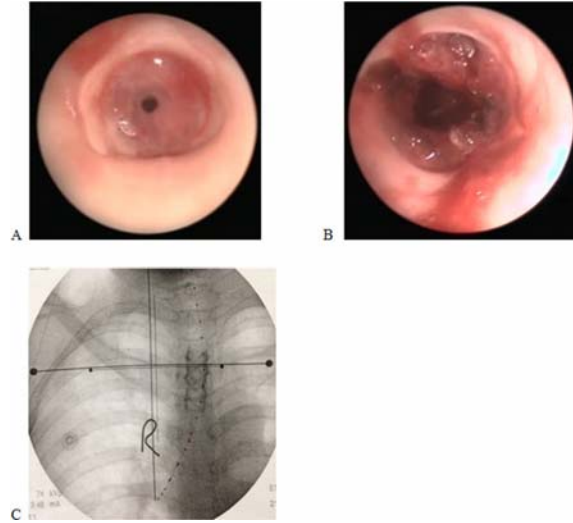


Fig. 1 A) Endoscopic view of tracheal stenosis in case 1 before dilatation B) View after electrocautery and mechanical dilatation C) The simulation film showed the radiopaque-dummy source in the catheter placed in the trachea and right main bronchus. Bronchoscopic examination provided evidence that the extent of disease located at proximal end of the stent to the carina

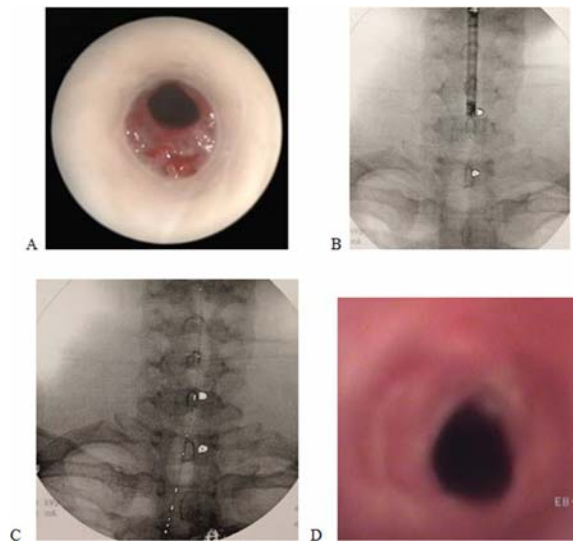


Fig. 2 A) Endoscopic views of granulation tissue at distal end of tracheal stent. B) After bronchoscopic examination under fluoroscopic guidance. Two markers were placed on the chest wall to indicate the upper and lower end of the lesion. C) The luminal catheter with radiopaque-dummy source was placed in the trachea. D) Residual stenosis of trachea after 4 months of HDR-EB

calculation (Fig. 2C), HDR-EB after loading with Iridium 192 with a total dose of 7.0 Gy at a depth of 1 cm around the center of the catheter was delivered. He was doing well 4 months there after with 50% tracheal stenosis and occasional stridor (Fig. 2D).

Discussion

Benign complex tracheobronchial stenosis (BCTS) is a stenosis of the trachea and bronchus that longer than 1 cm or has more than one stenotic area. Most common etiology causing BCTS is endobronchial tuberculosis. BCTS causes challenge in diagnosis and management because of nonspecific presentation and usually precluded surgical treatment. Available intervention bronchoscopic techniques fail to manage BCTS because of high rate of restenosis.

High dose rate endobronchial brachytherapy (HDR-EB) was accepted for the palliative management of endobronchial malignant obstruction. The use of HDR-EB in benign endobronchial obstruction was first described by Kennedy et al⁽⁴⁾ in 2000. Up until 2008, there were 25 cases reported in literatures^(4,9). Among these cases reports, 17 were caused by granulation tissue at post lung transplant anastomosis site; another 8 were stenosis at the stent sites. In only one patient was the stenosis caused by granulation tissue from previous tracheostomy. In the present report, the cause of stenosis was post endotracheal intubation in one patient; the other patient suffer from post endobronchial tuberculosis.

In endobronchial tuberculosis, some patients develop airway stenosis during treatment. Among these patients, few have recurrent airway stenosis after bronchoscopic intervention or surgical resection and end to end anastomosis. Abnormal expression of TGF β at the site of airway injury was proposed to be the explanation but has never been proven^(10,11). Local radiation to inhibit cells that lead to the expression of TGF β seems to be the reasonable approach in preventing restenosis⁽¹²⁾.

Hemoptysis and radiation bronchitis are recognized through late toxicity of HDR-EB in patients who have a malignant process. The endobronchial tumor length and tumor located in trachea and main bronchus were predictive factors for these late complications⁽¹³⁾. There are three cases of toxicity from HDR-EB in benign lesion. These were one anastomotic dehiscence, one bronchoarterial fistula and one radiation necrosis. There is no toxicity found in the present report. Because most patients are young and expected to have an excellent survival rate, long term

complications should not be expected during follow-up.

BCTS is a condition of medical challenge for the responsible physician. In some difficult cases, conventional methods in intervention bronchoscopy could only be palliative the obstructive symptom with high rate of rapidly recurrent. HDR-EB is promising in this specific situation but more information regarding suitable time for initiation of this treatment, dose of radiation, number of sessions and complications are needed.

Conclusion

Failure of interventional bronchoscopic techniques in management of BCTS was significantly shown by the restenosis even after endobronchial stent placement. HDR-EB had a beneficial role in preventing granulation tissue formation and for delay or prevention restenosis after bronchoscopic dilatation in selected cases of BCTS patients. The case selection and long term outcome studies are needed before introducing HDR-EB to be the standard care of BCTS patients.

Potential conflicts of interest

None.

References

1. Alvarez-Maldonado P, Pena J, Criales-Cortes JL, Navarro-Reynoso F, Perez-Romo A, Cicero-Sabido R. Benign tracheal stenosis: a case series analysis. *J Bronchology Interv Pulmonol* 2009; 16: 254-60.
2. Teirstein PS, Massullo V, Jani S, Popma JJ, Mintz GS, Russo RJ, et al. Catheter-based radiotherapy to inhibit restenosis after coronary stenting. *N Engl J Med* 1997; 336: 1697-703.
3. Pokrajac B, Potter R, Wolfram RM, Budinsky AC, Kirisits C, Lileg B, et al. Endovascular brachytherapy prevents restenosis after femoropopliteal angioplasty: results of the Vienna-3 randomised multicenter study. *Radiother Oncol* 2005; 74: 3-9.
4. Kennedy AS, Sonett JR, Orens JB, King K. High dose rate brachytherapy to prevent recurrent benign hyperplasia in lung transplant bronchi: theoretical and clinical considerations. *J Heart Lung Transplant* 2000; 19: 155-9.
5. Kramer MR, Katz A, Yarmolovsky A, Schifter D, Fenig E. Successful use of high dose rate brachytherapy for non-malignant bronchial obstruction. *Thorax* 2001; 56: 415-6.
6. Brenner B, Kramer MR, Katz A, Feinmesser R, Weissmann-Brenner A, Sulkes A, et al. High dose

- rate brachytherapy for nonmalignant airway obstruction: new treatment option. *Chest* 2003; 124: 1605-10.
7. Halkos ME, Godette KD, Lawrence EC, Miller JJ Jr. High dose rate brachytherapy in the management of lung transplant airway stenosis. *Ann Thorac Surg* 2003; 76: 381-4.
 8. Madu CN, Machuzak MS, Sterman DH, Musani A, Ahya V, McDonough J, et al. High-dose-rate (HDR) brachytherapy for the treatment of benign obstructive endobronchial granulation tissue. *Int J Radiat Oncol Biol Phys* 2006; 66: 1450-6.
 9. Tendulkar RD, Fleming PA, Reddy CA, Gildea TR, Machuzak M, Mehta AC. High-dose-rate endobronchial brachytherapy for recurrent airway obstruction from hyperplastic granulation tissue. *Int J Radiat Oncol Biol Phys* 2008; 70: 701-6.
 10. Kim Y, Kim K, Joe J, Park H, Lee M, Kim Y, et al. Changes in the levels of interferon-gamma and transforming growth factor-beta influence bronchial stenosis during the treatment of endobronchial tuberculosis. *Respiration* 2007; 74: 202-7.
 11. Zhang J, Li Q, Bai C, Han Y, Huang Y. Inhalation of TGF-beta1 antibody: a new method to inhibit the airway stenosis induced by the endobronchial tuberculosis. *Med Hypotheses* 2009; 73: 1065-6.
 12. Rubin P, Williams JP, Riggs PN, Bartos S, Sarac T, Pomerantz R, et al. Cellular and molecular mechanisms of radiation inhibition of restenosis. Part I: role of the macrophage and platelet-derived growth factor. *Int J Radiat Oncol Biol Phys* 1998; 40: 929-41.
 13. Hennequin C, Tredaniel J, Chevret S, Durdux C, Dray M, Manoux D, et al. Predictive factors for late toxicity after endobronchial brachytherapy: a multivariate analysis. *Int J Radiat Oncol Biol Phys* 1998; 42: 21-7.

การฉายรังสีพลังงานสูงทางหลอดเลือดในผู้ป่วยหลอดเลือดใหญ่อุดตันที่มีสาเหตุจากโรคไม่รุนแรง รายงานผู้ป่วยสองราย

แจ่มศักดิ์ ไชยคุนา, ศุภฤกษ์ ดิษยบุตร, จุมพฏ คัคณาพร, ลลิตา ตันติภูมิอมร, เยาวลักษณ์ ชาญศิลป์

ภูมิหลัง: ภาวะหลอดเลือดใหญ่อุดตันสาเหตุจากโรคไม่รุนแรงส่วนใหญ่มีสาเหตุมาจากการติดเชื้อวัณโรคในหลอดเลือดหรือจากการที่เคย์ใส่ท่อช่วยหายใจ ภาวะนี้มักทำให้เกิดปัญหาในการวินิจฉัยจากอาการที่ไม่จำเพาะและส่วนหนึ่งไม่สามารถรับการรักษาโดยการผ่าตัดได้เนื่องจากรอยโรคมีขนาดยาวหรือเป็นหลายจุด การรักษาโดยการขยายหลอดเลือดหรือการใส่ท่อค้ำหลอดเลือดมีข้อจำกัดที่มักมีการเกิดซ้ำของการตีบได้บ่อย รายงานนี้

วัตถุประสงค์: นำเสนอผู้ป่วยภาวะนี้สองรายที่ได้รับการรักษาด้วยการฉายรังสีพลังงานสูงทางหลอดเลือด เพื่อป้องกันการเกิดซ้ำของหลอดเลือดอุดตัน

รายงานผู้ป่วย: จากการสืบค้นรายงานประวัติการรักษาผู้ป่วยที่ได้รับการรักษาวิธีนี้จนถึงเดือนพฤษภาคม พ.ศ. 2555 มีผู้ป่วยสองราย รายแรกเป็นผู้ป่วยหญิงอายุ 39 ปีมีอาการของหลอดเลือดใหญ่กลางอุดตันความยาว 5 ซม. และหลอดเลือดใหญ่อันซ้ายอุดตันความยาว 2 ซม. หลังจากมารับการขยายหลอดเลือดรวม 36 ครั้ง และวางท่อค้ำหลอดเลือดใหญ่ 2 ชิ้น หลอดลมใหญ่ยังคงอุดตันซ้ำทุก 1 เดือนและเริ่มมีอาการแพ้ยาชา ผู้ป่วยได้รับการฉายรังสีพลังงานสูงทางหลอดเลือดในขนาด 10 Gy และไม่พบการอุดตันซ้ำอีกเลยหลังจากติดตาม 5 เดือน ผู้ป่วยรายที่สองเป็นผู้ชายอายุ 18 ปีมีหลอดเลือดใหญ่อุดตันยาว 4 ซม. หลังการใส่ท่อช่วยหายใจ เนื่องจากผู้ป่วยปฏิเสธการผ่าตัดจึงได้รับการขยายหลอดเลือดและใส่ท่อค้ำไว้นาน 1 ปี เมื่อนำท่อค้ำออก พบว่าหลอดเลือดใหญ่กลับมาอุดตันในเวลา 7 วัน จึงได้รับการใส่ท่อค้ำต่ออีก หนึ่งปีถัดมาได้นำท่อค้ำหลอดเลือดใหญ่ออก อีกครั้งนี้ได้ทำการฉายรังสีพลังงานสูงทางหลอดเลือดในขนาด 7.0 Gy ภายหลัง 4 เดือนต่อมาผู้ป่วยมีอาการ ของหลอดเลือดใหญ่อุดตันเล็กน้อย ตรวจหลอดเลือดพบการอุดตันของหลอดเลือดใหญ่ไม่มาก

สรุป: การขยายหลอดเลือดและมาตรการต่างๆ เช่นการใส่ท่อค้ำหลอดเลือดใหญ่ในผู้ป่วยหลอดเลือดใหญ่ อุดตันที่มีสาเหตุจากโรคไม่รุนแรงมีข้อจำกัดจากการอุดตันซ้ำที่เกิดขึ้นบ่อยในผู้ป่วยบางราย การฉายรังสี พลังงานสูงทางหลอดเลือด เป็นวิธีการรักษาหนึ่งที่น่าจะได้ประโยชน์ในกรณีนี้ อย่างไรก็ตามข้อมูลในการเลือกผู้ป่วย และการติดตามผู้ป่วยให้นานกว่านี้เพื่อดูผลข้างเคียง จำเป็นในการแนะนำการรักษาวิธีนี้ต่อไป
