

## Case Report

# Cesarean Scar Choriocarcinoma: A Case Report and Review of Literature

Thannaporn Kittisiam MD<sup>1</sup>, Thaovalai Thavaramara MD<sup>1</sup>,  
Chutima Chavanisakun MD<sup>2</sup>, Sunamchok Srijaipracharoen MD<sup>1</sup>, Siriwan Tanjitgamol MD<sup>1</sup>

<sup>1</sup> Department of Obstetrics and Gynecology, Faculty of Medicine Vajira Hospital,  
Navamindradhiraj University, Bangkok, Thailand

<sup>2</sup> Department of Pathology, Faculty of Medicine Vajira Hospital, Navamindradhiraj University, Bangkok, Thailand

Gestational choriocarcinoma [GCC] is an uncommon trophoblastic neoplasm. In an extremely rare circumstance, the GCC over the site of cesarean scar may occur. We reported a patient who presented with vaginal bleeding and rising beta-hCG level two weeks after treatment of abortion. Ultrasonography showed a small content located at lower part of uterus. Provisional diagnosis was a Cesarean scar pregnancy and the patient decided to have hysterectomy. Histopathologic examination reported small foci of choriocarcinoma at Cesarean scar. The diagnosis was stage 1:3 choriocarcinoma. After surgical treatment, her beta-hCG level gradually declined to normal value. Without adjuvant treatment, she was doing well with no evidence of recurrent disease for 25 months after surgery. In conclusion, although it has been generally known that GCC usually occurs months to years after pregnancy, gestational trophoblastic disease cannot be overlooked in the case that is clinically suspicious. Surgical treatment might be effective without adjuvant chemotherapy in some selected cases; however, the beta-hCG level must be monitored closely.

**Keywords:** Gestation choriocarcinoma, Cesarean scar, Pregnancy, Trophoblastic neoplasm

**J Med Assoc Thai 2018; 101 (Suppl. 8): S201-S204**

**Website:** <http://www.jmatonline.com>

Gestational choriocarcinoma [GCC] is an uncommon trophoblastic neoplasm. Among South-eastern Asian countries, the incidence ranged from 0.4 to 2 in 1,000 pregnancies<sup>(1)</sup>. Approximately half of GCC occurred after molar pregnancy, 22% followed normal pregnancy and only 3% took place after ectopic pregnancy<sup>(2)</sup>.

Parallel with a physiologic site of embryonic implantation, GCC is commonly found in the uterine body. The extrauterine origins which are less common include ovary<sup>(3)</sup>, cervix<sup>(4)</sup>, and vagina<sup>(5)</sup>. In a rare circumstance, the GCC over the site of cesarean scar may occur<sup>(6-10)</sup>.

The authors reported clinic-pathological findings of a patient with GCC occurring at unusual site of cesarean scar. Surgical treatment and a role of postoperative adjuvant chemotherapy were discussed.

### Correspondence to:

Kittisiam T. 681 Samsen Road, Dusit, Bangkok 10300, Thailand.

**Phone:** +66-81-4413492

**E-mail:** bowgamo@hotmail.com

### Case Report

A 52-year old woman, gravida 4, parity 1, complained of abnormal vaginal bleeding for one month. The bleeding was moderately profuse causing her fatigue. The other associated symptom was breast tenderness. Prior to this complain of abnormal bleeding, her previous menstrual period was regular every 30 days and lasts for 3 to 5 days. She did not have any contraception. The obstetrical history was 2 miscarriages (25 years and 23 years prior) and 1 tubal pregnancy (22 years prior). The last gravid was full term, delivered by cesarean section 9 years ago.

Pertinent findings from physical and pelvic examination were marked pale conjunctivae, vaginal and cervical congestion. The cervical os was open with a 3 cm detached piece brownish friable tissue in her vaginal canal. The uterus was globular, enlarged to 14-week gestational age, soft consistency, and with mild tenderness. Urine pregnancy test was positive. Transvaginal ultrasonography reported a 14.0x7.6x7.0 cm uterus with hyperechogenic content sized 3.0x1.1 cm located at lower part of uterus. Myometrium had diffuse hetero-echogenicity without a definite mass,

**How to cite this article:** Kittisiam T, Thavaramara T, Chavanisakun C, Srijaipracharoen S, Tanjitgamol S. Cesarean Scar Choriocarcinoma: A Case Report and Review of Literature. J Med Assoc Thai 2018;101;Suppl.8: S201-S204.

suggestive of adenomyosis. The laboratory test revealed an elevated serum beta-hCG to 1,448 mIU/ml.

A provisional diagnosis was incomplete abortion and uterine curettage was performed. The uterus involuted to 8-week gestational size after curettage. The operation was noted as uneventful. The pathological report described decidual change of endometrial tissue with fragments of chorionic villi.

A routine post-curettage follow-up examination at 2 weeks demonstrated a 12-week-gestation uterus. Transvaginal ultrasonography revealed uterus sized 12.2 x 7.0 x 7.8 cm with empty uterine cavity. An ill-defined heterogenous echoic hypervascularized lesion sized 2.27x1.85 cm with high doppler signal at lower uterine segment extending into myometrium was observed. Beta-hCG level increased to 4,315 mIU/ml. Provisional diagnosis was a cesarean scar pregnancy with a differential diagnosis of gestational trophoblastic tumor. After a thorough counseling and discussion, she decided to have abdominal hysterectomy.

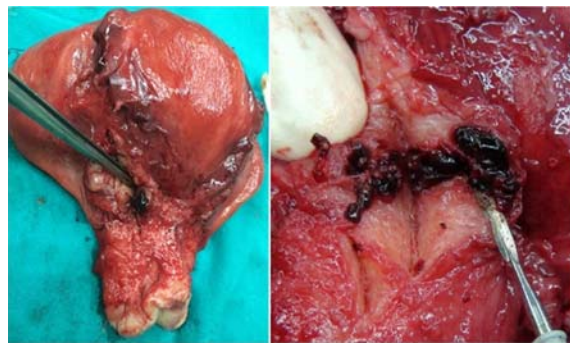
Intraoperative findings reported a 12.0x8.0x6.5 cm intact uterus. A 3 cm hemorrhagic lesion was found at right lateral aspect of lower uterine segment extending from endometrial surface through the serosal surface (Figure 1). Other areas of the uterine cavity, myometrium, and both adnexae were unremarkable.

Histopathologic examination of the lesion described a 1.2 x 0.7 cm tumor. Tumor cells arranged in dyscohesive sheets composing of cytotrophoblast and syncytiotrophoblasts among blood and fibrin background. No chorionic villi were evidenced (Figure 2). Immunohistochemical staining of tumor cells were strongly positive for beta-HCG and Ki-67 (Figure 3). Pathologic diagnosis was choriocarcinoma at cesarean scar. The metastatic survey was negative, and the International Federation of Gynecology and Obstetrics stage I: 3 was assigned.

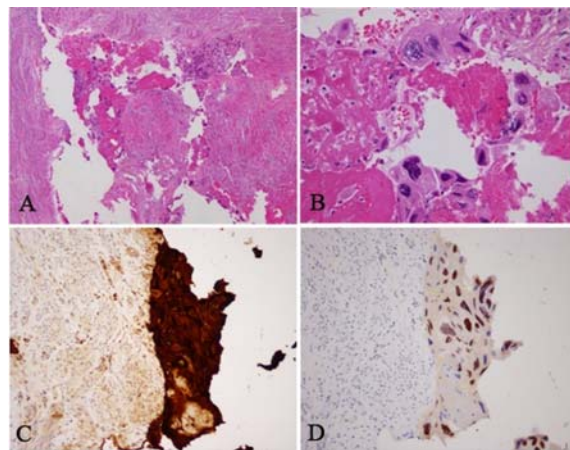
After the operation, her beta-HCG level gradually declined to normal value within 4 weeks. She denied postoperative adjuvant chemotherapy and attached to a surveillance program. She was doing well with normal beta-HCG levels for 25 months after surgery.

## Discussion

The GCC is uncommon and approximately half developed after a hydatidiform mole. The remaining may occur after abortion or even term pregnancy<sup>(14)</sup>. The latency from prior pregnancy to GCC varied from weeks to years<sup>(12)</sup>. From literature review, the shortest duration for developing choriocarcinoma after non



**Figure 1.** Gross examination, hemorrhagic lesion located at right lateral aspect of lower uterine segment. Lesion originated from endometrial surface and extended through serosal surface of uterus.



**Figure 2.** Microscopic examination, H&E stain 10X (A) and 40X(B). The malignant cells composed of cytotrophoblastic and syncytiotrophoblastic cells without chorionic villi were identified. Immunohistochemical staining for hcg (C) and Ki-67(D) index was high in the tumor tissue.

molar pregnancy was 10 weeks. For our patient, the choriocarcinoma developed only 2 weeks after her latest abortion which was exclusively short duration<sup>(10)</sup>.

Several modalities, such as, ultrasonography, MRI and CT scan were used to evaluate pelvic lesions. Among several imaging studies, ultrasonography with or without color Doppler is commonly used as the first line imaging study. The characteristic features of border and peripheral doppler signal pattern were reported to be reliable in a small series of patients in discriminating cesarean scar pregnancy, benign tumor and gestational trophoblastic tumor<sup>(13)</sup>. The hemodynamic indices

including resistance index, vascularization index, flow index, and vascularization-flow index were also studied, nevertheless, with discordant results<sup>(10,14)</sup>. Thus differential between CSP and GTT is difficult unless histopathologic examination confirmed.

The typical gross features of choriocarcinoma are dark-red friable masses with extensive hemorrhage and variable amount of necrosis. Local tumor usually locates in the uterine cavity, and may involve myometrial layer. Rarely, the tumor may arise at sites of ectopic pregnancy.

Histopathologic diagnosis is not mandatory in this rare tumor, but for our circumstance the report of choriocarcinoma absence of chorionic villi and presence of diffusely infiltrative cohesive sheets of trimorphic malignant intermediate trophoblast, cytotrophoblast, rimmed with syncytiotrophoblast confirmed the diagnosis of extremely rare cesarean scar choriocarcinoma<sup>(15)</sup>.

Generally, a diagnosis of choriocarcinoma is by clinical findings. Because the cancer can occur after any events of pregnancy, the diagnosis is always a challenge to a physician. In our patient, a differential diagnosis of exaggerated placental site reaction was also made. The exaggerated placental site reaction, also known as syncytial endometritis, is the normal physiologic variant of pregnancy which can be found in 1.6% of first trimester abortions, showing intermediate trophoblast accompanying by villi<sup>(16)</sup>. The certain diagnosis in our patient could not be made prior to histopathology from the hysterectomy due to several reasons. First, it is rare that the previous non-hydatidiform mole abortion developed to choriocarcinoma in only 2 weeks latency period. Second, although chorionic villi were not demonstrated in the tumor of our patient, we were not certain to make a definite diagnosis from subtle clinic-pathologic findings (small lesion and absence of lymphovascular invasion which is usually seen in choriocarcinoma). Hence, we performed immunohistochemical study and found tumor cells were strongly positive for Ki-67 favoring more of the choriocarcinoma<sup>(17,18)</sup>.

Caesarean scar choriocarcinoma is extremely rare. We performed a systematic search (MEDLINE) of the English medical literature published between 1966 and 2016, using the search terms 'choriocarcinoma' and 'cesarean scar pregnancy'. Only 3 cases reports were identified. The first patient was reported in 2012. She had preoperative diagnosis of cesarean scar pregnancy, and received uterine arterial embolization and arterial injection of 70 mg of methotrexate before

uterine curettage<sup>(6)</sup>. Pathological examination of tissue revealed a diagnosis of choriocarcinoma at cesarean section scar, FIGO stage I: 8. She received multi-agent chemotherapy for 8 cycles until complete remission. The second case report was published in mid-2016<sup>(7)</sup>. She had surgical treatment for uterine perforation at cesarean scar during first trimester pregnancy. Histopathologic finding at the perforating site showed choriocarcinoma. Additional treatment and follow-up data were not reported. The latest report was recently published on December 2016<sup>(10)</sup> revealed choriocarcinoma at cesarean section scar with lung metastasis. The patient underwent hysterectomy and received adjuvant chemotherapy.

Our patient was treated by total abdominal hysterectomy. Because choriocarcinoma is notorious from systemic involvement, systemic chemotherapy was offered as an option to eradicate any microscopic metastasis despite being in stage I without any gross evidence of extrauterine lesion. She declined further treatment, so was closely monitored until 25 months after diagnosis when she was doing well without any evidence of disease.

## Conclusion

Although it has been generally known that GCC usually occurred in months to years after pregnancy, gestational trophoblastic disease cannot be overlook in the case that clinically suspicious and surgical treatment might be effective without adjuvant chemotherapy in some selected case. However, the beta-hCG level must be monitored closely.

## What is already known on this topic?

Gestational choriocarcinoma [GCC] is an uncommon trophoblastic neoplasm. It is commonly confined to the uterus. The extrauterine origins are rare. Diagnosis is usually been made with clinical findings of history of preceding abnormal pregnancy, abnormal uterine bleeding, and rising of beta-hCG without evidence of pregnancy. Pathologic diagnosis is not required in this rare cancer. Chemotherapy is the standard treatment for GCC.

## What this study adds?

GCC can develop after abortion in a very short period of time. The physicians should always keep this rare cancer in their differential diagnoses because the unique diagnostic means and treatment than other gynecologic cancers. Although chemotherapy is the standard treatment, the physician may consider a

conservative management with close surveillance particularly in the patient who had localized disease which had been completely resected.

### Acknowledgements

The authors would like to thank the patient. The research was supported by the Faculty of Medicine Vajira Hospital Research Facilitation Unit.

### Potential conflicts of interest

The authors declare no conflict of interests.

### References

1. Buckley JD. The epidemiology of molar pregnancy and choriocarcinoma. *Clin Obstet Gynecol* 1984;27:153-9.
2. Sebire NJ, Lindsay I, Fisher RA, Seckl MJ. Intraplental choriocarcinoma: experience from a tertiary referral center and relationship with infantile choriocarcinoma. *Fetal Pediatr Pathol* 2005;24:21-9.
3. Joneborg U, Papadogiannakis N, Lindell G, Marions L. Choriocarcinoma following ovarian hydatidiform mole: a case report. *J Reprod Med* 2011;56:511-4.
4. Mitrovic SL, Arsenijevic PS, Kljakic D, Djuric JM, Milosavljevic MZ, Protrka ZM, et al. Gestational choriocarcinoma of the cervix. *Arch Iran Med* 2014;17:783-5.
5. Wong T, Fung EP, Yung AW. Primary gestational choriocarcinoma of the vagina: magnetic resonance imaging findings. *Hong Kong Med J* 2016;22:181-3.
6. Qian ZD, Zhu XM. Cesarean scar choriocarcinoma: a case report and review of the literature. *Eur J Med Res* 2014;19:25.
7. Sherer DM, Dalloul M, Cho Y, Mylvaganam SR, Adeyemo I, Zinn HL, et al. Spontaneous first-trimester perforation of the uterus following Cesarean scar pregnancy choriocarcinoma. *Ultrasound Obstet Gynecol* 2016;47:519-21.
8. Vimercati A, de Gennaro AC, Resta L, Cormio G, Cicinelli E. Sonographic and power doppler evaluation of an invasive mole located in a cesarean scar pregnancy. *J Ultrasound Med* 2016;35:1608-12.
9. Bekci T, Ozturk M, Danaci M. Cesarean scar choriocarcinoma: Ultrasound and magnetic resonance imaging findings. *J Belg Soc Radiol* 2016;100:46.
10. Sumangala S, Pillai MM, Chellamma N, Raji L. Choriocarcinoma following scar pregnancy: a case report. *Int J Reprod Contracept Obstet Gynecol* 2016;5:4519-21.
11. Bagshawe KD, Golding PR, Orr AH. Choriocarcinoma after hydatidiform mole. Studies related to effectiveness of follow-up practice after hydatidiform mole. *Br Med J* 1969;3:733-7.
12. Ober WB, Edgcomb JH, Price EB Jr. The pathology of choriocarcinoma. *Ann N Y Acad Sci* 1971;172:299-426.
13. Qin J, Ying W, Cheng X, Wu X, Lu B, Liang Y, et al. A well-circumscribed border with peripheral Doppler signal in sonographic image distinguishes epithelioid trophoblastic tumor from other gestational trophoblastic neoplasms. *PLoS One* 2014;9:e112618.
14. Wang W, Tian X, Zhang T, Wang Y, Han Z, An R. Characteristics of three-dimensional power doppler in gestational trophoblastic disease. *Dis Markers* 2015;2015:917687.
15. Kurman RJ, Carcangiu ML, Herrington CS, Young RH. WHO classification of tumours of female reproductive organs. Lyon: International Agency for Research on Cancer; 2014.
16. Yeasmin S, Nakayama K, Katagiri A, Ishikawa M, Iida K, Nakayama N, et al. Exaggerated placental site mimicking placental site trophoblastic tumor: case report and literature review. *Eur J Gynaecol Oncol* 2010;31:586-9.
17. Ozdemir O, Sari ME, Selimova V, Ilgin BU, Atalay CR. A case report of complete mole with co-existent exaggerated placental site reaction and review of the literature. *Niger Med J* 2014;55:180-2.
18. Shih IM, Kurman RJ. Ki-67 labeling index in the differential diagnosis of exaggerated placental site, placental site trophoblastic tumor, and choriocarcinoma: a double immunohistochemical staining technique using Ki-67 and Mel-CAM antibodies. *Hum Pathol* 1998;29:27-33.