

# Abacavir Hypersensitivity Reaction: The First Case Report in Thailand and Literature Review

Chutinart Chinudomporn MD<sup>1</sup>, Ornicha Thititagul MD<sup>1</sup>, Woraphot Tantisiriwat MD, MPH<sup>2</sup>

<sup>1</sup> Department of Medicine, HRH Princess Maha Chakri Sirindhorn Medical Center, Faculty of Medicine, Srinakharinwirot University, Nakhon Nayok, Thailand

<sup>2</sup> Department of Preventive Medicine, HRH Princess Maha Chakri Sirindhorn Medical Center, Faculty of Medicine, Srinakharinwirot University, Nakhon Nayok, Thailand

Abacavir-related hypersensitivity reaction (ABC-HSR) is a life-threatening condition. The incidence is low since it could have been prevented by screening with blood test for HLA-B\*5701, which is strongly associated with this reaction. However, the affordability for the HLA-B\*5701 screening test is still a challenging issue in many developing countries. Thai National Health Security Office (NHSO) recommends either using HLA-B\*5701 as a screening test or monitoring clinical presentation for ABC-HSR after using it. Therefore, the clinical presentation of ABC-HSR should be acknowledged for the diagnosis of this condition and death prevention. This was the first reported case and literature reviewed of ABC-HSR associated with the presence of the HLA-B\*5701 allele in Thailand.

**Keywords:** Abacavir, Hypersensitivity reaction, HLA-B\*5701, Clinical presentation, Thailand

Received 16 June 2020 | Revised 20 August 2020 | Accepted 21 August 2020

**J Med Assoc Thai 2021;104(1):159-63**

**Website:** <http://www.jmatonline.com>

## Case Report

The authors reported a case of a 53-year-old Thai woman with medical history of human immunodeficiency virus (HIV) infection and acquired immune deficiency syndrome (AIDS). Her symptoms were blurred vision that started in February 2009 and was later diagnosed with cytomegalovirus (CMV) retinitis. HIV result was positive and initial CD4 cell count was 3 cells/mm<sup>3</sup>.

Antiretroviral therapy (ART) was initially started with nevirapine, lamivudine, and stavudine combined drug (GPO-vir S-30) before changing to efavirenz, lamivudine, and stavudine after she developed generalized erythematous maculopapular rash. HIV genotype resistance test was sent after starting ART for six months, since the HIV viral load (VL) was detectable at 20,500 copies/mm<sup>3</sup>. The result reviewed

mutations included K103N, M184V, and M230L. ART regimen was then switched to zidovudine (100 mg) two capsules every 12 hours, tenofovir (300 mg) one tablet daily and lopinavir/ritonavir (200/50 mg) two tablets every 12 hours. The HIV VL around six months later demonstrated good response, dropping to below 40 copies/mL accompanied with rising of CD4 cell count level from 233 (8.7%) cells/mm<sup>3</sup> to 356 (10.3%) cells/mm<sup>3</sup>. This ART regimen was then continued for almost 10 years. Her CD4 cell count in February 2019 was 967 cells/mm<sup>3</sup> and HIV VL was not detected. Creatinine (Cr) had been insidiously rising from 0.9 mg/dL to 1.27 mg/dL during follow-ups. After excluding all possible causes, tenofovir induced nephrotoxicity was suspected. Abacavir (300 mg) one tablet every 12 hours was prescribed as a replacement for tenofovir in May 2019.

Nine days after abacavir was introduced, high grade fever developed. The fever was usually worse at night. She also complained of sore throat, loss of appetite, rash, diffuse myalgia, fatigue, nausea, and vomiting two to three times per day. Pruritic faintly red raised rash appeared on her back that developed at the same time as the fever before disappearance at day three. There was no complaint of cough, dyspnea, or arthralgia. On the fifth day of fever, she presented to the authors' internal medicine outpatient department. Her initial temperature was 37 degrees Celsius. A group of anterior left cervical

### Correspondence to:

Tantisiriwat W.

Department of Preventive Medicine, Faculty of Medicine, Srinakharinwirot University, 62 Moo 7, Ongkharak, Nakhon Nayok 26120, Thailand.

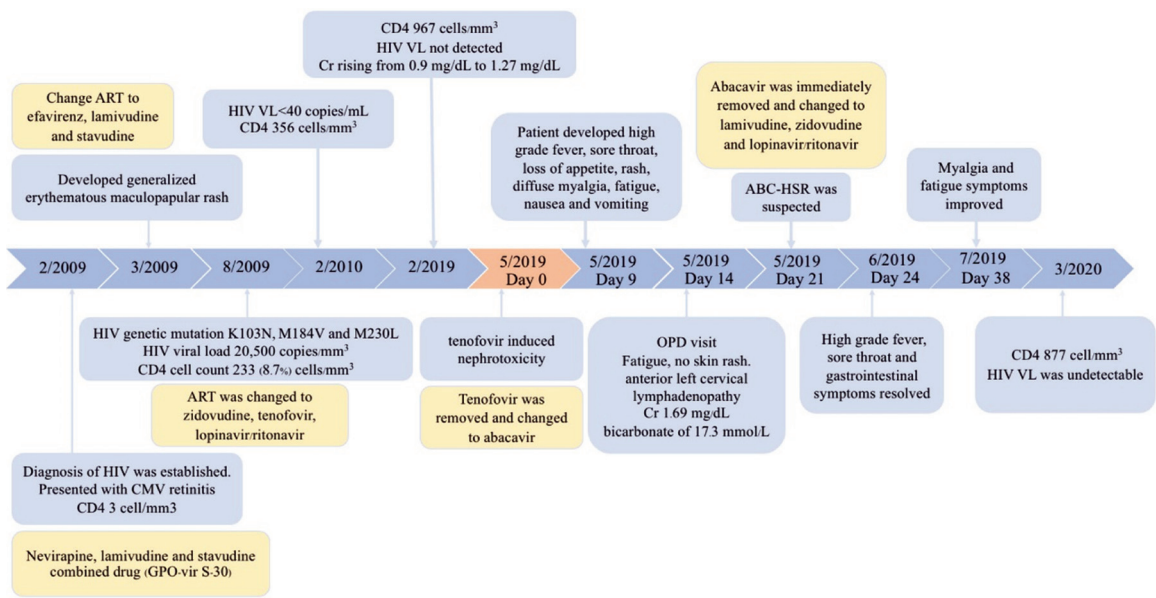
**Phone:** +66-37-395258 ext. 107270

**Email:** photmd@gmail.com

### How to cite this article:

Chinudomporn C, Thititagul O, Tantisiriwat W. Abacavir Hypersensitivity Reaction: The First Case Report in Thailand and Literature Review. *J Med Assoc Thai* 2021;104:159-63.

[doi.org/10.35755/jmedassocthai.2021.01.11569](https://doi.org/10.35755/jmedassocthai.2021.01.11569)



**Figure 1.** Timeline of clinical presentations, ART regimens and significant laboratory results in this case.

lymph nodes was palpable. There was no skin lesion, no conjunctivitis, no pharyngitis, and no hepatosplenomegaly. Blood urea nitrogen (BUN) and Cr were elevated to 22.6 mg/dL and 1.69 mg/dL. Electrolytes were abnormal including sodium of 132.9 mmol/L and bicarbonate of 17.3 mmol/L. Two days later after intravenous and oral hydration, Cr and electrolyte abnormalities were improved. She still complained of fatigue, diffused myalgia, vomiting, and night-time fever. Infectious diseases consultation was done for further management and abacavir-related hypersensitivity reaction (ABC-HSR) was suspected in this case. Abacavir was immediately removed from the ART treatment. Night-time fever and gastrointestinal symptoms resolved in three days after stopping abacavir. The HLA-B\*5701 test was done later and turned out to be positive. ART regimen was then switched to lamivudine (150 mg) one tablet every 12 hours, zidovudine (100 mg) two capsules every 12 hours and lopinavir/ritonavir (200/50 mg) two tablets every 12 hours. Her clinical symptoms resolved and returned to normal range within the next few weeks. On last follow-up in March 2020, she was well. Her CD4 cell count was 877 (35.36%) cells/mm<sup>3</sup> and HIV VL was undetectable. Figure 1 shows the timeline of clinical presentations, ART regimens, and significant laboratory results in the present case. The patient was informed and consented to have her medical record reviewed and data published.

## Discussion

A 53-year-old Thai woman with medical history of HIV infection developed high-grade night-time fever, sore throat, loss of appetite, rash, diffuse myalgia, fatigue, nausea, and vomiting two to three times per day after abacavir had been introduced for nine days. On physical examination, anterior left cervical lymph node was palpable. Laboratory examinations showed acute renal injury with mild metabolic acidosis. ABC-HSR was suspected and abacavir was immediately discontinued. After discontinuing abacavir, her clinical symptoms gradually improved and fully recovered after a few weeks.

Early diagnosis of ABC-HSR needs awareness from clinicians who prescribe abacavir including ART to patients. The risk of developing this adverse event was not related to CD4 cell count, HIV VL, protease inhibitors, non-nucleoside reverse transcriptase inhibitors use, or dose of abacavir<sup>(1,2)</sup>. There was no correlation between interruptions in abacavir dosing and increasing risk of ABC-HSR<sup>(1,2)</sup>. More than 93% of ABC-HSR occurred during the first six weeks of treatment and median time to develop the reaction was eight days but could be observed as early as on the first day of treatment. Delayed onset, more than 12 weeks, was reported in less than 6%<sup>(3)</sup>.

ABC-HSR symptoms usually present unspecific systemic symptoms and appear to be worse after each dose of abacavir<sup>(1)</sup>. The most common presentations

**Table 1.** All ABC-HSR clinical presentations had been reported based on frequency<sup>(3,4,9-11)</sup>

Common presentation of ABC-HSR	Less common reported signs and symptoms
<ul style="list-style-type: none"> <li>• Fever (78%)</li> <li>• Rash (66%)</li> <li>• Malaise/fatigue (46%)</li> <li>• Nausea/vomiting (46%)</li> </ul>	<ul style="list-style-type: none"> <li>• Myalgia</li> <li>• Arthralgia</li> <li>• Headache</li> <li>• Diarrhea</li> <li>• Pruritus</li> <li>• Abdominal pain</li> <li>• Respiratory symptoms (dyspnea, cough, or pharyngitis)</li> <li>• Liver function test abnormality</li> <li>• Renal failure</li> </ul>
Rare presentation of ABC-HSR	
<ul style="list-style-type: none"> <li>• Disseminated intravascular coagulation</li> <li>• Thrombotic thrombocytopenic purpura</li> </ul>	
ABC-HSR=abacavir-related hypersensitivity reaction	

are fever and rash, which should be kept in mind that they could disappear and might not be present on the day of visit as presented in the present case. Ninety-six percent of patients had fever and rash or a combination of both<sup>(3)</sup>, consistent with a retrospective medical review of 1,803 cases with hypersensitivity reactions during abacavir treatment<sup>(3)</sup>. The median time of the onset was 11 days. The most frequently reported symptoms associated with initial presentation of ABC-HSR were fever (78%), rash (66%), malaise or fatigue (46%), and nausea or vomiting (46%). The other less commonly reported signs and symptoms included myalgia or arthralgia, headache, diarrhea, pruritus, and respiratory symptoms such as dyspnea, cough, or pharyngitis<sup>(4)</sup>. Discontinuation of abacavir usually improves symptoms within 48 to 72 hours<sup>(5)</sup>.

The symptoms of ABC-HSR could be worsened and lead to fulminant hepatic failure in a HIV and HCV co-infected patient<sup>(6)</sup>. Re-challenging abacavir is not recommended if ABC-HSR is suspected<sup>(7)</sup>. Anaphylactic or immediate type of hypersensitivity reaction developed in 20% of patients who were re-challenged with abacavir after diagnosed with ABC-HSR<sup>(8)</sup>. Rare presentations of ABC-HSR included disseminated intravascular coagulation<sup>(9)</sup> and thrombotic thrombocytopenic purpura<sup>(4)</sup>. ABC-HSR should be diagnosed by exclusion since there could be many others causes for these symptoms, especially when abacavir was still being used.

There were few reports on ABC-HSR cases from Asia<sup>(10,11)</sup>. The first case presented with maculopapular rash, headache, and signs of hepatic damage suggestive of hypersensitivity reaction around two weeks after abacavir therapy. After discontinuation of abacavir, the rash disappeared within two to three days and liver function tests returned to normal values within five days<sup>(10)</sup>. Another was a 39-year-old HIV-infected Korean male who was admitted with five-day history

of fever, generalized rash, abdominal pain, watery diarrhea with rapid progression of hepatitis, and renal failure. He was found to have HLA-B\*3701 and B\*5701 alleles and was diagnosed with ABC-HSR. Three weeks after stopping abacavir, he exhibited no further symptoms, and all laboratory findings were normalized<sup>(11)</sup>. All ABC-HSR clinical presentations that were previously reported are included in Table 1.

According to many retrospective and prospective studies, strong association between HLA-B\*5701 allele and ABC-HSR have been seen<sup>(12,13)</sup>. The incidence of ABC-HSR was significantly lowered over the past decade since HLA-B\*5701 testing has been applied to clinical practice<sup>(12)</sup>. From one of the most significant studies about ABC-HSR, PREDICT-1, revealed the sensitivity of HLA-B\*5701 testing of 45.5% and specificity of 97.6%. The incidence of clinically diagnosed HSR in screened patients was 3.4% and 7.8% in unscreened patients<sup>(13)</sup>. Screening eliminated immunologically confirmed ABC-HSR, which was 0% in the prospective-screening group compared to 2.7% in the control group, which was statistically significant<sup>(13)</sup>. This resulted in a negative predictive value of 100% and a positive predictive value of 47.9% for the HLA-B\*5701 screening test<sup>(13)</sup>.

HLA-B\*5701 screening test is a helpful method to reduce the incidence of ABC-HSR<sup>(12,13)</sup>. However, there were also some incidence reports of ABC-HSR with negative HLA-B\*5701 tests<sup>(14)</sup>. The prevalence of HLA-B\*5701 was studied in HIV-infected children population in Thailand. It showed a relatively low prevalence, at the rate of 3.4%, compared to Caucasian population, which was significantly higher at 9% to 10%<sup>(15)</sup>.

Prior studies suggested that HLA-B\*5701 screening was cost-effective for populations with higher HLA-B\*5701 prevalence<sup>(16)</sup>. However, a study from Park et al showed that the Korean population

had lower prevalence of HLA-B\*5701, at the rate of 4%, which is about the same prevalence as of the Thai population. Therefore, it might not be cost-effective. The present study suggested that clinical observation could replace the genetic testing, especially in the area where resources were limited. However, the present study still had some limitation due to the small population<sup>(17)</sup>. Alternative method for screening test such as cutaneous patch test (PT), a simple and inexpensive screening test, had shown result in characterizing patients with true ABC-HSR<sup>(18)</sup> and could be an answer for the developing countries to decrease the ABC-HSR incidence in the future.

The current Thai National Health Security Office (NHSO) HIV treatment guideline recommended either using HLA-B\*5701 as a screening test before using abacavir or monitoring clinical presentation for ABC-HSR<sup>(19)</sup>. The clinical presentation of ABC-HSR should be well-aware for the Thai clinician since the genetic testing might not be available in some setting and unaffordable for some patients who were planning to use abacavir.

To date, there have been few published information describing ABC-HSR in Thai HIV population, leaving many questions about both exact prevalence of ABC-HSR and prevalence of HLA-B\*5701 positive cases in a large population<sup>(15,20)</sup>. Clinical observation is a significant choice since the screening test of HLA-B\*5701 might not be cost-effective in Thai population. Early clinical detection of ABC-HSR was important if screening for HLA-B\*5701 could not be done before using abacavir. The authors suggest further study for cost effectiveness of HLA-B\*5701 screening for ABC-HSR in Thailand to improve the knowledge into proper, personalized, and safe medicine.

## Conclusion

ABC-HSR is a life-threatening condition. Early clinical detection of ABC-HSR is important if screening for HLA-B\*5701 cannot be done before using abacavir. This should be of concern to clinicians who prescribe abacavir including ART to patients. When ABC-HSR is diagnosed, abacavir should be immediately removed from the ART treatment.

## What is already known on this topic?

ABC-HSR is a life-threatening condition. HLA-B\*5701 screening test is a helpful method to reduce the incidence of ABC-HSR. When ABC-HSR is diagnosed, abacavir should be immediately removed from ART treatment.

## What this study adds?

Early clinical detection of ABC-HSR is important if screening for HLA-B\*5701 cannot be done before using abacavir. The most common presentations of ABC-HSR are fever and rash, which should be kept in mind as they could disappear and might not be present on the day of initial visit. Prompt discontinuation of abacavir in clinical suspected cases and later confirmation with HLA-B\*5701 test is crucial.

## Acknowledgement

The authors would like to thank Ritt Chongsiriwatana, MD for reviewing and correcting the grammar for this paper.

## Conflicts of interest

The authors declare no conflict of interest.

## References

1. Cutrell AG, Hernandez JE, Fleming JW, Edwards MT, Moore MA, Brothers CH, et al. Updated clinical risk factor analysis of suspected hypersensitivity reactions to abacavir. *Ann Pharmacother* 2004;38:2171-2.
2. Loeliger AE, Steel H, McGuirk S, Powell WS, Hetherington SV. The abacavir hypersensitivity reaction and interruptions in therapy. *AIDS* 2001;15:1325-6.
3. Saag M, Balu R, Phillips E, Brachman P, Martorell C, Burman W, et al. High sensitivity of human leukocyte antigen-b\*5701 as a marker for immunologically confirmed abacavir hypersensitivity in white and black patients. *Clin Infect Dis* 2008;46:1111-8.
4. Olszewski AJ, Shapiro JM. Thrombotic thrombocytopenic purpura associated with abacavir in a patient with HIV infection. *J Intensive Care Med* 2003;18:156-9.
5. Hetherington S, McGuirk S, Powell G, Cutrell A, Naderer O, Spreen B, et al. Hypersensitivity reactions during therapy with the nucleoside reverse transcriptase inhibitor abacavir. *Clin Ther* 2001;23:1603-14.
6. Haas C, Ziccardi MR, Borgman J. Abacavir-induced fulminant hepatic failure in a HIV/HCV co-infected patient. *BMJ Case Rep* 2015;2015.
7. Escaut L, Liotier JY, Albengres E, Cheminot N, Vittecoq D. Abacavir rechallenge has to be avoided in case of hypersensitivity reaction. *AIDS* 1999;13:1419-20.
8. Frissen PH, de Vries J, Weigel HM, Brinkman K. Severe anaphylactic shock after rechallenge with abacavir without preceding hypersensitivity. *AIDS* 2001;15:289.
9. Dargère S, Verdon R, Bouhier K, Bazin C. Disseminated intravascular coagulation as a manifestation of abacavir hypersensitivity reaction. *AIDS* 2002;16:1696-7.

10. Janardhanan M, Amberkar VM, Vidyasagar S, Kumari KM, Holla SN. Hypersensitivity reaction associated with abacavir therapy in an Indian HIV patient - A case report. *J Clin Diagn Res* 2014;8:HD01-2.
11. Yoon JH, Kim M, Jin SJ, Kim SK, Lee SH, Cheon J, et al. The First Case of Abacavir Hypersensitivity Associated with the HLA-B\* 57: 01-Positive Allele in Korea. *Infect Chemother* 2012;44:399-402.
12. Rauch A, Nolan D, Martin A, McKinnon E, Almeida C, Mallal S. Prospective genetic screening decreases the incidence of abacavir hypersensitivity reactions in the Western Australian HIV cohort study. *Clin Infect Dis* 2006;43:99-102.
13. Mallal S, Phillips E, Carosi G, Molina JM, Workman C, Tomazic J, et al. HLA-B\*5701 screening for hypersensitivity to abacavir. *N Engl J Med* 2008;358:568-79.
14. Bonta PI, Vermeulen JN, Speelman P, Prins JM. Severe abacavir hypersensitivity reaction in a patient tested HLA-B\*5701 negative. *AIDS* 2008;22:1522-3.
15. Puthanakit T, Bunupuradah T, Kosalaraksa P, Vibol U, Hansudewechakul R, Ubolyam S, et al. Prevalence of human leukocyte antigen-B\*5701 among HIV-infected children in Thailand and Cambodia: implications for abacavir use. *Pediatr Infect Dis J* 2013;32:252-3.
16. Hughes DA, Vilar FJ, Ward CC, Alfirevic A, Park BK, Pirmohamed M. Cost-effectiveness analysis of HLA B\*5701 genotyping in preventing abacavir hypersensitivity. *Pharmacogenetics* 2004;14:335-42.
17. Park WB, Choe PG, Song KH, Lee S, Jang HC, Jeon JH, et al. Should HLA-B\*5701 screening be performed in every ethnic group before starting abacavir? *Clin Infect Dis* 2009;48:365-7.
18. Phillips EJ, Sullivan JR, Knowles SR, Shear NH. Utility of patch testing in patients with hypersensitivity syndromes associated with abacavir. *AIDS* 2002;16:2223-5.
19. Manosuthi W, Ongwandee S, Bhakeecheep S, Leechawengwongs M, Ruxrungtham K, Phanuphak P, et al. Guidelines for antiretroviral therapy in HIV-1 infected adults and adolescents 2014, Thailand. *AIDS Res Ther* 2015;12:12.
20. Sukasem C. Pharmacogenetic markers to predict drug-induced allergic reactions. *Thai Pharm Health Sci J* 2009;4:532-8.