

Marsupialization for Simple Fistula in Ano: A Randomized Controlled Trial

Chucheep Sahakitrungruang MD, MSc*, Jirawat Pattana-arun MD*,
Supakij Khomvilai MD*, Kasaya Tantiphlachiva MD*,
Puttarat Atittharnsakul MD*, Arun Rojanasakul MD*

* Colorectal Division, Department of Surgery, Faculty of Medicine, Chulalongkorn University, Bangkok, Thailand

Background: Marsupialization of anal fistulotomy results in less raw-surface wound and may improve postoperative outcomes. The present study was designed to test the benefit of marsupialization for simple fistula in ano.

Material and Method: This was a randomized controlled study conducted at King Chulalongkorn Memorial Hospital, Bangkok, Thailand. Fifty patients with simple uncomplicated fistula in ano were allocated into either fistulotomy group or fistulotomy with marsupialization group. Patients with complex fistula in ano, prior incontinence, immuno-compromised status and bleeding tendency were excluded from the present study. The postoperative pain score, the pain score after the first defecation, total amount of the analgesic usage and complications were evaluated. Recurrence was also assessed.

Results: There was no difference in the postoperative pain score between the treatment groups. However, there was a significant difference ($p = 0.017$) in the number of patients who needed pethidine injection (4 patients of the fistulotomy with marsupialization group versus 13 patients of the fistulotomy group). There was no statistical significant difference in the pain score after the first defecation and the amount of paracetamol usage in seven days. Five complications were found only in the fistulotomy group but the significant level was marginal ($p = 0.0501$). There was no recurrence of the fistula and none of the patients developed anal incontinence after the surgery.

Conclusion: Marsupialization for anal fistulotomy is safe. This technique helps to improve the postoperative outcomes.

Keywords: Fistula in ano, Fistulotomy, Marsupialization, Postoperative pain, Outcome

J Med Assoc Thai 2011; 94 (6): 699-703

Full text. e-Journal: <http://www.mat.or.th/journal>

Fistulotomy has long been accepted as the gold standard for simple fistula in ano⁽¹⁾. Despite low recurrent rate, fistulotomy leaves a raw unepithelialized wound, which may require hospitalization for irrigation and dressing. Substantial risk of bleeding and recurrent sepsis has also been reported^(2,3). Marsupialization of the fistulotomy wound has been introduced and used as an optional treatment for fistula in ano⁽⁴⁾.

This technique results in less raw surface of the fistulotomy wound thereby resulting in less postoperative blood loss and faster wound healing, which has been reported elsewhere^(5,6). Despite the benefit of marsupialization, the technique involves suturing the sensitive perianal skin to the opened fistula tract, which may affect the immediate outcomes

of the surgery *i.e.* postoperative pain and immediate complications. The aim of the present study was to compare the outcomes of fistulotomy with marsupialization and fistulotomy alone for simple fistula in ano.

Material and Method

This was a randomized controlled trial conducted at King Chulalongkorn Memorial Hospital between November 2004 and July 2005. There were 50 patients with simple uncomplicated fistula in ano (fistula tract depth not beyond the subcutaneous external sphincter *i.e.* external sphincter involvement less than 5 millimeters in thickness) enrolled and allocated into either treatment arm by drawing sealed envelopes. Individuals with complex fistula in ano, recurrent fistula, prior incontinence, immuno-compromised status and bleeding tendency were excluded from the present study. The present study was approved by the ethics committee of Chulalongkorn University. Informed consent was obtained.

Correspondence to:

Sahakitrungruang C, Colorectal Division, Department of Surgery, Faculty of Medicine, Chulalongkorn University, Bangkok 10330, Thailand.

Phone: 0-2256-4400, Fax: 0-2256-4194

E-mail: chucheep@hotmail.com

Fistulotomy was performed under spinal anesthesia in the prone position. The fistula tract was palpated and probed, and the tract was laid open. The granulation tissue was curetted out. The fistula tract length was measured. In patients randomized to fistulotomy with marsupialization, the skin edge was sutured to the side of the fistula tract using Vicryl Rapide 4-0 in a continuous fashion. In the postoperative care, patients in both groups received pethidine 50 milligrams intramuscularly and/or paracetamol 500 milligrams orally as needed. Bulk forming agent was also prescribed. Patients were instructed for self-wound cleansing using tap water in the hospital and at home. Self-reported forms of pain evaluation were given and collected at the first outpatient visit in two weeks. Subsequent visits were at 1-month intervals. The fecal continence using clinical continence grading⁽⁷⁾ was assessed during each visit.

Data accrued included patient demographics, the postoperative pain score (day 1, 3, 5, 7 and 14), the pain score after the first defecation, total amount of the analgesic usage, complications, the continent status, and the recurrence.

Data were expressed as mean \pm standard deviation (SD) or as median and range. Statistical significance was tested using the Student's t-test, the Mann-Whitney U test, the Fisher exact test and the Pearson Chi-square test when appropriate. Statistical significance was set at $p < 0.05$.

Results

The patient demographics and the fistula type were not different (Table 1). There was no difference in the postoperative pain score between the two treatment groups (Fig. 1). However, there was

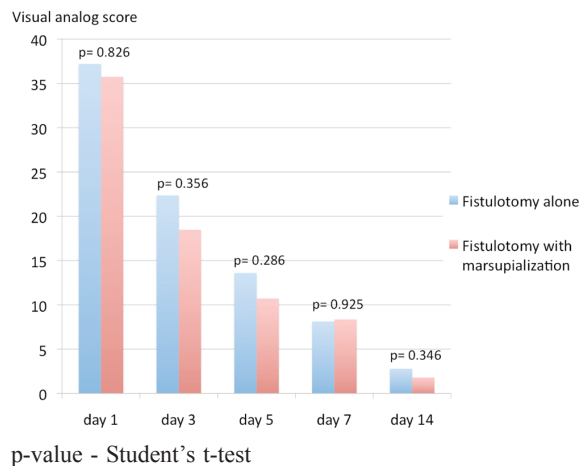


Fig. 1 Postoperative pain score

a significant difference ($p = 0.017$) in the number of patients needing pethidine injection (4 patients of fistulotomy with the marsupialization group and 13 of the fistulotomy group). There was no statistical significant difference of the pain score after the first defecation and the amount of paracetamol usage in seven days. All patients had good recovery except five patients in the fistulotomy alone group (2 urinary retention, 1 fever, and 2 wound bleeding). However, the significant level was marginal ($p = 0.0501$). Wound condition was evaluated at 2-week visit. Although wound inflammation was found in six patients following fistulotomy compared to three patients with marsupialization, there was no statistical difference. There was no recurrence of the fistula and none of the patients developed anal incontinence after the surgery (Table 2).

Table 1. Patient demographics

Parameter	Fistulotomy alone (n = 25)	Fistulotomy with marsupialization (n = 25)
Age (years)*	43.20 (13.67)	40.60 (10.75)
Sex (male : female)	23:2	20:5
Underlying disease	4	3
Diabetes	3	1
Hypertension	1	2
Fistula type (intersphincteric : low transphincteric)	9:16	8:17
Fistula tract length (cm)*	2.21 (0.81)	2.56 (0.87)

* Mean (SD)

Table 2. Results of the treatment

Parameter	Fistulotomy alone (n = 25)	Fistulotomy with marsupialization (n = 25)	p-value
Visual analog pain score on the first defecation*	37.44 (22.15)	36.80 (23.67)	0.922 ^a
Number of patients requiring pethidine injection	13	4	0.017 ^b
Time to first pethidine injection (hours)*	7.80 (4.36)	6.88 (0.56)	0.690 ^a
Number of paracetamol usage in 7 days (tablets)**	6 (0- 24)	4 (0- 18)	0.694 ^c
Wound condition at 2 weeks (not inflamed : inflamed)	19:6	22:3	0.463 ^d
Complications	5	0	0.0501 ^d
Urinary retention	2	0	
Fever	1	0	
Bleeding	2	0	
Incontinence	0	0	
Recurrence of the fistula	0	0	

* Mean (SD), ** Median (range)

^a Student's t-test, ^b Pearson Chi-square test (continuity correction), ^c Mann-Whitney U-test, ^d Fisher exact test

Discussion

Postoperative pain has been counted to be one of the major detrimental outcomes of surgery⁽⁸⁾. Thus, perioperative care has been improved such as the anesthetic technique^(9,10), the postoperative care, and the modification of the surgical technique⁽³⁾.

Fistulotomy leaves the sensitive perianal wound opened, which may cause undesired outcomes of pain and complications such as urinary retention and bleeding. Marsupialization of the laid open fistula has been introduced with the benefit of shortening the healing time and improving continence by minimizing anal deformity^(4,6).

Pescatori et al reported that marsupialization of the fistulotomy wound nearly halved the size of the wound intra-operatively which subsequently decreased in size significantly in four weeks, however, difference in the postoperative pain could not be demonstrated⁽⁵⁾.

The pattern of pain characteristic in the present study is typical for acute pain that is maximized in the early period and dramatically reduced after time goes by⁽¹¹⁾. The pain score immediately after the operation (day 0) may reflect the highest pain score for each individual. However, it was not included in the present study because it may be interfered by the effect of rescue treatment with pethidine injection.

Despite a lack of significant difference of the pain score between two treatment groups, there was a significant difference ($p = 0.017$) in the number of patients needing pethidine injection (4 patients of

fistulotomy with the marsupialization group and 13 of the fistulotomy group). This result can be assumed that fistulotomy with marsupialization improves the acute postoperative pain compare to fistulotomy alone.

Risk of postoperative suppuration and bleeding has been significantly reduced with the marsupialization technique by the matter of fact that the deep, unepithelialized wound has become smaller^(5,6). The authors found that none of the marsupialization but five in the fistulotomy alone developed postoperative complications. However, the significant level was marginal ($p = 0.0501$). The number of patients experiencing wound inflammation seems to be less with marsupialization, but there was no statistical difference. To test these aspects, more patients are warranted.

None of the patients in the present study reported fecal incontinence nor recurrence, which is compatible with the previous report elsewhere⁽⁶⁾.

Conclusion

Marsupialization for anal fistulotomy is safe. This technique helps to improve the postoperative outcomes.

Acknowledgement

The present study was supported by the Ratchadapisek Sompotch fund.

Potential conflicts of interest

None.

References

1. Rizzo JA, Naig AL, Johnson EK. Anorectal abscess and fistula-in-ano: evidence-based management. *Surg Clin North Am* 2010; 90: 45-68.
2. Malik AI, Nelson RL, Tou S. Incision and drainage of perianal abscess with or without treatment of anal fistula. *Cochrane Database Syst Rev* 2010; (7): CD006827.
3. Malik AI, Nelson RL. Surgical management of anal fistulae: a systematic review. *Colorectal Dis* 2008; 10: 420-30.
4. Garcia-Aguilar J, Belmonte C, Wong WD, Goldberg SM, Madoff RD. Anal fistula surgery. Factors associated with recurrence and incontinence. *Dis Colon Rectum* 1996; 39: 723-9.
5. Pescatori M, Ayabaca SM, Cafaro D, Iannello A, Magrini S. Marsupialization of fistulotomy and fistulectomy wounds improves healing and decreases bleeding: a randomized controlled trial. *Colorectal Dis* 2006; 8: 11-4.
6. Ho YH, Tan M, Leong AF, Seow-Choen F. Marsupialization of fistulotomy wounds improves healing: a randomized controlled trial. *Br J Surg* 1998; 85: 105-7.
7. Browning GG, Parks AG. Postanal repair for neuropathic faecal incontinence: correlation of clinical result and anal canal pressures. *Br J Surg* 1983; 70: 101-4.
8. Sommer M, de Rijke JM, van Kleef M, Kessels AG, Peters ML, Geurts JW, et al. Predictors of acute postoperative pain after elective surgery. *Clin J Pain* 2010; 26: 87-94.
9. Kausalya R, Jacob R. Efficacy of low-dose epidural anaesthesia in surgery of the anal canal—a randomised controlled trial. *Anaesth Intensive Care* 1994; 22: 161-4.
10. Werawatganon T, Charuluxanun S. Patient controlled intravenous opioid analgesia versus continuous epidural analgesia for pain after intra-abdominal surgery. *Cochrane Database Syst Rev* 2005; (1): CD004088.
11. Apfelbaum JL, Chen C, Mehta SS, Gan TJ. Postoperative pain experience: results from a national survey suggest postoperative pain continues to be undermanaged. *Anesth Analg* 2003; 97: 534-40.

การศึกษาเปรียบเทียบผลการรักษา simple fistula in ano ระหว่างวิธี fistulotomy with marsupialization และวิธี fistulotomy alone

ชูชีพ สหกิจรุ่งเรือง, จิรวัดณ์ พัฒนะอรุณ, สุภกิจ ชมวิสัย, กษยา ตันติผลาชีวะ, พุทธรัตน์ อธิษฐานสกุล, อรุณ โรจนสกุล

วัตถุประสงค์: เพื่อเปรียบเทียบวิธีการผ่าตัด fistulotomy และ fistulotomy with marsupialization ในการรักษา simple fistula in ano โดยดูจากความเจ็บปวดหลังผ่าตัด ความเจ็บปวดขณะถ่ายอุจจาระครั้งแรก จำนวนยาแก้ปวดที่ใช้ ภาวะแทรกซ้อน และการหายของ fistula

รูปแบบการศึกษา: การศึกษาเชิงทดลองทางคลินิกโดยการสุ่ม

สถานที่ทำการวิจัย: โรงพยาบาลจุฬาลงกรณ์

วัสดุและวิธีการ: ผู้ป่วย simple fistula in ano 50 ราย ที่เข้าตามเกณฑ์การศึกษา จะได้รับการแบ่งเป็น 2 กลุ่ม โดยวิธีสุ่มคือ กลุ่มหนึ่งได้รับการผ่าตัด fistulotomy เพียงอย่างเดียว และอีกกลุ่มหนึ่งได้รับการผ่าตัด fistulotomy with marsupialization ซึ่งทั้ง 2 กลุ่ม ได้รับการดูแลก่อนและหลังผ่าตัดด้วยวิธีการแบบเดียวกันที่เป็นมาตรฐาน และมีการประเมินระดับความเจ็บปวด โดยให้ผู้ป่วยเป็นผู้กรอกในวันที่ 1, 3, 5, 7 และ 14 หลังผ่าตัด นอกจากนี้ระดับความเจ็บปวดหลังการถ่ายอุจจาระครั้งแรก จำนวนยาแก้ปวดที่ใช้ ได้แก่ pethidine injection และ paracetamol tablet ภาวะแทรกซ้อนหลังผ่าตัด รวมถึงการหายขาดของ fistula จะได้รับการประเมินเพื่อเปรียบเทียบการรักษาระหว่างทั้ง 2 วิธี

ผลการศึกษา: ไม่พบความแตกต่างของความเจ็บปวดแผลหลังผ่าตัดระหว่างกลุ่มการรักษาทั้งสอง แต่พบว่าผู้ป่วย 13 คน ในกลุ่ม fistulotomy และผู้ป่วย 4 คน ในกลุ่ม fistulotomy with marsupialization ขอยาแก้ปวดชนิดฉีด (pethidine injection) เมื่อเปรียบเทียบกันพบว่ามีค่าความแตกต่างกันอย่างมีนัยสำคัญทางสถิติ ($p = 0.017$) สำหรับความเจ็บปวดแผลหลังการถ่ายอุจจาระครั้งแรก จำนวนยาแก้ปวดที่กิน (paracetamol) และภาวะแทรกซ้อนที่เกิดขึ้นระหว่างทั้งสองกลุ่ม พบว่าไม่มีค่าความแตกต่างกันอย่างมีนัยสำคัญทางสถิติ และไม่มีผู้ป่วยในกลุ่มใดเกิดปัญหาเรื่องการกลั้นอุจจาระหลังผ่าตัด หรือ มีการกลับเป็นซ้ำของ fistula

สรุป: การผ่าตัดด้วยวิธี fistulotomy with marsupialization ได้ผลการรักษาที่ดีและมีความปลอดภัย ดังนั้นวิธีนี้จึงควรเป็นอีกหนึ่งทางเลือกที่เหมาะสมสำหรับการรักษาผู้ป่วย simple fistula in ano
