

Wall Thickness and Outer Diameter of the Normal Appendix in Adults Using 64 Slices Multidetector CT

Aphinya Charoensak MD*,
Sopa Pongpornsup MD*, Wanwarang Suthikeeree MD*

* Department of Radiology, Faculty of Medicine, Siriraj Hospital, Mahidol University, Bangkok, Thailand

Objective: Determine wall thickness and outer diameter of the normal appendix in adults using 64 slices multidetector CT

Material and Method: A retrospective review of 538 patients (190 men, 348 women; mean age, 56.5 years \pm 15.2 SD) who were sent for abdomino-pelvic CT without clinical suspicion of acute appendicitis was conducted. Two radiologists blinded to the presented patient's history of appendectomy interpreted CT images regarding the visualization of the appendix, location, luminal contents and presence of appendicoliths. The maximum outer diameter and two walls thickness of the visualized appendices were measured.

Results: The sensitivity, specificity, positive and negative predictive value, and accuracy for visualization of the appendix were 90.8%, 100%, 100%, 76.5% and 92.9% for reader 1 and 97.3%, 97.6%, 99.3%, 91.7% and 97.4% for reader 2. The mean maximum outer diameter of the appendix was 6.6 mm \pm 1.5 (range, 3.4-14.0 mm). The mean two walls thickness of the appendix was 4.4 mm \pm 1.0 (range, 1.6-8.0 mm).

Conclusion: The normal appendix is frequently identified at 64 slices MDCT. Contrast to maximum outer diameter, normal two walls thickness of the appendix is infrequently exceeding the threshold of 6 mm.

Keywords: Computed tomography, Multidetector, Appendix, Adults

J Med Assoc Thai 2010; 93 (12): 1437-42

Full text. e-Journal: <http://www.mat.or.th/journal>

Computed tomography (CT) is a preferred imaging examination as compared to ultrasound to evaluate adult patients with clinically suspected appendicitis. That is, all adults except pregnant women whose radiation exposure is a major concern. Recent development of multidetector computed tomography (MDCT) improves both spatial and temporal resolution, and enables acquisition of thin sections with isotropic voxel size. It increases visualization rate of the appendix and improves the diagnostic accuracy. CT diagnosis of acute appendicitis is based on detection of enlarged and inflamed appendix, and presence of periappendiceal inflammatory changes including fluid collections or abscesses. Demonstration of normal appendix on CT normally excludes acute appendicitis and leads radiologists to look for other causes that can mimic acute appendicitis.

Based on sonographic results, it is widely accepted that the normal diameter of the appendix on CT is 6 mm or less. However, normal appendiceal diameter can be measured at greater than 6 mm especially in distended appendix. Recent articles⁽¹⁾ have suggested that wall thickness of the appendix is a more reliable measurement than appendiceal diameter. However, there are few studies⁽¹⁻⁵⁾ about normal diameter and/or wall thickness of the appendix using MDCT. Therefore, the present study was performed to determine the value of two walls thickness and maximum outer diameter of the normal appendix in adults using 64 slices MDCT.

Material and Method

Study population

The presented retrospective study was approved by institutional review board and patient informed consent was waived. Between January 1 and February 28, 2009, 610 consecutive adult patients (age greater than 18 years old) who were sent for abdomino-pelvic CT scans and did not have clinical suspicion of acute appendicitis were included in the present study. The exclusion criteria were (a) patients

Correspondence to:

Charoensak A, Department of Radiology, Faculty of Medicine Siriraj Hospital, Mahidol University, Bangkok, 10700, Thailand.
Phone:
E-mail: ch_aphinya@yahoo.com

who were diagnosed as appendicitis including spontaneous resolved appendicitis; (b) patients who were diagnosed as appendiceal tumor or diseases at ileocecal regions which can cause appendiceal enlargement such as tuberculosis, inflammatory bowel disease, right sided colitis, and cecal tumor; (c) patients without available history of appendectomy and (d) patients who abdomino-pelvic CT scan was performed without intravenous contrast media. The final study population included 538 patients, 190 men and 348 women, mean age 56.5 years \pm 15.2 SD (range, 18-95 years).

The most common indication for CT examination was staging or post treatment evaluation of known malignancies (379 patients, 70.4%). Among 379 patients with known malignancies, three most common malignancies were lymphoma (98 patients, 25.9%), cervix cancer (66 patients, 17.4%) and ovarian cancer (42 patients, 11.1%). Other indications were evaluation of abdominal mass (29 patients), abdominal pain (25 patients), fever (21 patients), checkup (21 patients), work up for primary tumor (20 patients), GI symptoms (14 patients), trauma (5 patients), and others (19 patients). The remaining five patients had no available information.

History of appendectomy

A radiologist who did not involve in image interpretation reviewed medical records to obtain patient's history of appendectomy. If history of appendectomy was not documented in medical records, a telephone call was made to ask about history of appendectomy.

CT technique

All examinations were performed with one of two 64-detector CT scanners (Somatom Definition, Siemens Medical Solution, Germany; and LightSpeed VCT, General Electric Medical Systems, Milwaukee, Wisconsin, USA). Images were obtained from hepatic dome to pubic symphysis with the following parameters: 120 kV(peak), 500 mA (GE) or 250 mAs with care dose (Siemens), a gantry rotation time of 0.5 second, section thickness of 1.25-1.5 mm and a pitch of 1:0.9 (Siemens) or 1: 0.984 (GE). One hour before the examination, each patient was instructed to drink 200-250 cc of oral contrast medium every 15 min. All patients included in the present study received oral contrast, rectal contrast and 100 mL intravenous contrast followed by 20 mL of normal saline at a rate of 2 mL/sec by using a power injector.

Imaging analysis

Two radiologists (SP, WS), blinded to history of appendectomy, interpreted CT images at picture archiving and communication systems workstations (PACS; Synapse, Fujifilm Medical Systems). Both radiologists have four years of abdominal CT interpretation experience. Each reader independently reviewed CT images for visualization of the appendix, which was assessed as visualized or not visualized. In addition to axial images, interpretations of coronal and sagittal reformation images were performed at PACS workstation. If there is discrepancy in visualization of the appendix, both readers together interpreted CT images for consensus opinion. For all visualized appendices, each reader measured maximum outer diameter and two walls thickness of the appendix by using electronic caliper. Two walls thickness of the appendix was measured by subtracting the luminal diameter from the maximum outer diameter. If the appendix was collapsed, two walls thickness was a half value of the maximum outer diameter of the appendix. Then, they were asked to identify location of the appendix, the content in appendiceal lumen (air, fluid, contrast medium) and presence of appendicoliths. Location of the tip of the appendix was classified as paracolic (adjacent to the ascending colon), retrocecal (behind the cecum), pelvic (extending to the pelvis), or midline (extending to the midline). Location of the base of the appendix was classified as anterior, posterior, medial or lateral and superior or inferior relative to the ileocecal valve.

Statistical analysis

Visualization of the appendix in patients who denied history of appendectomy was considered as true-positive results and non-visualization of the appendix in patients who had undergone appendectomy was considered as true-negative results. Visualization of the appendix in patients who had undergone appendectomy was considered as false-positive results and non-visualization of the appendix in patients who denied history of appendectomy was considered as false-negative results. The sensitivity, specificity, positive predictive value, negative predictive value, and accuracy for visualization of the appendix of each reader were determined. The kappa statistic was used to assess inter-observer agreement for visualization of the appendix. A kappa (k) value less than 0.2 indicated poor agreement, 0.21-0.4 indicated fair agreement, 0.41-0.6 indicated moderate agreement, 0.61-0.8 indicated good agreement and greater than 0.8 indicated

very good agreement, as suggested by Altman⁽⁶⁾. Mean \pm standard deviation (SD) and range of the measurements of maximum outer diameter and two walls thickness of the appendix by two readers were compared with a paired Student's t-test. Statistical analysis was computed using SPSS version 13.0 for Windows (Microsoft).

Results

Visualization of the appendix

Of 538 patients, 124 patients had a history of appendectomy. The prevalence of appendectomy in the present study was 23%. Visualization of the appendix by both readers is shown in Table 1. The inter-observer agreement for visualization of the appendix was good ($k = 0.79$). The sensitivity, specificity, positive predictive value, negative predictive value, and accuracy for visualization of the appendix of reader 1 were 90.8%, 100%, 100%, 76.5%, and 92.9%. The sensitivity, specificity, positive predictive value, negative predictive value, and accuracy for visualization of the appendix of reader 2 were 97.3%, 97.6%, 99.3%, 91.7% and 97.4%. Regarding the visualization of the appendix, 46 patients had discrepancy results between readers. After consensus review, the appendix was visualized in 407 patients

and not visualized in seven of 414 patients who denied a history of appendectomy. Of 124 patients who had undergone appendectomy, no patient whose appendix was visualized.

After retrospective review of CT images of three false positive cases interpreted by reader 2, a missed identification of collapsed distal ileum as an appendix was found in two cases and a missed identification of board ligament located adjacent to the cecum as an appendix (Fig. 1).

Outer diameter and two wall thickness of the appendix

Of 407 visualized appendices, the mean \pm SD and the range of maximum outer diameter and two walls thickness of the appendix measured by both readers are shown in Table 2. The paired t-test shows mean differences in measurement of maximum outer diameter between two readers was $0.4 \text{ mm} \pm 1.1$ (95% CI, 0.29, 0.51) and mean differences in measurement of two walls thickness between two readers was $0.6 \text{ mm} \pm 1.3$ SD (95% CI, 0.51, 0.78).

The mean \pm SD appendiceal outer diameter of average values measured by both readers was $6.6 \text{ mm} \pm 1.5$ (range, 3.4-14.0 mm). Of the 407 visualized appendices, the maximum outer diameter was measured greater than 6 mm but not greater than 10 mm in

Table 1. Visualization of the appendix

| Visualization of the appendix | Non appendectomy group (No. of patients) (n = 414) | Appendectomy group (No. of patients) (n = 124) |
|----------------------------------|---|---|
| Reader 1 | | |
| Visualized | 376 | 0 |
| Not visualized | 38 | 124 |
| Reader 2 | | |
| Visualized | 403 | 3 |
| Not visualized | 11 | 121 |
| Consensus opinion of both reader | | |
| Visualized | 407 | 0 |
| Not visualized | 7 | 124 |

Table 2. Maximum outer diameter and two walls thickness of the appendix measured by both readers

| Measurement of the appendix | Reader 1 mean \pm SD (range) | Reader 2 mean \pm SD (range) | Both readers* mean \pm SD (range) |
|-----------------------------|-----------------------------------|-----------------------------------|--|
| Maximum outer diameter | 6.4 mm \pm 1.6 (3-13.7 mm) | 6.8 mm \pm 1.5 (3.5-14.3 mm) | 6.6 mm \pm 1.5 (3.4-14.0 mm) |
| Two walls thickness | 4.7 mm \pm 1.4 (1.2-8 mm) | 4.1 mm \pm 1.0 (1.6-8.0 mm) | 4.4 mm \pm 1.0 (1.6-8.0 mm) |

* Average values for 407 visualized appendices that were measured by two readers

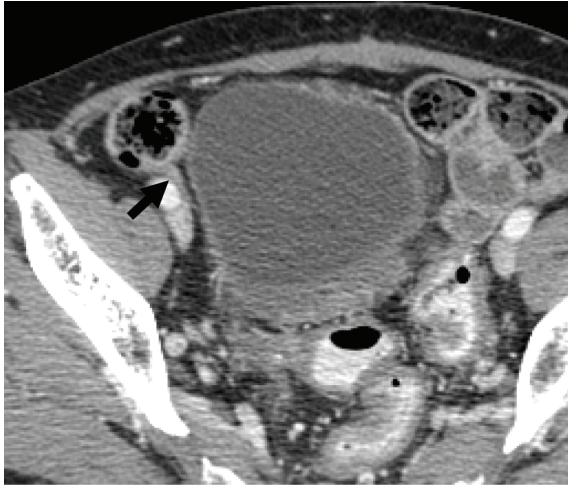


Fig. 1 The board ligament (arrow) located adjacent to the cecum was missed identification as an appendix

241 patients (59.2%) and the maximum diameter was measured greater 10 mm in 10 patients (2.5%). The appendix with largest maximum outer diameter (14.0 mm) contained fecal and air content (Fig. 2).

The mean two walls thickness of the appendix of average values measured by both readers was $4.4 \text{ mm} \pm 1.0$ (range, 1.6-8.0 mm). Of the 407 visualized appendices, the two walls thickness was measured greater than 6 mm in 27 patients (6.6%). In five of 27 patients, the two walls thicknesses were measured more than 7 mm.

Location of the appendix

The location of the appendiceal tip was midline in 149 (36.6%), pelvic in 108 (26.5%), paracolic in 93 (22.9%) and retrocecal in 57 (14.0%) of 407 visualized appendices. The base of the appendix was inferior to the ileocecal valve in 406 patients (99.8%) and superior in one patient (0.2%). The base of the appendix was medial in 226 patients (55.5%), posterior in 176 patients (43.2%), lateral in four patients (1.0%) and anterior in one patient (0.2%).

Luminal content and appendicoliths

The luminal contents of the appendix were visualized in 340 (83.5%) of 407 patients. In the remaining 67 patients (16.5%), the appendices were collapsed. Luminal contents were air only (222/407 patients, 54.5%), fluid only (36/407 patients, 8.9%), contrast medium only (33/407 patients, 8.1%), air and fluid (24/407 patients, 5.9%), air and contrast medium (23/407 patients, 5.7%),

air and feces (1/407 patient, 0.2%) and fluid and contrast medium (1/407 patient, 0.2%). Appendicoliths were detected in 29 patients (7.1%).

Discussion

Accurate preoperative diagnosis of acute appendicitis is important to prevent unnecessary surgery. When normal appendix is demonstrated on CT, appendicitis is nearly excluded and alternative causes of acute abdominal pain are sought. Although CT findings of enlarged appendix with periappendiceal fat stranding occurs in the majority

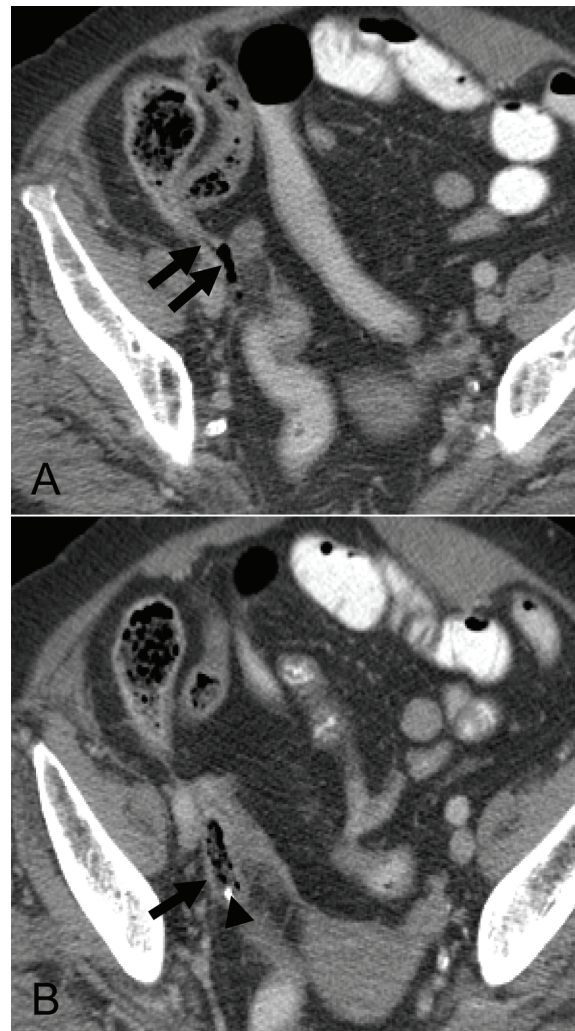


Fig. 2 An appendix which has the greatest outer diameter in the present study (arrow) contained air and fecal contents. An appendicolith (arrowhead) was also demonstrated

(93%) of appendicitis cases⁽⁷⁾, Jacobs et al⁽⁸⁾ has reported absence of periappendiceal inflammation in 15% of appendicitis patients examined with contrast enhanced CT. Thus, determination of normal size of the appendix is crucial especially in patients without periappendiceal inflammation.

The mean \pm SD maximum outer diameter of the normal appendix in the present study was 6.6 mm \pm 1.5. Approximately 62% of visualized appendices in the present study have maximum outer diameter greater than 6 mm and only 2.5% of visualized appendices have maximum outer diameter greater than 10 mm. This corresponds with results of the previous studies^(1,2,7,9) that suggested a diameter of 10 mm for the upper limit of normal. The largest outer diameter (14 mm) of the appendix measured in the present study is due to luminal distension with fecal content.

Regarding wall thickness of the appendix, previous studies^(1,4,9) have suggested that an upper limit of 6 mm can be used reliably only if the luminal content is recognized. Visualization of luminal content and use of intravenous contrast media are key factors to improve identification of the appendix wall. All patients in the present study received intravenous contrast media and luminal contents of the appendix were demonstrated in most patients (83.5%). Thus, appendiceal wall was well identified. In the study by Huwart L et al⁽¹⁾, the mean thickness of the two appendix walls measured more than 6 mm was found in 4.2% (2/47) of visualized appendices. In the study by Tamburrini S et al⁽⁴⁾, only 0.9% (2/222) of patients had an appendiceal wall thickness greater than or equal to 3 mm. The mean two walls thickness of the normal appendix in the present study was 4.4 mm \pm 1.0 and it was measured greater than 6 mm about 6.6%. Consequently, two walls thickness of the normal appendix is infrequently greater than the threshold of 6 mm. However, the accurate measurement is required. The present study demonstrated some variability in the measurement between different readers. Other than measurement error by individuals, another explanation is variation in thickness within the length of an appendix. Both readers possibly performed the measurement at different locations of the appendix.

The present study demonstrates high visualization rate (90.8% for reader 1 and 97.3% for reader 2) of the normal appendix on MDCT in patients who denied history of appendectomy. Result is similar to previous studies using MDCT⁽¹⁻⁵⁾, which reported 82%-96% visualization rate of normal appendix. Balthazar et al have suggested that visualization of the

normal appendix depends on the type and quality of CT examination, the amount of intraperitoneal fat, and meticulous radiologists⁽¹⁰⁾. However, the present study did not assess factors influenced with visualization of the appendix.

There are some limitations in the present study. First, history of appendectomy was used as gold standard reference instead of pathology because it is impossible to have a pathological proof of the normal appendix. There is possibility that some patients did not know that their appendix was removed during prior pelvic or abdominal surgery. Moreover, the authors disregarded the possibility of congenital absence of the appendix. There is estimated incidence of appendix agenesis in one of 100,000 laparotomies for patients suspected of having appendicitis⁽¹¹⁾. Second, the study population in the present study is not healthy adults. However, patients with diseases of the appendix or ileocecal region that can result in appendiceal enlargement were excluded in the present study. Finally, the present study did not assess precision and accuracy of the measurement. There is a possibility of measurement error by readers.

Conclusion

Using 64 slices MDCT, the normal appendix is frequently identified. Based on appendix measurement, the normal appendix frequently have two walls thickness less than or equal to 6 mm. In addition to appendix measurement, however, interpretation of the normal appendix should be based on absence of inflammation along the entire length of the appendix.

Acknowledgements

The authors wish to thank Dr. Chulaluk Komoltri for the statistic analysis.

References

1. Huwart L, El Khoury M, Lesavre A, Phan C, Rangheard AS, Bessoud B, et al. What is the thickness of the normal appendix on MDCT? *J Radiol* 2007; 88: 385-9.
2. Jan YT, Yang FS, Huang JK. Visualization rate and pattern of normal appendix on multidetector computed tomography by using multiplanar reformation display. *J Comput Assist Tomogr* 2005; 29: 446-51.
3. Johnson PT, Eng J, Moore CJ, Horton KM, Fishman EK. Multidetector-row CT of the appendix in healthy adults. *Emerg Radiol* 2006; 12: 248-53.

4. Tamburrini S, Brunetti A, Brown M, Sirlin CB, Casola G. CT appearance of the normal appendix in adults. *Eur Radiol* 2005; 15: 2096-103.
5. Joo SM, Lee KH, Kim YH, Kim SY, Kim K, Kim KJ, et al. Detection of the normal appendix with low-dose unenhanced CT: use of the sliding slab averaging technique. *Radiology* 2009; 251: 780-7.
6. Altman DG. *Practical statistics for medical research*. London: Chapman and hall; 1991.
7. Rao PM, Rhea JT, Novelline RA. Sensitivity and specificity of the individual CT signs of appendicitis: experience with 200 helical appendiceal CT examinations. *J Comput Assist Tomogr* 1997; 21: 686-92.
8. Jacobs JE, Birnbaum BA, Macari M, Megibow AJ, Israel G, Maki DD, et al. Acute appendicitis: comparison of helical CT diagnosis focused technique with oral contrast material versus nonfocused technique with oral and intravenous contrast material. *Radiology* 2001; 220: 683-90.
9. Benjaminov O, Atri M, Hamilton P, Rappaport D. Frequency of visualization and thickness of normal appendix at nonenhanced helical CT. *Radiology* 2002; 225: 400-6.
10. Balthazar EJ, Megibow AJ, Hulnick D, Gordon RB, Naidich DP, Beranbaum ER. CT of appendicitis. *AJR Am J Roentgenol* 1986; 147: 705-10.
11. Chevre F, Gillet M, Vuilleumier H. Agenesis of the vermiform appendix. *Surg Laparosc Endosc Percutan Tech* 2000; 10: 110-2.

ค่าความหนาของผนังและเส้นผ่านศูนย์กลางของไส้ติ่งปกติในผู้ใหญ่ตรวจโดยเครื่องเอกซเรย์คอมพิวเตอร์ชนิด 64 สไลซ์

อภิญา เจริญศักดิ์, โสภา พงศ์พรทรัพย์, วรรณวรงค์ สุทธิศิริ

วัตถุประสงค์: เพื่อหาค่าความหนาของผนังไส้ติ่งและค่าเส้นผ่านศูนย์กลางของไส้ติ่งปกติในผู้ใหญ่ที่ตรวจโดยเครื่องเอกซเรย์คอมพิวเตอร์ชนิด 64 สไลซ์

วัสดุและวิธีการ: ทำการศึกษาย้อนหลังในผู้ป่วยที่ส่งมาตรวจเอกซเรย์คอมพิวเตอร์ของช่องท้องและไม่มีอาการทางคลินิก สงสัยภาวะไส้ติ่งอักเสบเฉียบพลัน จำนวน 538 คน (เพศชาย 190 คน, เพศหญิง 348 คน, อายุเฉลี่ย 56.5 ปี) รังสีแพทย์ 2 คน ทำการแปลผลภาพเอกซเรย์คอมพิวเตอร์ โดยไม่ทราบประวัติการผ่าตัดไส้ติ่ง เก็บข้อมูลเกี่ยวกับการเห็นไส้ติ่ง, ตำแหน่งและสิ่งที่อยู่ในไส้ติ่ง จากนั้นทำการวัดเส้นผ่านศูนย์กลางของไส้ติ่ง และวัดความหนาของผนังไส้ติ่งทั้งสองด้าน

ผลการศึกษา: ค่าความไว, ความจำเพาะ, positive predictive value, negative predictive value, และค่าความแม่นยำของรังสีแพทย์คนแรก เท่ากับร้อยละ 90.8, 100, 100, 76.5, และ 92.9 และค่าความไว, ความจำเพาะ, positive predictive value, negative predictive value, และค่าความแม่นยำของรังสีแพทย์คนที่สอง เท่ากับร้อยละ 97.3, 97.6, 99.3, 91.7, และ 97.4 ค่าเฉลี่ยของเส้นผ่านศูนย์กลางของไส้ติ่งเท่ากับ 6.6 ± 1.5 มิลลิเมตร ค่าเฉลี่ยของความหนาของผนังไส้ติ่งสองด้านเท่ากับ 4.4 ± 1.0 มิลลิเมตร

สรุป: สามารถเห็นไส้ติ่งปกติได้บ่อยเมื่อตรวจด้วยเครื่องเอกซเรย์คอมพิวเตอร์ชนิด 64 สไลซ์ ค่าปกติของความหนาของผนังไส้ติ่งสองด้านส่วนมากมักมีค่าไม่เกิน 6 มิลลิเมตร