

Case Report

Left Subclavian Arterioesophageal Fistula Induced by Chicken Bone with Upper Gastrointestinal Hemorrhage and Unexpected Death: Report of a Case

Vichan Peonim MD*,
Jilta Udnoon MD*

* Department of Pathology, Faculty of Medicine, Ramathibodi Hospital, Mahidol University, Bangkok, Thailand

Left subclavian arterioesophageal fistula resulting from chicken bone ingestion is a rare occurrence. The authors report the death of a 42-year-old Thai female with mental retardation who presented to the hospital with severe hematemesis and arrested. Death occurred about 24 hours after laparotomy due to hypovolemic shock. Postmortem examination revealed a chicken bone embedded in middle part of esophagus with fistula between the esophagus and the left subclavian artery.

Keywords: Left subclavian arterioesophageal fistula, Chicken bone ingestion, Foreign body in the esophagus, Unexpected death, Upper gastrointestinal hemorrhage

J Med Assoc Thai 2010; 93 (II): 1332-5

Full text. e-Journal: <http://www.mat.or.th/journal>

Esophageal foreign bodies have regularly been found in both children and adults. Mostly in children aged between 1-5 years old⁽¹⁻³⁾, and in adult who swallowed chicken bone both unintentionally and intentionally. The demographic group most at risk includes the elderly, persons with dementia or mental retardation, and drug addict etc⁽⁴⁻⁶⁾. The people at risk also include persons wearing dentures⁽⁷⁾, having mental disorder, and prisoners^(1,7,8).

Esophageal foreign bodies that have frequently been found are bone, coins, and pins^(4,9). Most esophageal foreign bodies caused by bone are fish bones approximately 60% and chicken bone about 16%⁽⁹⁾. In addition, 90% of esophageal foreign bodies are able to pass through the gastrointestinal tract and eliminate in the stool with no harm^(1,2,7). Nonetheless, there are major risks with ingested esophageal foreign bodies as presented in case reports of fistula between the esophagus and major arteries inside the thorax that might cause death^(10,11) especially aorto-esophageal fistula^(4,11-14). Left subclavian arterioesophageal fistula from a fish bone swallowed

was presented in a previous report⁽¹⁵⁾. This report explains one case of death caused by left subclavian arterioesophageal fistula from a chicken bone struck in the esophagus.

Case Report

A Thai female, 42 years of age, with mental retardation, was sent to the hospital with symptoms of severe hematemesis. She had never been recorded as gastrointestinal bleeding or alcoholism, and took medicine in group of steroid or NSAIDs. She had pain and tenderness around the epigastric area. Her blood pressure was measured as 110/80-88/62 mm Hg and blood analysis, found hematocrit 24%, white blood cell count of 14.6×10^9 per liter, neutrophils 86%, lymphocytes 14%, and platelets count 49.8×10^9 per liter. Prothrombin and partial thromboplastin time were not prolonged. Liver and renal function test and blood electrolyte were unremarkable. At the early stage of admission, the patient had condition of hypovolemic shock and arrested. After emergency laparotomy, internal bleeding (800 ml) was found in esophagus and stomach. Gastrostomy with disconnected blood supply from greater and lesser curvature, esophagectomy with end-to-end anastomosis, and splenectomy were done. After the operation, shock condition had not recovered and the patient died within 24 hours in hospital. An autopsy was performed.

Correspondence to:

Peonim V, Forensic Unit, Department of Pathology, Faculty of Medicine, Ramathibodi Hospital, Mahidol University, Bangkok 10400, Thailand.

Phone & Fax: 0-2201-1145

E-mail: rapathology@diamond.mahidol.ac.th

Autopsy finding

The body was that of a well-developed, adult female weighing 63 kg and measuring 154 cm. There was surgical wound over upper midline of abdomen. In examination of the esophagus, a Y-shaped bone of chicken (clavicle) measuring 3 cm was found embedded in the middle part of esophagus at the 10 cm above gastroesophageal junction causing three penetrated wounds sized of 0.8 cm in diameter (Fig. 1). Unfortunately, one lesion perforated the esophageal wall and extended into the adjacent left subclavian artery. The stomach and proximal part of small intestine contained approximately 500 and 1,000 ml of blood, respectively. The other organs were unremarkable. Histopathological examination revealed that there was chronic inflammatory cell infiltration with necrosis and hemorrhage around the wounds and fistula tract of esophagus.

Discussion

Esophageal foreign bodies found are mostly bone, coins, and pins^(4,9) in both children⁽³⁾ and adults with risky conditions such as mental retardation, alcoholic, drug abuse, and psychoses⁽⁴⁻⁶⁾. According to numerous reports, bone is found in 19 to 84%^(6,9,16),

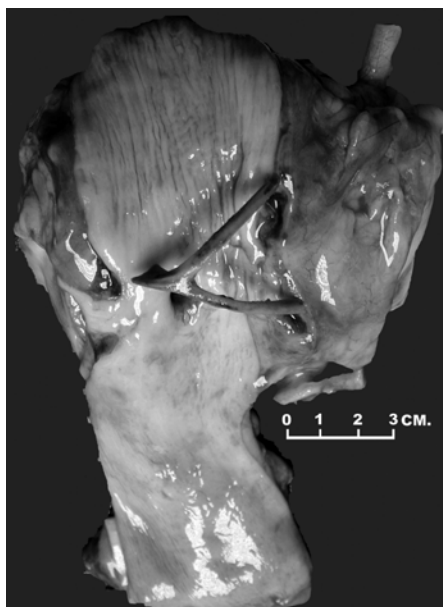


Fig. 1 The esophageal lumen was exposed, revealing the Y shaped of the chicken bone (clavicle) embedded in the mucosa with three penetrated wounds at left lateral and posterior wall

and the type of bone is fish bone in about 60% and chicken bone in about 16%⁽⁹⁾. The symptom of esophageal foreign bodies includes discomfort or pain on swallowing, tender on epigastric, and abnormal respiration such as choking, stridor, or respiratory distress⁽⁸⁾. However, in some patients, the symptom may not be present⁽¹⁷⁾. About 90% of esophageal foreign bodies may pass through the gastrointestinal tract by stooling. Almost 10% esophageal foreign bodies can be removed by endoscope and only the remaining 1% shall need an operation^(1,2,7). The intervening effect that may incur and cause death is fistula between the esophagus and the large arteries in the thoracic cavity^(10,11). Those are rare. Aorto-esophageal fistula is the most common problem found⁽¹¹⁻¹⁴⁾. Previously, there were cases reports of esophageal foreign bodies caused by chicken bones affecting aorto-esophageal fistula^(9,10), right common carotid arterio-esophageal fistula⁽¹⁸⁾, and left lingual artery oesophageal fistula⁽¹⁹⁾, and fish bone causing left subclavian arterio-esophageal fistula⁽¹⁵⁾.

In the present study, it was shown that the patient had a condition of mental retardation and died from severe upper gastrointestinal hemorrhage due to left subclavian arterio-esophageal fistula with no record of any clinical symptoms. After autopsy, the finding showed that a chicken bone was embedded in the upper thoracic part of esophagus that via narrowing part because it was pressed by the arch of aorta. The anatomy of the esophagus is four narrowing parts, which are one part at beginning of esophagus, two parts in thoracic, the area being pressed by arch of aorta and pressed by left main bronchus, and the last part is through the diaphragm^(9,17,20). The pressure on the end of bone pressing on esophagus was considered as direct injury and caused inflammation, necrosis, and fistula tract.

Conclusion

The case report was submitted representing a woman, 42 years of age, with mental retardation, and admission on massive upper gastrointestinal hemorrhage and death. Autopsy revealed that the patient had left subclavian arterio-esophageal fistula induced by chicken bone in the esophagus.

References

1. Eisen GM, Baron TH, Dominitz JA, Faigel DO, Goldstein JL, Johanson JF, et al. Guideline for the management of ingested foreign bodies. *Gastrointest Endosc* 2002; 55: 802-6.

2. Lin E, Fink AS. Endoscopy and endoscopic intervention. In: Zinner MJ, Ashley S Jr, editors. *Maingot's abdominal operations*. 11th ed. New York: McGraw-Hill; 2007: 35-68.
3. Chaikhouni A, Kratz JM, Crawford FA. Foreign bodies of the esophagus. *Am Surg* 1985; 51: 173-9.
4. Scher RL, Tegtmeyer CJ, McLean WC. Vascular injury following foreign body perforation of the esophagus. Review of the literature and report of a case. *Ann Otol Rhinol Laryngol* 1990; 99: 698-702.
5. Barber GB, Peppercorn MA, Ehrlich C, Thurer R. Esophageal foreign body perforation: report of an unusual case and review of the literature. *Am J Gastroenterol* 1984; 79: 509-11.
6. Caonamo A, Dumon JF, Meric B, Noirclerc MJ. Foreign body in the esophagus. In: Jamieson GG, editor. *Surgery of the oesophagus*. Edinburgh: Churchill Livingstone; 1988: 383-5
7. Chojnacki KA. Foreign bodies and bezoars of the stomach and small intestine. In: Yeo CJ, Dempsey DT, Klein AS, Pemberton JH, Perters JH, editors. *Shackelford's surgery of the alimentary tract*. 6th ed. Philadelphia: Saunders Elsevier; 2007: 940-6.
8. Thomas SH, Brown DFM. Foreign bodies. In: Marx JA, Hockberger RS, Walls RM, editors. *Rosen's emergency medicine: concepts and clinical practice*. St. Louis, MO: *Mosby*; 2002: 752-74.
9. Nandi P, Ong GB. Foreign body in the oesophagus: review of 2394 cases. *Br J Surg* 1978; 65: 5-9.
10. Lui RC, Johnson FE, Horovitz JH, Cunningham JN Jr. Aorto-esophageal fistula: case report and literature review. *J Vasc Surg* 1987; 6: 379-82.
11. Wu MH, Lai WW. Aorto-esophageal fistula induced by foreign bodies. *Ann Thorac Surg* 1992; 54: 155-6.
12. Grey TC, Mittleman RE, Wetli CV, Horowitz S. Aorto-esophageal fistula and sudden death. A report of two cases and review of the literature. *Am J Forensic Med Pathol* 1988; 9: 19-22.
13. Sloop RD, Thompson JC. Aorto-esophageal fistula: report of a case and review of literature. *Gastroenterology* 1967; 53: 768-77.
14. Cheng LC, Chiu CS. Foreign body-induced aorto-oesophageal fistula: a review of five cases and their management. *Hong Kong Med J* 2006; 12: 219-21.
15. Leow CK. Subclavian arterio-esophageal fistula secondary to fish bone impaction: report of a case. *Surg Today* 1998; 28: 409-11.
16. Clerf LH. Foreign bodies in the air and food passages: observations on end-results in a series of nine hundred and fifty cases. *Surg Gynecol Obstet* 1940; 70: 328-39.
17. Waltzman ML. Management of esophageal coins. *Curr Opin Pediatr* 2006; 18: 571-4.
18. Russo SS, Taff ML, Ratanaproeaksa O, Spitz WU. Sudden death resulting from chicken bone perforation of the esophagus. *Am J Forensic Med Pathol* 1986; 7: 263-5.
19. McCormack LR, Monroe LS. Esophageal perforation by swallowed foreign body causing arterial fistula with gastrointestinal hemorrhage. *Gastrointest Endosc* 1977; 23: 157-8.
20. Romanes GJ. *Cunningham's text book of anatomy*. 12th ed. London: Oxford University Press; 1981: 437.

Subclavian arterioesophageal fistula ข้างซ้ายสาเหตุจากกระดูกไก่ติดค้ำบริเวณหลอดอาหาร:
รายงานผู้ป่วยเสียชีวิต 1 ราย

วิชาญ เบี้ยวนิม, จิตตา อุดหนุน

Subclavian arterioesophageal fistula ข้างซ้ายที่เกิดจากกระดูกไก่ติดค้ำที่หลอดอาหารพบได้น้อยมาก รายงานนี้ได้นำเสนอ ผู้ป่วยหญิงไทย 1 ราย อายุ 42 ปี เป็นโรคปัญญาอ่อนมารับการรักษาด้วยอาการอาเจียนเป็นเลือด จำนวนมาก ได้ทำการรักษาโดยการผ่าตัดเข้าช่องท้องเพื่อห้ามเลือด และผู้ป่วยเสียชีวิตหลังเข้ารับการรักษาประมาณ 24 ชั่วโมง จากภาวะช็อกเนื่องจากเสียเลือดมาก ผลการผ่าตัดตรวจพบกระดูกไก่รูปตัว Y (กระดูกไหปลาร้าไก่) ติดค้ำ บริเวณหลอดอาหารส่วนกลาง เนื่องจากบริเวณนี้ตามลักษณะทางกายวิภาคศาสตร์ เป็นบริเวณที่แคบจากการถูกกดของ arch of aorta และแขนงหลอดลมใหญ่ข้างซ้าย และเกิดบาดแผลทะลุจากการกดของปลายกระดูกร่วมกับ การเกิดการอักเสบและเนื้อตายรอบ ๆ บาดแผล ทำให้เกิดช่องเชื่อมต่อระหว่างหลอดอาหารและหลอดเลือดแดง subclavian ข้างซ้าย ซึ่งเป็นสาเหตุทำให้เลือดออกมากที่ทางเดินอาหารส่วนบน และผู้ป่วยเสียชีวิตจากการภาวะช็อก
