

# The Landmarks of Centers of the Distal Femur and the Proximal Tibia in Sagittal Plane for Application in Computer Assisted Total Knee Arthroplasty

Naraphong Hangsaphuk MD\*,  
Aree Tanavalee MD\*\*

\* Department of Orthopedic Surgery, Sirindhorn Hospital, Bangkok, Thailand

\*\* Department of Orthopaedics, Faculty of Medicine, Chulalongkorn University, Bangkok, Thailand

---

**Background:** In the computer assisted total knee arthroplasty (CAS-TKA), the centers of the distal femur and the proximal tibia for the sagittal mechanical axis (SMA) of both femur and tibia have unclear references. Most CAS-TKA systems define both centers following the engineer's recommendation.

**Objective:** To evaluate the centers of the distal femur and the proximal tibia in sagittal plane and to determine the sagittal mechanical axis (SMA) of the normal knee in relation to the Blumensaat's line and the tibial anteroposterior line.

**Material and Method:** Fifty five normal healthy knees without flexion contracture or hyperextension were enrolled. The sagittal mechanical axis (SMA) was drawn from the center of the femoral head to the most prominent dome of the talus on the long standing hip-knee-ankle radiograph in lateral view. The point that the SMA passed the Blumensaat's line of distal femur and the tibial plateau at the proximal tibia were reported as the percentage of the total length of Blumensaat's line and of the anteroposterior width of tibial plateau respectively.

**Results:** Among 55 knees included in this study, 32 knees were right side and 23 knees were left sided. Of which, there were 14 females and 41 males. Their average age was 45 years. The average BMI was 25.67. The average knee alignment in sagittal plane was 1.7 degrees. At the distal femur, the point that SMA passed the Blumensaat's line was average 13% of the total length of Blumensaat's line. There were only 22% of the 55 knees that the SMA passed at the tip of Blumensaat's line. All of SMA in 55 knees passed within the first quarter of this line. At the proximal tibia, the point that SMA passed the tibial plateau average 45% of the anteroposterior width of tibial plateau.

**Conclusion:** The center of distal femur and proximal tibia on sagittal plane are not individual consistent. Therefore, they should be evaluated preoperatively before performing the CAS TKA to prevent the incorrect bone cutting, prosthesis malposition and poor soft tissue balance in sagittal plane.

**Keywords:** Sagittal mechanical axis (SMA), Computer assisted total knee arthroplasty, Registration, Alignment, Landmark, Long standing radiograph

*J Med Assoc Thai 2009; 92 (Suppl 6): S69-74*

**Full text. e-Journal:** <http://www.mat.or.th/journal>

---

Total knee arthroplasty (TKA) has demonstrated a long-term success for the treatment of the late-stage osteoarthritis and other disabling knee disorders. Restoring a near normal mechanical axis was an important factor to improve the implant survival rate<sup>(1-4)</sup>, while the errors in component malposition or

Correspondence to: Hangsaphuk N, Department of Orthopaedic, Sirindhorn Hospital, Bangkok, Thailand

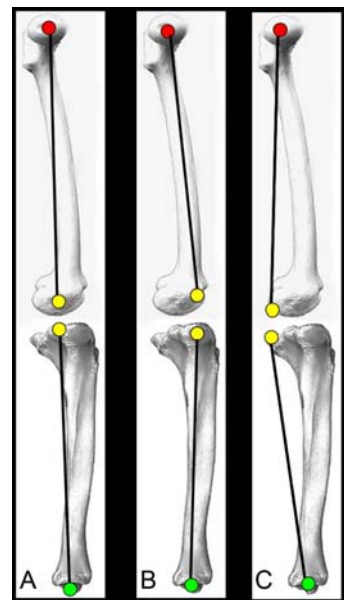
malalignment of the limb increased the failure rate<sup>(4-6)</sup>. Recently, the computer-assisted surgery TKA (CAS-TKA) has been introduced. This technology has been claimed to improve both component and limb alignment<sup>(7)</sup>. In CAS-TKA, the registration of certain landmarks provides data for determining the limb alignment, component rotation and the depth of bone cut. The goal of the lower limb alignment in frontal

plane is the neutral mechanical axis (MA), which the landmarks for centers of the distal femur and the proximal tibia are easily located using the hip-knee-ankle antero-posterior radiograph. In the sagittal plane, most computer navigation systems help the surgeon to register the roof of intercondylar notch of the distal femur and the tibial center in sagittal plane for the sagittal mechanical axis (SMA). However, these landmarks for the centers of the distal femur and the proximal tibia in the sagittal plane are somewhat unclear. If the registrations at the distal femur or proximal tibia are made anterior to true centers, the computer will interpret less full extension. Similarly, with posterior registrations to true centers, more extension is interpreted by the computer (Fig. 1).

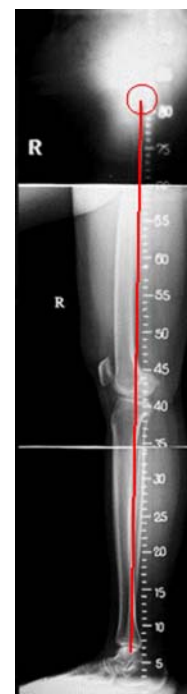The objective of this study was to identify bony landmarks for the center of the distal femur and the proximal tibia in the normal knee which represented the sagittal mechanical axis (SMA) of the lower extremity. These landmarks may help the surgeon in the registration process during performing CAS-TKA in order to create the correct mechanical axis in sagittal plane.

#### Material and Method

We enrolled 70 healthy adults between with the range of the ages from 19 to 45 years old whom had apparently normal knee alignment and full knee extension in the standing position (no flexion contracture or no hyperextension). All subjects had long (hip-knee-ankle), single limb standing, full extended, lateral radiographs using three standard 14 x 17-inch cassette. Of the 70 subjects initially enrolled, 55 subjects whose knees had true lateral radiographic projection and clear femoral head shadow were included in the study and be evaluated. The line connect between the center of the femoral head and the most prominent dome of the talus was drawn in all 55 knees (Fig. 2). Following the concept defining the mechanical axis of the lower extremity in the frontal plane, this line was defined as the mechanical axis of the lower extremity in sagittal plane (SMA). The intersections of the SMA vs. the Blumensaat's line and the SMA vs. the line representing the antero-posterior (AP) width of the most proximal tibial plateau were marked. The intersected point between the SMA and the Blumensaat's line was measured in term of the percentage of the total length of Blumensaat's line. Similarly, the intersected point between the SMA and the most proximal tibial AP width was measured antero-posteriorly as the percentage of the total tibial width



**Fig. 1** Center of the distal femur and the proximal tibia in sagittal plane determine the knee alignment A) True centers result in correct knee extension, B) Too anterior positions result in less full extension or flexion contracture, C) Too posterior positions result in more extension



**Fig. 2** The sagittal mechanical axis (SMA) of lower extremity in healthy normal hip-knee-ankle lateral radiograph

(Fig. 3). All data were analyzed using the SPSS for Windows, version 12. Descriptive statistics were applied for the patients' demographics, relationships of the femoral and tibial intersected points on the SMA.

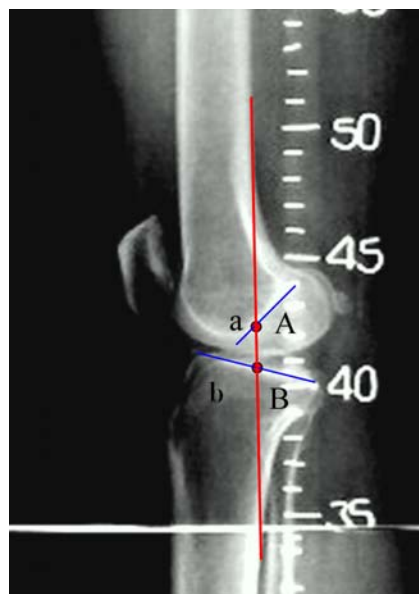
## Results

All of 55 volunteers, 41 volunteers (75%) were male and 14 were female (25%). The mean age was 45.21 years. The average BMI was 25.67. Most of the knees in the study were the right side (32/55). The motion of the knees assessed by the clinical measurement using the goniometer was averaged as 1.7 degrees in the full extension and 141.1 degrees in the end of flexion. The average alignment of the knee in the lateral hip-knee-ankle radiograph was 1.71 degrees, varies from 2 degrees of knee hyperextension to 5 degrees of knee flexion. All of the demographic data were shown in Table 1.

### *Relationship between the sagittal mechanical axis (SMA) of the lower extremity and the distal femur*

All of 55 knees, there were 12 knees (22%) that the SMA passed by the tip of the Blumensaat's line. The SMA of 43 knees (78%) passed posterior to the tip of Blumensaat's line. Most of the SMA passed the Blumensaat's line between 10%-20% of the total length of this line (38/55). There were 4 knees that the SMA passed the Blumensaat's line between 0%-10% of the total length. Only one of the SMA intersected the Blumensaat's line at 20% to 30% of the total length. No any the SMA passed beyond the tip of the Blumensaat's line. The SMA intersected the Blumensaat's line at the point averaged 13% of the

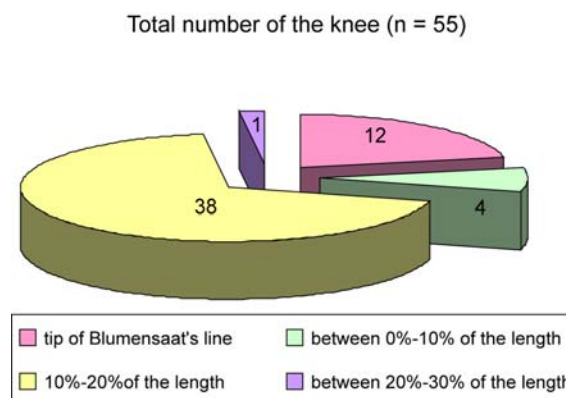
total length of Blumensaat's line, varied from 0% to 22% of the total length of the Blumensaat's line. The distribution of location on the Blumensaat's line related with the SMA was shown in Fig. 4.



**Fig. 3** Relationship of SMA with the Blumensaat's line (a/A) and the most proximal anteroposterior width of tibial plateau on the SMA (b/B) (a: the length from the anterior most of the Blumensaat's line to the intersected point between the SMA and the Blumensaat's line, A: total length of Blumensaat's line, b: the length from the anterior most of tibial plateau to the intersected point between the SMA and the tibial plateau, B: total length of the anteroposterior width of tibial plateau)

**Table 1.** Demographic data of 55 volunteers (55 knees)

Variable	Value
Gender (n)	55
Male	41 (75%)
Female	14 (25%)
Age (mean $\pm$ SD) (year)	45.21 $\pm$ 14.35
BMI	25.67 $\pm$ 2.34
Side of knee	
Right	32 (58%)
Left	23 (42%)
Knee motion (mean $\pm$ SD) (degree)	
Extension	1.71 $\pm$ 2.42
Flexion	141.05 $\pm$ 5.91
Knee alignment in lateral view (mean $\pm$ SD) (degree)	1.71 $\pm$ 1.99



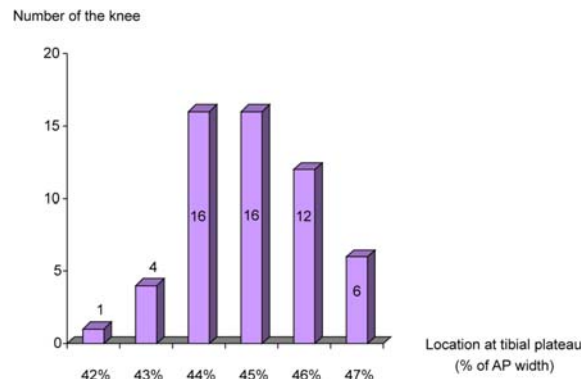
**Fig. 4** Distribution of location on the Blumensaat's line related with the SMA

***The relationship between the sagittal mechanical axis (SMA) of the lower extremity and the proximal tibia (anteroposterior width of tibial plateau)***

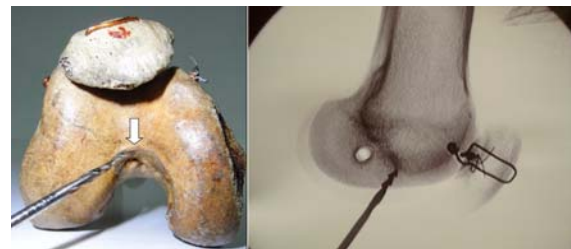The sagittal mechanical axis (SMA) of the lower extremity in 55 knees passed the tibial plateau averaged 45% of the antero-posterior width of the tibial plateau, ranged from 42% to 47% of AP width. The number of the knees classified according to the relationship between the sagittal mechanical axis (SMA) and the antero-posterior width (AP width) of the tibial plateau was shown in Fig. 5.

**Discussion**

The use of a radiograph including the femoral head and the ankle (hip-knee-ankle radiograph) was essential to verify the mechanical axis of the lower extremity both coronal and the sagittal plane<sup>(8)</sup>. This study showed that the landmark represented the center of the distal femur was varies, ranged from the anterior most of the Blumensaat's line to the point lined at the 22% of the total length of Blumensaat's line. Twelve knees had the center of the distal femur at the tip of Blumensaat's line (the SMA passed the tip of Blumensaat's line). Most of the SMA passed posterior to the tip of Blumensaat's line at 10% to 20% of the total length of Blumensaat's line (38/55). The SMA passed the Blumensaat's line at 20% to 30% of the total length of Blumensaat's line was in only one knee. Of this knee, the radiographic alignment was 5 degrees of knee flexion. Flexion alignment of this knees tended the center of the distal femur located in too posterior. The point at 13% of the total length of Blumensaat's line was the average value representing the center of the distal femur. In cadaveric model, the roof of intercondylar notch at the distal femur is compatible with the tip of Blumensaat's line showed on the radiograph (Fig. 6). More flexion of the sagittal mechanical axis of lower extremity or knee alignment is presented on the computer if the point of registration is at the roof of intercondylar notch during performing CAS-TKA. Following the false flexion alignment, the angle of distal femoral bone cutting is slightly more extension than usual. Placement of the femoral prosthesis in extension shortened the longevity of the knee replacement. Moreover, the femoral notching can easily occur. However, Faris and his colleague<sup>(9)</sup> studied on the 623 total knee arthroplasties to determine the relationship between the sagittal plane position of the femoral component and the final range of motion of the prosthetic knee. Their studies showed no correlation between the sagittal plane position of the



**Fig. 5** The relationship between the SMA and the AP width of tibial plateau



**Fig. 6** In cadaveric model, the roof of intercondylar notch is compatible with the tip of Blumensaat's line

femoral component and the final knee range of motion when the femoral component was placed between 20 degrees of flexion and 20 degrees of extension.

At the proximal tibia, the center of the proximal tibia located at the point average 45% of the antero-posterior width of the tibial plateau. Unlike the distal femur, the variety of tibial center was less, ranging from 42% to 47% of AP width of the tibial plateau. None of the SMA passed the posterior half of the tibial plateau. Routine registration at the mid of the tibial plateau during CAS-TKA would create the tibial mechanical axis slightly more extension. Then the posterior tibial slope after bone cutting was more than the expectation affecting the gap balancing and the longevity of the prosthesis.

To be restored nearly the normal mechanical axis of the lower extremity after CAS TKA, the point of registration should be determined preoperatively. Ideally, the radiograph includes the femoral head and the ankle in the normal side (non-operative side) of the

knee in each patient should be taken as a template before performing CAS-TKA to identify the center of the distal femur and the proximal tibia for registration. If the non-operative side is not look like normal, the use of the average values in this study, 13% of total length of Blumensaat's line for registration at distal femur and 45% of the AP width of tibial plateau for registration at the proximal tibia, will be the guide to create the sagittal mechanical axis (SMA) of the lower extremity in performing CAS-TKA. Ree<sup>(10)</sup> recommended the use of the posterior border of the lower femoral diaphysis as the representative of the mechanical axis of the femur in sagittal plane.

The results in this study demonstrated the landmark of the center of the distal femur and the proximal tibia in the sagittal plane for registration to create nearly the normal sagittal mechanical axis of the lower extremity during CAS-TKA. The corrected mechanical axis will prevent the incorrect bone cutting, the malposition of the prosthesis, and the poor soft tissue balance in the sagittal plane. However, the long term clinical outcome related with the position of the prosthesis components in the sagittal plane needs to be followed.

### Conclusion

This study demonstrated the relationship of the sagittal mechanical axis (SMA) of the lower extremity with the distal femur and the proximal tibia in fifty-five normal knees. The sagittal mechanical axis (SMA) was drawn from the center of the femoral head to the most prominent dome of the talus in the lateral view of the long standing hip-knee-ankle radiograph. The center of the distal femur was located at the 13% of the total length of Blumensaat's line. At the proximal tibia, the tibial center was about 45% of the antero-posterior width of the tibial plateau.

### References

1. Bargren JH, Blaha JD, Freeman MA. Alignment in total knee arthroplasty. Correlated biomechanical and clinical observations. *Clin Orthop Relat Res* 1983; (173): 178-83.
2. Hood RW, Vanni M, Insall JN. The correction of knee alignment in 225 consecutive total condylar knee replacements. *Clin Orthop Relat Res* 1981; (160): 94-105.
3. Ranawat CS, Boachie-Adjei O. Survivorship analysis and results of total condylar knee arthroplasty. Eight- to 11-year follow-up period. *Clin Orthop Relat Res* 1988; (226): 6-13.
4. Tew M, Waugh W. Tibiofemoral alignment and the results of knee replacement. *J Bone Joint Surg Br* 1985; 67: 551-6.
5. Vail TP, Lang JE. Surgical Techniques and instrumentation in total knee arthroplasty. In: Scott WN, editor. *Insall & Scott surgery of the knee*. 4<sup>th</sup> ed. Philadelphia: Churchill Livingstone; 2006: 1455-521.
6. Jeffery RS, Morris RW, Denham RA. Coronal alignment after total knee replacement. *J Bone Joint Surg Br* 1991; 73: 709-14.
7. Mason JB, Fehring TK, Estok R, Banel D, Fahrbach K. Meta-analysis of alignment outcomes in computer-assisted total knee arthroplasty surgery. *J Arthroplasty* 2007; 22: 1097-106.
8. Moreland JR, Bassett LW, Hanker GJ. Radiographic analysis of the axial alignment of the lower extremity. *J Bone Joint Surg Am* 1987; 69: 745-9.
9. Faris PM, Ritter MA, Keating EM. Sagittal plane positioning of the femoral component in total knee arthroplasty. *J Arthroplasty* 1988; 3: 355-8.
10. Rees JL, Price AJ, Beard DJ, Robinson BJ, Murray DW. Defining the femoral axis on lateral knee fluoroscopy. *Knee* 2002; 9: 65-8.



---

## การศึกษาตำแหน่งในการกำหนดจุดบริเวณหัวเข่าเพื่อแสดงถึงแนวแกนของขาในแนวด้านข้าง เพื่อใช้ในการผ่าตัดตัดเปลี่ยนผิวข้อเข่าเทียมโดยใช้คอมพิวเตอร์

นราพงษ์ หังสพฤกษ์, อารี ตनावลี

**ภูมิหลัง:** การกำหนดจุดบริเวณรอบหัวเข่าขณะทำการผ่าตัดเปลี่ยนผิวข้อเข่าเทียมโดยใช้คอมพิวเตอร์ เพื่อให้ได้แนวแกนของขาที่มีความสำคัญเป็นอย่างยิ่ง อย่างไรก็ตามยังไม่มีการศึกษากันมากนัก ในส่วนของแนวแกนของขาในแนวด้านข้างทำให้การกำหนดจุดรอบหัวเข่าเพื่อให้ได้แนวแกนของขาในแนวด้านข้างที่ถูกต้องทำได้ยาก ซึ่งอาจนำมาสู่การตัดกระดูกและการวางข้อเทียมที่ผิดตำแหน่งได้

**วัตถุประสงค์:** เพื่อศึกษาความสัมพันธ์ระหว่างแนวแกนของขาทางด้านข้างกับกระดูกต้นขาส่วนปลาย และกระดูกทibia ในหัวเข่าปกติ

**วัสดุและวิธีการ:** ผู้ศึกษาได้ลากเส้นแทนแนวแกนของขาทางด้านข้าง โดยลากจากจุดกึ่งกลางของหัวกระดูกสะโพกกับจุดสูงสุดของกระดูก talus ของอาสาสมัครที่มีหัวเข่าปกติจำนวน 55 เข่า และทำการวัดตำแหน่งที่เส้นแนวแกนของขาในแนวด้านข้างตัด Blumensaat's line โดยรายงานเป็นร้อยละของความยาวของ Blumensaat's line และวัดตำแหน่งที่เส้นแนวแกนของขาในแนวด้านข้างตัดกับ tibial plateau โดยรายงานเป็นร้อยละของความกว้างของ tibial plateau ทางด้านข้าง

**ผลการศึกษา:** จากหัวเข่าทั้งหมด 55 เข่า ที่ศึกษา มีหัวเข่าด้านขวา 32 ข้าง หัวเข่าด้านซ้าย 23 เข่า อาสาสมัครส่วนใหญ่เป็นผู้ชาย 41 คน เป็นผู้หญิง 14 คน โดยมีอายุเฉลี่ย 45 ปี มี BMI เฉลี่ย 25.67 มีแนวแกนของขาในแนวด้านข้างประมาณ 1.7 องศา จากการลากเส้นแนวแกนของขาในแนวด้านข้าง พบว่าแนวแกนของขาตัดผ่าน Blumensaat's line ที่ตำแหน่งประมาณร้อยละ 13 ของความยาวของ Blumensaat's line โดยมีเพียงร้อยละ 22 ของหัวเข่าทั้ง 55 เข่าเท่านั้นที่มีแนวแกนของขาตัดผ่านจุดหน้าสุดของ Blumensaat's line ซึ่งแนวแกนของขาในแนวด้านข้างของหัวเข่าทั้งหมดผ่านบริเวณหนึ่งในสี่ส่วนของ Blumensaat's line ในส่วนของกระดูกทibia พบว่าแนวแกนของขาในแนวด้านข้างผ่าน tibial plateau ที่ตำแหน่งประมาณร้อยละ 45 ของความกว้างของ tibial plateau ซึ่งวัดในแนวหน้า-หลัง

**สรุป:** จุดอ้างอิงสำหรับแนวแกนของขาในแนวด้านข้างของปลายกระดูกต้นขา และกระดูกทibia มีความแตกต่างกันไปในแต่ละบุคคล ดังนั้นการประเมินเพื่อให้ทราบถึงจุดดังกล่าวก่อนที่จะทำการผ่าตัดเปลี่ยนผิวข้อเข่าเทียมโดยใช้คอมพิวเตอร์จึงมีความสำคัญ และจำเป็นเป็นอย่างยิ่งเพื่อที่จะสามารถสร้างแนวแกนของขาในแนวด้านข้างได้ถูกต้องซึ่งช่วยลดความผิดพลาดขณะทำการผ่าตัดในส่วนของการตัดกระดูกและการวางตำแหน่งของข้อเทียม

---