

## Comparison of Short-Term Results between Minimally Invasive Cardiac Surgery and Conventional Median Sternotomy for Atrial Septal Defect Closure

Siam Khajarern, MD<sup>1</sup>, Suchart Chaiyaroj, MD<sup>1</sup>, Montien Ngotngamtaweek, MD<sup>1</sup>, Piya Samarnkatiwat, MD<sup>1</sup>, Parinya Leelayana, MD<sup>1</sup>, Narongrit Kantathut, MD<sup>1</sup>, Piya Chernthanomwong, MD<sup>1</sup>, Pasathorn Pongbanditpisit, MD<sup>1</sup>

<sup>1</sup> Division of Cardiothoracic Surgery, Department of Surgery, Faculty of Medicine Ramathibodi Hospital, Mahidol University, Bangkok, Thailand

**Background:** Median sternotomy (MS) is the standard approach for atrial septal defect (ASD) closure. Recently, minimally invasive cardiac surgery (MICS) for ASD closure via right mini-thoracotomy has been proposed as a promising alternative approach.

**Objective:** To compare short-term results of standard median sternotomy with minimally invasive cardiac surgery for ASD closure in Ramathibodi Hospital.

**Materials and Methods:** The authors retrospectively analyzed 59 patients who underwent surgical ASD closure between January 2014 and July 2020. There were 32 patients in MICS group and 27 patients in MS group. Patient demographic data, intraoperative parameters and postoperative results were collected and compared between the two groups.

**Results:** There were no statistically significant difference in age, gender, body mass index, mean pulmonary artery pressure and left ventricular ejection fraction between the two groups. Intraoperative parameters were not different in ASD size, concomitant procedures and aortic cross-clamp time. Complete atrial septal defect closure were achieved in all patients of both groups without residual defect. Median cardiopulmonary bypass time was significantly longer in MICS group (91 (77, 140) min vs. 76 (51, 98) min  $p=0.006$ ). The success rate of MICS approach was 96.9% (31 of 32 patients) and conversion rate was 3.1% (1 of 32 patients). Postoperative median drainage volume and incidence of patients required PRC transfusion were significantly lower in MICS group (270 (145, 480) ml vs. 460 (300, 660) ml  $p=0.002$ ) and (43% vs. 85%  $p=0.001$ ) respectively. Postoperative ventilation time, pain score, analgesic drug usage, neurological complications, renal complications, wound infection, ICU stay and hospital stay were similar.

**Conclusion:** MICS for ASD closure is a reliable alternative approach that has lower post-operative drainage volume and incidence of PRC transfusion when compared to standard median sternotomy. However, MICS has longer cardiopulmonary bypass time but no difference in post-operative complications and hospital stay.

**Keywords:** Cardiac surgical procedures; Atrial septal defect; Minimally invasive cardiac surgery; Median sternotomy; Comparison; Short-term results; Minimally invasive ASD closure

J Med Assoc Thai 2021;104(Suppl5): S127-32

Website: <http://www.jmatonline.com>

Atrial septal defect (ASD) is a common congenital heart disease in adult with a prevalence of 0.85 per thousand in Canada<sup>(1)</sup>. Adult patient with ASD without treatment result in progressive right ventricular failure due to volume overload and pulmonary hypertension. Many studies revealed that

ASD without intervention, 25% of patient died before 27<sup>th</sup> year and 90% dies before 60<sup>(2)</sup>. The first modern era ASD closure was done by John Gibbon in 1954 with favorable outcome<sup>(3)</sup>. Nowadays, ASD device closure is the standard treatment for secundum ASD closure. However, Surgical closure has a role in those who were not suitable for device closure such as defect  $\geq 37$  mm from echocardiography, less than 5 mm margin from right superior pulmonary vein, atrioventricular valve and coronary sinus, primum ASD and sinus venosus ASD<sup>(4)</sup>. Median sternotomy (MS) is the conventional approach applied in the treatment of ASD closure. However, this method causes extensive injury to sternal bone and increase intensity of postoperative pain. Most of patients has large amount of blood loss and blood transfusion. Time to complete sternal bone healing and return to work may up to 2 and 3 months. Moreover, 20% of median sternotomy wound developed hypertrophic scar formation causes functional, aesthetic and emotional problems<sup>(5)</sup>. Recently, minimally invasive cardiac surgery (MICS) is an alternative approach provide less tissue

### Correspondence to:

Pongbanditpisit P.

Division of Cardiothoracic Surgery, Department of Surgery, Faculty of Medicine Ramathibodi Hospital, Mahidol University, 270 Rama VI Road, Phyathai, Ratchathewi, Bangkok 10400, Thailand.

Phone: +66-83-0788569, Fax: +66-2-2011316

Email: fillnet\_wan@hotmail.com

### How to cite this article:

Khajarern S, Chaiyaroj S, Ngotngamtaweek M, Samarnkatiwat P, Leelayana P, Kantatut N, Chernthanomwong P, Pongbanditpisit P. Comparison of Short-Term Results between Minimally Invasive Cardiac Surgery and Conventional Median Sternotomy for Atrial Septal Defect Closure. J Med Assoc Thai 2021;104(Suppl5): S127-32

[doi.org/10.35755/jmedassocthai.2021.S05.00090](https://doi.org/10.35755/jmedassocthai.2021.S05.00090)

trauma, less blood loss and transfusion, cosmetic advantage and avoid sternotomy complications<sup>(6)</sup>. The present study retrospectively reviewed the results of minimally invasive cardiac surgery (MICS) for ASD closure and compared with conventional median sternotomy (MS) approach in our center.

## Materials and Methods

A total number of 59 consecutive adult patients underwent surgical ASD closure in our institution from January 2014 to July 2020. Inclusion criteria are all adult patients over 15 years old who diagnosed secundum ASD and contraindicated to percutaneous ASD device closure. The patients with previous cardiac surgery through median sternotomy or concomitant with mitral and tricuspid valve disease were also included. Patients who underwent concomitant coronary artery bypass grafting and aortic surgery were excluded. The surgery were performed by 5 attending surgeons in our institution. Surgical approach was decided by surgeon preferences. Computerized tomographic angiography of the whole aorta was selectively performed in the reoperation or suspected of aortopathy cases. There were 27 patients in MS group and 32 patients in MICS group.

The primary outcomes are the success rate of MICS (without conversion to MS) approach and the completeness of atrial septal defect closure. Secondary outcomes included 30 day mortality, aortic cross clamp time, cardiopulmonary bypass time, concomitant procedures, reoperation rate, amount of drainage volume, incidence of PRC transfusion, pain score, ICU stay, hospital stay, cardiac arrhythmia, neurological complications, renal complications and surgical wound complications.

Preoperative demographic data included age, gender, body mass index, ASD size, mean pulmonary artery pressure and left ventricular ejection fraction. Intraoperative and postoperative data were collected by reviewing of medical record and operative note. ASD size were measured intraoperatively with direct measurement. Completeness of atrial septal defect closure was confirmed by intraoperative transesophageal echocardiography. Cardiopulmonary bypass time, aortic cross clamp time and intraoperative PRC transfusion were collected. Total drainage was defined as sum of all chest tube drainage postoperatively until the drain were removed. Intraoperative and intensive care unit (ICU) PRC transfusion was collected. Prolonged mechanical ventilation were defined as patient cannot be extubated within 24 hours postoperatively. Pain score were measured by visual analog scale assessment every 4 hours until 72 hour postoperatively. Analgesic usage defined as morphine equivalence thus there were variation between analgesia in some patients. ICU stay, hospital stay and postoperative complications included 30-day mortality rate, reoperation, cardiac arrhythmia, surgical wound infection, neuro and renal complications were collected. Readmission is defined as unexpected readmitted within 30 day after discharged. The study has been approved by Ethical committee of Ramathibodi hospital, Mahidol University Thailand (COA.

MURA2018/247)

In MS group, standard median sternotomy was performed, the incision from sternal notch to xiphoid (20 to 25 cm) was made. The sternal bone was fully cut in the middle using sternal saw. Central cardiopulmonary bypass was established as usual ascending aortic and bi-caval cannulation. The ascending aorta was cross clamped, antegrade cold crystalloid or blood cardioplegia was administered via aortic root cannula. The right atrium was opened and ASD was closed directly or with bovine pericardial patch. Concomitant procedure included mitral and tricuspid valve surgery was performed as indicated. The sternum was stabilized using 6 interrupted sternal wire ligation.

In MICS group, general anesthesia was performed. Double lumen endotracheal tube was used in all cases. Right internal jugular vein was cannulated as superior vena cava (SVC) drainage with Seldinger technique, then the patients were positioned slightly right-side elevation. External defibrillator pad was used in all cases. After sterile prepping and draping, a small incision (2 to 3 cm) was made in the right inguinal region. Right common femoral artery and vein were dissected anteriorly, no extensive dissection needed for proximal and distal control. Double layers of purse string suture was applied on both vessels. The venous cannula was inserted on the prepared common femoral vein using Seldinger technique with transesophageal echocardiography guidance, the tip was positioned at the inferior vena cava (IVC) to right atrium junction. Two venous cannula was connected to the cardiopulmonary bypass circuit. Arterial cannula was inserted on the prepared common femoral artery, the tip of the cannula was positioned at aortic bifurcation level. Simultaneously, right anterolateral mini-thoracotomy incision (4 to 5 cm) at sub-mammary line or peri-areolar incision was made. The 4<sup>th</sup> intercostal space was entered. A soft tissue retractor was applied to enhanced the exposure, no rib spreader was used to reduced postoperative pain. Right lung was collapsed, carbon dioxide (CO<sub>2</sub>) field flooding was introduced into right thorax through another 8 mm puncture wound at the 7<sup>th</sup> intercostal space. A 5 mm puncture wound was made on the 3<sup>rd</sup> intercostal space for thoracoscopic port. After initiated peripheral cardiopulmonary bypass with vacuum-assisted drainage, under the thoracoscopic visualization, the pericardium was opened longitudinally 2 cm anterior to right phrenic nerve. Long shaft cardioplegic cannula was inserted to the aortic root. SVC was occluded with endo bulldog, IVC was encircled and snared with umbilical tape. Aortic cross clamp was achieved using a Cygnet flexible clamp and then 1,000 ml of modified del Nido cardioplegia (lactated Ringer's base solution for del Nido cardioplegia<sup>(7)</sup>) was perfused via aortic root. Right atrium was opened and the ASD was inspected. Concomitant mitral or tricuspid valve surgery was done as indicated. The ASD was closed directly or with bovine pericardial patch. In case of poor visualization, inadequate exposure, difficult peripheral cannulation, severe lung adhesion or uncontrolled bleeding, the approach will be converted to standard median sternotomy without hesitation.

Categorical variable was reported as frequency and percentage. Comparison between variables were using Chi-square test. Continuous variable was compared using student t-test reported as median and interquartile range in non-normal distribution variable and reported as mean and SD in normal distribution variables.

## Results

### Patient characteristics

Between January 2014 and July 2020, among the patients who received surgical atrial septal defect closure in our institution, 59 patients aged 20 to 73 years old underwent surgical atrial septal defect closure and fulfilled the inclusion criteria to entered the study. Twenty-seven (45.8%) patients underwent ASD closure with median sternotomy approach (MS group) and the remaining 32 (54.2%) patients with minimally invasive cardiac surgery approach (MICS group). Pre-operative characteristics in terms of age, gender, body mass index (BMI), mean pulmonary artery pressure (PAP), left ventricular ejection fraction (LVEF), chronic atrial fibrillation and concomitant valvular disease did not differ between groups (Table 1).

### Intra-operative details

The size of atrial septal defect, concomitant valvular procedures and aortic cross clamp time did not differ between groups. Median cardiopulmonary bypass time was significantly longer in MICS group (97 (77, 140) minutes vs. 76 (51, 98) minutes,  $p=0.006$ ). Complete atrial septal defect closure were achieved in all cases of both groups which was confirmed by intraoperative transesophageal echocardiography. The success rate of MICS approach was 96.9% (31 of 32 patients). There was 1 (3.12%) conversion from MICS to MS approach due to uncontrolled bleeding from IVC, the bleeding site was safely secured

after converted to median sternotomy approach without serious complications. The incidence of intraoperative PRC transfusion was significantly lower in MICS group (14 (43.75%) vs. 23 (85.19%),  $p=0.001$ ) (Table 2).

### Post-operative results

Total drainage was significantly lower in MICS group (270 (145, 480) ml vs. 460 (300, 600) ml,  $p=0.04$ ). There were no significant differences in incidence of postoperative PRC transfusion, prolonged mechanical ventilation, intensive care unit (ICU) stay and postoperative hospital stay between groups. Mean 72-hour postoperative pain score ( $2.59\pm 1.39$  vs.  $2.06\pm 0.90$ , ( $p=0.96$ )) and total morphine equivalence usage (18 (9, 27)) mg vs. 12 (9, 18) mg ( $p=0.081$ )) were slightly lower in MICS group without statistical significance (Table 3).

### Post-operative complications

There were no 30-day mortality, reoperation, neurological and renal complications in both groups. The incidence of postoperative transient atrial arrhythmia was not differ between groups ( $p=0.74$ ). There was 1 (3.7%) readmission from sternal wound dehiscence in MS group while no readmission and wound complications in MICS group but the differences is not statistically significant ( $p=0.458$ ) (Table 4).

## Discussion

The advantages of minimally invasive approach via the right mini-thoracotomy for cardiac surgery have been proved by many authors<sup>(8,9)</sup>. Less bleeding, less transfusions, no sternal wound infection, reducing the time to return to work and improve cosmesis without compromising the short term and long term outcomes. However, to begin the minimally invasive cardiac surgery program, a surgeon who

**Table 1.** Patient demographic data

Characteristics	MS group (n=27)	MICS group (n=32)	p-value
Age (year), mean±SD	44.67±14.80	44.43±16.02	0.955
Gender, n (%)			
Male	10 (37.04)	5 (15.63)	0.060
Female	17 (62.96)	27 (84.38)	0.060
BMI (kg/m <sup>2</sup> ), mean±SD	20.93±6.13	22.38±3.97	0.298
Mean PAP (mmHg), mean±SD	35.18±13.19	29.90±10.59	0.093
LVEF (%), mean±SD	65.85±9.41	65.57±6.59	0.896
Chronic atrial fibrillation, n (%)	5 (18.52)	5 (15.63)	0.768
Concomitant valvular disease, n (%)			
Mitral valve	3 (11.11)	3 (9.38)	0.999
Tricuspid valve	3 (11.11)	3 (9.38)	0.999

MS = median sternotomy; MICS = minimally invasive cardiac surgery; BMI = body mass index; PAP = pulmonary artery pressure; LVEF = left ventricular ejection fraction

**Table 2.** Intraoperative details

	MS group (n=27)	MICS group (n=32)	p-value
ASD size (cm), mean±SD	3.12±1.26	2.57±0.90	0.057
Concomitant valve surgery, n (%)			
Mitral valve	3 (11.11)	3 (9.38)	0.999
Tricuspid valve	3 (11.11)	3 (9.38)	0.999
Aortic cross clamp time (min), median (IQR)	47 (27, 64)	58 (36, 82)	0.106
Cardiopulmonary bypass time (min), median (IQR)	76 (51, 98)	97 (77, 140)	0.006
Conversion from MICS to MS, n (%)		1 (3.12)	-
Intraoperative TEE detectable residual ASD	0	0	-
Incidence of intraoperative PRC transfusion, n (%)	23 (85.19)	14 (43.75)	0.001

MS = median sternotomy; MICS = minimally invasive cardiac surgery; ASD = atrial septal defect; TEE = transesophageal echocardiography

**Table 3.** Postoperative results

	MS group (n=27)	MICS group (n=32)	p-value
Total drainage (ml), median (IQR)	460 (300, 660)	270 (145, 480)	0.004
Incidence of postoperative PRC transfusion, n (%)	0	0	-
Prolonged mechanical ventilation, n (%)	0	0	-
Pain score, mean±SD	2.59±1.39	2.06±0.90	0.096
Total morphine equivalence usage (mg), median (IQR)	18 (9, 27)	12 (9, 18)	0.081
ICU stay(day), median (IQR)	2 (2, 4)	2 (2, 3)	0.297
Hospital stay (day), median (IQR)	6 (5, 7)	6 (5, 7)	0.143

MS = median sternotomy; MICS = minimally invasive cardiac surgery; PRC = packed red cells; ICU = intensive care unit

**Table 4.** Postoperative complications

	MS group (n=27)	MICS group (n=32)	p-value
30 day mortality, n (%)	0	0	-
Reoperation, n (%)	0	0	-
Transient atrial arrhythmia, n (%)	6 (22.22)	6 (18.75)	0.741
Neurological complications, n (%)	0	0	-
Renal complications, n (%)	0	0	-
Wound complications, n (%)	1 (3.7)	0	0.458
Readmission, n (%)	1 (3.7)	0	0.458

MS = median sternotomy; MICS = minimally invasive cardiac surgery

is experienced in conventional median sternotomy approach required about 75 to 100 cases to overcome the learning curve<sup>(10)</sup>.

ASD closure is one of the most simplest cardiac surgery for starting minimally invasive program in

unexperienced cardiac center. Several studies of MICS for ASD closure have been performed, and most results have revealed comparable outcomes with conventional median sternotomy approach<sup>(11-13)</sup>. Our center, Ramathibodi Hospital had started MICS program since 2014, until now, more than

250 cases of MICS had been performed, the very first case was MICS for ASD closure.

This retrospective study reviewed the results of our early experience in MICS for ASD closure and compared the outcomes with conventional median sternotomy. Total number of 59 patients, 27 patients in MS group and 32 patients in MICS group, underwent surgical ASD closure by 5 different attending surgeons at the same period of time. Three surgeons performed only MS approach and 2 surgeons always performed MICS, so there were unavoidable selection bias. However, the patients characteristics were similar in both groups.

Our results revealed that the MICS group experienced slightly longer CPB time, because of early learning curve period. The restricted operative field, long-shaft instruments handling and lack of 3 dimensional visualization from camera monitor also results in longer operative time<sup>(14)</sup>. However, successfulness of the procedures by MICS can be achieved with 2 to 3% incidence of conversion. The main reason conversion is either bleeding or other medical conditions<sup>(15)</sup>. In the present study, the atrial septal defect were completely closed without residual lesions in all cases. The concomitant valve surgery were successfully performed without compromising. Incidence of intraoperative PRC transfusion significantly lower in MICS group results from smaller incision, less tissue trauma and avoidance of sternal injury<sup>(16)</sup>.

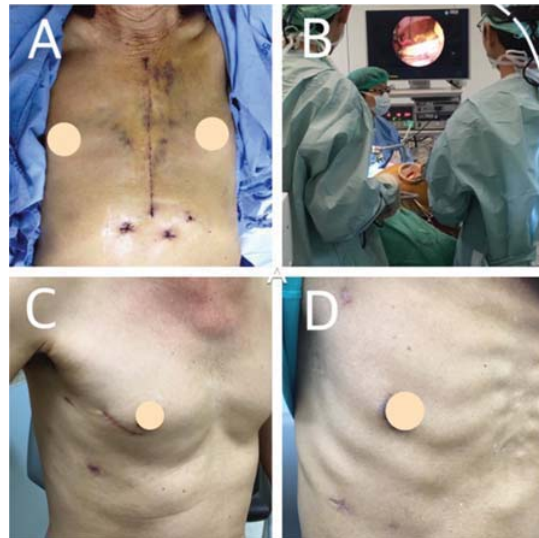
Post-operative drain volume were significantly lower in MICS group supported the hypothesis of less tissue injury. Mean 72 hour post-operative pain score and total morphine equivalence usage tend to lower in MICS group but did not statistically significant. However, after MICS, earlier mobilization is possible because of a better stability of the bony thorax, resulting in lower pain levels<sup>(17)</sup>.

Post-operative complications were similar between groups in terms of 30-day mortality, reoperation, mechanical ventilation time, ICU stay, hospital stay, renal and neurological complications. There has been some concerned of increasing stroke rate after MICS regarding to peripheral perfusion. However, numerous recent reports revealed no significant differences in neurologic events when compared with the conventional sternotomy approach<sup>(18,19)</sup>. MICS served a smaller incision and promising cosmesis (Figure 1). Vanermen reported that 99.3% of his patients feel they have an aesthetically pleasing scar and 46% are back at work within 3 weeks<sup>(20)</sup>. There was an important study reported that those who have had a MICS approach as their second procedure all felt that their recovery was more rapid and less painful than their previous sternotomy<sup>(21)</sup>.

Despite all aspects of those reported in the present study, patient's post-operative pain score and total morphine equivalence usage were not significantly different between both groups according to small sample size.

Patient's satisfaction of surgical wounds and also recovery time still needs long-term follow-up.

A multicenter randomized controlled study with larger sample size of patients should be performed to overcome



**Figure 1.** A) Conventional median sternotomy scar, B) Operative setting of minimally invasive cardiac surgery, C) Minimally invasive cardiac surgery scar, D) Peri-areolar incision.

the limitations of this study.

### Conclusion

MICS via right mini-thoracotomy is a reliable alternative approach to standard median sternotomy for ASD closure. The results demonstrated similar morbidities and mortality between groups, and favored MICS in lower chest tube drainage and incidence of PRC transfusion.

### What is already known in this topic?

MICS for ASD closure have revealed comparable outcomes with conventional median sternotomy approach.

### What this study adds?

This is early experience first retrospective comparison of MICS and MS for ASD closure in Thailand.

### Potential conflicts of interest

The authors declare no conflict of interest.

### References

1. Marelli AJ, Ionescu-Ittu R, Mackie AS, Guo L, Dendukuri N, Kaouache M. Lifetime prevalence of congenital heart disease in the general population from 2000 to 2010. *Circulation* 2014;130:749-56.
2. Campbell M. Natural history of atrial septal defect. *Br Heart J* 1970;32:820-6.
3. Gibbon JH Jr. Application of a mechanical heart and lung apparatus to cardiac surgery. *Minn Med*

- 1954;37:171-85.
4. Du ZD, Hijazi ZM, Kleinman CS, Silverman NH, Larntz K. Comparison between transcatheter and surgical closure of secundum atrial septal defect in children and adults: results of a multicenter nonrandomized trial. *J Am Coll Cardiol* 2002;39:1836-44.
  5. Srivastava DK. Median sternotomy scar outcome: our experience. *J Cosmetol* 2019;3:000116.
  6. Modi P, Hassan A, Chitwood WR Jr. Minimally invasive mitral valve surgery: a systematic review and meta-analysis. *Eur J Cardiothorac Surg* 2008;34:943-52.
  7. Kantathut N, Chertnanomwong P, Khajareern S, Leelayana P. Lactated Ringer's as a base solution for delnido cardioplegia. *J Extra Corpor Technol* 2019;51:153-9.
  8. Van Praet KM, Stamm C, Sundermann SH, Meyer A, Unbehaun A, Montagner M, et al. Minimally invasive surgical mitral valve repair: State of the art review. *Interv Cardiol* 2018;13:14-9.
  9. Glauber M, Miceli A, Canarutto D, Lio A, Murzi M, Gilmanov D, et al. Early and long-term outcomes of minimally invasive mitral valve surgery through right minithoracotomy: a 10-year experience in 1604 patients. *J Cardiothorac Surg* 2015;10:181.
  10. Vo AT, Nguyen DH, Van Hoang S, Le KM, Nguyen TT, Nguyen VL, et al. Learning curve in minimally invasive mitral valve surgery: a single-center experience. *J Cardiothorac Surg* 2019;14:213.
  11. Ryan WH, Cheirif J, Dewey TM, Prince SL, Mack MJ. Safety and efficacy of minimally invasive atrial septal defect closure. *Ann Thorac Surg* 2003;75:1532-4.
  12. Chu MW, Losenno KL, Fox SA, Adams C, Al-Habib H, Guo R, et al. Clinical outcomes of minimally invasive endoscopic and conventional sternotomy approaches for atrial septal defect repair. *Can J Surg* 2014;57:E75-81.
  13. Sabate Rotes A, Burkhart HM, Suri RM, Grogan M, Taggart NW, Li Z, et al. Minimally invasive video-assisted surgical closure of atrial septal defects: a safe approach. *World J Pediatr Congenit Heart Surg* 2014;5:527-33.
  14. Chitwood WR Jr, Wixon CL, Elbeery JR, Francalancia NA, Lust RM. Minimally invasive cardiac operation: adapting cardioprotective strategies. *Ann Thorac Surg* 1999;68:1974-7.
  15. Yadava OP, Casselman F. Conversion in minimally invasive cardiac surgery. *Indian J Thorac Cardiovasc Surg* 2019;35:135.
  16. Soltesz EG, Cohn LH. Minimally invasive valve surgery. *Cardiol Rev* 2007;15:109-15.
  17. Walther T, Falk V, Metz S, Diegeler A, Battellini R, Autschbach R, et al. Pain and quality of life after minimally invasive versus conventional cardiac surgery. *Ann Thorac Surg* 1999;67:1643-7.
  18. Speziale G, Nasso G, Esposito G, Conte M, Greco E, Fattouch K, et al. Results of mitral valve repair for Barlow disease (bileaflet prolapse) via right minithoracotomy versus conventional median sternotomy: a randomized trial. *J Thorac Cardiovasc Surg* 2011;142:77-83.
  19. Iribarne A, Easterwood R, Russo MJ, Wang YC, Yang J, Hong KN, et al. A minimally invasive approach is more cost-effective than a traditional sternotomy approach for mitral valve surgery. *J Thorac Cardiovasc Surg* 2011;142:1507-14.
  20. Casselman FP, Van Slycke S, Wellens F, De Geest R, Degrieck I, Van Praet F, et al. Mitral valve surgery can now routinely be performed endoscopically. *Circulation* 2003;108 Suppl 1:II48-54.
  21. Felger JE, Chitwood WR Jr, Nifong LW, Holbert D. Evolution of mitral valve surgery: toward a totally endoscopic approach. *Ann Thorac Surg* 2001;72:1203-8; discussion 8-9.