

# Outcomes of Steroid Therapy in Combination with Endoscopic Optic Nerve Decompression Surgery for Direct Traumatic Optic Neuropathy: A Case-Series

Suntaree Thitiwichienlert MD<sup>1</sup>, Raywat Noiphithak MD<sup>2</sup>

<sup>1</sup> Department of Ophthalmology, Faculty of Medicine, Thammasat University, Pathum Thani, Thailand

<sup>2</sup> Department of Neurosurgery, Faculty of Medicine, Thammasat University, Pathum Thani, Thailand

**Background:** Direct traumatic optic neuropathy (TON) carries a poor prognosis. However, the outcome of this injury is diverse and is related to time to treatment and treatment protocol.

**Objective:** To evaluate the outcomes of the combined treatment protocol in patients with direct TON.

**Materials and Methods:** The authors retrospectively reviewed the medical records of patients between January 2015 and August 2019. Main outcome was visual acuity (VA) improvement after the treatment.

**Results:** Thirteen patients (15 eyes) were included. The mean age was 38.61 years with a range of 13 to 65 years. Initial VA varied from no light perception (NPL) in seven eyes of six patients, light perception (PL) in one eye, counting fingers in two eyes, 20/200 in three eyes, and 20/60 in two eyes. Average timing to treatment was 2.8 days (range 0 to 7 days). There were no side effects of high-dose corticosteroids treatment in all patients. During a follow-up period of three months, six of 13 patients (46.1%) had VA improvement.

**Conclusion:** Despite poor prognosis of direct TON, the combined treatment protocol provides a favorable successful rate with most patients on having stable vision, and some having visual improvement from reducing intracanalicular pressure of the optic nerve.

**Keywords:** Endoscopic optic nerve decompression; Traumatic optic neuropathy; Visual acuity; Case series

Received 1 March 2021 | Revised 2 June 2021 | Accepted 4 June 2021

J Med Assoc Thai 2021;104(7):1166-71

Website: <http://www.jmatonline.com>

Traumatic optic neuropathy (TON) is an uncommon condition of visual loss, found in 5% of patients with head injury<sup>(1)</sup>. It can be classified into direct and indirect injuries to the optic nerve. The former is a relatively rare condition caused by avulsion, penetration, or impingement of the optic nerve, whereas the latter is a condition associating with force transmitting to injure the nerve<sup>(2,3)</sup>. Consequently, the secondary damage of the optic nerve occurs because of tissue edema and increased pressure inside the optic nerve sheath, compromising vascular supply<sup>(4)</sup>. This is specifically in the intracanalicular

portion of the optic nerve where the nerve is surrounded by narrow bony canal<sup>(5)</sup>. Tissues become swollen and compressed more on the surrounding of the optic nerve tissue to cause more damage as well as the compartment syndrome of the optic canal. This damage results in retinal ganglion cell death<sup>(1,2)</sup>.

For a long time, attempts have been made for treatment of TON based on prevention of further damage from tissue swelling. These consisted of corticosteroid therapy, surgical decompression, and combination of both medical and surgical treatments<sup>(6)</sup>. However, the optimal management of TON remains unclear due to lack of evidence from large prospective clinical trial<sup>(7,8)</sup>. In addition, the previous studies mostly involved patients with indirect TON or did not clearly show the treatment outcomes classified by each type of TON<sup>(9-11)</sup>.

Direct TON, despite poor prognosis, has different degree of visual outcome. This is associated with degree of injury, ranging from impingement to transection of the nerve. Moreover, the diverse outcome of direct TON is related with time to treatment and treatment protocol of each institution<sup>(9,12)</sup>. In the present study, the authors present the outcomes of patients with

## Correspondence to:

Thitiwichienlert S.

Department of Ophthalmology, Faculty of Medicine, Thammasat University, Pathum Thani 12120, Thailand.

Phone: +66-2-9269957, Fax: +66-2-9869212

Email: [punoipunoi@hotmail.com](mailto:punoipunoi@hotmail.com)

## How to cite this article:

Thitiwichienlert S, Noiphithak R. Outcomes of Steroid Therapy in Combination with Endoscopic Optic Nerve Decompression Surgery for Direct Traumatic Optic Neuropathy: A Case-Series. J Med Assoc Thai 2021;104:1166-71.

[doi.org/10.35755/jmedassocthai.2021.07.12657](https://doi.org/10.35755/jmedassocthai.2021.07.12657)

direct TON at the present study institution.

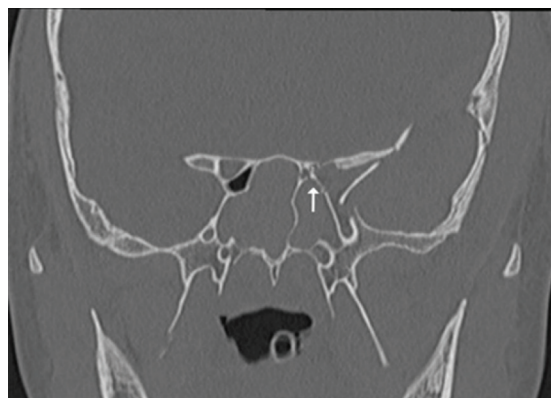## Materials and Methods

After approval of the Institutional Review Board (MTU-EC-OP-2-158/62), the authors retrospectively reviewed the medical records of patients with direct TON between January 2015 and August 2019, following the combined treatment protocol, including intravenous high-dose corticosteroid therapy, endoscopic optic decompression, and topical steroid application. Data, including age, gender, timing of injury, eye examinations, associating injuries, pre- and postoperative neuroimaging, intraoperative records, complications of treatment, and final visual acuity (VA), were collected. The informed consents were obtained from all patients.

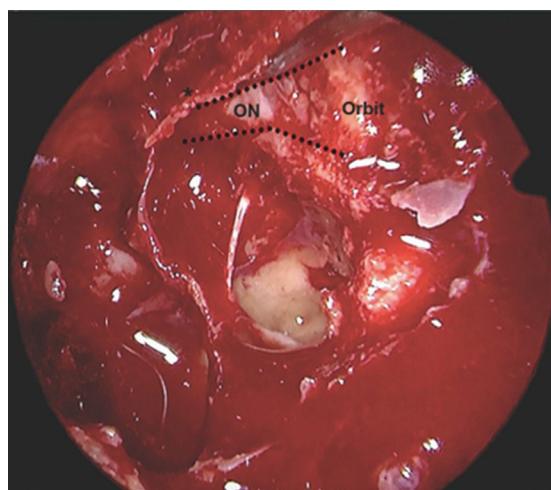
All patients were diagnosed of direct TON based on clinical examinations by neuro-ophthalmologist as well as preoperative neuroimaging from computed tomography (CT) scan of brain and orbit (Figure 1). After the diagnosis, the treatment was given within seven days initially with high dose of intravenous methylprednisolone (IVMP) at a dose of 1 g/day for three days. Subsequently, endoscopic optic nerve decompression was performed after completion of steroids regimen or immediately if the patient experienced visual deterioration during the treatment. Follow-up was required at three months after the treatment. The authors excluded patients with associating orbital injuries causing visual loss and those who had contraindication of high-dose corticosteroids treatment or surgical decompression. An independent observer assessed clinical and surgical data. The authors reported this retrospective consecutive case-series following the PROCESS guideline<sup>(13)</sup>.

## Surgical procedure

Endoscopic optic decompression was performed by a single neurosurgeon in the present study tertiary care academic institution. After preparation of nasal cavities with povidone irrigation and decongestant packing, the surgery was carried out utilizing 4-mm diameter and 18 cm in length, Hopkin II, 0°, 30°, 45° rod-lens endoscopes (Karl Sotrz Endoscopy, Tuttlingen, Germany). The superior turbinate was removed via a uni-nostril approach in the affected side. Then, posterior ethmoidectomy and sphenoidotomy were performed. In case of bilateral TON or inadequate exposure, bi-nostril approach was required with posterior septectomy and bilateral sphenoidotomy. After the optic canal was completely identified, fracture fragments and bone covering



**Figure 1.** CT scan shows comminuted fracture of sphenoid bone compromising left optic canal (white arrow).



**Figure 2.** Intraoperative view of the exposure of left optic nerve (dotted line) after decompression from bony fragment (asterisk).

optic canal were carefully removed exposing the intracanalicular part of optic nerve sheath. A 40 mg of Triamcinolone acetonide (40 mg/mL) (Kenacort) was infused into the exposed optic canal. Then, an absorbable material (Gelfoam) soaked with the rest of Triamcinolone acetonide was pasted over the affected optic nerve sheath (Figure 2). In case of cerebrospinal fluid (CSF) leak, surgical repair was performed by artificial dura, fat graft, and nasoseptal flap as appropriated. Bleeding was stopped with warm saline irrigation and hemostatic agents. Nasal packing was not used after the surgery.

## Results

Fifteen patients were first enrolled in the present study, but data of two patients were lost. So, thirteen

**Table 1.** A summary data of 13 patients with direct TON

Case No.	Age (years)	Sex	Timing (days)	Laterality	Initial VA	Associated injury	Site of optic canal fracture	Degree of injury	Complication	Final VA
1	15	M	0	Left	Fc 3 feet	Orbital fracture, EDH	Medial wall	Nerve compression	No	Fc 3 feet
2	21	M	1	Left	20/60	Orbital fracture	Medial wall	None	No	20/40
3	22	M	5	Bilateral	NPL, NPL	Orbital fracture, SAH, skull base fracture	Superior and medial walls	Nerve sheath tear and nerve contusion	Bilateral anosmia	NPL, NPL
4	27	M	2	Left	NPL	Orbital fracture	Medial wall	Nerve sheath hematoma	No	PL
5	33	M	4	Left	Fc 1 foot	Orbital fracture, skull base fracture, sinus injury	Medial wall	Nerve sheath hematoma	No	20/200
6	29	M	7	Right	PL	Orbital fracture, cerebral contusion	Superior and medial walls	Nerve sheath hematoma	No	PL
7	53	M	2	Left	NPL	Orbital fracture	Superior and lateral walls	Nerve sheath hematoma	No	NPL
8	33	M	4	Left	NPL	Cerebral contusion, sinus injury	Superior and medial walls	Nerve sheath hematoma	No	NPL
9	64	F	3	Bilateral	Right: 20/200 Left: NPL	EDH	Right: medial wall Left: superior and medial walls	Right: nerve compression Left: nerve sheath hematoma	No	Right: 20/60 Left: NPL
10	63	F	4	Right	20/200	Orbital fracture, skull base fracture	Medial wall	Nerve sheath hematoma	No	20/200
11	64	F	4	Right	20/200	Orbital fracture, SDH, sinus injury	Medial wall	Nerve sheath tear	CSF rhinorrhea	20/100
12	65	M	1	Left	NPL	Orbital fracture, SDH	Superior and medial walls	Nerve sheath tear and nerve contusion	No	NPL
13	13	M	0	Left	20/60	Orbital fracture, EDH	Medial wall	Nerve compression	No	20/40

VA=visual acuity; M=male; F=female; NPL=no light perception; PL=light perception; EDH=epidural hematoma; SAH=subarachnoid hemorrhage; SDH=subdural hematoma

patients, including 15 eyes, were included in the study. The mean age was 38.61 years with a range of 13 to 65 years. Ten (76.9%) were male and three (23.1%) were female. The most common etiology of TON is a motor vehicle accident in 12 patients (92.3%), followed by fall in one patient (7.7%). Direct TON was diagnosed in the left eye of eight (61.5%) patients and in the right eyes of three (23.1%) patients, whereas two (15.4%) patients had bilateral TON. Initial VA varied from no light perception (NPL) in seven eyes of six patients, light perception (PL) in one eye, counting fingers in two eyes, 20/200 in three eyes, and 20/60 in two eyes. All patients had associated injuries including orbital wall fracture in 11 patients (84.63%), skull base fracture in three patients (23%), cerebral contusion in two patients (15.4%), epidural hematoma (EDH) in three patients (23%), subdural hematoma (SDH) in two patients (15.4%), subarachnoid hemorrhage (SAH) in one patient (7.7%), and sinus injury in three patients (23%).

Average timing to treatment was 2.8 days (range 0 to 7 days). There were no side effects of high-dose corticosteroids treatment occurred in all patients. Intraoperative findings demonstrated optic canal fracture with bony fragments compressing optic nerve

in 12 patients. One patient had fracture compromising optic canal on preoperative CT scan but there was no obvious impingement to the nerve during the surgery. Regarding the degree of optic nerve damage, the authors found optic nerve sheath hematoma in seven patients, optic nerve sheath tear in three patient, and optic nerve contusion in two patients. Postoperative complications occurred in two patients, including one with bilateral anosmia, and one with CSF rhinorrhea.

All patients had follow-up interval of one week, one month, and three months after the surgery. The visual improvement was considered if there was an increase of one line or more on the Snellen acuity chart, or if their VA had increased one level such as from NPL to PL, from PL to hand motion, or from hand motion to counting finger. During a follow-up period of three months after surgery, six of 13 patients (46.1%) had gradual visual improvement. For six patients with seven eyes with NPL before surgery, one patient (one eye) had final VA of PL while five patients with six eyes still had NPL. For eight patients with eight eyes with some residual vision before surgery, five patients with five eyes had visual improvement and three patients with three eyes remained stable (Table 1).

## Discussion

TON, especially the direct injury to the nerve, results in unfavorable outcome because of the irreversible lesion of primary injury. Therefore, treatment, either medication or surgery, has been attempted to reduce the further damage of free radical and inflammatory reactions causing optic nerve swelling from the process of secondary injury<sup>(4)</sup>.

High-dose corticosteroid provides an antioxidant effect by inhibiting free radical-induced lipid peroxidation. It has been applied for the treatment of CNS injuries, including brain, spinal cord, and optic nerve, to reduce the devastating effect of inflammatory process<sup>(14,15)</sup>. However, the effectiveness of high-dose corticosteroids remains controversial, and it can cause side effects of gastrointestinal bleeding, sepsis, respiratory complications, or worsening outcomes of the head injury.

Surgical decompression for TON aims to increase the space, similar to the concept compartment syndrome. This procedure help reducing edematous pressure resulting in reversing ischemia and axonal conduction of the optic nerve<sup>(10)</sup>. For decades, several techniques of optic nerve decompression have been described, such as transfrontal craniotomy, external transthemoidal, or transorbital approaches<sup>(16-19)</sup>. Currently, an endoscopic endonasal decompression technique has evolved from the advent of endoscopic skull base techniques and has been widespread used as a minimally invasive technique for the optic nerve decompression<sup>(12,20,21)</sup>. This technique allows adequate exposure of the optic canal in a similar degree to the traditional surgery. Moreover, this less invasive technique yields better outcomes in term of shorter duration of surgery, faster recovery, and better cosmesis, compared with the conventional approaches. Therefore, endoscopic decompression is considered the standard for the treatment of optic nerve injury at present.

The International Optic Nerve Trauma Study (IONTT) found no clear benefit for either corticosteroids or optic canal decompression in indirect TON<sup>(9)</sup>. The present study also concluded that surgical decompression had a limited role and supported the use of surgery in certain scenarios such as when a bony fragment is abutting to optic nerve or in the case of the nerve sheath hematoma. However, there is not enough data supporting surgery for indirect TON. In addition, several published studies showed that the rates of spontaneous improvement have ranged 20% to 57%<sup>(22)</sup>. Therefore, the appropriate treatment for indirect TON can be

through observation, medication, and considering surgery in case of an optic canal fracture, a hematoma, or facial fractures. In contrast, patients with direct TON who had bony fragment compressing the nerve, a combination of treatment modalities including high-dose corticosteroids, surgical decompression, and topical steroids may provide some benefits if there were no contraindications to either of the combined treatment.

Previous studies reported the visual improvement rate of combined treatment between 40.6% to 83.3%<sup>(23,24)</sup>. He et al reported the outcome of endoscopic optic canal decompression in 11 adults with TON in their retrospective study. All cases received IVMP at a dose of 20 mg/kg/day for two to three days. The VA improvement rate was about 45.5% and they concluded that endoscopic decompression of the optic canal is an effective treatment of TON<sup>(25)</sup>. Previous prospective study reported the outcome of endoscopic trans-ethmosphenoid optic canal decompression in 62 children with indirect TON. All cases received IVMP at a dose of 20 mg/kg and mouse-derived nerve growth factor (NGF) at a dose of 30 µg/mL/day for three days. The overall VA improvement rate of combined treatment was about 54.84% and they concluded that patients with residual vision had better postoperative visual prognosis and benefited more from optic canal decompression<sup>(11)</sup>.

Preoperative VA of NPL, presence of optic canal fracture, and orbital wall fracture were the significant factors of poor visual outcome in patients with TON<sup>(26,27)</sup>. Moreover, previous study reported the time lapse between injury and treatment was the other significant prognostic factor. Rajiniganth et al reported the visual outcome of a combined therapy protocol of methylprednisolone injections and endoscopic optic nerve decompression in 44 patients with indirect TON in their prospective study. The visual improvement rate was about 70% of the patients in whom treatment was started before seven days after the injury, whereas the visual improvement was only 24% in whom treatment was started after seven days. They concluded that the combined therapy protocol results in a better visual outcome when treatment is started within seven days of injury<sup>(1)</sup>. In cases the patients present early, with NPL or especially in cases with unclear optic canal fracture from CT scan, the risk benefits must be discussed before starting the treatment. In the present study, all patients received treatment within seven days of injury, but almost half of them had initial VA of NPL, and all patients had optic canal fractures illustrated

on preoperative CT scan. However, the authors found one patient had no obvious compression from bony fragment during the surgery. This may be associated with good visual improvement in this patient. As a result, the authors reported a postoperative visual improvement of 46.1%, comparable with the previous reports<sup>(23,24)</sup>. However, the present study success rate is less achieved than that of the children, this is due to the study in children included indirect TON only<sup>(11)</sup>. Moreover, the present study was conducted in a tertiary center where most of the cases were more complicated. The highly heterogenous presentation of TON patients also affected the success rate.

A systematic literature review showed that the visual evoked potential (VEP) has diagnostic value in patients with unclear onset of injury, unreliable pupillary light responses, or bilateral optic nerve involvement. In addition, VEP allows predicting the prognosis of vision. Visual recovery may be possible in patients with better response to VEP<sup>(28)</sup>. However, VEP has some limitations in clinical practice. First, VEP is an objective test to quantify the functional integrity of the visual pathways from retina via the optic nerve, chiasm, tract, optic radiation to the occipital cortex, which is not specific to the site of etiology. Therefore, VEP for detecting of TON may mislead in patients with concurrent brain injury<sup>(29)</sup>. Second, equipping and transporting of VEP is difficult for patients with multiple injuries. In the present study, the authors did not test the VEP due to these limitations.

Postoperative complications occurred in two patients as one patient with bilateral anosmia and the other with CSF rhinorrhea. Nevertheless, these were related to the consequence of such injuries. The former case had fracture of anterior skull base, which may cause injury to the olfactory nerve, whereas the authors found CSF leak from optic nerve sheath tear during the surgery in the latter case. However, the CSF rhinorrhea was spontaneous resolved on postoperative day 3.

Limitations of the present study include retrospective nature and small sample size. Recruitment of the case was difficult because the low incidence of TON. Moreover, the diagnosis was troublesome, especially in unconscious patients. However, the present study exclusively reported the outcomes of combined treatment protocol for direct TON. Although several factors may confound the outcomes of direct TON, such as initial VA or associating injury, treatment should be considered in patients with evidence of nerve compression on

radiographic findings. The authors suggested that the study should be done with a prospective cohort.

## Conclusion

In conclusion, despite poor prognosis of direct TON, the combined treatment protocol provides a favorable successful rate with most patients having stable vision and some patients having visual improvement from reducing intracanalicular pressure of the optic nerve.

## What is already known on this topic?

The role of corticosteroids as a medical decompression based on the hypothesis that major central nervous system (CNS) injury causes pathological free radical reactions, high dose corticosteroids are antioxidants that inhibit free radical-induced lipid peroxidation, helping to reduce inflammation and edema in the optic canal. The role of surgical decompression based on the hypothesis that when TON occurs, tissue swelling in the optic canal is like a mechanism of compartment syndrome, so surgery has been done to increase space to reduce edematous pressure and may reverse ischemia and axonal conduction. Therefore, in patients with direct TON who had optic canal fracture or bony fragment that compress over the nerve, combined high dose corticosteroids and decompression surgery may be useful if there are no contraindications to either of the combined treatment.

## What this study adds?

This study presents the outcomes of patients with direct TON at the authors' institution and revealed a better outcome for the improvement of VA. To the best of the authors' knowledge, this study is one of the most exclusive case-series of patients with direct TON that received specific combined treatment protocol.

## Acknowledgement

The present study was funded by the Faculty of Medicine, Thammasat University.

## Conflicts of interest

The authors declare that there is no conflict of interest.

## References

1. Rajiniganth MG, Gupta AK, Gupta A, Bapuraj JR. Traumatic optic neuropathy: visual outcome following combined therapy protocol. Arch Otolaryngol Head Neck Surg 2003;129:1203-6.

2. Steinsapir KD, Goldberg RA. Traumatic optic neuropathy. *Surv Ophthalmol* 1994;38:487-518.
3. Steinsapir KD, Goldberg RA. Traumatic optic neuropathy: an evolving understanding. *Am J Ophthalmol* 2011;151:928-33.e2.
4. Levkovitch-Verbin H. Animal models of optic nerve diseases. *Eye (Lond)* 2004;18:1066-74.
5. Osborne NN, Chidlow G, Layton CJ, Wood JP, Casson RJ, Melena J. Optic nerve and neuroprotection strategies. *Eye (Lond)* 2004;18:1075-84.
6. Kumaran AM, Sundar G, Chye LT. Traumatic optic neuropathy: a review. *Craniofac Trauma Reconstr* 2015;8:31-41.
7. Yu-Wai-Man P, Griffiths PG. Surgery for traumatic optic neuropathy. *Cochrane Database Syst Rev* 2005;(4):CD005024.
8. Yu-Wai-Man P, Griffiths PG. Surgery for traumatic optic neuropathy. *Cochrane Database Syst Rev* 2013;6:CD005024.
9. Levin LA, Beck RW, Joseph MP, Seiff S, Kraker R. The treatment of traumatic optic neuropathy: the International Optic Nerve Trauma Study. *Ophthalmology* 1999;106:1268-77.
10. Oh HJ, Yeo DG, Hwang SC. Surgical treatment for traumatic optic neuropathy. *Korean J Neurotrauma* 2018;14:55-60.
11. Yu B, Chen Y, Ma Y, Tu Y, Wu W. Outcome of endoscopic trans-ethmoidal optic canal decompression for indirect traumatic optic neuropathy in children. *BMC Ophthalmol* 2018;18:152.
12. Kountakis SE, Maillard AA, El-Harazi SM, Longhini L, Urso RG. Endoscopic optic nerve decompression for traumatic blindness. *Otolaryngol Head Neck Surg* 2000;123:34-7.
13. Agha RA, Fowler AJ, Rajmohan S, Barai I, Orgill DP. Preferred reporting of case series in surgery; the PROCESS guidelines. *Int J Surg* 2016;36:319-23.
14. Bains M, Hall ED. Antioxidant therapies in traumatic brain and spinal cord injury. *Biochim Biophys Acta* 2012;1822:675-84.
15. Saxena R, Singh D, Menon V. Controversies in neuro-ophthalmology: steroid therapy for traumatic optic neuropathy. *Indian J Ophthalmol* 2014;62:1028-30.
16. Guyer DR, Miller NR, Long DM, Allen GS. Visual function following optic canal decompression via craniotomy. *J Neurosurg* 1985;62:631-8.
17. Sewall EC. External operation on the ethmoidalphenoidfrontal group of sinuses under local anesthesia: technique for removal of part or optic foramen wall for relief of pressure on optic nerve. *Arch Otolaryngol* 1926;4:377-411.
18. Kennerdell JS, Amsbaugh GA, Myers EN. Transantral-ethmoidal decompression of optic canal fracture. *Arch Ophthalmol* 1976;94:1040-3.
19. Knox BE, Gates GA, Berry SM. Optic nerve decompression via the lateral facial approach. *Laryngoscope* 1990;100:458-62.
20. Chow JM, Stankiewicz JA. Powered instrumentation in orbital and optic nerve decompression. *Otolaryngol Clin North Am* 1997;30:467-78.
21. Luxenberger W, Stammberger H, Jebeles JA, Walch C. Endoscopic optic nerve decompression: the Graz experience. *Laryngoscope* 1998;108:873-82.
22. Samardzic K, Samardzic J, Janjetovic Z, Samardzic I, Sekelj S, Latic-Hodzic L. Traumatic optic neuropathy - to treat or to observe? *Acta Inform Med* 2012;20:131-2.
23. Yang QT, Zhang GH, Liu X, Ye J, Li Y. The therapeutic efficacy of endoscopic optic nerve decompression and its effects on the prognoses of 96 cases of traumatic optic neuropathy. *J Trauma Acute Care Surg* 2012;72:1350-5.
24. Li H, Zhou B, Shi J, Cheng L, Wen W, Xu G. Treatment of traumatic optic neuropathy: our experience of endoscopic optic nerve decompression. *J Laryngol Otol* 2008;122:1325-9.
25. He ZH, Lan ZB, Xiong A, Hou GK, Pan YW, Li Q, et al. Endoscopic decompression of the optic canal for traumatic optic neuropathy. *Chin J Traumatol* 2016;19:330-2.
26. Chen M, Jiang Y, Wen JF, Li N, Qiu J, Zhang NK, et al. Clinical features of traumatic optic neuropathy in 265 cases. *Zhonghua Er Bi Yan Hou Tou Jing Wai Ke Za Zhi* 2017;52:659-63.
27. Sefi-Yurdakul N, Koç F. Risk factors affecting the visual outcome in patients with indirect traumatic optic neuropathy. *Int Ophthalmol* 2018;38:1647-52.
28. Mahapatra AK. Visual evoked potentials in optic nerve injury. Does it merit a mention? *Acta Neurochir (Wien)* 1991;112:47-9.
29. Kumaran AM, Sundar G, Chye LT. Traumatic optic neuropathy: a review. *Craniofac Trauma Reconstr*;8:31-41.