

Recurrent Acute Pancreatitis in Pregnancy Caused by Parathyroid Hyperplasia: A Case Report and Literature Review

Tanawan Kongmalai, MD¹, Sirinart Sirinvaravong, MD¹, Mongkol Boonsripitayanon, MD², Mongkol Uiprasertkul, MD³, Paweena Chunharojrith, MD¹

¹ Division of Endocrinology and Metabolism, Department of Medicine, Faculty of Medicine Siriraj Hospital, Mahidol University, Bangkok, Thailand

² Division of Head, Neck, and Breast Surgery, Department of Surgery, Faculty of Medicine Siriraj Hospital, Mahidol University, Bangkok, Thailand

³ Department of Pathology, Faculty of Medicine Siriraj Hospital, Mahidol University, Bangkok, Thailand

Background: Hypercalcemia during pregnancy leads to multiple maternal and fetal complications. To date, fewer than 30 cases of primary hyperparathyroidism (PHPT)-induced pancreatitis have been diagnosed during pregnancy. Most cases have been caused by a parathyroid adenoma. In the present report, the author described the first case of PHPT due to parathyroid hyperplasia presented with recurrent, acute pancreatitis during pregnancy.

Case Report: A 38-year-old female, with a history of acute pancreatitis during her first pregnancy, presented with severe epigastric pain, nausea, and vomiting for three days at 24 weeks of gestation. Parathyroid-dependent, hypercalcemia-induced recurrence of pancreatitis was diagnosed based on the clinical presentation and laboratory investigations. An ultrasound on her neck revealed a possible parathyroid adenoma located on the inferior pole of the left thyroid gland. She underwent an uneventful left-lower parathyroidectomy. The pathological examination revealed parathyroid hyperplasia. Her serum calcium and parathyroid hormone levels returned to normal after surgery. She delivered a healthy male newborn at gestational age 38 weeks without any complications.

Conclusion: PHPT-induced acute pancreatitis during pregnancy is rare. Hypercalcemia, involving both total and ionized calcium, should be investigated in pregnant women who present with acute pancreatitis. Early diagnosis and appropriate management can significantly improve the maternal, fetal, and pregnancy outcomes.

Keywords: Hypercalcemia, Recurrent pancreatitis, Pregnancy, Primary hyperparathyroidism, Parathyroid hyperplasia

Received 9 July 2020 | Revised 20 July 2020 | Accepted 23 July 2020

J Med Assoc Thai 2020;103(9):952-9

Website: <http://www.jmatonline.com>

Primary hyperparathyroidism (PHPT) in pregnancy is a rare clinical entity. The reported prevalence of PHPT in pregnancy is less than 1%. However, the actual prevalence is underestimated

because of non-specific symptoms and physiological changes in one's calcium homeostasis during pregnancy⁽¹⁾. PHPT in pregnancy is associated with increased maternal complications, including nephrolithiasis, bone changes, preeclampsia, hyperemesis gravidarum, miscarriages, pancreatitis, and hypercalcemic crisis. Additionally, fetal complications related to PHPT in pregnancy include intra-uterine growth restriction (IUGR), intra-uterine fetal demise, preterm labor, low birth weight, postpartum neonatal hypocalcemia, and respiratory failure in newborns⁽²⁾.

A previous study had demonstrated that PHPT in the general population was associated with acute or chronic pancreatitis, and the mean frequency of this complication was 3.6% of PHPT cases (with a range of 1.5% to 15.3%)⁽³⁾. Acute pancreatitis in the pregnant population caused by PHPT occurs with a higher prevalence (7% to 13% of pregnant

Correspondence to:

Chunharojrith P.

Division of Endocrinology and Metabolism, Department of Medicine, Faculty of Medicine Siriraj Hospital, Mahidol University, Asadang Building 8th floor, 2 Wang Lang Road, Bangkoknoi, Bangkok 10700, Thailand.

Phone: +66-2-4197799, **Fax:** +66-2-4197792

Email: paweena.chn@mahidol.ac.th

How to cite this article:

Kongmalai T, Sirinvaravong S, Boonsripitayanon M, Uiprasertkul M, Chunharojrith P. Recurrent Acute Pancreatitis in Pregnancy Caused by Parathyroid Hyperplasia: A Case Report and Literature Review. *J Med Assoc Thai* 2020;103:952-9.

doi.org/10.35755/jmedassocthai.2020.09.11628

women with PHPT)⁽²⁾. It may be assumed that pregnant women with PHPT have an increased risk of acute pancreatitis. However, PHPT-induced acute pancreatitis in pregnancy is rare; there have only been 23 cases reported in studies published in the English literature⁽⁴⁻²⁶⁾. Interestingly, three of these case reports involved recurrent acute pancreatitis in pregnancy. A parathyroid adenoma is the most common cause of this condition, and accounts for 95.6% of all cases, followed by parathyroid carcinoma (4.4%). Notably, parathyroid hyperplasia has never been reported before in PHPT-induced acute pancreatitis in pregnancy. Thus, the author reported the first case of PHPT caused by parathyroid hyperplasia presenting with acute pancreatitis at 24 weeks of gestation. A prior cesarean delivery due to acute pancreatitis at 37 weeks of gestation was noted in the medical record. Severe hypercalcemia was corrected gradually after rehydration. Furthermore, the patient's serum calcium level returned to normal after a parathyroidectomy during the second trimester.

Case Report

A 38-year-old female, gravida 2 para 1, presented with severe epigastric pain with nausea and vomiting for three days. During her first pregnancy, six years ago, she reported the same complaints throughout her pregnancy. At 37 weeks of gestation, an acute pancreatitis was diagnosed. The patient underwent a cesarean section due to acute pancreatitis. She delivered a healthy newborn, birth weight 2,750 g. After delivery, an abdominal ultrasound showed a gallbladder polyp with multiple floating gallstones. However, she received no further investigation and management. Since then, she had had no abdominal symptoms. But then, during her recent early gestation, she had severe nausea and vomiting and was diagnosed as morning sickness. At 24 weeks of gestation, she came to the hospital due to severe abdominal pain with nausea and vomiting for three days. She denied drinking any alcohol. Physical examination revealed tenderness at her left upper abdomen. Otherwise, her condition seemed normal.

Investigation

Her laboratory investigations are shown in Table 1. Acute pancreatitis was diagnosed based on the clinical presentation and laboratory findings. To identify the etiology of her pancreatitis, an ultrasound of her abdomen showed normal fetal development, with an estimated fetal weight of 534 g, no gallstones, and an absence of common bile duct

Table 1. Laboratory investigations in this patient

	Result	Normal value
BUN (mg/dL)	5.2	6 to 20
Creatinine (mg/dL)	0.57	0.51 to 0.95
Albumin (g/dL)	3.5	3.5 to 5.2
Alkaline phosphatase (U/L)	51	35 to 104
Amylase (U/L)	685	13 to 53
Corrected serum calcium (mg/dL)	14.7	8.6 to 10
Phosphorus (mg/dL)	2	2.5 to 4.5
Magnesium (mg/dL)	0.9	1.6 to 2.6
Parathyroid hormone (pg/mL)	121.1	15 to 65
25(OH)D (ng/mL)	11.01	≥30

BUN=blood urea nitrogen; 25(OH)D=25-hydroxyvitamin D

dilatation. However, a 0.5-cm left renal stone was found. Her serum calcium and parathyroid hormone (PTH) levels were significantly elevated, with a low serum phosphorus (Table 1). Thus, PTH-dependent, hypercalcemia-induced acute pancreatitis was diagnosed. In addition, her 24-hour urine calcium was 348.3 mg/day (with a reference range of 100 to 300 mg/day). Her 24-hour urine calcium over creatinine clearance ratio was 0.032. Hence, familial hypocalciuric hypercalcemia was excluded.

A computerized tomography (CT) scan and a sestamibi scan were contraindicated during pregnancy. An ultrasound of her parathyroid glands was performed to localize the cause of PTH-dependent hypercalcemia. An oval-shaped hypo-echoic lesion, just inferior to the lower pole of the left thyroid size of 0.99×0.74×1.67 cm, with the possibility of a left inferior parathyroid adenoma was seen (Figure 1). The patient refused a fine-needle aspiration (FNA) with a PTH wash of this lesion. Based on the investigation mentioned above, PHPT with acute pancreatitis was diagnosed at 24 weeks of gestation.

Treatment

Though an aggressive saline infusion (4 to 6 L per day) was introduced to reduce her serum calcium, the serum total and ionized calcium level remained elevated (ranging between 10.3 to 12 mg/dL and 6.3 to 6.8 mg/dL, respectively). Due to severe hypercalcemia and acute pancreatitis, she underwent a bilateral neck exploration with left lower parathyroidectomy four days after hospitalization. The intraoperative finding revealed an enlargement of her left lower parathyroid gland of 1 cm in diameter. Her left upper and right

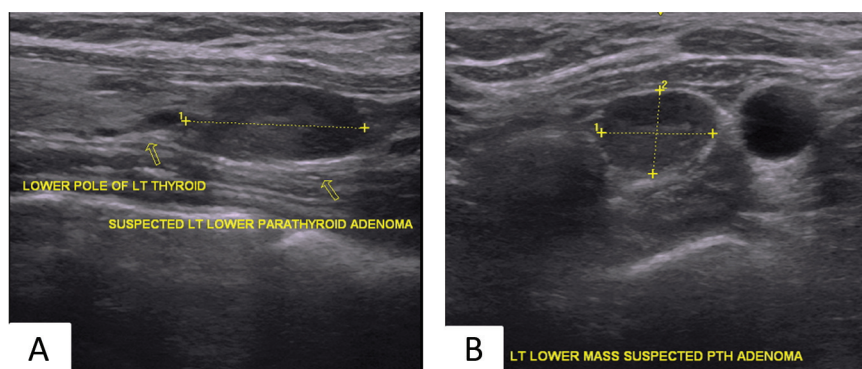


Figure 1. Ultrasound of thyroid. A) Sagittal view showed an oval-shaped hypoechoic lesion inferior to lower pole of left thyroid lobe. B) Transverse view showed a round shape hypoechoic lesion at lower pole of left thyroid lobe size 0.99×0.74×1.67 cm with suspicious of left inferior parathyroid adenoma.

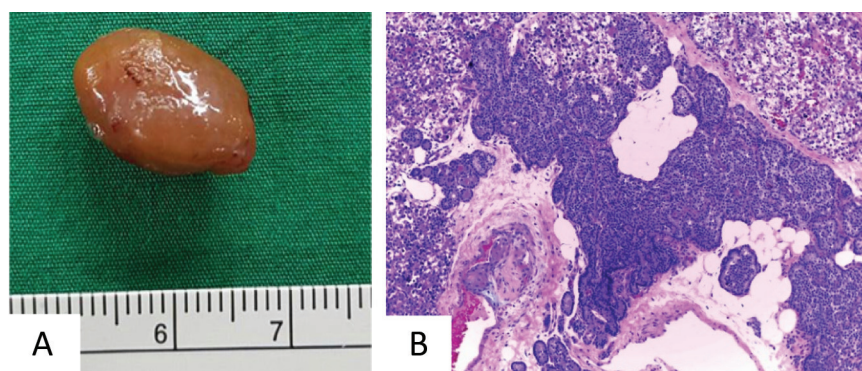


Figure 2. A) A gross macroscopic examination revealed an enlarged parathyroid gland with bulging, yellowish-brown tissue. No encapsulated mass was identified. B) A microscopic micrograph (H&E, ×100) demonstrated chief cells, admixed with oxyphil cells, some clear cells, and adipocytes. No discrete mass was found.

lower parathyroid glands were normal. However, her right upper parathyroid gland could not be identified. Pathological examination showed the parathyroid gland weighed 7.0 g. The cut section showed a yellowish-brown tissue and no definite mass was identified. Microscopic examination revealed chief cells, oxyphil cells, and adipocytes. Adipose tissue was found among the major component, chief cells, compatible with parathyroid hyperplasia (Figure 2). The patient's PTH level significantly dropped from 301 pg/mL to 13.01 pg/mL, two hours post-operatively.

Outcome and follow-up

After a resolution of her hypercalcemia, the abdominal pain, nausea, and vomiting subsided. Her serum calcium gradually decreased, without any consequent hungry-bone syndrome. She reported no signs or symptoms of hypocalcemia. Vitamin D 40,000 units per week was prescribed due to her vitamin D deficiency. She was closely monitored

and her serum calcium and PTH remained within a normal range. She underwent an uneventful cesarean section at gestational age 38 weeks, delivered a term male infant, birth weight 2,900 g, without neonatal hypocalcemia. According to her young age at diagnosis and her parathyroid hyperplasia, genetic hyperparathyroidism should be considered. However, she reported no visual disturbances, no headaches, or galactorrhea. She denied any family history of hypercalcemia or other endocrinopathies. Her physical examination was unremarkable. Thus, genetic testing such as MEN1, MEN2, MEN4, or hyperparathyroidism jaw-tumor syndrome (HPT-JT) were not requested. However, PHPT might be a first manifestation of this genetic syndrome. Thus, careful monitoring is essential. In the present patient, after two years of diagnosis, her serum calcium and PTH remained within a normal range. Bone mineral density after delivery showed below the expected range for age, Z-score was -2.2, at L1-L4 vertebrae.

Discussion

Acute pancreatitis is a rare condition in pregnancy, with a reported incidence ranging broadly between 0.02% and 0.1% of pregnancies^(27,28). Gallstone is the most common etiology. Less common etiologies include hypertriglyceridemia, alcohol, and cystic fibrosis⁽²⁷⁻²⁹⁾. Hypercalcemia, resulting from PHPT, is also a rare cause of acute pancreatitis in pregnancy. Both PHPT and acute pancreatitis in pregnancy were associated with increased adverse maternal and fetal outcomes^(2,28). Therefore, early diagnosis and appropriate management of PHPT are essential to reduce maternal and fetal complications. Early recognition of PHPT in pregnancy is challenging because most patients with PHPT are asymptomatic, and clinical symptoms such as nausea, vomiting, anorexia, weakness, and fatigue are non-specific and similar to common health problems during pregnancy. Furthermore, physiological changes in one's calcium homeostasis during pregnancy, including intravascular fluid expansion leading to gestational hemodilution, hypoalbuminemia, hypercalciuria resulting from an increase in glomerular filtration, and transplacental transfer of calcium from mother to fetus, tend to decrease the total serum calcium level during pregnancy, contributing to under-detected hypercalcemia⁽²⁾. One report of a pregnant patient with acute pancreatitis from PHPT that had a normal calcium level, leading to an underdiagnosis of PHPT, whereas her ionized calcium level was high⁽²¹⁾. Thus, an ionized calcium level, which is not affected by pregnancy, may play an important role in the investigation of PHPT in pregnancy when the total serum calcium level is normal in the suspected cases.

Notably, the medical history of 23 pregnant patients with pancreatitis secondary to PHPT revealed that they had nephrolithiasis (22%), miscarriages (13%), acute pancreatitis (4.3%), and acute pancreatitis in a previous pregnancy (4.3%)^(14,16-18,23,24) (Table 2). Knowing the patient's medical history may help to early identify PHPT in pregnancy by screening for hypercalcemia in patients with those medical history during the preconception period and antenatal care. An ultrasound of the abdomen of the present patient revealed a left renal stone. This suggested that she had longstanding hypercalcemia. Data from 23 reported cases in English indicated that acute pancreatitis in pregnancy induced by PHPT usually developed in the third trimester (54.6%), followed by the first trimester (22.7%), the postpartum period (13.6%), and the second trimester (9.1%). In the

present patient, it happened both in the third trimester of a previous pregnancy and the second trimester of the present pregnancy. Interestingly, in the case reports of the three patients who had recurrent acute pancreatitis in pregnancy caused by PHPT, one had acute pancreatitis in a previous pregnancy⁽¹⁶⁾ and the other two developed a second episode of acute pancreatitis during pregnancy after resolved the first episode of acute pancreatitis in pregnancy^(15,26). The present patient also had recurrent acute pancreatitis during her second pregnancy. She underwent a cesarean section at 37 weeks of gestation due to the acute pancreatitis. It may be assumed that pregnancy may aggravate hypercalcemia in PHPT in some patients.

The possible mechanisms of PHPT-induced acute pancreatitis in pregnancy have been described as hypercalcemia that accelerates trypsinogen activation and trypsin stability, causing pancreatic autodigestion, and pancreatic duct obstruction resulting from hypercalcemia-induced pancreatic calculi and the growth of the uterus in the peritoneal cavity^(25,30). The most common cause of PHPT in both pregnant and non-pregnant patients is a solitary parathyroid adenoma (90%), which is usually located in the inferior parathyroid glands. The remaining causes are parathyroid hyperplasia (6% to 9%) and parathyroid carcinoma (1%)⁽²⁾. Although parathyroid hyperplasia has been reported in pregnant patients with PHPT, it has never been presented with acute pancreatitis in pregnancy. Significantly, this is the first case report of parathyroid hyperplasia presenting with acute pancreatitis during pregnancy. It was located in the left inferior parathyroid gland. According to the young age at diagnosis and her parathyroid hyperplasia, a familial syndrome associated with PHPT, including MEN1, MEN2, MEN 4, and HPT-JT should be considered. However, genetic testing was not performed on the present patient because she did not have any of those syndromes.

Localization of a causative tumor of PHPT in pregnancy has limitations, especially due to the potential risks of radiation exposure to the fetus. Thus, an ultrasonography of the neck is the first choice of investigation during pregnancy. It has a sensitivity of 69% and a specificity of 94%⁽²⁾. In case of the ultrasound findings do not distinguish parathyroid adenoma from thyroid adenoma, an ultrasound-guided FNA, and a measurement of the PTH level in the aspirate fluid, with a high degree of sensitivity. Alternatively, an MRI of the neck without gadolinium in pregnancy can also effectively identify a tumor if

Table 2. Literature review of pregnant woman with acute pancreatitis caused by primary hyperparathyroidism

Authors	GA	Presenting signs and symptoms	Past medical history	Ca/Ca ⁺⁺	Surgery	Pathology	Maternal outcomes	Fetal outcomes
Soyanwo, et al. 1968 ⁽⁴⁾	16	Persistent vomiting, drowsy, conscious loss, crampy abdominal pain	-	19 ⁺ /-	1 day PP	Parathyroid adenoma	Bilateral nephrocalcinosis, cardiac arrest, death	Spontaneous abortion (16 week)
Bronsky, et al. 1970 ⁽⁵⁾	40	Hypotension, obtunded, unresponsive 6 hours after delivery	-	12.5 to 15 ⁺ /-	4 weeks PP	Parathyroid adenoma	Pancreatitis after childbirth	Induced labor (40 weeks), tremor; transient hypocalcemia (6.5a)
Levine, et al. 1979 ⁽⁶⁾	33	Right upper abdominal pain with radiation to back, vomiting	-	15 ⁺ /-	33 GA	Parathyroid carcinoma	Transient hypocalcemia	Natural delivery (38 weeks), healthy baby
Hess, et al. 1980 ⁽⁷⁾	31	Upper abdominal and left flank pain, nausea, vomiting, conscious change	-	14.1 ⁺ /-	31 GA	Parathyroid adenoma	Kidney calcification, acute kidney injury, pancreatic pseudocyst, transient hypocalcemia (6 months), rib fractures	Spontaneous premature rupture of membranes, induced labor (36 weeks), assisted ventilation for 2 days, transient hypocalcemia
Thomason, et al. 1981 ⁽⁸⁾	36	Vomiting, severe epigastric pain	-	12.9 ⁺ /1.72 ^c	5 weeks PP	Parathyroid adenoma	Transient hypocalcemia	Induced labor (38 weeks), marginal placenta abruption, assisted ventilation for 2 days, transient hypocalcemia (7.1a)
Fabrin, et al. 1986 ⁽⁹⁾	36	Severe abdominal pain, vomiting, loss of consciousness	-	14.8 ⁺ /-	PP	Parathyroid adenoma	Transient hypocalcemia	C/S (36 weeks), healthy baby, transient hypocalcemia
Rajala, et al. 1987 ⁽¹⁰⁾	36	Severe upper abdominal pain, nausea	-	12.3 ⁺ /-	2 weeks PP	Parathyroid adenoma	Normocalcemia	C/S (36 weeks), healthy baby, normocalcemia
Inabnet, et al. 1996 ⁽¹¹⁾	11	Acute abdominal pain	-	11.8 ⁺ /1.83 ^c	19 GA	Parathyroid adenoma	Transient hypocalcemia	Natural delivery (40 weeks), healthy baby; transient hypocalcemia
Kondo, et al. 1998 ⁽¹²⁾	31	Lumbago, abdominal pain, and loss of consciousness	-	18.3 ⁺ /-	10 days PP	Parathyroid adenoma	Multiple organ dysfunction (DIC, respiratory failure, and acute renal failure) brain damage, pneumonia, and death	C/S (31 weeks), normocalcemia
Kort, et al. 1999 ⁽¹³⁾	13	Nausea, vomiting, symptomatic UTI, loss of consciousness	-	15.8 ⁺ /-	The second trimester	NA	NA	Fetal death during the second trimester
Hong, et al. 2001 ⁽¹⁴⁾	30→4	Severe epigastric pain, vomiting, fever, progressive shortness of breath	3 miscarriages in 4 years, bilateral urolithiasis	17.9 ⁺ /-	6 days PP	Parathyroid adenoma	Preeclampsia, metabolic acidosis with impending respiratory failure hyperglycemia, anemia, hypoalbuminemia, and a UTI	C/S (31+3 weeks), MV for 2 days, transient hypocalcemia (7.7a)
Dahan, et al. 2001 ⁽¹⁵⁾	32	Frequent uterine contractions, abdominal pain, nausea, vomiting	-	11.6 ⁺ /-	13 weeks PP	Parathyroid adenoma	Bilateral kidney stones, preterm labor	Natural delivery (36 weeks), healthy baby

GA=gestational age; PP=postpartum; UTI=urinary tract infection, NA=not available; DIC=disseminated intravascular coagulation; C/S=cesarean section; MV=mechanical ventilation; IUGR=intrauterine growth restriction

^a Total serum calcium concentration in mg/dL (normal range 8.5 to 10.5). ^b Corrected serum calcium concentration in mg/dL (normal range 8.5 to 10.5). ^c Ionized calcium concentration in mmol/L (normal range 1.15 to 1.3)

Table 2. (continued)

Authors	GA	Presenting signs and symptoms	Past medical history	Ca/Ca ⁺⁺	Surgery	Pathology	Maternal outcomes	Fetal outcomes
Krysiak, et al. 2011 ⁽¹⁶⁾	8	Strong abdominal pain, nausea, vomiting, anorexia	3 miscarriages, ureteral stone, acute pancreatitis at 6 weeks of gestation in a previous pregnancy	10.45 ^b /1.3 ^c	3 months PP	Parathyroid adenoma	Bilateral massive nephrolithiasis	Natural delivery (38 weeks), healthy baby, transient hypercalcemia (11.3a)
Chamathi, et al. 2011 ⁽¹⁷⁾	32	The middle-to-lower back pain with radiation to the upper abdomen, vomiting	Kidney stone	11.88 ^b /1.42 ^c	Before delivery	Parathyroid adenoma	Mild preeclampsia	C/S (37 weeks), healthy baby
Lee, et al. 2014 ⁽¹⁸⁾	37	Severe diffuse acute abdomen pain after childbirth 1 day	1 miscarriage	18 ^b /-	11 weeks PP	Parathyroid adenoma	Pancreatitis after childbirth, pancreatic abscess, bilateral hydronephrosis caused by renal stones, neurological complications (eye deviation, visual field defect, and seizure)	Natural delivery (37 weeks), healthy baby, normocalcemia
Liu, et al. 2016 ⁽¹⁹⁾	31	Headache, dizziness, nausea, vomiting, irritability, high blood pressure	-	15.2 ^b /-	3 days PP	Parathyroid adenoma	Preeclampsia, pancreatitis after childbirth	C/S (31 weeks), transient hypercalcemia (12.6a)
Burks, et al. 2017 ⁽²⁰⁾	11	Refractory nausea and vomiting	-	12.6 ^b /-	12 GA	Parathyroid adenoma	Worsening symptoms hypercalcemia	Healthy baby
Dale, et al. 2017 ⁽²¹⁾	32+3	High blood pressure, scotomata, epigastric pain	-	10.2 ^b /1.58 ^c	PP	Parathyroid adenoma	Preeclampsia	C/S (32 weeks), healthy baby
Rupprecht, et al. 2017 ⁽²²⁾	-	Massive upper abdominal pain, vomiting	-	-/2.13 ^c	2 days PP	Parathyroid adenoma	Massive necrotizing pancreatitis, death	Healthy baby
Han, et al. 2018 ⁽²³⁾	34	Nausea, vomiting, acid reflux	Acute pancreatitis, kidney stones	16.9 ^b /2.05 ^c	35 GA	Parathyroid adenoma	Polyhydramnios, florid bilateral nephrocalcinosis, refractory hypercalcemia	C/S (36 weeks), healthy baby, transient hypocalcemia, neonatal nephrocalcinosis
Richa, et al. 2018 ⁽²⁴⁾	11	Epigastric pain, nausea, bilious vomiting	Nephrolithiasis	12.35 ^b /-	13 GA	Parathyroid adenoma	Refractory hypercalcemia, hungry bone syndrome	C/S (36 weeks), healthy baby
Yang, et al. 2019 ⁽²⁵⁾	37	Sudden attack of persisting epigastric pain, nausea, bilious vomiting	-	12.6 ^b /1.77 ^c	10 days PP	Parathyroid adenoma	Bilateral nephrolithiasis, severe acute necrotizing pancreatitis, transient hypocalcemia, death 72 days after childbirth	C/S (37 weeks), healthy baby
Bansal, et al. 2020 ⁽²⁶⁾	24	Severe epigastric pain, multiple episodes of vomiting	-	12.8 ^b /-	Ethanol ablation at 27 weeks GA	Parathyroid adenoma	Recurrent pancreatitis during pregnancy at 27 weeks GA, normocalcemia	C/S (38 weeks), healthy baby, normocalcemia
Present case	24	Severe abdominal pain, nausea, vomiting	Acute pancreatitis at 37 weeks GA in a previous pregnancy	14.7 ^b /1.57 ^c	26 GA	Parathyroid hyperplasia	Left renal stone	IUGR, C/S (38 weeks), healthy baby, normocalcemia

GA=gestational age; PP=postpartum; UTI=urinary tract infection, NA=not available; DIC=disseminated intravascular coagulation; C/S=cesarean section; MV=mechanical ventilation; IUGR=intrauterine growth restriction

^a Total serum calcium concentration in mg/dL (normal range 8.5 to 10.5), ^b Corrected serum calcium concentration in mg/dL (normal range 8.5 to 10.5), ^c Ionized calcium concentration in mmol/L (normal range 1.15 to 1.3)

an ultrasound is unremarkable^(24,26). A CT scan of the neck and a Technetium-^{99m}-sestamibi scintigraphy are contraindicated in pregnancy.

Since there are no standard guidelines for management of PHPT in pregnancy, individualized treatment should be based on one's gestational age, symptoms, severity of hypercalcemia, and the risks-benefits of surgery. Parathyroidectomy is the only curative treatment and should be considered for patients with symptoms of moderate to severe hypercalcemia. Some experts recommend surgery if the serum calcium was above 11 mg/dL^(31,32). The optimal time for surgery is during the second trimester, due to incomplete organogenesis in the first trimester and the risk of preterm labor in the third trimester^(2,33). However, uneventful parathyroidectomy in the first and third trimester has also been reported^(6,15,20,23,24,31,34).

Medical management is considered the mainstay of treatment in asymptomatic, mild hypercalcemia (of less than 11 mg/dL). Unfortunately, there are some limitations during pregnancy. Oral or intravenous fluid administration and a low calcium diet with or without a diuretic are the first line of treatment⁽¹⁾. Nevertheless, this has limited and temporary effects, as demonstrated in the present patient. Calcitonin does not cross the placenta and it is safe for the mother and fetus. However, calcitonin associated with tachyphylaxis after 48 hours of use. Cinacalcet has limited and controversial data reported in pregnancy^(35,36). Bisphosphonates can cross the placenta and are associated with fetal skeletal abnormalities. Thus, it is contraindicated during pregnancy.

Conclusion

PHPT-induced pancreatitis during pregnancy is rare. Screening for hypercalcemia should be considered in patients with a history of nephrolithiasis, miscarriages, and idiopathic pancreatitis during preconception and antenatal care. Moreover, ionized calcium should be investigated if patient had clinical suspicious of hypercalcemia but total serum calcium was normal. Early diagnosis and appropriate management can significantly improve the maternal, fetal, and pregnancy outcomes.

What is already known on this topic?

- PHPT in pregnancy is uncommon and rarely presents with acute pancreatitis.
- Both acute pancreatitis and hypercalcemia in pregnancy are associated with a poor pregnancy outcome.
- Parathyroid adenoma is the most common cause

of PHPT in pregnancy.

What this report adds?

- The prevalence of acute pancreatitis caused by PHPT in pregnant female is higher than in the general population. Thus, pregnant females may be at risk of developing pancreatitis in PHPT.
- Ultrasound parathyroid is a useful form of imaging to investigate during pregnancy.
- Parathyroid hyperplasia can be an etiology of PHPT-induced pancreatitis in pregnant women.

What are the implications for public health practice?

- PHPT should be considered as a cause of recurrent pancreatitis.
- Screening for hypercalcemia should be considered in patients with a history of nephrolithiasis, miscarriages, and idiopathic pancreatitis during preconception and antenatal care.
- The ionized calcium level should be measured when PHPT is suspected during pregnancy.
- Early-diagnosis and appropriate management can reduce maternal and fetal complications.

Acknowledgement

Consent for publication was obtained from the patient in written form.

Conflicts of interest

The authors declare no conflict of interest.

References

1. Norman J, Politz D, Politz L. Hyperparathyroidism during pregnancy and the effect of rising calcium on pregnancy loss: a call for earlier intervention. *Clin Endocrinol (Oxf)* 2009;71:104-9.
2. Schnatz PF, Curry SL. Primary hyperparathyroidism in pregnancy: evidence-based management. *Obstet Gynecol Surv* 2002;57:365-76.
3. Bai HX, Giefer M, Patel M, Orabi AI, Husain SZ. The association of primary hyperparathyroidism with pancreatitis. *J Clin Gastroenterol* 2012;46:656-61.
4. Soyannwo MA, Bell M, McGeown MG, Milliken TG. A case of acute hyperparathyroidism, with thyrotoxicosis and pancreatitis, presenting as hyperemesis gravidarum. *Postgrad Med J* 1968;44:861-6.
5. Bronsky D, Weisbery MG, Gross MC, Barton JJ. Hyperparathyroidism and acute postpartum pancreatitis with neonatal tetany in the child. *Am J Med Sci* 1970;260:160-4.
6. Levine G, Tsin D, Risk A. Acute pancreatitis and hyperparathyroidism in pregnancy. *Obstet Gynecol*

- 1979;54:246-8.
7. Hess HM, Dickson J, Fox HE. Hyperfunctioning parathyroid carcinoma presenting as acute pancreatitis in pregnancy. *J Reprod Med* 1980;25:83-7.
 8. Thomason JL, Sampson MB, Farb HF, Spellacy WN. Pregnancy complicated by concurrent primary hyperparathyroidism and pancreatitis. *Obstet Gynecol* 1981;57(6 Suppl):34S-6S.
 9. Fabrin B, Eldon K. Pregnancy complicated by concurrent hyperparathyroidism and pancreatitis. *Acta Obstet Gynecol Scand* 1986;65:651-2.
 10. Rajala B, Abbasi RA, Hutchinson HT, Taylor T. Acute pancreatitis and primary hyperparathyroidism in pregnancy: treatment of hypercalcemia with magnesium sulfate. *Obstet Gynecol* 1987;70:460-2.
 11. Inabnet WB, Baldwin D, Daniel RO, Staren ED. Hyperparathyroidism and pancreatitis during pregnancy. *Surgery* 1996;119:710-3.
 12. Kondo Y, Nagai H, Kasahara K, Kanazawa K. Primary hyperparathyroidism and acute pancreatitis during pregnancy. Report of a case and a review of the English and Japanese literature. *Int J Pancreatol* 1998;24:43-7.
 13. Kort KC, Schiller HJ, Numann PJ. Hyperparathyroidism and pregnancy. *Am J Surg* 1999;177:66-8.
 14. Hong MK, Hsieh CT, Chen BH, Tu ST, Chou PH. Primary hyperparathyroidism and acute pancreatitis during the third trimester of pregnancy. *J Matern Fetal Med* 2001;10:214-8.
 15. Dahan M, Chang RJ. Pancreatitis secondary to hyperparathyroidism during pregnancy. *Obstet Gynecol* 2001;98:923-5.
 16. Krysiak R, Wilk M, Okopien B. Recurrent pancreatitis induced by hyperparathyroidism in pregnancy. *Arch Gynecol Obstet* 2011;284:531-4.
 17. Chamarthi B, Greene MF, Dluhy RG. Clinical problem-solving. A problem in gestation. *N Engl J Med* 2011;365:843-8.
 18. Lee CC, Chao AS, Chang YL, Peng HH, Wang TH, Chao A. Acute pancreatitis secondary to primary hyperparathyroidism in a postpartum patient: a case report and literature review. *Taiwan J Obstet Gynecol* 2014;53:252-5.
 19. Liu Y, Wang JN, Huang Y, Zhu YH, Liu RL, Xu CF, et al. Case report: Acute pancreatitis and preeclampsia induced by parathyroid adenoma in pregnancy: a case report and literature review. *Int J Clin Exp Med* 2016;9:22652-5.
 20. Burks ML, Harary S, Solorzano CC, Bao S. Primary hyperparathyroidism in a first-trimester woman with hyperemesis gravidarum and pancreatitis. *AACE Clin Case Rep* 2017;3:e31-4.
 21. Dale AG, Holbrook BD, Sobel L, Rappaport VJ. Hyperparathyroidism in pregnancy leading to pancreatitis and preeclampsia with severe features. *Case Rep Obstet Gynecol* 2017;2017:6061313.
 22. Rupperecht H, Reinfelder J, Turkoglu A. A case of severe acute necrotizing pancreatitis in a 38-year-old woman postpartum due to a parathyroid adenoma. *GMS Interdiscip Plast Reconstr Surg DGPW* 2017;6:Doc13.
 23. Han ES, Fritton K, Bacon P, Slodzinski MK, Argani C. Preterm parturient with polyhydramnios and pancreatitis: Primary presentation of hyperparathyroidism. *Case Rep Obstet Gynecol* 2018;2018:2091082.
 24. Richa CG, Saad KJ, Chaaban AK, El Rawas MS. A rare case of hypercalcemia-induced pancreatitis in a first trimester pregnant woman. *Endocrinol Diabetes Metab Case Rep* 2018;2018:17-0175.
 25. Yang J, Dong MJ, Chen F. A rare lethal case of severe acute necrotizing pancreatitis due to a parathyroid adenoma in a third-trimester pregnant woman. *BMC Endocr Disord* 2019;19:82.
 26. Bansal S, Kaushik RM, Kaushik R, Modi S, Raghuvanshi S, Kusum A. Primary hyperparathyroidism presenting as severe hypercalcemia with acute pancreatitis in pregnancy. *Gynecol Endocrinol* 2020;36:469-72.
 27. Tang SJ, Rodriguez-Frias E, Singh S, Mayo MJ, Jazrawi SF, Sreenarasimhaiah J, et al. Acute pancreatitis during pregnancy. *Clin Gastroenterol Hepatol* 2010;8:85-90.
 28. Hernandez A, Petrov MS, Brooks DC, Banks PA, Ashley SW, Tavakkolizadeh A. Acute pancreatitis and pregnancy: a 10-year single center experience. *J Gastrointest Surg* 2007;11:1623-7.
 29. Jain P. Acute pancreatitis in pregnancy: an unresolved issue. *World J Gastroenterol* 2010;16:2065-6.
 30. Khoo TK, Vege SS, Abu-Lebdeh HS, Ryu E, Nadeem S, Wermers RA. Acute pancreatitis in primary hyperparathyroidism: a population-based study. *J Clin Endocrinol Metab* 2009;94:2115-8.
 31. Schnatz PF, Thaxton S. Parathyroidectomy in the third trimester of pregnancy. *Obstet Gynecol Surv* 2005;60:672-82.
 32. Diaz-Soto G, Linglart A, Sénat MV, Kamenicky P, Chanson P. Primary hyperparathyroidism in pregnancy. *Endocrine* 2013;44:591-7.
 33. DiMarco AN, Meeran K, Christakis I, Sodhi V, Nelson-Piercy C, Tolley NS, et al. Seventeen cases of primary hyperparathyroidism in pregnancy: A call for management guidelines. *J Endocr Soc* 2019;3:1009-21.
 34. Tachamo N, Timilsina B, Dhital R, Lynn T, Magaji V, Gabriely I. Primary hyperparathyroidism in pregnancy: successful parathyroidectomy during first trimester. *Case Rep Endocrinol* 2018;2018:5493917.
 35. Vera L, Oddo S, Di Iorgi N, Bentivoglio G, Giusti M. Primary hyperparathyroidism in pregnancy treated with cinacalcet: a case report and review of the literature. *J Med Case Rep* 2016;10:361.
 36. Horjus C, Groot I, Telting D, van Setten P, van Sorge A, Kovacs CS, et al. Cinacalcet for hyperparathyroidism in pregnancy and puerperium. *J Pediatr Endocrinol Metab* 2009;22:741-9.