

# Verrucous Psoriasis Successfully Treated with Ixekizumab: A Case Report with Review Literature

Kamonrat Sunantawanich, MD<sup>1</sup>, Vesarat Wessagowit, MD, PhD<sup>1</sup>, Poonnawis Sudtikoonaseth, MD<sup>1</sup>, Pailin Puangpet, MD<sup>1</sup>

<sup>1</sup> Institute of Dermatology, Department of Medical Services, Ministry of Public Health, Bangkok, Thailand

Verrucous psoriasis is a rare variant of plaque-type psoriasis with only about 35 cases reported. The authors reported a man with a history of psoriasis vulgaris for seven years, presented with progressive verrucous hyperkeratotic plaques on both legs for three years. His earlier investigations favored the diagnosis of tuberculosis verrucosa cutis. After completing the antituberculous therapy, the lesions persisted. The later investigations favored a rare subtype of psoriasis named verrucous psoriasis.

**Keywords:** Verrucous psoriasis, Tuberculosis verrucosa cutis, Mycobacterium tuberculosis, Ixekizumab

Received 23 March 2020 | Revised 4 June 2020 | Accepted 6 June 2020

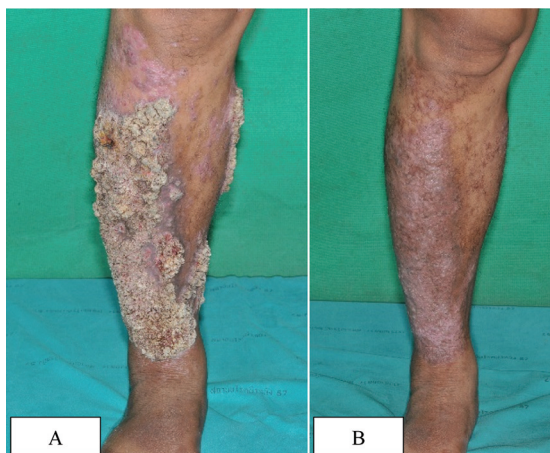
**J Med Assoc Thai 2020;103(9):948-51**

**Website:** <http://www.jmatonline.com>

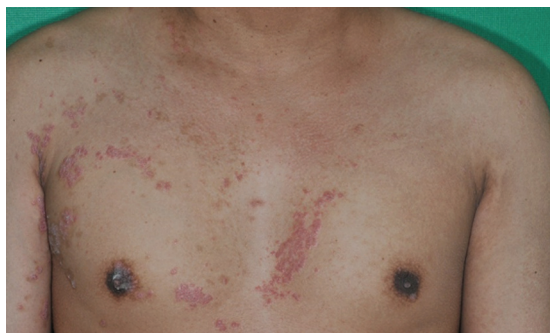Psoriasis vulgaris is a common disease in the dermatological field and can be diagnosed by classical manifestations in most cases. There are variants of plaque-type psoriasis mimicking other diseases that are difficult to diagnose. Verrucous variant is one of the rare presentations of psoriasis. Reported successful treatments vary from topical treatment to biologic therapy.

## Case Report

A 35-year-old non-obese male patient, with underlying disease of psoriasis vulgaris since the age of 28, presented with a 3-year history of progressive verrucous plaques on both legs (Figure 1A). Multiple scattered well-defined scaly erythematous plaques were noted on the trunk and the upper extremities (Figure 2). His fingernails showed subungual hyperkeratosis and distal onycholysis. The



**Figure 1.** A and B show verrucous hyperkeratotic plaques on right leg before and after 16 weeks of ixekizumab treatment, respectively.



**Figure 2.** Shows multiple scattered well-defined scaly erythematous papules and plaques on chest wall.

## Correspondence to:

Sunantawanich K.

Institute of Dermatology, Department of Medical Services, Ministry of Public Health, 420/7 Rajvithi Road, Phayathai District, Rajthevee, Bangkok 10400, Thailand.

**Phone:** +66-2-3545222

**Email:** [tarnkmr@gmail.com](mailto:tarnkmr@gmail.com)

## How to cite this article:

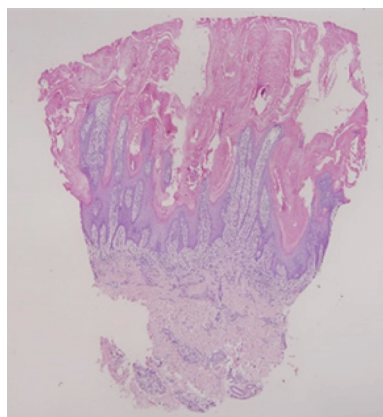
Sunantawanich K, Wessagowit V, Sudtikoonaseth P, Puangpet P. Verrucous Psoriasis Successfully Treated with Ixekizumab: A Case Report with Review Literature. *J Med Assoc Thai* 2020;103:948-51. doi.org/10.35755/jmedassocthai.2020.09.11241

clinical differential diagnosis included tuberculosis verrucosa cutis (TVC) and cutaneous human papillomavirus (HPV) infection. The first skin biopsy from the verrucous lesion showed papillomatosis, hyperkeratosis, parakeratosis, and dermal fibrosis admixed with mixed inflammatory cells infiltration, including lymphocytes, neutrophils, and plasma cells. Tissue culture showed negative result. Tissue polymerase chain reaction (PCR) for mycobacteria was positive for *Mycobacterium tuberculosis* (MTB). Skin test and interferon-gamma release assay (IGRA) were negative. Standard anti-tuberculosis regimen (isoniazid, rifampicin, pyrazinamide, and ethambutol) was prescribed. The patient later developed an allergic skin reaction to ethambutol, the regimen was then switched to isoniazid, rifampicin, pyrazinamide, and ofloxacin.

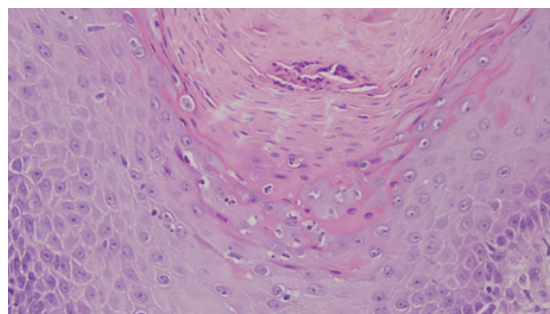
After the patient completed the antituberculosis therapy, the lesions showed no improvement. Testing for acquired immunodeficiency diseases, including HIV status, CD4+ and CD8+ cell number and ratio, and anti-interferon-gamma antibody, were all normal. Another biopsy showed papillomatosis and psoriasiform epidermal hyperplasia with hyperkeratosis and parakeratosis (Figure 3). Hypogranulosis and neutrophilic collection in stratum corneum were observed (Figure 4). The features were suggestive for psoriasis vulgaris. PCR and mycobacterial culture were negative. Immunohistochemical staining with HPV antibody was also negative. The rare variant of psoriasis vulgaris, verrucous psoriasis, was suspected. As the hyperkeratotic verrucous plaques responded poorly to prior topical agents and there was a case report of successful treatment of recalcitrant thick linear psoriasis with ixekizumab<sup>(1)</sup>, ixekizumab 80 mg subcutaneously every two weeks for 16 weeks was prescribed. At the sixteenth week, the Psoriasis Area and Severity Index (PASI) score decreased from 22.1 to 4.3 (Figure 1B). The good response to an anti-psoriatic medication together with the patient's underlying disease of psoriasis supported the diagnosis of verrucous psoriasis.

## Discussion

Verrucous psoriasis is usually reported in longstanding cases of psoriasis vulgaris. The pathogenesis is not certain. To best of the authors' knowledge, there are about 35 cases reported<sup>(2)</sup>. In 1996, Sato et al proposed that psoriatic lesions that have numerous lymphatic vessels could develop lymphatic disturbances, particularly in the presence



**Figure 3.** Shows papillomatosis, epidermal psoriasiform hyperplasia and hyperkeratosis.



**Figure 4.** Shows hypogranulosis and neutrophilic collection at stratum corneum and stratum granulosum (microabscess of Munro and spongiiform pustules of Kogoj).

of local bacterial infection and result in wart-like changes of the skin<sup>(3)</sup>. Cessation of anti-psoriatic therapy, administration of lithium carbonate, and interferon gamma were found to be triggering factors of verrucous psoriasis<sup>(4-6)</sup>. In addition to diabetes, obesity, immunosuppression, and cardiopulmonary conditions, venous stasis and lymphatic obstruction are suspected to be the major trigger factors of the papillomatous appearance<sup>(7-10)</sup>. Scratching could be the cause of verrucous change of the skin, as for lichen simplex chronicus and prurigo nodularis, however, it has never been reported to cause verrucous psoriasis. Diagnosis of verrucous psoriasis is usually made from physical examination, histopathological study, and exclusion of other possible conditions that can cause the warty appearances. Marked papillomatosis and acanthosis along with other typical features of psoriasis including elongation of the rete ridges and dilatation of vessels and neutrophils admixed with parakeratosis or spongiiform pustules support the diagnosis of verrucous psoriasis<sup>(11)</sup>.

Apart from verrucous psoriasis, there are other rare variants of plaque-type psoriasis presenting with thick hyperkeratotic plaques. Rupoid psoriasis or coral-reef or ostraceous psoriasis, presents with cone-shaped limpet-like lesions or with concave outer surface with annular hyperkeratotic rim like an oyster shell<sup>(12-15)</sup>. Elephantine psoriasis shows large, thick, flat long-standing plaques, typically found in the dorsal area, buttocks, and upper and lower limbs<sup>(16)</sup>. It should be noted that thick hyperkeratotic variants, including verrucous psoriasis, have poorer response to treatment and are usually associated with nail involvement and psoriatic arthritis<sup>(12-16)</sup>.

The present patient had repeated minor trauma of both legs from motorcycling and no verrucous lesions were observed elsewhere. He denied aggressive scratching or rubbing the lesions. The authors presumed the triggering factors of progression from psoriasis vulgaris to verrucous plaques were repetitive trauma of the legs and TVC. Infection could be the cause of lymphatic disturbance and, as a result, the warty change<sup>(17)</sup>. However, there are some objections that the present patient might not actually be infected with MTB. Firstly, he had no response to antituberculous treatment. Secondly, the tuberculin skin test and IGRA were negative. The positive PCR result could be false positive. Lastly, psoriasis is an autoinflammatory disorder that has a high level of many cytokines such as TNF-alpha, IFN-gamma and IL-17, which promote host immune response against infections, including mycobacterial infection<sup>(18-23)</sup>.

There is no standard management for verrucous psoriasis. The reported effective treatments are etretinate<sup>(10,24)</sup>, biologic agents such as apremilast<sup>(25)</sup>, ustekinumab<sup>(6,26)</sup>, and adalimumab<sup>(5)</sup>. Combined treatment with compressive dressing in cases with venous stasis or lymphatic malfunction and debridement of the hyperkeratotic surface can be used.

## Conclusion

The authors reported a case of verrucous psoriasis that responded well to ixekizumab. It is crucial to exclude other diseases presenting with verrucous lesions such as TVC, cutaneous HPV infection, and verrucous carcinoma. One should keep in mind that verrucous psoriasis is a differential diagnosis in patients presenting with verrucous lesions, particularly in psoriasis cases. Systemic therapy is usually required.

## What is already known on this topic?

Trauma is an aggravating factor of psoriasis

vulgaris. Recalcitrant conditions should be re-evaluated.

## What this study adds?

There are rare variants of plaque-type psoriasis presenting with hyperkeratotic lesions, such as verrucous psoriasis. Verrucous psoriasis should be kept in mind as a differential diagnosis of verrucous lesion. To make a definite diagnosis, re-evaluation of the patient is essential. Therapeutic treatment can be considered in some circumstances. Biologic agent, such as ixekizumab, might be used as verrucous psoriasis treatment.

## Conflicts of interest

The authors declare no conflict of interest.

## References

1. Ghoneim S, Ramos-Rodriguez AJ, Vazquez dL, Bonomo L. The successful treatment of a case of linear psoriasis with ixekizumab. *Case Rep Dermatol Med* 2017;2017:3280215.
2. Garvie K, McGinley SM, Logemann N, Lackey J. Verrucous psoriasis: A rare variant of psoriasis masquerading as verrucous carcinoma. *JAAD Case Rep* 2019;5:723-5.
3. Sato T, Katagiri K, Itami S, Takayasu S. A case of stasis papillomatosis associated with psoriasis vulgaris. *J Dermatol* 1996;23:352-6.
4. Scavo S, Gurrera A, Mazzaglia C, Magro G, Pulvirenti D, Gozzo E, et al. Verrucous psoriasis in a patient with chronic C hepatitis treated with interferon. *Clin Drug Investig* 2004;24:427-9.
5. Maejima H, Katayama C, Watarai A, Nishiyama H, Katsuoka K. A case of psoriasis verrucosa successfully treated with adalimumab. *J Drugs Dermatol* 2012;11:e74-e75.
6. Ger TY, Chang CH, Huang YH. Verrucous psoriasis: developing after discontinuation of ustekinumab and good response after readministration [abstract]. *J Am Acad Dermatol* 2018;79:AB311.
7. Baba A, Fujii K, Arimura A, Tada K, Higashi Y, Matsushita S, et al. Psoriasis with verrucous appearance. *Int J Dermatol* 2016;55:e419-21.
8. Okuyama R, Tagami H. Psoriasis verrucosa in an obese Japanese man; a prompt clinical response observed with oral etretinate. *J Eur Acad Dermatol Venereol* 2006;20:1359-61.
9. Wakamatsu K, Naniwa K, Hagiya Y, Ichimiya M, Muto M. Psoriasis verrucosa. *J Dermatol* 2010;37:1060-2.
10. Inuma S, Matsuo R, Fujii M, Honma M, Ishida-Yamamoto A. Psoriasis verrucosa complicated by generalized pustular psoriasis. *J Dermatol* 2018;45:e57-8.
11. Khalil FK, Keehn CA, Saeed S, Morgan MB. Verrucous psoriasis: a distinctive clinicopathologic

- variant of psoriasis. *Am J Dermatopathol* 2005;27:204-7.
12. Park M, Park MJ, Choi MS, Nam CH, Park BC, Hong SP, et al. A case of ostrateous psoriasis with psoriatic arthritis in an AIDS patient. *Indian J Dermatol* 2018;63:512-4.
  13. Arias-Santiago SA, Naranjo-Sintes R. Images in clinical medicine. Generalized ostrateous psoriasis. *N Engl J Med* 2010;362:155.
  14. Menon R. Ostrateous psoriasis presenting over distal extremities. *Int J Dermatol* 2011;50:1115-6.
  15. Bonciani D, Bonciolini V, Antiga E, Verdelli A, Caproni M, Senetta R. A case of rupioid psoriasis exacerbated by systemic glucocorticosteroids. *Int J Dermatol* 2015;54:e100-e102.
  16. Koley S, Mandal RK, Chatterjee K, Hassan SM, Pathak S. Elephantine psoriasis with papillomatosis and alternating hypogranulosis and hypergranulosis. *Indian J Dermatol* 2015;60:264-7.
  17. Dean SM, Zirwas MJ, Horst AV. Elephantiasis nostras verrucosa: an institutional analysis of 21 cases. *J Am Acad Dermatol* 2011;64:1104-10.
  18. Nomura I, Goleva E, Howell MD, Hamid QA, Ong PY, Hall CF, et al. Cytokine milieu of atopic dermatitis, as compared to psoriasis, skin prevents induction of innate immune response genes. *J Immunol* 2003;171:3262-9.
  19. Henseler T, Christophers E. Disease concomitance in psoriasis. *J Am Acad Dermatol* 1995;32:982-6.
  20. Dias MF, Bernardes FF, Quaresma MV, Nascimento LV, Nery JA, Azulay DR. Update on cutaneous tuberculosis. *An Bras Dermatol* 2014;89:925-38.
  21. Kurschus FC, Moos S. IL-17 for therapy. *J Dermatol Sci* 2017;87:221-7.
  22. Malakouti M, Brown GE, Wang E, Koo J, Levin EC. The role of IL-17 in psoriasis. *J Dermatolog Treat* 2015;26:41-4.
  23. Saini C, Kumar P, Tarique M, Sharma A, Ramesh V. Regulatory T cells antagonize proinflammatory response of IL-17 during cutaneous tuberculosis. *J Inflamm Res* 2018;11:377-88.
  24. Sinha P, Tripathy DM, Radhakrishnan S, Verghese B, Sunita BS. Tuberculosis verrucosa cutis presenting with unilateral elephantiasis nostras verrucosa of the left lower limb: A rare entity. *Int J Mycobacteriol* 2019;8:202-4.
  25. Okazaki S, Osawa R, Nakajima H, Nakajima K, Sano S. Favorable response to apremilast in a patient with refractory psoriasis verrucosa. *J Dermatol* 2019;46:544-7.
  26. Curtis AR, Yosipovitch G. Erythrodermic verrucous psoriasis. *J Dermatolog Treat* 2012;23:215-8.