

Sympathetic Ophthalmia in Northern Thailand

Pathanapitoon K, MD, PhD¹, Buajamrattanawong W, MD¹, Kunavisarut P, MD¹, Rothova A, MD, PhD²

¹ Department of Ophthalmology, Faculty of Medicine, Chiang Mai University, Chiang Mai, Thailand

² Department of Ophthalmology, Erasmus Medical Centre, Rotterdam, Netherlands

Objective: To report on ocular manifestations and visual outcomes of Thai patients with sympathetic ophthalmia (SO).

Materials and Methods: Medical records of 14 SO patients (nine males and five females) between 2006 and 2017 were retrospectively reviewed. Ocular manifestations, treatment modalities, complications, and visual outcomes were registered.

Results: Ten patients (72%) had history of ocular trauma and four patients (28%) had history of intraocular surgery including glaucoma surgery (n=2) and scleral patch graft for perforated corneal ulcer (n=2). Five of inciting eyes (36%) were enucleated, but none within two weeks after initial trauma or surgery. Median time from initial trauma or surgery to development of SO was 1.75 years. In sympathizing eyes, the most common ocular manifestations were panuveitis (79%) with disc edema (71%) and exudative retinal detachment (57%). Ocular complications were seen in 82% of the patients and included glaucoma, cataract, and macular edema. Most of the patients were treated with systemic corticosteroids, and 36% of the patients received additional immunosuppressive agents. At the final visit, 71% of the patients maintained a visual acuity (VA) of 20/70 or better in their sympathizing eye, and none of the sympathizing eyes had VA of 20/200 or worse.

Conclusion: Despite the high rate of ocular complications, most sympathizing eyes in Northern Thai patients with SO maintained good visual outcomes and only one third required additional immunosuppressive agents to control inflammation.

Keywords: Sympathetic ophthalmia, Enucleation, Ocular manifestations, Complications, Visual outcomes, Thailand

J Med Assoc Thai 2019;102(11):1200-4

Website: <http://www.jmatonline.com>

Received 11 Mar 2019 | Revised 29 Apr 2019 | Accepted 1 May 2019

Sympathetic ophthalmia (SO) is a rare, bilateral, granulomatous uveitis that occurs after ocular trauma or surgical procedures to one eye (inciting eye), where the sight-threatening inflammation develops in the fellow eye (sympathizing eye)⁽¹⁾. The most common causes of SO are penetrating eye injuries and various surgical procedures including glaucoma surgery⁽²⁾, cyclodestructive procedures⁽³⁻⁵⁾, vitreoretinal surgery⁽⁶⁾, and plaque brachytherapy⁽⁷⁾. Patients commonly present with bilateral intraocular inflammation, which may develop after one week to 66 years after the initial injury⁽⁸⁾. Ocular manifestations include bilateral granulomatous panuveitis with mutton-fat keratic precipitates, anterior chamber cells and flare,

posterior synechiae, as well as vitritis, choroiditis, optic nerve swelling, and serous retinal detachment. Later manifestations include Dalen-Fuchs nodules and sunset glow fundus appearance. Though uncommon, extraocular signs may also develop and include vitiligo, poliosis, alopecia, dysacusis, deafness, and meningism, which underlies the similarity to Vogt-Koyanagi-Harada disease.

Treatment usually comprises of topical and systemic corticosteroids. Then, if it was insufficient to control the inflammation, adjuvant subtenon triamcinolone acetate injection and immunosuppressive agents may be required.

Several retrospective case-series from single centers⁽⁹⁻¹²⁾ and multicenter studies have been reported^(13,14). Herein, the authors report on ocular manifestations, treatment modalities, complications, and visual outcomes in SO patients in the Northern Thai population.

Correspondence to:

Kunavisarut P.

Department of Ophthalmology, Faculty of Medicine, Chiang Mai University, 110, Intawaroros Road, Chiang Mai 50200, Thailand.

Phone: +66-53-935512, **Fax:** +66-53-936121

Email: pkunavisarut@hotmail.com, paradee.k@cmu.ac.th

How to cite this article: Pathanapitoon K, Buajamrattanawong W, Kunavisarut P, Rothova A. Sympathetic Ophthalmia in Northern Thailand. *J Med Assoc Thai* 2019;102:1200-4.

Materials and Methods

Medical records of 14 SO patients from the uveitis clinic of Chiang Mai University Hospital between 2006 and 2017 were reviewed. The demographic data, medical history, and ocular findings of inciting eye and sympathizing eye were recorded. These included type of injury (trauma or surgery), time interval from initial injury to development of SO, date of enucleation (if performed), visual acuity (VA) at onset and at final visit, treatment modalities, and development of the ocular complications (elevated intraocular pressure (>25 mmHg) or glaucoma, cataract, and macular edema). All patients underwent workup for uveitis, which included complete blood cell counts, urinalysis, serological tests for human immunodeficiency virus, syphilis, tuberculin skin test, and radiological chest examination. Diagnosis of SO was based on the clinical presentation of patients with bilateral or contralateral ocular inflammation occurring after trauma or surgery after exclusion of other possible causes of uveitis.

Each patient underwent a full ophthalmic examination, including slit lamp biomicroscopy, tonometry, and indirect ophthalmoscopy. Additional tests as fluorescein angiography (n=10) and optical coherence tomography (n=11) were performed when required. Uveitis was classified according to the anatomic localization recommended by the Standardization of Uveitis Nomenclature (SUN) Working Group⁽¹⁵⁾.

Results

The present study included 14 SO patients. There were nine males and five females for a male: female ratio of 1.8:1. Mean age at diagnosis of SO was 54 years (range 26 to 70 years) and mean follow-up time was three years (median 1.29 years; range 0.08 to 10 years).

The etiology of SO was penetrating trauma in 10 out of 14 (71%; seven males and three females) and surgical trauma in four patients (two males and two females; two after glaucoma surgery and two after scleral patch graft for perforated corneal ulcer). Median time from initial trauma or surgery to diagnosis of SO was 1.75 years (range 0.08 to 20 years). Half of the patients (7/14; 50%) developed SO within one year after the initial trauma or surgery. Five out of 14 (36%) patients underwent enucleation of the inciting eyes, but none within two weeks after initial trauma or surgery. At the initial visit, all inciting eyes had VA of less than 20/200, while four out of 14 sympathizing eyes (28%) had VA of less than

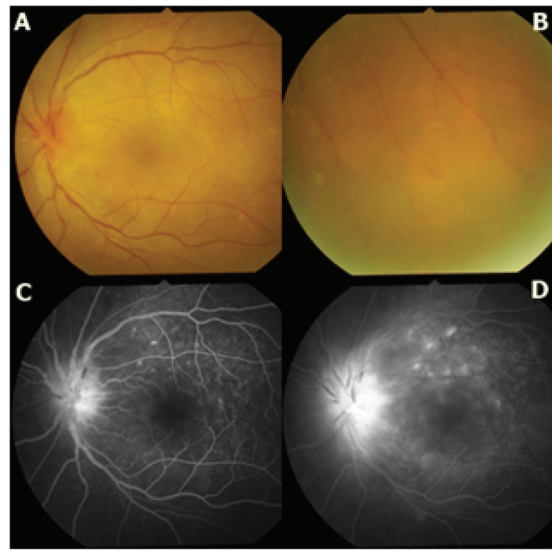


Figure 1. A-D: Left fundus photography and fluorescein angiography (FA) of 50-year-old male with previous history of right eye trauma 2 months before developing blur vision on his left eye. Visual acuity of right eye was no light perception and left eye was 20/100. Fundus photography showed (A) disc edema with hyperemia and (B) exudative retinal detachment. FA demonstrated (C) multiple early leakage with (D) late staining of fluorescein at retina and optic disc.

20/200. Panuveitis was the most common anatomical type of uveitis (11/14, 79%). Ocular features of the sympathizing eye included disc edema and exudative retinal detachment in most cases (Table 1, Figure 1). Two patients (14%) developed associated extraocular manifestations including vitiligo and deafness.

Most patients (13/14; 93%) received oral corticosteroids. Three patients received intravenous pulse methylprednisolone for three days for their severe exudative retinal detachment in the sympathizing eye. Five patients (36%) required additional immunosuppressive agents including azathioprine (n=5), methotrexate (n=1), and cyclosporine (n=1). One patient only required topical corticosteroids.

One or more of ocular complications developed in 12/14 (82%) of sympathizing eyes. Glaucoma and cataract were the most frequent complications (Table 1). One or more surgeries were required in seven of 14 sympathizing eyes (50%). Cataract surgery was the most common surgery performed (71%; 5/7) followed by laser iridotomy (57%; 4/7) and trabeculectomy (14%; 1/7).

At the final visit, all except one of the inciting eyes had VA of less or equal to 20/200, while all sympathizing eyes had VA better than 20/200

Table 1. Characteristics of patients with sympathetic ophthalmia

| | |
|--|----------|
| Number of patients with sympathetic ophthalmia | 14 |
| Sympathetic eye: initial VA | |
| VA \geq 20/70 | 7 (50%) |
| VA >20/200 to <20/70 | 3 (22%) |
| VA \leq 20/200 | 4 (28%) |
| Sympathetic eye: VA at the end of follow-up | |
| VA \geq 20/70 | 10 (71%) |
| VA >20/200 to <20/70 | 4 (29%) |
| VA \leq 20/200 | 0 (0%) |
| Characteristics of sympathizing eyes | |
| Anatomic type of uveitis | |
| • Anterior | 1 (7%) |
| • Posterior | 2 (14%) |
| • Panuveitis | 11 (79%) |
| Ocular manifestations | |
| • Mutton-fat keratic precipitates | 5 (36%) |
| • Posterior synechiae | 7 (50%) |
| • Exudative retinal detachment | 8 (57%) |
| • Optic disc edema | 10 (71%) |
| • Dalen-Fuchs nodules | 4 (28%) |
| Ocular complications | |
| • Glaucoma | 8 (57%) |
| • Cataract | 7 (50%) |
| • Macular edema | 1 (7%) |
| Inciting eye: initial VA | |
| VA 20/200 to <20/70 | 0 |
| VA \leq 20/200 | 10 |
| Inciting eye: VA at final visit | |
| VA 20/200 to <20/70 | 1 |
| VA \leq 20/200 | 8 |
| Enucleation | 5 |
| Characteristics of inciting eyes | |
| Previous history | |
| • Penetrating trauma | 10 (71%) |
| • Surgery* | 4 (28%) |
| Enucleation of inciting eyes | |
| • Before diagnosis of SO | 4 |
| • After diagnosis of SO | 1 |

SO=sympathetic ophthalmia; VA=visual acuity

* Two cases had spontaneous corneal perforation due to ulcer and underwent scleral patch

(Table 1). Patients with previous enucleation of inciting eyes had similar visual outcomes as those without (VA of 20/70 or greater in four out of five versus six out of nine; Pearson chi-square $p=0.831$).

Discussion

The present study demonstrated that despite a high rate of ocular complications, most sympathizing eyes in the Northern Thai patients with SO maintained good visual outcomes and only one third required non-steroidal immunosuppressive agents to control inflammation. Further, the present study showed that patients with previous enucleated inciting eyes had similar visual outcomes as those without enucleation.

The manifestations of SO in the Northern Thai patients were similar to the previous reports as SO developed more often after ocular trauma than after surgery and was more frequent in males^(12,14). The time between the injury and the onset of uveitis was longer in the present study than previously reported (1.75 versus 0.85 years)⁽¹³⁾. Ocular features of the sympathizing eye included disc edema and exudative retinal detachment in most cases, and these features were more common than previously observed (5% to 10%). This could be in part due to the possible delay presentation to ophthalmologist in Thailand. However, the baseline frequency of severe vision loss (VA of 20/200 or worse) in 28% of the sympathizing eye in the present study was similar to previous studies^(13,14).

In the present series, most of the sympathizing eyes developed at least one ocular complication. This high prevalence of complications could be in part influenced by the possible late initial presentation and by long-term use of corticosteroids. Prevalence of glaucoma in the present study was similar to results from U.K., and prevalence of cataract was similar to findings from South India (Table 2)⁽¹⁴⁾. The variable prevalence of complications might be explained by the differences in ethnicity, time of initial presentation, duration of follow-up and treatment regimens used.

Visual prognosis of the sympathizing eye in the present study was relatively good, though the mainstay of treatment were oral corticosteroids. Previous studies illustrated the heterogeneity in treatment among various centers. One study showed that more than half of SO patients in Singapore and U.K. did not receive immunosuppressive agents, while the majority of patients in South and North India received at least one immunosuppressive agent⁽¹⁴⁾. A study from U.S. demonstrated that 43% of SO patients received non-steroidal immunosuppressive drugs⁽¹³⁾ (Table 2). Azathioprine was the most common

Table 2. Summary of previous reports on clinical features of sympathizing eyes

| Study | Number of patients | Common ocular complications | | Treatment with immunosuppressive agents | Visual acuity at final visit $\leq 20/200$ |
|-------------------------------|--------------------|-----------------------------|----------|---|--|
| | | Glaucoma | Cataract | | |
| Present | | | | | |
| Thailand | 14 | 57.0% | 50.0% | 36.0% | 0.0% |
| Single center ⁽¹³⁾ | | | | | |
| U.S.A. | 85 | 9.0%* | 32.0% | 43.0% | 26.0% |
| Multicenter ⁽¹⁴⁾ | | | | | |
| U.K. | 30 | 46.7% | 73.3% | 43.3% | 30.0% |
| South India | 73 | 36.9% | 56.2% | 86.3% | 13.7% |
| North India | 16 | 31.3% | 12.5% | 66.7% | 6.2% |
| Singapore | 11 | 36.4% | 18.2% | 45.5% | 27.3% |

* Ocular hypertension

immunosuppressive agent prescribed in the present series, which was also the first drug of choice in India and Singapore, while mycophenolate mofetil was the most common immunosuppressive agent used in the U.K.⁽¹⁴⁾. Moreover, a beneficial prognosis in Asian patients with SO was already noticed⁽¹⁴⁾.

Previous studies claimed a favorable effect of early enucleation (within two weeks after the onset of SO) of the inciting eye on visual outcome of the sympathizing eye^(16,17). While other reported that early enucleation could decrease the number of flare-ups but did not impact visual outcome⁽¹⁸⁾. In the present series, the enucleation in this time limit was not performed. The visual outcomes of those with enucleation (later than two weeks after the onset) and those without enucleation were similar, which was already previously reported⁽¹⁴⁾. Galor et al demonstrated that exudative retinal detachment and active intraocular inflammation were significantly associated with poorer VA in the sympathizing eye, but that was not the case in the present series⁽¹³⁾.

Limitations of the present study include its retrospective character, a small number of patients with variable follow-up duration and no firm diagnostic criteria for SO. It is feasible that some of the present cases could suffer from idiopathic uveitis, mainly when manifesting a long time after the initial trauma. Due to the clinical diagnostic criteria of SO, this, however, applies to all reports on SO.

Conclusion

The present study demonstrates that SO in the Northern Thai population is characterized by panuveitis commonly associated with disc edema

and exudative retinal detachment. Despite a high rate of complications, the visual prognosis was relatively good, even with the treatment limited to corticosteroids and traditional immunosuppressive drugs.

What is already known on this topic?

Sympathetic ophthalmia is a rare, bilateral uveitis that occurs after ocular trauma or surgical procedures to one eye, where the sight-threatening inflammation develops in the fellow eye (sympathizing eye).

What this study adds?

Manifestations of SO in the Northern Thai patients were similar to the previous reports, and the visual prognosis was relatively good, even with the treatment limited to corticosteroids and traditional immunosuppressive drugs.

Acknowledgement

The authors would like to thank Chansathya Khieu, MD, Department of Ophthalmology, Faculty of Medicine, Chiang Mai University, Thailand and Khmer-Soviet Friendship Hospital, Phnom Penh, Cambodia for the English correction.

Conflicts of interest

The authors declare no conflict of interest.

References

1. Castiblanco CP, Adelman RA. Sympathetic ophthalmia. *Graefes Arch Clin Exp Ophthalmol* 2009;247:289-302.
2. Shamma HF, Zubyk NA, Stanfield TF. Sympathetic uveitis following glaucoma surgery. *Arch Ophthalmol* 1977;95:638-41.

3. Jonas JB, Back W, Sauder G, Junemann U, Harder B, Spandau UH. Sympathetic ophthalmia in vater association combined with persisting hyperplastic primary vitreous after cyclodestructive procedure. *Eur J Ophthalmol* 2006;16:171-2.
4. Bawankar P, Das D, Tayab S, Kuri GC, Medhi J, Barman M, et al. Cyclophotocoagulation-induced sympathetic ophthalmia in a Coats' disease patient supported by histopathology and immunohistochemistry. *Indian J Ophthalmol* 2017;65:744-6.
5. Albahlal A, Al Dhibi H, Al Shahwan S, Khandekar R, Edward DP. Sympathetic ophthalmia following diode laser cyclophotocoagulation. *Br J Ophthalmol* 2014;98:1101-6.
6. Jonas JB, Holbach LM, Schonherr U, Naumann GO. Sympathetic ophthalmia after three pars plana vitrectomies without prior ocular injury. *Retina* 2000;20:405-6.
7. Ahmad N, Soong TK, Salvi S, Rudle PA, Rennie IG. Sympathetic ophthalmia after ruthenium plaque brachytherapy. *Br J Ophthalmol* 2007;91:399-401.
8. Gasch AT, Foster CS, Grosskreutz CL, Pasquale LR. Postoperative sympathetic ophthalmia. *Int Ophthalmol Clin* 2000;40:69-84.
9. Chan CC, Roberge RG, Whitcup SM, Nussenblatt RB. 32 cases of sympathetic ophthalmia. A retrospective study at the National Eye Institute, Bethesda, Md., from 1982 to 1992. *Arch Ophthalmol* 1995;113:597-600.
10. Su DH, Chee SP. Sympathetic ophthalmia in Singapore: new trends in an old disease. *Graefes Arch Clin Exp Ophthalmol* 2006;244:243-7.
11. Gupta V, Gupta A, Dogra MR. Posterior sympathetic ophthalmia: a single centre long-term study of 40 patients from North India. *Eye (Lond)* 2008;22:1459-64.
12. Guzman-Salas PJ, Serna-Ojeda JC, Guinto-Arcos EB, Pedroza-Seres M. Characteristics of sympathetic ophthalmia in a single international center. *Open Ophthalmol J* 2016;10:154-9.
13. Galor A, Davis JL, Flynn HW Jr, Feuer WJ, Dubovy SR, Setlur V, et al. Sympathetic ophthalmia: incidence of ocular complications and vision loss in the sympathizing eye. *Am J Ophthalmol* 2009;148:704-10.
14. Tan XL, Seen S, Dutta MP, Ganesh SK, Agarwal M, Soni A, et al. Analysis of 130 cases of sympathetic ophthalmia - a retrospective multicenter case series. *Ocul Immunol Inflamm* 2018;1-8. doi: 10.1080/09273948.2018.1517894.
15. Jabs DA, Nussenblatt RB, Rosenbaum JT. Standardization of uveitis nomenclature for reporting clinical data. Results of the First International Workshop. *Am J Ophthalmol* 2005;140:509-16.
16. Reynard M, Riffenburgh RS, Maes EF. Effect of corticosteroid treatment and enucleation on the visual prognosis of sympathetic ophthalmia. *Am J Ophthalmol* 1983;96:290-4.
17. Lubin JR, Albert DM, Weinstein M. Sixty-five years of sympathetic ophthalmia. A clinicopathologic review of 105 cases (1913-1978). *Ophthalmology* 1980;87:109-21.
18. Kuo PK, Lubin JR, Ni C, Wang KM, Albert DM. Sympathetic ophthalmia: a comparison of the histopathological features from a Chinese and American series. *Int Ophthalmol Clin* 1982;22:125-39.