

Endoscopic Dacryocystorhinostomy Modification Techniques: A 12-Year Experience

Wanumkarng N, MD¹, Nimitwongsakul A, MD², Nimkarn A, MD³, Pongpirul K, MD, MPH, PhD^{1,4,5}

¹ Bumrungrad International Hospital, Bangkok, Thailand

² Mettapharacharak Wat Rai Khing Hospital, Nakhon Pathom, Thailand

³ Charoenkrung Pracharak Hospital, Bangkok, Thailand

⁴ Department of Preventive and Social Medicine, Faculty of Medicine, Chulalongkorn University, Bangkok, Thailand

⁵ Department of International Health, Johns Hopkins Bloomberg School of Public Health, Baltimore, MD, USA

Objective: The present study was aimed to systematically explore how modifications to the original endoscopic dacryocystorhinostomy (DCR) contributed to the success or failure of the outcome.

Materials and Methods: Procedure and clinical outcome data in the Thai endoscopic dacryocystorhinostomy (TED) Collaborative were analyzed and compared with various modified endoscopic DCR techniques identified from published literatures. Main outcome measures were improved symptom of tearing, free flow of lacrimal sac irrigation, and ostium patency. The three periods of surgical technique modifications were 2004 to 2005, 2006 to 2007, and 2008 to 2015. The detailed steps of the present study approaches are described and comparatively discussed with the approaches used by the others.

Results: TED data contained 729 operations (primary NLDO 89.30%) performed in 537 patients (male 17.88%, age 58.29 years) at three sites between 2004 and 2015. Overall success rate was 92.04%. Primary DCR had significantly better success than revision DCR (93.55% versus 79.49%, $p < 0.001$). Between 2004 and 2005, the conventional antero-posterior flap without suturing was performed in 150 operations with unsatisfactory outcomes. The success rate increased from 81.33% to 88.52% for 270 operations performed between 2006 and 2007. This is mainly because of the adequate bone removal, assessed by using the "45-degree" test, and partly because of the supero-inferior flap with suturing that was introduced in selected cases. Additionally, the suturing was added to the antero-posterior flap technique. The suturing was aimed to promote primary intention healing. The success rate dramatically increased in the 309 operations performed between 2008 and 2015 because of appropriate selection of flap creation and suturing technique in addition to the use of the "45-degree" test to ensure adequate bone removal.

Conclusion: The improvement of endoscopic DCR outcomes has been contributed by at least two key modifications to the original technique, which are adequate bone removal assessed by using the "45-degree" test and primary intention healing using flap creation and suturing.

Keywords: Dacryocystorhinostomy, 45-Degree test, Nasolacrimal duct obstruction

J Med Assoc Thai 2019;102(7):783-8

Website: <http://www.jmatonline.com>

Received 15 Mar 2019 | Revised 6 Jun 2019 | Accepted 7 Jun 2019

Dacryocystorhinostomy (DCR) has been a procedure of choice for nasolacrimal duct obstruction (NLDO) for more than a century⁽¹⁾. The main goal was to create a bypass tract for better drainage system. Endoscopic approach has been replacing external

DCR for no scar or lacrimal pumping disturbance and faster recovery time⁽¹⁾.

The improved success rates from 92%⁽²⁾ to 96%⁽³⁾ have been from some modifications to the original approach. In 2003, Tsirbas and Wormald created anterior and posterior flaps in the lacrimal sac with nasal mucosa preserved. To improve flap approximation, Kirtane et al added suture to the flaps⁽⁴⁾. It is worth to note that the outcome of some non-mechanical techniques such as laser have not been promising (Table 1).

There has been no systematic comparison of

Correspondence to:

Pongpirul K.

Department of Preventive and Social Medicine, Faculty of Medicine, Chulalongkorn University, Bangkok 10330, Thailand.

Phone: +66-86-6055088

Email: doctorkrit@gmail.com

How to cite this article: Wanumkarng N, Nimitwongsakul A, Nimkarn A, Pongpirul K. Endoscopic Dacryocystorhinostomy Modification Techniques: A 12-Year Experience. J Med Assoc Thai 2019;102:783-8.

Table 1. Success rates of DCR

	n	Success rates
Overall	729	92.04%
Primary DCR	651	93.55%
Primary NLDO	545	93.63%
Acute dacryocystitis	57	92.59%
Chronic dacryocystitis	27	96.15%
Congenital NLDO	12	100.00%
Secondary NLDO	10	77.78%
Revision DCR	78	79.49%

DCR=dacryocystorhinostomy; NLDO=nasolacrimal duct obstruction

various aspects and outcomes across the techniques. In a large single-surgeon series with 1,083 cases performed in Korea between 2007 and 2013 with 92.7% success rate, no detail on technique modification was given, resulting in limited improvement opportunity.

Thai endoscopic dacryocystorhinostomy (TED) Collaborative is the national initiative of ophthalmologist network with special training in DCR. The present study aimed to share the authors' experiences with systematic modifications to DCR technique and outcome of 729 operations.

Materials and Methods

TED database was a collection of demographics and clinical characteristics of 729 operations in 537 patients from 24 countries that underwent Endoscopic DCR performed by a single surgeon at the three eye institutes in Thailand between 2004 and 2005, 2006 and 2007, and 2008 and 2015, respectively. Thirty-seven cases with incomplete data were excluded from the study. A relevant history and eye examination were performed in all cases, including slit-lamp biomicroscopy, lacrimal sac syringing, ocular surface evaluation, and endoscopic evaluation of nasal cavity. Clinical outcome was assessed using anatomical improvement of the lacrimal duct obstruction.

Preoperative assessment

The pre-operative diagnosis based on eye examination and lacrimal syringing of the lacrimal drainage system to identify level of the blockage was done by responsible ophthalmologist. Patients diagnosed of primary NLDO, acute or chronic dacryocystitis, congenital NLDO, secondary NLDO following trauma, and patients with history of failed external or endoscopic DCR were included in the

present study. All cases of functional epiphora were excluded.

The modified endoscopic DCR

The endoscopic DCR was performed using a 30-degree side viewing endoscope, under general anesthesia. Nasal packing was done with rolled gauze soaked with 0.05% oxymethazoline solution. Three milliliters of 2% lidocaine with adrenaline (1:80,000) was injected into nasal mucosa just anterior to the axilla of middle turbinate. The sharp end of Freer periosteal elevator was used to create the 12-mm vertical incision started at 6 mm above the insertion of the middle turbinate. Then, sharp-end Steven scissors were used to extend the incision posteriorly in horizontal fashion. The posterior-based nasal flap was removed with Takahashi nasal forceps to expose frontal process of maxillary and lacrimal bone. The lower two-third of the bone was removed with 2-mm and 3-mm Kerrison Rongeur. The upper one-third was removed with 4-mm beveled edge chisel and mallet. The thin lacrimal bone was elevated and removed with Blakesley nasal forceps. The adequacy of removed bone was assessed using "45-degree test" as followed: insert Bowman probe horizontally (0 degree) through upper punctum then pass along the canaliculus, and common canaliculi to reach lacrimal sac (Figure 1a). The probe was rotated adductly until a 45-degree angle was formed (Figure 1b, c). Then, the tip of the Bowman probe was moved upwardly and medially (Figure 1d, e). The bone removal/adequacy assessment were repeated until the septal mucosa was reached by the probe with no resistance (Figure 1f).

Then, the medial wall of lacrimal sac was cut vertically with 15-degree straight stab blade. The upper and lower end of the vertical incision was extended anteriorly and posteriorly in horizontal fashion to create the anterior and posterior flap with Sickle knife. Flap suturing was done using S-24 8.00 mm 6-0 Coated VICRYL (Ethicon US, LLC), which was manually bended from ¼ circle to ½ circle shape to facilitate the suturing procedure in such a narrow cavity (the newly designed 8.00 mm 6-0 ½ circle is being patented). Bicanalicular intubation was performed. Gel foam was placed at the ostium. Triamcinolone acetonide solution 20 mg (0.5 ml of 40 mg/ml) was injected at surrounding nasal mucosa.

Postoperative assessment

The patients were followed up at day 1, day 7, day 30, day 90, day 180, and yearly after the surgery. The symptoms and sac syringing were evaluated

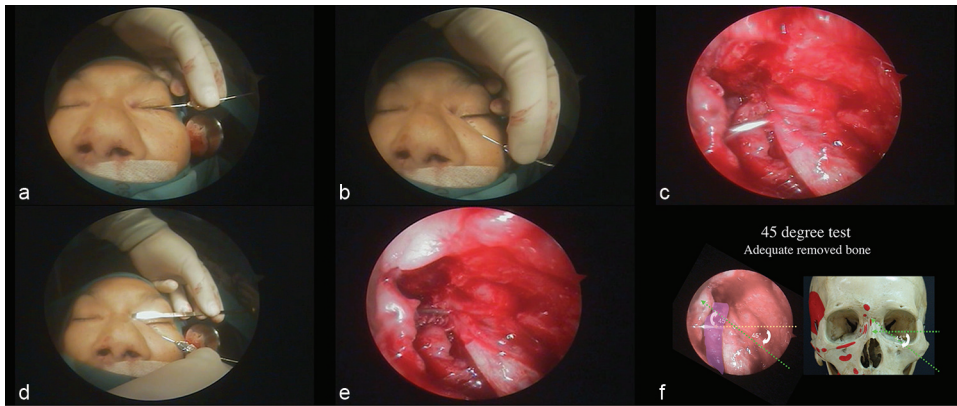


Figure 1. “45-degree” test for bone removal adequacy assessment. (a) Horizontal insertion of Bowman probe. (b) Adduct rotation of Bowman probe. (c) Zero degree of Bowman probe (endoscopic view). (d) 45-degree of Bowman probe (surgeon view). (e) 45-degree of Bowman probe (endoscopic view). (f) Adequate bone removal (pink area).

during each visit by an ophthalmologist (Wanumkarng N). Surgical success was defined as symptoms free, 100% free flow of lacrimal sac irrigation, and patency of the ostium, which was confirmed by endoscopic examination post-operatively. Post-operative functional epiphora was diagnosed in a patient with persistent post-operative tearing with 100% free flow in lacrimal sac irrigation. All of the unsuccessful cases were reviewed to identify potential causes and revision surgery was then performed by the first author (Wanumkarng N).

Statistical analysis

Descriptive statistics (means and standard deviation) were used to analyze the data as appropriate. Categorical variables were compared using chi-square or Fisher’s exact test.

Ethical consideration

The present study was approved by the Bumrungrad International Institutional Review Board (BI/IRB No.225-04-16 Dh Exp).

Results

Demographics

Five hundred thirty-seven patients (male 17.88%, mean age 58.29 years) that received 729 DCR operations (right side 51.58%) were included in this study. Most of the patients (87.15%) were Thai, followed by Middle Eastern (5.96%), non-Thai Asians (4.47%), Caucasian (2.05%), and African (0.37%). The three sites performed 371, 249, and 109 operations.

Etiologies of NLDO

Of the 729 operations performed, 89.30% were primary and 10.70% were revision DCR. Of primary DCR, 83.87%, 8.76%, 4.15%, 1.84%, and 1.54% were primary NLDO, acute dacryocystitis, chronic dacryocystitis, congenital NLDO, and secondary NLDO following trauma, respectively.

Clinical outcomes

Of the 537 patients, overall success rate was 90.88%. Of 729 operations, overall success rate was achieved in 671 operations (92.04%) (Table 1). Primary DCR had significantly higher success rate than revision DCR (93.55% versus 79.49%, respectively; $p < 0.001$). Subgroup analysis revealed comparable success rates across various etiologies of the obstruction except secondary NLDO, which had the lowest success.

Of the 78 revision DCR, 75.64% required only one revision to cure whereas 17.95%, 5.13%, and 1.28% required two, three, and four revisions before satisfactory outcomes were achieved, respectively, (mean 1.32 revisions). The success rate of the first and second revision was 83.93% and 61.54%, respectively.

TED N1 (2004 to 2005)

Between 2004 and 2005, the conventional antero-posterior flap without suturing (Figure 2a, b) was performed in 150 DCR operations (115 primary and 35 revision DCR) in 96 cases, which yielded 81.33% overall success rate. The success rate of primary DCR operation was 84.35%, compared with 71.43% of revision DCR.

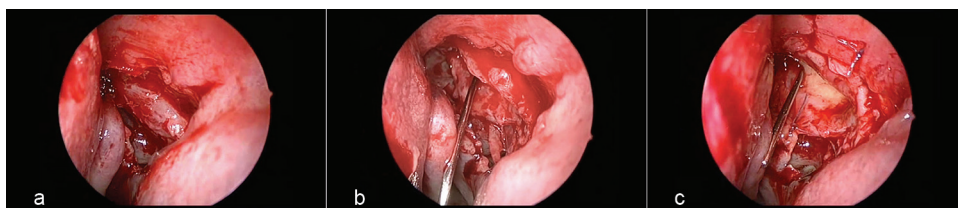


Figure 2. Antero-posterior flaps. (a) Medial wall of lacrimal sac (before lacrimal sac opening). (b) I-shaped incision of the lacrimal sac. (c) Suturing of the antero-posterior flaps.

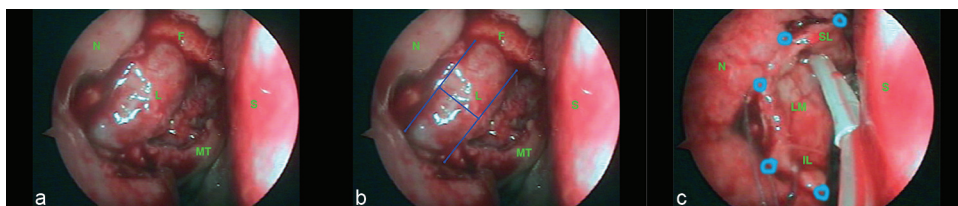


Figure 3. Supero-inferior flaps. (a) Medial wall of distended lacrimal sac (before lacrimal sac opening). (b) H-shaped incision of the lacrimal sac. (c) Suturing of the supero-inferior flaps.

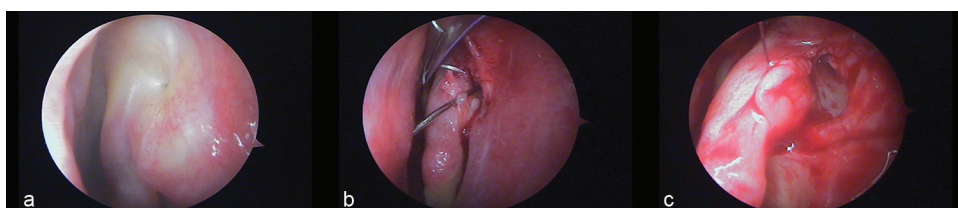


Figure 4. Sump syndrome (failed DCR). (a) Fibrotic tissue of lacrimal sac. (b) Suturing of the isolated flaps (before). (c) Suturing of the isolated flaps (after).

TED N2 (2006 to 2007)

To improve the success rate, supero-inferior flap with suturing was introduced in selected cases in 2006 (Figure 3) whereas the suturing was added to antero-posterior flap technique (Figure 2c).

The overall success rate of 88.52% was achieved in 270 operations (226 primary and 44 revision DCR operations) performed in 204 cases using the first modified version of DCR (N2 TED). The success rate of primary DCR operation was 88.94%, compared with 86.36% of revision DCR.

While removal of the lower two-third of the frontal process of maxillary bone was easily performed using Kerrison rongeur, the upper one-third portion should be removed carefully using the following steps. Chisel and mallet were used for initial bony removal of the upper one-third frontal process of maxillary bone. To prevent cerebrospinal fluid (CSF) leakage from excessive bony removal, it is critical that the bone was meticulously removed, and the adequacy of

bone removal should be assessed using a “45-degree” test as described earlier (Figure 1).

TED N3 (2008 to 2014)

With the third generation of the modification to DCR technique, all 309 operations (308 primary and 1 revision DCR operations) performed in 237 cases were successful as of the most recent follow-up visits (success rate 100%). The key steps for uncomplicated cases were 1) partially remove lower two-third of frontal process of maxillary bone, 2) perform 45-degree test and remove the upper one-third as necessary, 3) perform I-shaped incision of the medial wall of lacrimal sac to create antero-posterior flaps (Figure 2a, b), and 4) suture the anterior flap (Figure 2c).

In patients with distended lacrimal sac, after performing the first two steps, an H-shaped incision of the medial wall of the lacrimal sac was done to create supero-inferior flaps (Figure 3a, b) then both

Table 2. Development of endoscopic DCR

	McDonogh et al. ⁽¹⁾	Durvasura et al. ⁽²⁾	Tsirbas et al. ⁽⁶⁾	TED N1	Sonkhya et al. ⁽⁷⁾	Kirtane et al. ⁽⁴⁾	TED N2	TED N3
Year	1989	1997 to 2000	1999 to 2001	2004 to 2005	2003 to 2006	2006 to 2009	2006 to 2007	2008 to 2015
No. of patients	N/A	70	86	96	226	20	204	237
No. of operations	N/A	75	104	150	226	23	270	309
Success rate (anatomical)	N/A	92%	95%	81%	92%	87%	89%	100%
Oculoplastic	N	Y	N	Y	Y	Y	Y	Y
ENT	Y	Y	Y	N	Y	Y	N	N
Septoplasty	N/A	Y (2.85%)	Y (46%)	N	Y (36%)	N	N	N
Bone removal instruments	N	Rongeur	Rongeur/ drill	Rongeur/ chisel & mallet	Rongeur/ chisel & mallet/drill	Rongeur/ drill	Rongeur/ chisel & mallet	Rongeur/ chisel & mallet
45-degree test	N	N	N	N	N	N	Y	Y
Instrument for opening lacrimal sac	Rosen curette	Ophthalmic keratome	Scalpel	15-degree blade, sickle knife	Ophthalmic keratome, sickle knife	Scalpel	15-degree keratome sickle knife	15-degree blade, sickle knife
Flap - AP	N	N/A	Y	Y	Y	Y	Y	Y
Flap - SI	Y	N/A	N	N	N	N	Y	Y
Flap - combined	N	N/A	N	N	N	N	N	Y
Flap suturing	N	N	N	N	N	Y	Y	Y
Silicone stent	N	Y	Y	Y	N	N	Y	Y
Mitomycin C	N	N	N	N	N	Y	N	N
Anesthesia - general	Y	Y (15%)	Y	N	Y	Y	Y	Y
Anesthesia - local	Y	Y (85%)	N	N	Y	N	N	N
IV sedation	N	N	N	Y	N	N	Y	N

DCR=dacryocystorhinostomy; TED=Thai endoscopic dacryocystorhinostomy; AP=anterio-posterior; SI=supero-inferior; IV=intravenous; N/A=not available

flaps were sutured (Figure 3c).

In some failed cases (sump syndrome), the 'isolated flap' technique was done by a vertical incision of the fibrotic tissue of the lacrimal sac (Figure 4a, b), then the posterior flap was sutured to the middle turbinate (Figure 4c).

No cases of CSF fluid leakage or orbital tissue damage were found. Five cases had post-operative nasal bleeding within the first week, which were easily managed by anterior nasal packing with oxymethazoline-soaked gauze.

Discussion

The present study showed not only the clinical outcome of 729 endoscopic DCR operations performed in 12 years, but also the comparative analysis of the outcomes across various modifications to the original endoscopic DCR technique introduced in cadaver

by Rice in 1988⁽⁵⁾, and in human by McDonogh and Meiring in 1989⁽¹⁾, Durvasura and Gatland (1997 to 2000)⁽²⁾, Tsirbas and Wormald (1999 to 2001)⁽⁶⁾, Sonkhya and Mishra (2003 to 2006)⁽⁷⁾, and Kirtane et al (2006 to 2009)⁽⁴⁾. Table 2 presents a brief summary of endoscopic DCR development.

The unsatisfactory outcomes during the first period resulted in an attempt to identify potential determinants of success. The authors' initial belief that primary intention healing by flap suturing, as performed in external DCR, could not only reduce bleeding but also prevent formulation of granulation or scar tissues and, therefore, a better outcome was later confirmed by at least two randomized controlled trials^(8,9) presented in the recent meta-analysis⁽¹⁰⁾. However, limited information about effect of the flap shapes had been available before the present study. As antero-posterior flaps were not suitable for some

chronic dacryocystitis cases with distended lacrimal sac, supero-inferior flaps were tried (Figure 3a). The superior flap was always sutured to reduce anticipated gravity effect whereas the inferior flap suturing was optional, depending on the intraoperative judgement of the surgeon. This supero-inferior flaps with suturing technique are partly comparable to the “inferiorly based flap” introduced by McDonogh and Meiring in 1989⁽¹⁾, of which the suturing was always done because of the shape of the inferior flap created. Another important lesson was the inadequate bone removal found in most of the failed cases during the first period. Therefore, the authors tried intraoperative assessment of the adequacy of bone removal and the “45-degree” test was simple and useful enough for this purpose.

It should be noted that the success rates of each team presented in Table 2 were not directly comparable. The improved success rates of TED N1, N2, and N3 might be contributed partly by the learning curve effect⁽¹¹⁾. In addition, the relatively poorer visibility of the endoscope unit used in TED N1 might also contribute to the worse clinical outcome than TED N2 and N3.

Conclusion

The improvement of endoscopic DCR outcomes has been contributed by at least two key modifications to the original technique, which are the adequate bone removal assessed by using the “45-degree” test and the primary intention healing using flap creation and suturing.

What is already known on this topic?

DCR is a procedure of choice for nasolacrimal duct obstruction. Many modifications to the endoscopic DCR have been attempted but the modified procedures and outcomes have not been systematically compared.

What this study adds?

This study elaborates on various modifications of the endoscopic DCR technique applied in a large series of patients. This study adds to the literature that adequate bone removal assessed by using the 45-degree test and primary intention healing using flap creation and suturing are the two critical determinants for the successful clinical outcomes.

Meeting presentation

The American Academy of Ophthalmology Annual Meeting, 2016 (Chicago)

- Best Poster Award: Wanumkarng N, Nimkarn A, Nimitwongsakul A, Chandraparnik P, Pongpirul K. Endoscopic Dacryocystorhinostomy: A 12-Year Experience with 729 Operations.
- Fan Favorite Award: Wanumkarng N. Classification of Flap Suturing and 45 Degree Test for Endoscopic DCR.

Conflicts of interest

The authors declare no conflict of interest.

References

1. McDonogh M, Meiring JH. Endoscopic transnasal dacryocystorhinostomy. *J Laryngol Otol* 1989;103:585-7.
2. Durvasula VS, Gatland DJ. Endoscopic dacryocystorhinostomy: long-term results and evolution of surgical technique. *J Laryngol Otol* 2004;118:628-32.
3. Jin HR, Yeon JY, Choi MY. Endoscopic dacryocystorhinostomy: creation of a large marsupialized lacrimal sac. *J Korean Med Sci* 2006;21:719-23.
4. Kirtane MV, Lall A, Chavan K, Satwalekar D. Endoscopic dacryocystorhinostomy with flap suturing. *Indian J Otolaryngol Head Neck Surg* 2013;65:236-41.
5. Rice DH. Endoscopic intranasal dacryocystorhinostomy-a cadaver study. *Am J Rhinol* 1988;2:127-8.
6. Tsirbas A, Wormald PJ. Endonasal dacryocystorhinostomy with mucosal flaps. *Am J Ophthalmol* 2003;135:76-83.
7. Sonkhya N, Mishra P. Endoscopic transnasal dacryocystorhinostomy with nasal mucosal and posterior lacrimal sac flap. *J Laryngol Otol* 2009;123:320-6.
8. Ji QS, Zhong JX, Tu YH, Wu WC. New mucosal flap modification for endonasal endoscopic dacryocystorhinostomy in Asians. *Int J Ophthalmol* 2012;5:704-7.
9. Khalifa MA, Ragab SM, Saafan ME, El Guindy AS. Endoscopic dacryocystorhinostomy with double posteriorly based nasal and lacrimal flaps: a prospective randomized controlled trial. *Otolaryngol Head Neck Surg* 2012;147:782-7.
10. Green R, Gohil R, Ross P. Mucosal and lacrimal flaps for endonasal dacryocystorhinostomy: a systematic review. *Clin Otolaryngol* 2017;42:514-20.
11. Lee JJ, Lee HM, Lim HB, Seo SW, Ahn HB, Lee SB. Learning curve for endoscopic endonasal dacryocystorhinostomy. *Korean J Ophthalmol* 2017;31:299-305.