

# Endoscope-Assisted Stapedotomy with Microdrill: Comparison with a Conventional Technique

Yuvatiya Plodpai MD\*,  
Viraporn Atchariyasathian MD\*, Wandee Khaimook MD\*

\* Department of Otolaryngology, Faculty of Medicine, Prince of Songkla University, Hatyai, Songkhla, Thailand

**Objective:** To compare endoscope-assisted microdrill stapedotomy with the conventional technique.

**Material and Method:** A retrospective comparative study of 37 otosclerosis stapes fixation surgeries performed with the conventional technique or the endoscope-assisted microdrill stapedotomy were evaluated. Audiometric data and intraoperative and postoperative complications were recorded.

**Results:** The mean operating time was 128 min in the endoscopic group and 132 min in the conventional group, ( $p = 0.72$ ). Residual air-bone gaps of  $\leq 10$  decibels were obtained in 83.3% and 47.4% of the patients in the endoscopic group and the conventional group, respectively, ( $p = 0.04$ ). No footplate fractures and incidences of postoperative vertigo and chorda tympani nerve injuries were found in the endoscopic group. Postoperative vertigo was found in 31.6% of the conventional group, and 26.3% of the patients in the conventional group had undergone an endaural surgical approach owing to inadequate exposure under the microscope.

**Conclusion:** An endoscope-assisted microdrill stapedotomy was associated with significantly better hearing results, a lower postoperative vertigo rate, and fewer footplate fractures and chorda tympani nerve injuries than the conventional technique.

**Keywords:** Otosclerosis, Endoscope, Microscope, Stapedotomy, Microdrill

*J Med Assoc Thai* 2017; 100 (2): 190-196

Full text. e-Journal : <http://www.jmatonline.com>

There have been a number of significant advances in otosclerosis surgery in recent years. The small fenestra stapedotomy has evolved from the stapedectomy to enhance hearing outcome and minimize complications. The fenestration technique on the stapes footplate is often employed based on the surgeon's preference and the availability of necessary instruments, such as a handheld perforator, microdrill, or laser. Although potential inner ear trauma due to drilling vibrations has been a concern, many studies have shown excellent postoperative air-bone gap closure by using a microdrill to create a fenestra without long-term postoperative sensorineural hearing loss<sup>(1-3)</sup>. We introduced the microdrill technique instead of a hand drill because it provided precise cutting at the

footplate, and was less traumatic than the conventional procedure.

Most preferred surgical approaches to the middle ear either use a transcanal or an endaural approach under an operating microscope. In cases of a narrowing or curved ear canal, transmeatal exposure is limited and more extensive drilling of the bony canal is often needed. Endoscopy has had an increasing role in otologic surgery because of several advantages associated with this technique. Unlike microscope-assisted surgery, the endoscope-assisted approach is much more useful in providing adequate views of the entire stapes, the pyramidal eminence, the round window, and the tympanic segment of the facial nerve, while minimizing exposure. Stapes mobilization was also facilitated by this approach. Poe et al<sup>(4)</sup>, in 2000, was credited with introducing the endoscope in stapes surgery. Recently, a number of studies examining the benefits of the endoscope-assisted approach in stapes surgery have been published<sup>(5-7)</sup>. However, to date there have been no studies comparing the results of the microdrill

---

**Correspondence to:**

Plodpai Y, Department of Otolaryngology, Faculty of Medicine, Prince of Songkla University, Hatyai, Songkhla 90110, Thailand.  
Phone: +66-74-451390, Mobile: +66-81-5988403,  
Fax: +66-74-429619,  
E-mail: yuva078@hotmail.com

stapedotomy using the endoscopic approach, to the conventional technique.

The present study aimed to compare outcomes of the endoscope-assisted approach with a microdrill stapedotomy, with the conventional technique, in terms of hearing improvement and postoperative complication.

### Material and Method

The present study was based on a retrospective review of medical and surgical records of patients having otosclerosis stapes fixation, and underwent a stapedotomy from January 2012 to October 2014. The Prince of Songkla University's Institutional Review Board approved the study. The study adhered to the tenets of the Declaration of Helsinki. The patients were divided into two groups, a conventional group and an endoscopic group. The endoscopic group was defined as patients in whom the procedure was performed using an endoscope with a microdrill to create a fenestration in the footplate. The conventional group was defined as patients in whom the procedure was using an operating microscope, and the handheld perforator to establish a fenestration in the footplate.

All procedures were performed under local anesthesia, in an outpatient setting. Preoperative and postoperative audiometric evaluations were performed for each patient, including pure tone threshold averages (PTA) of air conduction (AC) and bone conduction (BC), at frequencies of 0.5, 1, 2, and 4 kilohertz (kHz). Air-bone gaps (ABG) were calculated from the difference between air conduction and bone conduction averages. Preoperative variables, including: age, sex, side of surgery, contralateral ear status, duration of operation, and intraoperative and postoperative complications, were collected. The primary outcome measure was hearing improvement. The secondary outcomes were intraoperative and postoperative complications, including chorda tympani nerve injury, footplate fracture, sensorineural hearing loss, and vertigo. Hearing improvement was defined as a postoperative ABG of 10 decibels (dBs) or less. The audiological outcomes were evaluated at 2 and 6 months postoperatively.

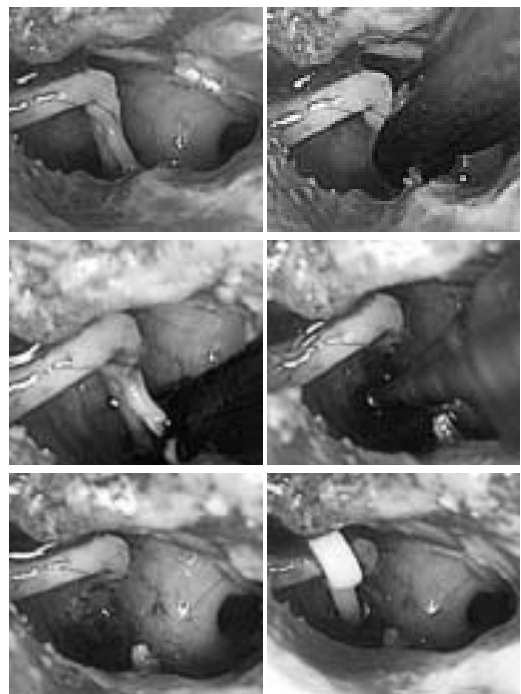
### Instruments

For the endoscopic group, two rigid endoscopes, one of 4 mm in diameter, and 18 cm in length with a 0° angle of view, a second endoscope of 2.7 mm in diame-

ter, and 14 cm in length with a 30° angle of view, were used together with a high-definition camera head and monitor (Karl Storz, Tuttlingen, Germany). A 0.7-mm microdrill (Skeeter Otologic Drill System; Medtronic Xomed Surgical Products, Inc., Jacksonville, FL, USA) with a diamond tip was used to create a round fenestra in the footplate. For the conventional group, a Zeiss OPMI 111 (Carl Zeiss, Jena, Germany) operating microscope was used, and the hand perforator was used to create a fenestra in the footplate. A standard ear surgery set and prosthesis were used similarly in both groups.

### Surgical technique

In the endoscopic group, the entire tympanic membrane was visualized through the ear canal. All surgical steps were performed under endoscopic visualization (Fig 1). An operating microscope was kept available in case of any unexpected problems. The four quadrants of the external ear canal were injected with 2% xylocaine with a 1:80,000 dilution



**Fig. 1** (A) An endoscopic view of the ossicular chain and otosclerosis foci. (B) The stapedius tendon section. (C) The posterior crus divided by the Fisch crurotomy scissors. (D) The hole in the footplate, made with the microdrill. (E) A round fenestra in the footplate. (F) The piston prosthesis inserted into the fenestra and fixed around the long process of the incus.

**Table 1.** Patient demographics and baseline audiometric data of the study ears in the groups undergoing a stapedotomy by using an endoscope with a microdrill (the endoscopic group) versus those using an operating microscope (the conventional group)

	Endoscopic group (n = 18)	Conventional group (n = 19)	p-value
Age (years ± SD)	44.8±12.1	42.2±11.7	0.51 <sup>a</sup>
Male/female, n (%)	15 (83)/3 (17)	16 (84)/3 (16)	0.92 <sup>b</sup>
Right/left, n (%)	9 (50)/9 (50)	6 (32)/13 (68)	0.42 <sup>c</sup>
Preoperative PTA of air conduction (dBs ± SD)	63.8±9.8	58.3±8.0	0.14 <sup>a</sup>
Preoperative PTA of bone conduction (dBs ± SD)	27.7±7.1	23.5±6.1	0.35 <sup>a</sup>
Preoperative air-bone gaps (dBs ± SD)	38.1±7.6	35.2±5.9	0.21 <sup>a</sup>
Mean operative time (minutes ± SD)	128.0±27.1	131.9±38.7	0.72 <sup>a</sup>

PTA = pure-tone threshold averages; dBs = decibels; SD = standard deviation

<sup>a</sup>Independent t-test; <sup>b</sup>Fisher's exact test; <sup>c</sup>Pearson's chi-square test

of epinephrine (M&H Manufacturing Co., Ltd., Samautprakarn, Thailand). The tympanomeatal flap was created and elevated to the annulus. The annulus was elevated from its sulcus, from 6 o'clock inferiorly to 12 o'clock superiorly. The middle ear was entered, preserving the chorda tympani nerve. The bony canal in the posterior-superior quadrant was removed using a 1.4-mm microdrill, and together with a bone curette, was continued until the optimal exposure was reached. The optimal exposure for a stapedotomy requires good visualization of the entire stapes, the long process of the incus, the tympanic segment of the facial nerve, the pyramidal eminence with the stapedius tendon, and the round window niche. The malleus and incus were gently palpated to assess their mobility. The mobility of the stapes was also examined. The patency of the round window and location of the facial nerve were examined. The incudostapedial joint was separated with an angle pick. The stapedius tendon was sectioned with scissors, and the posterior crus was cut with crurotomy scissors. The residual stapes arch was fractured toward the promontory and removed. The distance between the footplate, to the long process of the incus, was measured with a House-measuring rod. A 0.7-mm microdrill with a diamond tip was used to create a round fenestra in the footplate. A Causse loop

piston of 0.6-mm diameter (Medtronic Xomed Surgical Products, Inc.) was used. Then, the piston was inserted into the perforation of the footplate and fixed to the long process of the incus. The tympanomeatal flap was repositioned, and hearing was checked immediately. Spongostan® (Ferrosan Medical Devices, Soeborg, Denmark) soaked with antibiotic ointment was placed on the tympanomeatal flap. Patients were discharged from the hospital a few hours after surgery. In the conventional group, the surgical steps and sequence were performed similar as the endoscopic group, except all procedures were performed under operating microscope, and a handheld perforator was used to create the fenestra in the footplate.

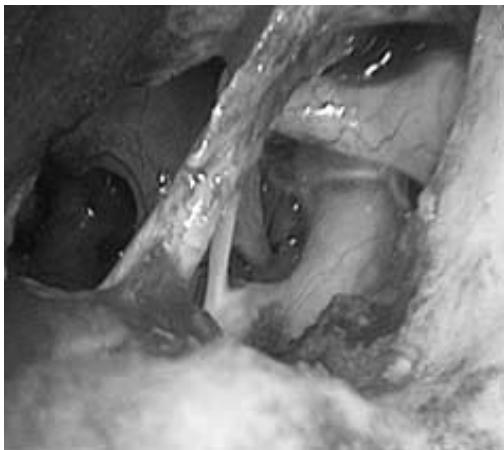
## Results

A total of 37 operations in 36 patients were reviewed retrospectively. The conventional technique was performed on 19 ears (18 patients) and the endoscope assisted with microdrill stapedotomy technique was used in 18 patients. The two groups were comparable regarding to age, sex, side of operation, preoperative ABG, AC, and BC threshold. The demographic and audiometric data were summarized in Table 1. The mean operating time was 128 min in the endoscopic group and 131.9 min in the conventional

**Table 2.** Comparison of the postoperative hearing outcomes and complications of the endoscopic group versus the conventional group

	Endoscopic group (n = 18)	Conventional group (n = 19)	<i>p</i> -value
Postoperative PTA of air conduction (dBs ± SD)	33.7±9.7	38.1±17.7	0.37 <sup>a</sup>
Postoperative PTA of bone conduction (dBs ± SD)	27.0±8.4	23.9±6.0	0.20 <sup>a</sup>
Postoperative air-bone gaps, median (IQR)	5.5 (5, 8.8)	13 (2, 17)	0.26 <sup>b</sup>
Residual air-bone gaps of			
≤ 10 dBs, n (%)	15 (83.3)	9 (47.4)	0.04 <sup>c</sup>
11–20 dBs, n (%)	3 (16.7)	6 (31.6)	
> 20 dBs, n (%)	0	4 (21.0)	
Vertigo, n (%)	0	6 (31.6)	0.02 <sup>c</sup>
Footplate fracture, n (%)	0	1 (5.3)	0.98 <sup>c</sup>
Chorda tympani nerve injury, n (%)	0	2 (10.5)	0.49 <sup>c</sup>

PTA = pure-tone threshold averages; dBs = decibels; SD = standard deviation; IQR = interquartile range. <sup>a</sup>Independent t-test; <sup>b</sup>Wilcoxon rank-sum test; <sup>c</sup>Fisher's exact test



**Fig. 2** The optimal exposure with minimal posterosuperior bony wall removal under a 30° endoscopic view.

group, no significant difference between these two groups (t-test,  $p = 0.72$ ).

### Postoperative hearing outcomes

The postoperative hearing outcomes of the endoscopic group and the conventional group were listed in Table 2. The mean postoperative AC and BC

threshold and the mean ABG were comparable. In the endoscopic group, a residual ABG of 10 dBs or less was obtained in 15 patients (83.3%) and a residual ABG of 20 dBs or less was obtained in all patients. In the conventional group, the ABG was within 10 dBs in 47.4% of the patients, and within 20 dBs in 78% of the patients ( $p = 0.04$ ). There were no significance differences between preoperative and postoperative BC thresholds in the two groups. The postoperative ABG and mean air conduction threshold were satisfactory in the endoscopic group.

### Intraoperative and postoperative complications

Although differences in footplate fracture and chorda tympani nerve injury between the two groups were not significant (Fisher's exact test,  $p = 0.98$  and  $0.49$ , respectively), both complications occurred in the conventional group and none in the endoscopic group. Remarkably, there was postoperative vertigo 31.6% in the conventional group, and 26.3% of the patients in the conventional group had undergone endaural surgical procedures due to inadequate exposure under the microscope. Complications were summarized in Table 2.

## Discussion

The choice of the stapedotomy approach is the surgeon's preference; however, the surgical approach affects the surgical outcome. A safe and effective stapedotomy requires good exposure of the middle ear, because an adequate access pathway provides clear visualization of the middle ear anatomy and eases the introduction of the required surgical micro-instruments. The endoscope-assisted approach is a worthwhile surgical technique, because it not only allows for excellent vision of the ossicular chain and neighboring structures, but also allows the stapes surgery to be performed in as minimally invasive as possible, and also effective in approaching a narrowing or curved external ear canal<sup>(4)</sup>. However, using the transcanal or an endaural approach under an operating microscope involves restricted operative views with extensive bone drilling as necessary.

We reported an optimal hearing improvement with a residual air-bone gap of 10 dBs or less in 83.3% of the patients in the endoscopic group, and a residual air-bone gap of 20 dBs or less was obtained in 100% of the patients in the endoscopic group. These results were comparable to previous studies<sup>(2,5)</sup>. Our study showed that satisfactory stapedotomy results could be obtained from the endoscope-assisted approach with microdrill. No footplate fractures, postoperative vertigo, and chorda tympani nerve injuries were found in the endoscopic group. One-fourth of the patients in the conventional group required an endaural incision because the visualization under the microscope was limited.

To expose the entire stapes and oval window, the bony canal at the posterior scutum must be removed. The exposure should provide a view of the origin of the stapedius tendon at the pyramidal eminence and its insertion at the neck of the stapes, as well as the anterior and posterior crural region of the stapes, (Fig 2). Under the endoscope, bone drilling or curettage can be minimized with minimal effort, which can help avoiding a subsequent retraction pocket. Kojima et al. performed a total endoscopic stapedotomy by using a 0° endoscope with minimal drilling<sup>(5)</sup>. Migirov and Wolf demonstrated a complete procedure under direct endoscopic viewing, without drilling of the scutum or mobilization of the chorda tympani nerve<sup>(6)</sup>. The risk of inadvertent chorda tympani nerve injury was reduced<sup>(6)</sup>.

In the present study, there were no cases with chorda tympani nerve section, tympanic membrane perforation, or incus subluxation in the endoscopic group. The anterior and posterior stapedius crus were carefully fractured clearly, under direct endoscopic views. This surgical step was done blindly when the microscope was used<sup>(7)</sup>. It was noteworthy that such meticulous surgical techniques could be obtained with careful concentration to detail, when using the endoscope. This could explain why postoperative vertigo in the endoscopic group was less than in the conventional group.

The main disadvantage of the endoscope was loss of stereoscopic vision, which is important in depth perception and the ability to judge distances accurately. Practice and sharp image quality could help to develop mechanisms to compensate for this drawback. The other limitation of the endoscopic approach is that a one-handed technique is required. Stapes surgery under an operating microscope is also a single-handed procedure, as the surgeon is required to hold the ear speculum with one hand.

There is as yet no consensus on the optimal fenestration technique, which often depends on the surgeon's preference, skills, and the availability of the instrument. In our study, the microdrill was used to create the fenestra, owing to several advantages of this instrument, including ultralight weight, low torque, low noise intensity, a long thin guide shaft, very fine tip, and availability and suitability for endoscope-assisted transmeatal surgery. The shape of the fenestra in the footplate performed by the microdrill had smooth edges, and was round, better than the hand perforator-performed fenestra. It was able to drill out the bone at the posterior scutum or massive ossification footplate with minimal effort and duration, in only a few seconds<sup>(9)</sup>. Although Somers et al<sup>(3)</sup> have reported the possibility of acoustic trauma in the inner ear when using the microdrill, Yavuz et al<sup>(2)</sup> compared the microdrill stapedotomy with the pick perforator method, and found similar results without evidence of acoustic trauma. Mangham et al. reported the microdrill stapedotomy group was superior to the hand drill group in terms of better hearing outcomes and reductions in the incidences of footplate fractures<sup>(1)</sup>. A stapedotomy, using a hand perforator, can be technically more demanding and should be performed only by highly experienced otologists, because the footplate can fracture



unpredictably. In recent years, fenestration trends have evolved towards using the laser technique that provides a “no-touch” procedure to reduce the risk of footplate mobilization<sup>(10,11)</sup>. The laser and microdrill were found to be equally effective and safe in the creation of the fenestra<sup>(12)</sup>. Laser machines are however unavailable in many institutions.

To the best of our knowledge, the present study was the first large comparative study of stapedotomy techniques, comparing the endoscope-assisted microdrill and the conventional technique. However, the present study had certain limitations. It was a retrospective review, and further prospective randomized studies and a larger population are still necessary to determine the ideal treatment procedure for patients with otosclerotic stapes fixation underwent a stapedotomy.

### Conclusion

A particularly beneficial aspect of endoscope-assisted microdrill stapedotomy was excellent visualization with minimal exposure, leading to an effective and safe procedure. This technique was associated with significantly better hearing results, a lower postoperative vertigo rate, and fewer footplate fractures and chorda tympani nerve injuries than when using the conventional technique.

### What is already known on this topic?

Since the introduction of the endoscope in the field of otology, many surgical techniques that utilize these adjuncts have been described. However the report of the benefit of the endoscope in stapes surgery is still limited.

### What this study adds?

This study showed the main advantages of the endoscope in stapes surgery with microdrill are: no chorda tympani nerve injury, no footplate fracture, no extra-incision and provide an excellent visualization of the surgical field with minimal bone removal.

### Acknowledgment

The authors thank the Faculty of Medicine, Prince of Songkla University for funded support. We would also like to thank Dr. Weerawat Kiddee, assistant professor, Prince of Songkla University for his critique of the manuscript.

### Potential conflicts of interest

None.

### References

1. Mangham CA Jr. Reducing footplate complications in small fenestra microdrill stapedotomy. *Am J Otol* 1993; 14: 118-21.
2. Yavuz H, Caylakli F, Ozer F, Ozluoglu LN. Reliability of microdrill stapedotomy: comparison with pick stapedotomy. *Otol Neurotol* 2007; 28: 998-1001.
3. Somers T, Vercruyssen JP, Zarowski A, Verstreken M, Offeciers E. Stapedotomy with microdrill or carbon dioxide laser: influence on inner ear function. *Ann Otol Rhinol Laryngol* 2006; 115: 880-5.
4. Poe DS. Laser-assisted endoscopic stapedectomy: a prospective study. *Laryngoscope* 2000; 110: 1-37.
5. Kojima H, Komori M, Chikazawa S, Yaguchi Y, Yamamoto K, Chujo K, et al. Comparison between endoscopic and microscopic stapes surgery. *Laryngoscope* 2014; 124: 266-71.
6. Migirov L, Wolf M. Endoscopic transcanal stapedotomy: how I do it. *Eur Arch Otorhinolaryngol* 2013; 270: 1547-9.
7. Nogueira Junior JF, Martins MJ, Aguiar CV, Pinheiro AI. Fully endoscopic stapes surgery (stapedotomy): technique and preliminary results. *Braz J Otorhinolaryngol* 2011; 77: 721-7.
8. Yung MW, Oates J, Vowler SL. The learning curve in stapes surgery and its implication to training. *Laryngoscope* 2006; 116: 67-71.
9. Schmid P, Hausler R. Revision stapedectomy: an analysis of 201 operations. *Otol Neurotol* 2009; 30: 1092-100.
10. Cuda D, Murri A, Mochi P, Solenghi T, Tinelli N. Microdrill, CO<sub>2</sub>-laser, and piezoelectric stapedotomy: a comparative study. *Otol Neurotol* 2009; 30: 1111-5.
11. Wegner I, Kamalski DM, Tange RA, Vincent R, Stegeman I, van der Heijden GJ, et al. Laser versus conventional fenestration in stapedotomy for otosclerosis: a systematic review. *Laryngoscope* 2014; 124: 1687-93.
12. Sedwick JD, Loudon CL, Shelton C. Stapedectomy vs stapedotomy. Do you really need a laser? *Arch Otolaryngol Head Neck Surg* 1997; 123: 177-80.

---

การผ่าตัดเจาะรูฐานกระดูกโกลนด้วยเครื่องกรอขนาดเล็กผ่านการส่องกล้องผ่านช่องทางหู: เปรียบเทียบกับวิธีดั้งเดิม

ยุวดียา ปลอดภัย, วิราภรณ์ อัจฉริยะเสถียร, วันดี ไชยมุก

**วัตถุประสงค์:** เปรียบเทียบผลการรักษาของผู้ป่วยที่รับการรักษาดูด้วยวิธีการผ่าตัดส่องกล้องผ่านช่องทางหูร่วมกับการเจาะรูฐานกระดูกโกลนด้วยเครื่องกรอขนาดเล็กกับวิธีการผ่าตัดแบบวิธีดั้งเดิม

**วัสดุและวิธีการ:** การศึกษาย้อนหลังถึงผลการรักษา, ผลตรวจการได้ยิน, ภาวะแทรกซ้อนระหว่างการผ่าตัดและหลังการผ่าตัดที่ได้รับการบันทึกของผู้ป่วยที่เป็นโรคหินปูนเกาะกระดูกหู 37 รายที่รับการรักษาดูด้วยวิธีการผ่าตัดส่องกล้องผ่านช่องทางหู ร่วมกับการเจาะรูฐานกระดูกโกลนด้วยเครื่องกรอขนาดเล็กเปรียบเทียบกับวิธีการผ่าตัดแบบดั้งเดิม

**ผลการศึกษา:** ค่าเฉลี่ยระยะเวลาการผ่าตัดในกลุ่มที่ส่องกล้องผ่านช่องทางหูคือ 128 นาที และ 132 นาที ในกลุ่มที่ผ่าตัดแบบดั้งเดิม ( $p = 0.72$ ) *Air-bone gap* ที่น้อยกว่า 10 เดซิเบลเท่ากับร้อยละ 83.3 และ ร้อยละ 47.4 ในกลุ่มที่ส่องกล้องผ่านช่องทางหูและกลุ่มที่ผ่าตัดแบบดั้งเดิมตามลำดับ ( $p = 0.04$ ). ไม่พบการแตกของฐานกระดูกโกลน และการได้รับบาดเจ็บของเส้นประสาท *chorda tympani* ในกลุ่มที่ได้รับการผ่าตัดด้วยวิธีส่องกล้องผ่านช่องทางหู ภาวะเวียนศีรษะบ้านหมุนหลังการผ่าตัดพบได้ร้อยละ 31.6 ในกลุ่มที่ได้รับการผ่าตัดแบบดั้งเดิม และร้อยละ 26.3 ของกลุ่มที่รับการผ่าตัดแบบดั้งเดิมต้องเพิ่มแผลผ่าตัดแบบ *endaural* เนื่องจากความสามารถในการมองเห็นผ่านกล้อง *microscope* ไม่เพียงพอ

**สรุป:** การผ่าตัดเจาะรูฐานกระดูกโกลนด้วยเครื่องกรอขนาดเล็กผ่านการส่องกล้องผ่านช่องทางหูส่งผลให้เพิ่มความสามารถในการได้ยินมากกว่า, ลดอัตราการเกิดภาวะเวียนศีรษะบ้านหมุนหลังการผ่าตัด, ลดการแตกของฐานกระดูกโกลน และลดการได้รับการบาดเจ็บของเส้นประสาท *chorda tympani* เมื่อเปรียบเทียบกับวิธีการผ่าตัดแบบดั้งเดิม

---