

DCE-MRI-Derived Parameters as Predictors of Response to Neo-Adjuvant Chemoradiation Treatment of Rectal Carcinoma

Sith Phongkitkarun MD*, Umalin Tohmad MD*, Noppadol Larbcharoensub MD**,
Kanit Sumbunnanonnda MD***, Thiti Swangsilpa MD*, Ekaphop Sirachainan MD****

* Department of Diagnostic and Therapeutic Radiology, Faculty of Medicine, Ramathibodi Hospital, Mahidol University, Bangkok, Thailand

** Department of Pathology, Faculty of Medicine, Ramathibodi Hospital, Mahidol University, Bangkok, Thailand

*** Department of Surgery, Faculty of Medicine, Ramathibodi Hospital, Mahidol University, Bangkok, Thailand

**** Department of Internal Medicine, Faculty of Medicine, Ramathibodi Hospital, Mahidol University, Bangkok, Thailand

Background: Preoperative combined chemoradiation treatment (CRT) is now accepted as the treatment of choice due to its benefits of decreasing the primary tumor volume and enhancing the sphincter preservation surgery. Determining whether a patient is responding to therapy is crucial for rectal cancer patients who may benefit from prompt treatment modifications.

Objective: To evaluate the use of dynamic contrast-enhanced magnetic resonance imaging (DCE-MRI) in predicting the treatment response.

Material and Method: Nineteen patients with histologically proven rectal adenocarcinoma who were candidates for neo-adjuvant CRT were prospectively included. All patients were examined by conventional and DCE-MRI at three time points (pre-, during-, and post-CRT). Surgical resection was performed after complete CRT. The pathological response and Dworak regression grade were assessed. All parameters were blindly analyzed.

Results: The median pathologic response rate for all patients was 40%. Dworak regression grades of 0, 1, 2, 3, and 4 were found in 0.0%, 21.1%, 42.1%, 26.3%, and 10.5% of patients, respectively. The tumor thickness and length were 30% and 32.9% lower at during-CRT and 40.6% and 44.7% lower post-CRT and had moderate and fair negative correlations with the pathologic response rate and Dworak regression rate, respectively. Among the DCE-MRI parameters, only a change in the time to peak between pre- and during-CRT was correlated with the Dworak regression grade ($p = 0.01$). The percentage change in the time to peak in patients with poor regression (grades 0-1) was significantly greater than in patients with intermediate/complete regression (grades 2-4) [139.25% vs. 6.13%].

Conclusion: Changes in the tumor thickness and length evaluated by conventional MRI and the time to peak evaluated by DCE-MRI during CRT may be useful for predicting the treatment response of rectal cancer patients.

Keywords: Rectal cancer, Magnetic resonance imaging, Contrast media, Chemoradiotherapy, Neoadjuvant therapy

J Med Assoc Thai 2016; 99 (3): 338-47

Full text. e-Journal: <http://www.jmatonline.com>

Colorectal cancer is the third most commonly diagnosed cancer in males and the second most commonly diagnosed cancer in females worldwide⁽¹⁾. Locally advanced rectal cancer (LARC) remains one of the most problematic forms of rectal cancer to treat due to substantial local recurrence after surgery⁽²⁾. Preoperative combined chemoradiation treatment (CRT) is now accepted as the treatment of choice due to its benefits of decreasing the primary tumor volume and enhancing the sphincter preservation surgery.

This neo-adjuvant treatment regimen reduces the risk of local recurrence⁽³⁾. Early identification of the therapeutic response to CRT is crucial for patients who are ineffectively treated and who may benefit from prompt modification of their treatment protocol⁽⁴⁾.

Conventional MRI is accepted as an accurate imaging modality for characterizing rectal carcinoma⁽⁵⁾. However, this method lacks physiologic parameters and functional characterization of changes in the microvasculature. Its combination with dynamic contrast-enhanced magnetic resonance imaging (DCE-MRI) is becoming the accepted non-invasive in vivo technique for evaluating the tumor microvasculature. In rectal cancer patients, DCE-MRI with paramagnetic contrast agent administration allows for the evaluation of the tumor vascular physiology such as the

Correspondence to:

Phongkitkarun S, Department of Diagnostic and Therapeutic Radiology, Ramathibodi Hospital, Mahidol University, 270 Rama VI Road, Ratchathewi, Bangkok 10400, Thailand.

Phone: +66-2-2011212, Fax: +66-2-2011247

E-mail: sith.bkk@gmail.com

microvascular flow and endothelial permeability, which can then be related to CRT. However, several DCE-MRI parameters that are obtained have not been standardized^(6,7).

Several studies have shown the diagnostic value of the perfusion parameters in DCE-MRI for predicting the therapeutic outcome of LARC after neo-adjuvant treatment. However, most reported parameters require special software with mathematic modelling to derive those results^(4,8,9). Therefore, the purpose of the present study was to evaluate the use of the simple parameters of DCE-MRI to predict the treatment response of rectal cancer patients who underwent neo-adjuvant CRT followed by surgery, and these findings were correlated with the pathologic response.

Material and Method

Patient selection

The present study involved prospective data collection. The Committee on Human Rights Related to Researches Involving Human Subjects of Faculty of Medicine, Ramathibodi Hospital approved the study, and the written informed consent was obtained from all patients. We enrolled patients with rectal cancer who met the following inclusion criteria: (i) histologically confirmed adenocarcinoma of rectum, (ii) tumor clinically staged as cT3 or cT4 with any N-stage and without any evidence of distant metastases according to pelvic MRI, and (iii) age greater than 18 years. The exclusion criteria were tumor clinically staged as cT1 or cT2 or patient who received neither complete CRT nor definitive surgical resection. Twenty patients were enrolled between May 2009 and November 2012. One patient refused surgery. We enrolled 19 patients (mean age, 56.05±9.0 years [standard deviation, SD]), comprising 10 men (mean age, 51.6±10.1 years) and nine women (mean age, 61.0±4.0 years) ($p = 0.019$). Definitive surgical resection with total mesorectal excision was performed after complete CRT.

Neo-adjuvant chemoradiation treatment

Patients were treated according to the preoperative CRT trial. The preoperative radiotherapy schedule for rectal cancer was performed with megavoltage equipment. The radiotherapy treatment volume covered the primary tumor with locoregional extension and pelvic lymph nodes. Patients received a tumor dose of 180 cGy/fraction for a total tumor dose of 4,500-5,040 cGy/5-5.5 weeks. Chemotherapy was performed concomitantly with radiotherapy with

oxaliplatin (Eloxatin; Sanofi-Avantis, Paris, France) infusion 50 mg/m² on days 1, 8, 22, and 29 of radiotherapy plus oral capecitabine (Xeloda; Hoffmann-La Roche, Basel, Switzerland) 825 mg/m² twice daily on days 1-14 (first cycle) and days 22-35 (second cycle) of radiotherapy.

MR imaging technique

All patients were examined with MRI three times: before CRT (pre-CRT), after the first cycle of chemotherapy (during-CRT), and post-CRT. All MRI studies were performed with 1.5 T scanner (Signa HDxt; GE Healthcare, Milwaukee, Wisconsin, USA). Standard anatomical imaging using a thin slice sagittal T2W FSE was acquired with 24-cm FOV, 3-mm slice thickness, and no interslice gap including the tumor. Axial (perpendicular to the rectal tumor lumen) and coronal oblique T2W images were acquired.

For the DCE-MRI study, multi-slice pre- and post-contrast, axial, T1W, and three-dimensional (3D) spoiled gradient echo sequences (LAVA, GE Healthcare) (24-cm FOV; 5-mm slice thickness) were acquired. The temporal resolution of the LAVA sequence was approximately 15 seconds, and dynamic data acquisition was started after the contrast medium injection and repeated 30 times (phases) through the main bulk of the tumor at each time point. The average scan time was approximately 7.29 minutes. Subsequent studies were performed in the same axial plane as the previous examination, unless the tumor was no longer visible, in which case, the axial section was taken through what remained of the main bulk of the tumor. All patients received a bolus of 0.1 mmol/kg gadobutrol (Gadovist), which was administered intravenously through a peripheral vein at the antecubital fossa at the rate of 3.0 mL/second with a power injector (Medrad, Spectris Solaris EP MR Injector System; Medrad Inc., Indianola, PA, USA) and was followed by a 30-mL saline flush.

MR image analysis

Pre-, during-, and post-CRT MR images of each patient were analyzed in consensus by two radiologists (one specialist in body imaging and one fellow, with 10 and two years' experience in DCE-MRI, respectively) who were blinded to the clinical and pathologic data related to the treatment response. All MR images were restored in a picture archiving and communication system (PACS).

The T1W DCE-MR images were processed using commercially available software (Functool 4.5.3,

GE Healthcare), and the following quantitative perfusion parameters were calculated: the maximum slope of enhancement, peak enhancement (MR Unit), and time to peak (millisecond [msec], time until peak enhancement). A circular or oval region of interest (ROI) was manually placed in the tumor at the highest enhancing portion, slice by slice. The area of the ROI was approximately 11-154 mm². After each ROI was placed, color-coded maximum slope of enhancement and time-intensity curves were generated. From these time-intensity curves, the peak enhancement and time to peak were obtained. The ROI with the highest maximal slope of enhancement value was selected to record the peak enhancement and the time to the peak values for each tumor.

The maximal tumor thickness and length were also recorded on T2W images. T- and N-staging was attributed to the post-CRT MR images. A lymph node was considered positive if its short-axis length was more than 5 mm (mesorectal region) or 10 mm (iliac region), its contour was irregular or rounded and its signal intensity relative to the tumor showed a loss of chemical shift artifact or mixed signal intensity on T2W images. It was considered negative if it had a uniformly low signal intensity and was less than 5 mm⁽¹⁰⁾.

The Response Evaluation Criteria in Solid Tumors (RECIST version 1.1) measurement⁽¹¹⁾ was used to assess the response of rectal cancer on MRI post-CRT using the maximal tumor thickness and maximal tumor length on pre-CRT and post-CRT. The MRI responses of the tumor thickness and length were evaluated separately; these two response parameters for each patient were included in the overall RECIST response of each patient, which was defined as the RECIST response. The patients were categorized as responders (complete response (CR) or partial response (PR)) or non-responders (stable disease (SD) or progressive disease (PD)) based on the tumor thickness and length measurements, as well as its signal intensity on T2W.

Histopathologic examination

The tumor thickness and length were measured. Pathologic tumor staging was recorded according to the TNM system. The Dworak regression grade system proposed by Dworak et al⁽¹²⁾ and the response rate (0 to 100%) were applied to evaluate the treatment response to CRT⁽¹³⁾. The Dworak's grade 0 represents no regression. Grade 1 is minor regression (fibrosis seen in 25% or less of the tumor mass). Grade 2 is moderate regression (fibrosis seen in 26 to 50% of

the tumor mass). Grade 3 is good regression (fibrosis outgrowing the tumor mass or more than 50% tumor regression). Grade 4 is total regression (no viable tumor cells, only fibrotic mass). The Dworak regression grade was also divided into the following two groups: grades 0 and 1 (none and poor regression) and grades 2 to 4 (intermediate regression for grades 2 and 3 and complete regression for grade 4). The response rate was defined as 0 to 100%, 0 was no regression and 100% was complete regression.

Statistical analysis

All analyses were performed using STATA version 13 (StatCorp, 2013). Continuous variables were expressed as the mean \pm standard deviation or median, and categorical variables were expressed as a number and percentage.

Spearman correlation analysis or the Kruskal-Wallis test was used to determine the correlation between the percentage change of each MRI parameter and the pathologic response result (response rate and Dworak regression grade). The association between the percentage change of each MRI parameter and grouped Dworak regression grade was evaluated with the Mann-Whitney test. The association between the percentage changes of the MRI tumor thickness and length with the pathologic response results was analyzed with the Chi-square (χ^2) test or Mann-Whitney test. The Chi-square (majority), Kruskal-Wallis, and Mann-Whitney tests were used to compare between the overall MRI responses using the RECIST criteria (version 1.1) and the pathologic response results. The correlation coefficient (r) from 0 to 0.25 (or -0.25) indicates little or no relationship, those from 0.25 to 0.50 (or -0.25 to -0.50) reflects a fair degree; and those from 0.50 to 0.75 (or -0.50 to -0.75) a moderate degree, while correlations over 0.75 (or -0.75) reflect a strong relationship.

The correlations of the MRI post-CRT tumor thickness and length and T- and N-stages with the pathologic results were established with the Spearman correlation analysis or Fisher's exact test. A *p*-value less than 0.05 was considered statistically significant.

Results

The results of the tumor thickness and length from the conventional MRI and DCE-MRI parameters on pre-, during-, and post-CRT of the patients were presented in Fig. 1. The median of the pathologic response rate in all patients was 40% (range 10-100%). Dworak regression grades of 0, 1, 2, 3, and 4 were found

in zero, four (21.1%), eight (42.1%), five (26.3%), and two (10.5%) patients, respectively. The meantime interval between the MRI post-CRT and pathologic results was 34.1 days (range 12-66 days).

Correlation between the MRI findings and pathologic results

Tumor length and thickness

The tumor length measured by MRI post-CRT (median 3.1 cm, range 0.5 to 8 cm) was significantly correlated with the tumor length of the histopathologic specimen (median 2 cm, range 0 to 5 cm) with the correlation coefficient $r = 0.56$ ($p = 0.01$). There was a fair correlation ($r = 0.43$) between the tumor thickness, as measured by MRI post-CRT (median 1 cm, range 0.5 to 1.9 cm), and the pathologic specimens (median 1 cm, range 0 to 3 cm), but this correlation was not significant ($p = 0.06$).

The comparison analysis between the percentage changes in the MRI parameters and pathologic response, comparing pre- vs. during-CRT and pre- vs. post-CRT, was shown in Table 1. During chemoradiation, the mean tumor thickness of all patients decreased by 30%, and this was significantly correlated with the pathologic response rate and Dworak regression grade. While the tumor thickness decreased by 40.63% post-CRT, this was not significantly correlated with the pathologic response rate or Dworak regression grade. Meanwhile, the

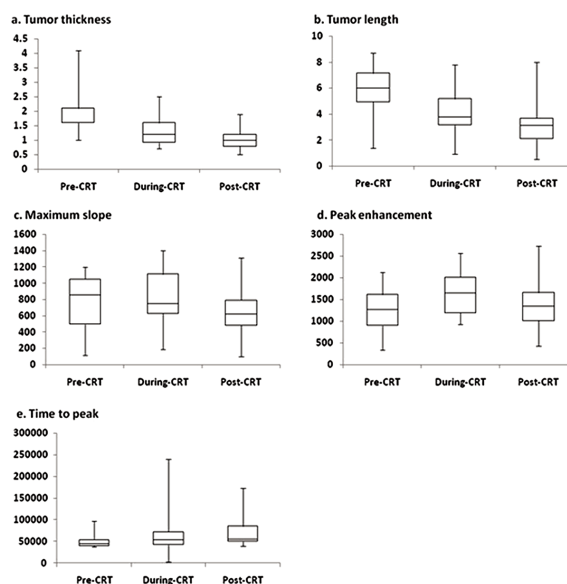


Fig. 1 Each graph (a-e) consists of box and whisker plots that were used to compare the tumor thickness and length, maximum slope of increase, peak enhancement and time to peak at each time point for all 19 patients. The box represents the values from the lower to the upper quartile (25th to 75th percentile). The whiskers indicate the range from the maximum to the minimum parameters.

decreases in tumor length during- and post-CRT were not significantly correlated with the pathologic responses.

Table 1. Correlation between the MRI parameters and the pathologic response

Parameters	MRI median (min, max)	Response rate		Dworak grade	
		r	p-value	r	p-value
Conventional MRI					
Δ Tumour thickness					
During-CRT vs. pre-CRT	-30.00 (-56.25, 0)	-0.46	0.05	-0.51	0.03
Post-CRT vs. pre-CRT	-40.63 (-69.23, -5)	-0.28	0.24	-0.29	0.23
Δ Tumour length					
During-CRT vs. pre-CRT	-32.91 (-66.67, 0)	-0.23	0.34	-0.31	0.20
Post-CRT vs. pre-CRT	-44.68 (-81.61, 6.67)	-0.31	0.19	-0.31	0.20
DCE-MRI					
Δ Max slope of enhancement					
During-CRT vs. pre-CRT	4.45 (-80.98, 531.12)	-0.01	0.96		0.28
Post-CRT vs. pre-CRT	-17.66 (-90.67, 487.42)	0.09	0.70		0.89
Δ Peak enhancement					
During-CRT vs. pre-CRT	28.97 (-29.55, 395.84)	0.09	0.72		0.42
Post-CRT vs. pre-CRT	3.92 (-35.39, 318.07)	-0.05	0.85		0.84
Δ Time to peak					
During-CRT vs. pre-CRT	10.29 (-94.95, 266.67)	-0.13	0.60		0.01
Post-CRT vs. pre-CRT	5.95 (-32.46, 266.67)	-0.12	0.64		0.20

MRI = magnetic resonance imaging; CRT = chemoradiation treatment; DCE-MRI = dynamic contrast-enhanced magnetic resonance imaging; r = correlation coefficient; Δ = percentage change
The median of the pathologic response rate = 40 (range 10-100)

DCE-MRI parameters

There were no significant correlation between the percentage changes of the DCE-MRI parameters and the pathologic responses on either the pre-CRT vs. during-CRT or the pre-CRT vs. post-CRT MRI, except for time to peak on the pre-CRT vs. during-CRT MRI, which was correlated with the Dworak regression grade ($p = 0.01$). The time to peak during-CRT increased by 10.29% compared with pre-CRT, while the time to peak on the MRI post-CRT was increased by 5.95% compared with the MRI pre-CRT.

The percentage change in the time to peak in patients with poor regression (grades 0 and 1) was significantly greater than among patients with intermediate/complete regression (grades 2 to 4) (Table 1).

Comparison results of T- and N-stage between MRI and histopathology

When comparing the T-stage evaluated by MRI post-CRT and histopathology in all 19 patients, 15 patients (78.9%) were correctly classified, and four patients were incorrect. MRI post-CRT showed overstaging for two patients and understating for two patients. When comparing the N-stage (positive nodes or not) evaluated by MRI and histopathology in all 19 patients, 15 patients (78.9%) showed the correct nodal status, and four patients showed the incorrect. MRI showed over-evaluation of the nodal status in these four patients.

The T- and N-stage showed highly significant correction between the MRI post-CRT and pathologic results, as shown in Table 2 (p -value <0.001 and 0.01, respectively). The sensitivity, specificity, positive predictive value, and negative predictive value of the T-stage were shown in Table 3.

Comparison between the MRI response and pathologic response

According to the RECIST response criteria, the MRI response was found in 15 patients, and the MRI nonresponse was found in four patients. The comparison analysis between the RECIST response criteria (CR, PR, and SD) of MRI and the pathologic response rate ($p = 0.07$), as well as between the overall response of MRI (response and nonresponse) and the pathologic response rate ($p = 0.06$), were concordant, but this was not significant (Table 4). The RECIST response and overall response of MRI showed high concordance with the Dworak regression grade ($p = 0.004$ to 0.04), which was summarized in Table 5.

Discussion

MRI parameters and pathologic responses

Imaging markers for tumor angiogenesis can help monitor the disease progression and treatment response⁽¹⁴⁾. It would be beneficial to predict whether an individual cancer patient will respond to therapy at an early stage of treatment. Ineffective treatment may cause unnecessary toxicity in those patients and delay

Table 2. Tumour and nodal stages evaluated by MRI vs. histopathology

Parameters	Pathologic stage	p -value
MRI post-CRT		
Overall T-stage		<0.001 ($r = 0.82$)
T-stage	ypT0 to 2 ypT3 and 4	<0.001
- T0 to 2	6 1	
- T3 and 4	0 12	
N-stage	ypN0 ypN1 and 2	0.01
- Positive	4 7	
- Negative	8 0	

r = correlation coefficient

Table 3. Diagnostic performances of the T- and N-stages evaluated by MRI

Parameters	Grouped T-stage	Grouped N-stage
Sensitivity (%)	92.3 (64.0-99.8)	100 (59.0-100)
Specificity (%)	100 (54.1-100)	66.7 (34.9-90.1)
Positive predictive value (%)	100 (73.5-100)	63.6 (30.8-89.1)
Negative predictive value (%)	85.7 (42.1-99.6)	100 (63.1-100)
Accuracy (%)	96.2 (88.6-100)	83.3 (69.4-97.3)

Data in parentheses are the 95% CI

Table 4. Comparison between the MRI response and pathologic response rate

MRI	Response rate		p -value
	No.	Median (min, max)	
RECIST response ¹			0.07
Complete response	1	100	
Partial response	16	40.0 (10, 100)	
Stable disease	2	12.5 (10, 15)	
Overall response			0.06
Response	17	40.0 (10, 100)	
Non-response	2	12.5 (10, 15)	

No. = number of patients; RECIST = response evaluation criteria in solid tumors

¹ Overall response, including the tumour thickness and length, according to the RECIST criteria

Table 5. Comparison between the MRI response and pathologic Dworak grade

MRI	Dworak grade (No.)				<i>p</i> -value	Grouped Dworak grade (No.)		<i>p</i> -value
	1	2	3	4		0-1	2-4	
RECIST response ¹					0.009			0.01
Complete response	0	0	0	1		0	1	
Partial response	2	8	5	1		2	14	
Stable disease	2	0	0	0		2	0	
Overall response					0.04			0.004
Response	2	8	5	2		2	15	
Non-response	2	0	0	0		2	0	

No. = number of patients

¹ Overall response, including the tumour thickness and length, according to the RECIST criteria

proper treatment. The purpose of the present study was to evaluate the use of the parameters of DCE-MRI for predicting the treatment response in rectal cancer patients who undergo neo-adjuvant CRT. The results demonstrate that the DCE-MRI parameters as the imaging markers fluctuated during treatment and were not correlated with the pathologic response, except for the time to peak parameter. We found that patients who had poor regression had a greater significant increase in the time to peak during-CRT compared with patients who had intermediate or complete regression compared to MRI pre-CRT, which suggests that a slower (increased) time to peak during-CRT may be predictive of poor regression. Our study was in agreement with the study by Dinter et al, which also showed that the decrease in the slope of the contrast enhancement curve in the response group (downstaging) was significantly greater than in the non-response group (without downstaging)⁽⁸⁾. However, our study used a different histopathological outcome (response rate and Dworak regression grade). Lim et al reported that higher pre-CRT K^{trans} values tend to have better tumor regression grade (TRG) responses (i.e., a lower tumor TRG), but the rates of the tumor K^{trans} values in the early-CRT and post-CRT phases relative to the K^{trans} in the pre-CRT phase were not correlated with the TRG⁽⁴⁾. It should be noted that different MR parameters were used and that the correlations were found at different time points.

The correlation between the changes of time to peak during-CRT and tumor response may be explained by the fact that the slower time to peak affected the delivery of chemotherapeutic agents into the tumor mass, which might have resulted in non-responsiveness. Additionally, the slower time to peak could be related to the hypoxic microenvironment, which increased the overall tumor resistance to radiation⁽¹⁵⁾. A faster tumor enhancement may be

indicative of more tumor angiogenic activity⁽¹⁴⁾, which is targeted by anti-angiogenic therapy and is found among intermediate and regression patients. Thus, MRI analysis of the time to peak parameter of during-CRT for measuring early temporal changes appears to be helpful for predicting the therapeutic outcome.

In addition, Hong et al reported that time to peak was positively correlated with histologic tumor grade, i.e., poorly differentiated tumors showed longer times to reach the peak enhancement compared to those of well-differentiated lesions⁽¹⁶⁾. The slower time to peak in poorly differentiated tumors could be due to poorly perfused tumoral vessels. Tuncbilek et al found that time to peak was not significantly correlated with histologic grade, but it was strongly negative correlated with microvessel density⁽¹⁷⁾. This implied that the slower time to peak could be due to fewer microvessels within the tumor. However, both studies evaluated time to peak with pre-treatment histopathology. Unfortunately, the present study was unable to perform correlations between MRI parameters and pre-treatment histopathology (biopsied specimens) because the histopathologic result might not represent the whole tumor.

DCE-MRI research has focused on different tumors and has shown mixed results in the relationship between the tumor dynamic enhancement patterns and tumor angiogenesis and response^(7,18,19). Different methods to derive those MRI parameters have been proposed⁽⁷⁾. In the present study, however, we decided to use semi-quantitative analysis (i.e., peak enhancement, maximal slope of enhancement, and time to peak) that was performed directly with the T1WIs due to its speed, reproducibility, and availability. These parameters can be obtained immediately by generating time-intensity curves from a workstation in routine clinical practice, unlike quantitative analyses [i.e., blood flow, blood volume, permeability or transfer constant (K^{trans})],

which require more scanning techniques and mathematical modeling for conversion of the MR signal intensities to Gd-DTPA concentrations^(20,21). Our study found mixed results among three time points (pre-, during-, and post-CRT), and there were no significant correlation between the maximum slope of enhancement or peak enhancement and the pathologic response. However, we were able to demonstrate a temporal change in the perfusion parameters in tumors after CRT. These results generated additional research questions for the future.

Conventional MRI and pathologic results

MRI post-CRT and the histopathologic tumor length had a significant correlation (Table 2), similar to that reported in a previous study⁽²²⁾. The tumor thickness and MRI tumor length tended to decrease in size with a higher pathologic response. However, there was a significant correlation between the change in the tumor thickness on the MRI pre-CRT vs. during-CRT and the pathologic response.

The T-stage on MRI post-CRT was highly correlated with the pathologic stage. There was higher sensitivity and specificity than in the recent study by van der Paardt et al⁽²³⁾. In the present study, there was a T-stage correction of 78.9% between MRI post-CRT and the histopathology, which was similar to the observations in the study by Johnston et al⁽²⁴⁾. However, Dinter et al⁽⁸⁾ reported that pre-surgical MRI could not predict the ypT stage.

The nodal status on post-CRT was correlated with the pathologic result with high sensitivity and accuracy. The present study showed higher sensitivity than previous studies, with a sensitivity of 57 to 95%⁽²⁵⁻²⁸⁾, but we found similar specificity (67 to 75%) and accuracy⁽²²⁾. Most of the inaccuracy in the N-stages was caused by overstaging, and this remained challenging due to the high prevalence of malignancy in normal-sized lymph nodes. Brown et al⁽¹⁰⁾ reported that the signal intensity and border characteristics of the nodes were superior to the size in predicting the nodal status. The high spatial resolution of the MR imaging technique was needed in assessing the border irregularity, combined with the heterogeneity of the intranodal signal intensity.

The MRI response (RECIST and overall responses) was better concordant with the Dworak regression grade than the pathologic response rate. The Dworak regression grade is considered a significant prognostic factor for survival and local recurrence after preoperative CRT⁽²⁹⁻³¹⁾. Therefore, the MRI response

may predict the treatment response and may be a prognostic factor.

There were some limitations to the present study. First, the number of patients was relatively small and the sample size was not calculated. Second, the time interval between the MRI post-CRT and the pathologic result varied considerably (12-66 days), and changes in the disease status could occur in this time frame. A previous study demonstrated that a prolonged interval between neo-adjuvant CRT and surgery still might improve the pathologic complete response rate⁽³²⁾. Third, the time to peak measurement in a patient with a slow circulation time would result in a long time to peak even if the tumor enhanced rapidly. This was not an issue for any of the patients in the present study because they all had a similar time to arterial enhancement. Fourth, the choice of the ROI for the dynamic sequences was very crucial because single-slice ROI analysis was prone to bias and might not adequately represent the tumor heterogeneity. To minimize these limitations, ROIs were drawn at the highest enhancement region of the central levels of the tumor.

In conclusion, the changes in the tumor thickness and length of rectal cancer evaluated by conventional MRI, and the time to peak evaluated by DCE-MRI during CRT may be useful for predicting treatment response, and these factors have a good correlation with the pathological response. Tumors with a faster time to peak tend to respond favorably to CRT, according to the Dworak regression grade. Early evaluation of the response during neo-adjuvant CRT treatment shows great promise in predicting the tumor response.

What is already known on this topic?

Several studies had shown the diagnostic value of the perfusion parameters in DCE-MRI for predicting the therapeutic outcome of locally advanced rectal carcinoma after neo-adjuvant treatment. However, most reported parameters require special software with mathematic modeling to derive those results, which was not practical in clinical practice. In addition, there were some conflicting results on perfusion parameters in term of which parameters to use and when to assess the treatment as well as the correlation to histopathology results.

What this study adds?

This study demonstrated DCE-MRI parameters as the imaging markers fluctuated during

treatment and were not correlated with the pathologic response, except for the time to peak parameter. The result showed that patients who had poor regression had a greater significant increase in the time to peak during-CRT compared to patients who had intermediate or complete regression compared to MRI pre-CRT, which suggested that a slower (increased) time to peak during-CRT may be predictive of poor regression.

The tumor length measured by MRI post-CRT was significantly correlated with the tumor length of the histopathologic specimen. While, the percentage change of tumor thickness during-CRT was significantly correlated with the pathologic response rate and Dworak regression grade.

Acknowledgements

This research was supported by a grant from Mahidol University. The authors wish to thank Mr. Dittapol Muntham from the Section for Clinical Epidemiology and Biostatistics, Research Center, Faculty of Medicine Ramathibodi Hospital, Mahidol University for statistical consultation.

Potential conflicts of interest

None.

References

1. Jemal A, Bray F, Center MM, Ferlay J, Ward E, Forman D. Global cancer statistics. *CA Cancer J Clin* 2011; 61: 69-90.
2. Engstrom PF, Arnoletti JP, Benson AB 3rd, Chen YJ, Choti MA, Cooper HS, et al. NCCN Clinical Practice Guidelines in Oncology: rectal cancer. *J Natl Compr Canc Netw* 2009; 7: 838-81.
3. Kapiteijn E, Marijnen CA, Nagtegaal ID, Putter H, Steup WH, Wiggers T, et al. Preoperative radiotherapy combined with total mesorectal excision for resectable rectal cancer. *N Engl J Med* 2001; 345: 638-46.
4. Lim JS, Kim D, Baek SE, Myoung S, Choi J, Shin SJ, et al. Perfusion MRI for the prediction of treatment response after preoperative chemoradiotherapy in locally advanced rectal cancer. *Eur Radiol* 2012; 22: 1693-700.
5. Beets-Tan RG, Beets GL, Vliegen RF, Kessels AG, Van Boven H, De Bruine A, et al. Accuracy of magnetic resonance imaging in prediction of tumour-free resection margin in rectal cancer surgery. *Lancet* 2001; 357: 497-504.
6. George ML, Dzik-Jurasz AS, Padhani AR, Brown G, Tait DM, Eccles SA, et al. Non-invasive methods of assessing angiogenesis and their value in predicting response to treatment in colorectal cancer. *Br J Surg* 2001; 88: 1628-36.
7. Hotker AM, Garcia-Aguilar J, Gollub MJ. Multiparametric MRI of rectal cancer in the assessment of response to therapy: a systematic review. *Dis Colon Rectum* 2014; 57: 790-9.
8. Dinter DJ, Horisberger K, Zechmann C, Wenz F, Brade J, Willeke F, et al. Can dynamic MR imaging predict response in patients with rectal cancer undergoing cetuximab-based neoadjuvant chemoradiation? *Onkologie* 2009; 32: 86-93.
9. Gollub MJ, Gultekin DH, Akin O, Do RK, Fuqua JL 3rd, Gonen M, et al. Dynamic contrast enhanced-MRI for the detection of pathological complete response to neoadjuvant chemotherapy for locally advanced rectal cancer. *Eur Radiol* 2012; 22: 821-31.
10. Brown G, Richards CJ, Bourne MW, Newcombe RG, Radcliffe AG, Dallimore NS, et al. Morphologic predictors of lymph node status in rectal cancer with use of high-spatial-resolution MR imaging with histopathologic comparison. *Radiology* 2003; 227: 371-7.
11. Eisenhauer EA, Therasse P, Bogaerts J, Schwartz LH, Sargent D, Ford R, et al. New response evaluation criteria in solid tumours: revised RECIST guideline (version 1.1). *Eur J Cancer* 2009; 45: 228-47.
12. Dworak O, Keilholz L, Hoffmann A. Pathological features of rectal cancer after preoperative radiochemotherapy. *Int J Colorectal Dis* 1997; 12: 19-23.
13. Rödel C, Martus P, Papadopoulos T, Fuzesi L, Klimpfinger M, Fietkau R, et al. Prognostic significance of tumor regression after preoperative chemoradiotherapy for rectal cancer. *J Clin Oncol* 2005; 23: 8688-96.
14. Zhang XM, Yu D, Zhang HL, Dai Y, Bi D, Liu Z, et al. 3D dynamic contrast-enhanced MRI of rectal carcinoma at 3T: correlation with microvascular density and vascular endothelial growth factor markers of tumor angiogenesis. *J Magn Reson Imaging* 2008; 27: 1309-16.
15. Wachsberger P, Burd R, Dicker AP. Tumor response to ionizing radiation combined with antiangiogenesis or vascular targeting agents: exploring mechanisms of interaction. *Clin Cancer Res* 2003; 9: 1957-71.
16. Hong HS, Kim SH, Park HJ, Park MS, Kim KW, Kim WH, et al. Correlations of dynamic

- contrast-enhanced magnetic resonance imaging with morphologic, angiogenic, and molecular prognostic factors in rectal cancer. *Yonsei Med J* 2013; 54: 123-30.
17. Tuncbilek N, Karakas HM, Altaner S. Dynamic MRI in indirect estimation of microvessel density, histologic grade, and prognosis in colorectal adenocarcinomas. *Abdom Imaging* 2004; 29: 166-72.
 18. Buadu LD, Murakami J, Murayama S, Hashiguchi N, Sakai S, Masuda K, et al. Breast lesions: correlation of contrast medium enhancement patterns on MR images with histopathologic findings and tumor angiogenesis. *Radiology* 1996; 200: 639-49.
 19. Wang B, Gao ZQ, Yan X. Correlative study of angiogenesis and dynamic contrast-enhanced magnetic resonance imaging features of hepatocellular carcinoma. *Acta Radiol* 2005; 46: 353-8.
 20. Parker GJ, Suckling J, Tanner SF, Padhani AR, Revell PB, Husband JE, et al. Probing tumor microvasculature by measurement, analysis and display of contrast agent uptake kinetics. *J Magn Reson Imaging* 1997; 7: 564-74.
 21. Galbraith SM, Lodge MA, Taylor NJ, Rustin GJ, Bentzen S, Stirling JJ, et al. Reproducibility of dynamic contrast-enhanced MRI in human muscle and tumours: comparison of quantitative and semi-quantitative analysis. *NMR Biomed* 2002; 15: 132-42.
 22. Barbaro B, Fiorucci C, Tebala C, Valentini V, Gambacorta MA, Vecchio FM, et al. Locally advanced rectal cancer: MR imaging in prediction of response after preoperative chemotherapy and radiation therapy. *Radiology* 2009; 250: 730-9.
 23. van der Paardt MP, Zagers MB, Beets-Tan RG, Stoker J, Bipat S. Patients who undergo preoperative chemoradiotherapy for locally advanced rectal cancer restaged by using diagnostic MR imaging: a systematic review and meta-analysis. *Radiology* 2013; 269: 101-12.
 24. Johnston DF, Lawrence KM, Sizer BF, Arulampalam TH, Motson RW, Dove E, et al. Locally advanced rectal cancer: histopathological correlation and predictive accuracy of serial MRI after neoadjuvant chemotherapy. *Br J Radiol* 2009; 82: 332-6.
 25. Chen CC, Lee RC, Lin JK, Wang LW, Yang SH. How accurate is magnetic resonance imaging in restaging rectal cancer in patients receiving preoperative combined chemoradiotherapy? *Dis Colon Rectum* 2005; 48: 722-8.
 26. Cho YB, Chun HK, Kim MJ, Choi JY, Park CM, Kim BT, et al. Accuracy of MRI and 18F-FDG PET/CT for restaging after preoperative concurrent chemoradiotherapy for rectal cancer. *World J Surg* 2009; 33: 2688-94.
 27. Engelen SM, Beets-Tan RG, Lahaye MJ, Lammering G, Jansen RL, van Dam RM, et al. MRI after chemoradiotherapy of rectal cancer: a useful tool to select patients for local excision. *Dis Colon Rectum* 2010; 53: 979-86.
 28. Koh DM, Chau I, Tait D, Wotherspoon A, Cunningham D, Brown G. Evaluating mesorectal lymph nodes in rectal cancer before and after neoadjuvant chemoradiation using thin-section T2-weighted magnetic resonance imaging. *Int J Radiat Oncol Biol Phys* 2008; 71: 456-61.
 29. Park YJ, Oh BR, Lim SW, Huh JW, Joo JK, Kim YJ, et al. Clinical significance of tumor regression grade in rectal cancer with preoperative chemoradiotherapy. *J Korean Soc Coloproctol* 2010; 26: 279-86.
 30. Suárez J, Vera R, Balén E, Gómez M, Arias F, Lera JM, et al. Pathologic response assessed by Mandard grade is a better prognostic factor than down staging for disease-free survival after preoperative radiochemotherapy for advanced rectal cancer. *Colorectal Dis* 2008; 10: 563-8.
 31. Losi L, Luppi G, Gavioli M, Iachetta F, Bertolini F, D'Amico R, et al. Prognostic value of Dworak grade of regression (GR) in patients with rectal carcinoma treated with preoperative radiochemotherapy. *Int J Colorectal Dis* 2006; 21: 645-51.
 32. Moore HG, Gittleman AE, Minsky BD, Wong D, Paty PB, Weiser M, et al. Rate of pathologic complete response with increased interval between preoperative combined modality therapy and rectal cancer resection. *Dis Colon Rectum* 2004; 47: 279-86.

การตรวจด้วยคลื่นแม่เหล็กไฟฟ้าโดยวิธี *dynamic contrast enhancement* เพื่อประเมินผลการตอบสนองต่อการรักษาของผู้ป่วยมะเร็งลำไส้ส่วนปลายด้วยเคมีบำบัดร่วมกับการให้รังสีรักษา ก่อนผ่าตัด

สิทธิ์ พงษ์กิจการุณ, อุมานินทร์ โต้ะหมาด, นพดล ลากเจริญทรัพย์, คณิต สัมบุญณานนท์, ธิติ สว่างศิลป์, เอกภพ สิริชัยนันท์

ภูมิหลัง: การรักษาด้วยเคมีบำบัดร่วมกับการให้รังสีรักษา ก่อนการผ่าตัดในผู้ป่วยมะเร็งลำไส้ส่วนปลายระยะลุกลามก่อนการผ่าตัด จะช่วยลดขนาดของก้อนมะเร็งและเพิ่มโอกาสการได้รับการผ่าตัดที่สามารถเก็บกล้ามเนื้อหูรูดไว้ได้ ทั้งนี้ต้องได้รับการประเมินการตอบสนองต่อการรักษาด้วยความแม่นยำ เพื่อจะเป็นข้อมูลสำหรับการวางแผนการรักษา ปัจจุบันการตรวจคลื่นแม่เหล็กไฟฟ้ามีวิธีการตรวจที่สามารถให้ข้อมูลเชิงลึกเกี่ยวกับการเปลี่ยนแปลงภายในก้อนมะเร็งหลังได้รับการรักษา

วัตถุประสงค์: เพื่อศึกษาหาค่าผลลัพธ์ที่ได้จากการตรวจคลื่นแม่เหล็กไฟฟ้าด้วยวิธี *dynamic contrast enhancement* ในการที่จะช่วยพยากรณ์ผลการรักษาของผู้ป่วยมะเร็งลำไส้ส่วนปลายระยะลุกลาม ที่ได้รับเคมีบำบัดร่วมกับการให้รังสีรักษา ก่อนการผ่าตัด วัตถุประสงค์และวิธีการ: เป็นการศึกษาแบบไปข้างหน้า โดยผ่านการพิจารณารับรองโดยคณะกรรมการจริยธรรมการวิจัยในคน โดยมีผู้ป่วยมะเร็งลำไส้ส่วนปลายระยะลุกลามที่ต้องได้รับการรักษาด้วยเคมีบำบัดร่วมกับการให้รังสีรักษา ก่อนการผ่าตัดทั้งสิ้น 19 ราย ทุกรายได้รับการตรวจคลื่นแม่เหล็กไฟฟ้าวิธีทั่วไป และ *dynamic contrast enhancement* ไล่ละ 3 ครั้ง คือ ก่อนเริ่มการรักษา ระหว่างได้รับการรักษา และเมื่อรับการรักษาครบด้วยเคมีบำบัดร่วมกับการให้รังสีรักษา หลังจากนั้นผู้ป่วยจะเข้ารับการผ่าตัดด้วยเทคนิค *total mesorectal excision* ทุกรายจะทำการบันทึกข้อมูลความหนา ความยาวของมะเร็ง รวมถึงค่าผลลัพธ์ ได้แก่ *maximal slope of enhancement*, *peak enhancement* และ *time to peak* ที่วัดได้จากการตรวจคลื่นแม่เหล็กไฟฟ้า นำมาหาความสัมพันธ์กับลักษณะทางคลินิกและผลการตรวจทางพยาธิวิทยา

ผลการศึกษา: ผลทางพยาธิวิทยาของผู้ป่วย 19 ราย พบ *Dworak regression grade* ของมะเร็งที่ระดับ 0, 1, 2, 3 และ 4 เท่ากับร้อยละ 0, 21.1, 42.1, 26.3 และ 10.5 ตามลำดับ โดยพบว่าขนาดของก้อนมะเร็งที่วัดจากการตรวจคลื่นแม่เหล็กไฟฟ้า หลังการให้การรักษา มีความสัมพันธ์ระดับ *moderate* และ *fair* กับผลการตรวจทางพยาธิวิทยา ทั้งความหนาและความยาวของก้อนมะเร็ง นอกจากนี้การเปลี่ยนแปลงของขนาดก้อนมะเร็งที่วัดได้จะสอดคล้องกับผลการตรวจทางพยาธิวิทยา ที่ประเมินด้วยวิธี *Dworak Regression Grade* ส่วนผลลัพธ์ค่าการเปลี่ยนแปลงของ *maximal slope of enhancement* และ *peak enhancement* ที่วัดได้จากการตรวจวิธี *dynamic contrast enhancement* ไม่แสดงความสัมพันธ์กับการตอบสนองต่อการรักษา ยกเว้นผลลัพธ์ค่าการเปลี่ยนแปลงของ *time to peak* ระหว่างได้รับการรักษา พบมีความสัมพันธ์กับ *Dworak regression grade* และพบว่าค่า *time to peak* จะมีค่าการเปลี่ยนแปลงเพิ่มขึ้นในกลุ่มผู้ป่วยที่มะเร็งไม่ตอบสนองต่อการรักษา โดยมีค่าเพิ่มขึ้นร้อยละ 139.25 เมื่อเทียบกับกลุ่มที่ตอบสนองต่อการรักษา ที่มีค่าเปลี่ยนแปลงเพียงร้อยละ 6.13

สรุป: การเปลี่ยนแปลงของขนาดก้อนมะเร็งจากภาพการตรวจคลื่นแม่เหล็กไฟฟ้าและผลลัพธ์จากการตรวจด้วยวิธี *dynamic contrast enhancement* ที่ได้จากการตรวจระหว่างได้รับการรักษาเปรียบเทียบกับก่อนรักษา มีความสัมพันธ์กับผลการตอบสนองทางพยาธิวิทยา ซึ่งผลดังกล่าวอาจช่วยในการพยากรณ์การตอบสนองต่อการรักษาในผู้ป่วยมะเร็งลำไส้ส่วนปลายที่ได้รับเคมีบำบัดร่วมกับการให้รังสีรักษา ก่อนการผ่าตัด
