

Case Report

Bisphosphonate Therapy for Refractory Langerhans Cell Histiocytosis: A Case Report

Chayamon Takpradit MD*,
Nassawee Vathana MD*, Nattee Narkbunnam MD*,
KleebSabai Sanpakit MD*, Jassada Buaboornam MD*

* Department of Pediatrics, Faculty of Medicine Siriraj Hospital, Mahidol University, Bangkok, Thailand

Although patients diagnosed as Langerhans cell histiocytosis (LCH) with bone lesion initially respond well to treatment, some may experience relapse or refractory disease. Pamidronate, a potent N-bisphosphonate, has been used in several primary bone diseases, benign bone tumors, and metastatic bone cancers. The mechanism includes an inhibitory effect on osteoclast activity by decreasing development and recruitment of osteoclast progenitors and promoting osteoclast apoptosis. Herein, we introduce a seven-month-old Thai girl who was diagnosed as multiple-relapse LCH with refractory bone lesions and was treated with standard and salvage steroid-based therapies. After receiving two courses of intravenous pamidronate, she had marked clinical and radiographical improvement without any adverse events. She has been in remission for two years after receiving six courses of therapy. This report supports the efficacy of pamidronate in LCH-related bone lesions, but further studies in large cohort are warranted.

Keywords: Langerhans cell histiocytosis, Pamidronate, Refractory

J Med Assoc Thai 2015; 98 (11): 1145-9

Full text. e-Journal: <http://www.jmatonline.com>

Langerhans cell histiocytosis (LCH) is a histiocytic disorder caused by an uncontrolled clonal proliferation of dendritic cells with Langerhans cell⁽¹⁾. Clinical manifestation of LCH is heterogeneous, ranging from isolated skin or osteolytic lesion (the most common form) to systemic involvement, such as pituitary gland, liver, and bone marrow⁽²⁾. Although survival of patients with single, solitary lesion is satisfactory⁽²⁾, some patients experience reactivation of the disease. Bony lesions, particularly those in facial bones and cranial fossa, increase the risk of central nervous system diseases, i.e., diabetes insipidus (DI) and neurodegenerative disorders⁽³⁾. Treatment modalities for LCH vary, ranging from curettage or high-dose methylprednisolone in single bone lesion to systemic chemotherapy in multiple bone lesions or multisystem diseases⁽⁴⁾.

Bisphosphonate is an analog inorganic pyrophosphate that negatively targets osteoclasts, resulting in inhibition of bone resorption⁽⁵⁾. Several studies have demonstrated the efficacy of this agent in benign bone tumors, such as fibrous dysplasia and LCH, particularly in pediatric patients^(6,7). Herein, we

present a case of LCH with multiple reactivations of bone lesions that responded to pamidronate (a nitrogen-containing bisphosphonate) despite the patient having received multiple previous courses of chemotherapy.

Case Report

A previously healthy seven-month-old Thai girl was referred to our hospital with progressive neck mass. On physical examination, she was febrile and anemic. Multiple bilateral cervical lymphadenopathies (1.5 to 2 cm in diameter) and marked hepatosplenomegaly were observed. Complete blood count showed hemoglobin 8.6 gm/dl, white blood cell count 12,700/mm³, platelet count 689,000/mm³, and differential white blood count: neutrophils 85%, lymphocytes 7%, monocytes 5.8%, eosinophils 2%, and basophils 0.2%. Liver function test was within normal limits. Histopathological examination of cervical lymph node biopsy confirmed diagnosis of LCH by S-100 protein and CD1a antibody test, and bone marrow study found LCH involvement. Radiographic skeletal survey and radionuclide bone scan identified multiple osteolytic lesions known to be compatible with bone lesion LCH.

She was treated according to arm B, LCH-II risk organ protocol, consisting of oral prednisolone, intravenous vinblastine, and intravenous etoposide administration as shown in Fig. 1⁽⁸⁾. Treatment was given until completion of the induction phase; however,

Correspondence to:

Buaboornam J, Department of Pediatrics, Faculty of Medicine Siriraj Hospital, Mahidol University, Bangkok 10700, Thailand
Phone: +66-2-8663021
E-mail: onco008@yahoo.com

the lymphadenopathy and hepatosplenomegaly persisted. Thus, a cytarabine-based regimen⁽⁹⁾, a salvage treatment protocol, was prescribed. She initially responded to the salvage treatment, but later developed high-grade fever and recrudescent cervical lymphadenopathy. A follow-up bone scan also identified the progression of multiple osteolytic lesions. Because of the release of the LCH-III protocol, she was then treated according to arm A, LCH-III treatment, consisting of oral prednisolone, intravenous vinblastine, and methotrexate intravenous injection as shown in Fig. 2⁽¹⁰⁾. She responded well to treatment, with radionuclide and bone scan showing marked improvement in bony lesions. She came into complete remission after two months of therapy. However, she continued to experience growth failure and osteopenia,

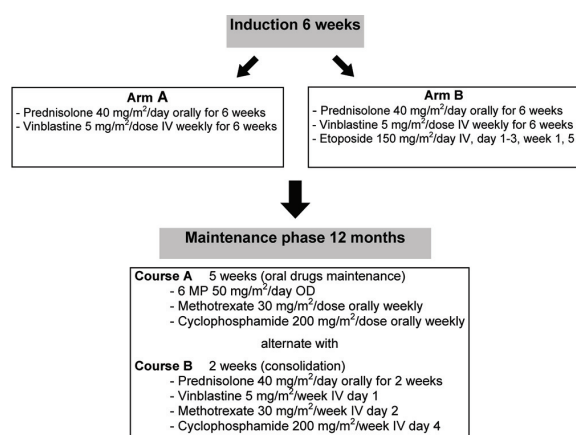


Fig. 1 LCH-II risk organ protocol⁽⁸⁾.

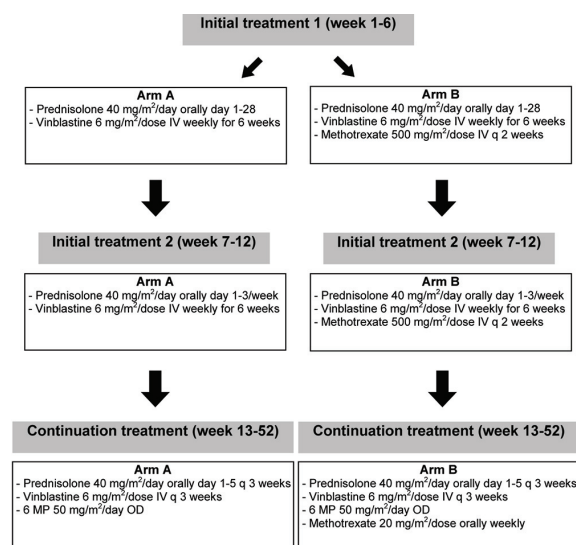


Fig. 2 LCH-III risk treatment⁽¹⁰⁾.

resulting from prolonged use of prednisolone. Treatment therapy was continued for 12 months.

Unfortunately, four months after completion of treatment, she developed intertrochanteric fracture of the right femur and bone pain. Bone scan findings were compatible with relapse of bone disease. She underwent diagnostic and therapeutic curettage at the fracture site, which confirmed recrudescence of LCH. She received four courses of intravenous pulse methylprednisolone therapy, but her bone pain persisted. Follow-up imaging studies identified new abnormal osteolytic lesions, one each at left scapula and left tibia (Fig. 3a). After discussion with and approval from her parents, pamidronate 1 mg/kg intravenous drip over a ten-hour period was given and repeated every four weeks. Her bone pain was resolved after two courses of pamidronate. Her pamidronate treatment continued for six courses without any progression of the disease. During treatment, she experienced no adverse effects from pamidronate and her creatinine and electrolyte levels remained normal. After completion of treatment with pamidronate, a follow-up bone scan revealed marked improvement in all osteolytic lesions (Fig. 3b). Our patient had been in remission for two years since completion of pamidronate treatment, with follow-up bone surveys demonstrating complete resolution of osteolytic lesions.

Discussion

In cases of LCH reactivation, it normally occurs nine to 12 months after completion of treatment, with bone involvement being the most common site⁽¹¹⁾. Optimal treatment for reactivation of LCH has not been well established. Salvage regimens include re-induction with LCH protocol, consisting of vinblastine, prednisolone, and 6-mercaptopurine⁽¹²⁾, cytarabine-based regimen⁽⁹⁾, and cladribine⁽¹³⁾. However, prolonged use of cytotoxic agents and prednisolone might result in neutropenia and growth failure, respectively⁽¹³⁾. In this case, our patient had previously received cytarabine-based regimen as a salvage therapy, but did not clinically respond to it. Alternatively, she was treated according to arm A LCH-III protocol, but her disease reactivated 4 months after completion of treatment.

Pamidronate is a nitrogen-containing bisphosphonate (N-bisphosphonate), which has a higher potency of inhibiting osteoclast activities than simple bisphosphonate⁽¹⁴⁾. Both simple bisphosphonate and N-bisphosphonate have a high affinity for hydroxyapatite (HA), which is responsible for the

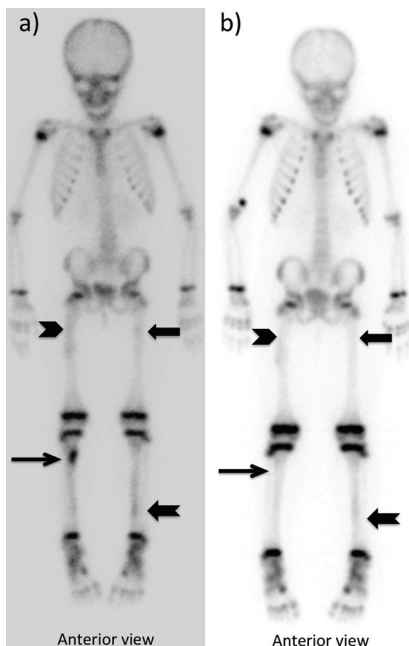


Fig. 3 Whole body bone scan (Tc-99m MDP 12.5 mCi). a) Before bisphosphonate: Tc-99m MDP bone scintigraphy showed new areas of increased uptake at proximal left femur, along proximal half of right femur, proximal right tibia, and along left tibia; all suggestive of new bony metastases. b) After bisphosphonate: Tc-99m MDP bone scintigraphy showed disappearance of abnormal radiotracer uptake at proximal right tibia and improvement of bony metastases at all other sites. Please be advised that avid uptake at right distal humerus was the leakage of the tracer from the injection site.

retention of bisphosphonate in the bones. The mechanistic study of N-bisphosphonate that has been proposed involves the inhibition of the mevalonate enzymatic pathway in the osteoclast, leading to a decrease in isoprenylated proteins, which results in caspase-3 activation and apoptosis of the osteoclast⁽¹⁵⁾. N-bisphosphonate also induces apoptosis in malignant cells (e.g., neuroblastoma cell line) by decreasing phosphorylated Bcl-2, Bcl-2, and Bcl-X(L) expression⁽¹⁶⁾.

In several clinical studies, pamidronate has been found effective in the treatment of several primary and metastatic bone tumors. Morimoto et al undertook a large study of pamidronate treatment in reactivated LCH and reported efficacious results⁽¹⁷⁾. Most patients received pamidronate with meloxicam added as an adjuvant treatment. Few difficult to manage side effects (e.g., acute phase reaction, hypocalcemia, and/or

uveitis) were observed. Of interest, the pediatric patient profiled in the present report responded satisfactorily to single pamidronate (not combined with meloxicam) for six courses without any adverse event.

In addition, improvements in radiographic findings were observed in steroid-induced osteopenic children⁽¹⁸⁾. Accordingly, this strategy may be considered adjuvant therapy for LCH patients treated with protracted courses of prednisolone.

Conclusion

Pamidronate should be considered as a front-line treatment or salvage therapy in bone-lesion LCH, but further investigations are warranted. The findings in this case report support the efficacy of pamidronate in reactivated LCH.

What is already known on this topic?

Treatments for refractory LCH, such as oral prednisolone, intravenous vinblastine, and methotrexate are acknowledged. This patient was treated according to standard treatment and salvage-treatment protocols, but her disease remained refractory.

What this study adds?

Pamidronate is effective in the treatment of refractory LCH, consistent with the findings of Japanese studies. This was the first case report from Thailand describing the effectiveness of pamidronate in the treatment of refractory LCH in a pediatric patient. This report may provide guidance to clinicians engaged in pediatric hematology management in Thailand.

Potential conflicts of interest

None.

References

1. Laman JD, Leenen PJ, Annels NE, Hogendoorn PC, Egeler RM. Langerhans-cell histiocytosis 'insight into DC biology'. *Trends Immunol* 2003; 24: 190-6.
2. Weitzman S, Egeler RM. Langerhans cell histiocytosis: update for the pediatrician. *Curr Opin Pediatr* 2008; 20: 23-9.
3. Imashuku S, Kinugawa N, Matsuzaki A, Kitoh T, Ohki K, Shioda Y, et al. Langerhans cell histiocytosis with multifocal bone lesions: comparative clinical features between single and multi-systems. *Int J Hematol* 2009; 90: 506-12.
4. Nauert C, Zornoza J, Ayala A, Harle TS. Eosinophilic granuloma of bone: diagnosis and

- management. *Skeletal Radiol* 1983; 10: 227-35.
5. Rogers MJ, Gordon S, Benford HL, Coxon FP, Luckman SP, Monkkonen J, et al. Cellular and molecular mechanisms of action of bisphosphonates. *Cancer* 2000; 88: 2961-78.
 6. Gibbons CL, Petra M, Smith R, Athanasou NA. Bisphosphonate treatment of benign multifocal and unifocal osteolytic tumours of bone. *Sarcoma* 2003; 7: 35-41.
 7. Cornelis F, Truchetet ME, Amoretti N, Verdier D, Fournier C, Pillet O, et al. Bisphosphonate therapy for unresectable symptomatic benign bone tumors: a long-term prospective study of tolerance and efficacy. *Bone* 2014; 58: 11-6.
 8. Gadner H, Grois N, Potschger U, Minkov M, Arico M, Braier J, et al. Improved outcome in multisystem Langerhans cell histiocytosis is associated with therapy intensification. *Blood* 2008; 111: 2556-62.
 9. Egeler RM, de Kraker J, Voute PA. Cytosine-arabioside, vincristine, and prednisolone in the treatment of children with disseminated Langerhans cell histiocytosis with organ dysfunction: experience at a single institution. *Med Pediatr Oncol* 1993; 21: 265-70.
 10. Gadner H, Minkov M, Grois N, Potschger U, Thiem E, Arico M, et al. Therapy prolongation improves outcome in multisystem Langerhans cell histiocytosis. *Blood* 2013; 121: 5006-14.
 11. Pollono D, Rey G, Latella A, Rosso D, Chantada G, Braier J. Reactivation and risk of sequelae in Langerhans cell histiocytosis. *Pediatr Blood Cancer* 2007; 48: 696-9.
 12. Titgemeyer C, Grois N, Minkov M, Flucher-Wolfram B, Gatterer-Menz I, Gadner H. Pattern and course of single-system disease in Langerhans cell histiocytosis data from the DAL-HX 83- and 90-study. *Med Pediatr Oncol* 2001; 37: 108-14.
 13. Weitzman S, Braier J, Donadieu J, Egeler RM, Grois N, Ladisch S, et al. 2'-Chlorodeoxyadenosine (2-CdA) as salvage therapy for Langerhans cell histiocytosis (LCH). results of the LCH-S-98 protocol of the Histiocyte Society. *Pediatr Blood Cancer* 2009; 53: 1271-6.
 14. Eghbali-Fatourehchi G. Bisphosphonate therapy in pediatric patients. *J Diabetes Metab Disord* 2014; 13: 109.
 15. Benford HL, Frith JC, Auriola S, Monkkonen J, Rogers MJ. Farnesol and geranylgeraniol prevent activation of caspases by aminobisphosphonates: biochemical evidence for two distinct pharmacological classes of bisphosphonate drugs. *Mol Pharmacol* 1999; 56: 131-40.
 16. Peng H, Sohara Y, Moats RA, Nelson MD Jr, Groshen SG, Ye W, et al. The activity of zoledronic acid on neuroblastoma bone metastasis involves inhibition of osteoclasts and tumor cell survival and proliferation. *Cancer Res* 2007; 67: 9346-55.
 17. Morimoto A, Shioda Y, Imamura T, Kanegane H, Sato T, Kudo K, et al. Nationwide survey of bisphosphonate therapy for children with reactivated Langerhans cell histiocytosis in Japan. *Pediatr Blood Cancer* 2011; 56: 110-5.
 18. Noguera A, Ros JB, Pavia C, Alcover E, Valls C, Villaronga M, et al. Bisphosphonates, a new treatment for glucocorticoid-induced osteoporosis in children. *J Pediatr Endocrinol Metab* 2003; 16: 529-36.

การรักษาด้วยยาบิสฟอสโฟเนต สำหรับผู้ป่วยแลงเกอร์ฮานส์ เซลล์ อีสทิโอไซโทซิสที่ติดต่อการรักษาด้วยยาสเตียรอยด์
และยาเคมีบำบัด: รายงานผู้ป่วย

ชฎามน ทักษ์ประดิษฐ์, ณัฏวีร์ วัฒนา, นัทธี นาคบุญนำ, กลีบสไบ สรรพกิจ, เจษฎา บัวบุญนำ

แม้ว่าผู้ป่วยโรคแลงเกอร์ฮานส์ เซลล์ อีสทิโอไซโทซิส ที่มีรอยโรคในกระดูก จะมีแนวโน้มที่จะตอบสนองดีต่อการรักษา แต่ผู้ป่วยจำนวนหนึ่งกลับประสบปัญหาโรคกลับเป็นซ้ำหลังหยุดยา หรือ บางรายคือต่อการรักษา จากการใช้ยาพามิโดรเนต ซึ่งเป็นยากลับบิสฟอสโฟเนตที่มีฤทธิ์แรงในการรักษากระดูกความผิดปกติของกระดูกหลายชนิด เช่น โรคเนื้องอกของกระดูก โรคมะเร็งที่มีการกระจายไปที่กระดูก โดยอาศัยคุณสมบัติของยาในการยับยั้งการทำงานของเซลล์ออสติโอคลาส รายงานฉบับนี้เป็นการรายงานผลการใช้ยาพามิโดรเนตในผู้ป่วยเด็กหญิงไทยที่ได้รับการวินิจฉัยเป็นโรคแลงเกอร์ฮานส์ เซลล์ อีสทิโอไซโทซิส และมีปัญหาโรคกลับเป็นซ้ำหลายครั้งร่วมกับมีรอยโรคในกระดูกที่ติดต่อการรักษาด้วยยาเคมีบำบัดและสเตียรอยด์ หลังจากที่ผู้ป่วยได้รับการรักษาด้วยยาพามิโดรเนตทางหลอดเลือดดำทุก 4 สัปดาห์ ผู้ป่วยมีอาการและผลการประเมินทางรังสีที่ดีขึ้นอย่างชัดเจนตั้งแต่วินิจฉัยครั้งแรกของการรักษา โดยไม่พบผลข้างเคียงจากการใช้ยา ผู้ป่วยได้รับยาพามิโดรเนตทั้งหมด 6 ครั้ง ปัจจุบันผู้ป่วยอยู่ในภาวะโรคสงบเป็นเวลาสองปีหลังหยุดยา รายงานฉบับนี้สนับสนุนประโยชน์ของยาพามิโดรเนตในผู้ป่วยแลงเกอร์ฮานส์ เซลล์ อีสทิโอไซโทซิสที่มีรอยโรคในกระดูก อย่างไรก็ตามบทบาทของยาพามิโดรเนตในผู้ป่วยกลุ่มนี้ควรมีการศึกษาเพิ่มเติมในผู้ป่วยจำนวนมากขึ้น
