

# Descriptive Profile Outcomes between Closed and Open Drainage Systems Following Urethroplasty

Piyawan Chiengkriwate MD\*,  
Wararat Chamnanniam BNS\*, Nopporn Ketwilai BSc, MPA\*

\* Pediatric Surgery Unit, Department of Surgery, Faculty of Medicine, Prince of Songkla University, Hat Yai, Songkhla, Thailand

**Background:** An indwelling urinary catheter or urethral stent are standardly used following a urethroplasty to prevent post-operative urinary retention. There are both closed drainage system (CDS) and open drainage system (ODS) available.

**Objective:** The study was designed to determine the outcomes between post-operative CDS and ODS.

**Material and Method:** Fifty-seven hypospadias patients with 66 urethroplasties, performed by a single surgeon, were assessed. During the 40-month study period, the operative outcomes relative to the technique of both urinary catheter drainage systems were evaluated for length of hospital stay (LOS), cost of hospitalization, and post-operative complications.

**Results:** CDS and ODS drainage systems were performed in 32 and 34 operations, respectively. The patient characteristics, the surgical profiles, and post-operative complications were not statistically significant. The CDS/ODS group had median LOS (range) of 9 (1 to 22)/2 (1 to 6) days, respectively, and cost of hospitalization (SD) of 22,908 (4,455)/18,408 (3,848) Bahts respectively. Both had statistical significance,  $p < 0.001$ . The subgroup of 26 posterior hypospadias and TIP urethroplasties were also evaluated.

**Conclusion:** Patients with hypospadias given an open drainage system after urethroplasty have a higher rate of early discharge, lower cost of hospitalization, and a lower rate of wound infection.

**Keywords:** Drainage system, Hypospadias, Urethroplasty, Urinary catheter

*J Med Assoc Thai* 2015; 98 (7): 664-9

Full text. e-Journal: <http://www.jmatonline.com>

Hypospadias is a common congenital anomaly of the penis. It is defined by abortive development of the urethral spongiosum and ventral prepuce, and in more severe cases, ventral penile curvature<sup>(1)</sup>. The physical examination of the penis typically finds a proximally displaced urethral orifice anywhere along the penile shaft, or even in the scrotum or perineum<sup>(2)</sup>. A recent American Academy of Pediatrics review suggests that the ideal age for genital surgery is between 6 and 12 months<sup>(3)</sup>. The physician must also consider psychological concerns when planning medical procedures for children, as psychological trauma at a young age can have wide-ranging effects on later adult behavior<sup>(4)</sup>. Given these various considerations, a recent report concluded the best time for hypospadias repair is between 6 and 18 months<sup>(5)</sup>.

The therapeutic goal of hypospadias is the reconstruction of the primary malformation into a normal penis. The successful hypospadias involves

urethroplasty or penile straightening, urethroplasty, meatoplasty and glanuloplasty, scrotoplasty, and skin coverage<sup>(1)</sup>, which are performed in different operative steps depending on the individual components required. Many operative techniques have evolved to correct hypospadias. Tubularized incised plate (TIP) urethroplasty is currently one of the most popular techniques for hypospadias repair that has now been successfully applied to all varieties of hypospadias<sup>(6-9)</sup>.

An indwelling urinary catheter or urethral stent are standard usage following a urethroplasty to prevent post-operative urinary retention, but there are often undesirable side effects from these techniques such as infection or increased morbidity due to pain, inadvertent pressure on the neourethra, bladder spasms, and migration. There are two different drainage systems available for use in post-operative catheterization, the closed drainage system (CDS)<sup>(10)</sup> and open drainage system (ODS)<sup>(11-14)</sup>. It has not yet been decided in Thai context whether CDS or ODS is more beneficial, or has less side effects. The present study was descriptive profile of the operative outcomes and proportion of post-operative infections relative to the different types of catheter drainage, CDS and ODS, in post-operative urethroplasty.

**Correspondence to:**

Chiengkriwate P, Pediatric Surgery Unit, Department of Surgery, Faculty of Medicine, Prince of Songkla University, Hat Yai, Songkhla 90110, Thailand.

Phone: +66-74-451401, Fax: +66-74-429384

E-mail: [chiengkriwate\\_piyawan@hotmail.com](mailto:chiengkriwate_piyawan@hotmail.com)

## Material and Method

With ethical approval by the Institutional Review Board, a retrospective study of 66 urethroplasties in hypospadias patients whose operations were performed by a single pediatric surgeon, at Songklanagarind Hospital between 2009 and 2012 were reviewed.

The characteristics, surgical profiles, and post-operative complication were reviewed, comparison between CDS and ODS following urethroplasty. The data included age, type of hypospadias, ventral penile curvature, redo-urethroplasty, neourethral length (interquartile range), operative time, post-operative antibiotic, duration of retaining urethral catheter (interquartile range), and post-operative complication.

## Surgical procedure

Urethral dilatation was performed and the skin marked. The 1% xylocaine with 1:100,000 adrenaline was infiltrated at the skin mark. A hanging stitch at the glans penis was performed using 4-0 chromic catgut suture. An eight-French feeding tube was inserted into the bladder as a urinary catheter. The skin incision was then made, and the particular method of surgical urethroplasty was then decided depending on the findings following the incision. Tubularization was performed using 8-0 PGA (polyglycolic acid absorbable suture) in two layers: a continuous suture in the first subepithelial layer, and interrupted sutures in the second layer. The pedicular subcutaneous flap was dissected and brought to cover the entire neourethra and suture line. The meatoplasty and glansplasty were performed by separated glans wing and closed with 6-0 PDS (polydioxanone violet monofilament absorbable suture) and 8-0 PGA. The penile skin base was fixed to the penile base with 6-0 PDS. The penis was covered with the dorsal prepuce skin flap.

A pressure dressing was made with sterile Tegaderm™ (transparent film dressing frame style, 6 cm x 7 cm, 3M Health Care), as demonstrated in Fig. 1. The tube was fixed to the glans with loosely tied 4-0 chromic suture. In the CDS closings the catheter was connected to a urinary drainage bag, while in the ODS closings the catheter was cut 2 cm distal to the urethral meatus and allowed to drain into a single diaper.

## Post-operative protocol

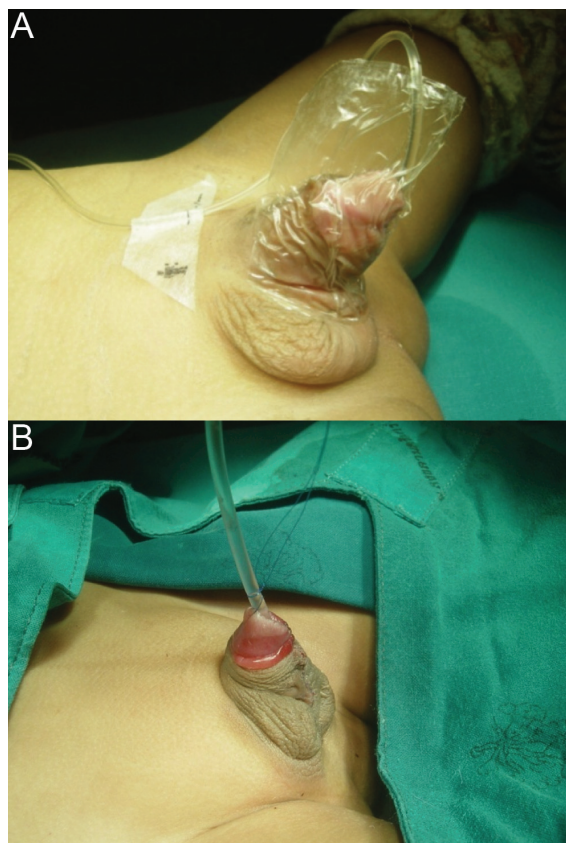
Post-operative analgesia consisted of oral acetaminophen, and most patients were given an oral antibiotic while they were on the stent. Suprapubic

diversion was not used for any of the patients. The parents were instructed by the patient care team in general post-operative care, dressing and cleansing the operative site with normal saline, stent care, what activities the infant could be allowed to do, and nutrition, parents were given a hotline phone number and the surgeon's e-mail in case of emergencies or questions.

Before April 2011, the patients were provided with urinary diversion via a CDS for approximately one to two weeks, were restricted in the allowed activities, and were not discharged until the stent was removed. However, in April 2011, we changed our protocol, patients were mobilized as they could tolerate it, with early discharge when deemed safe, and the stent later removed by the surgeon in the outpatient clinic one to two weeks post-operatively.

## Statistical analysis

Statistical analyses were undertaken using the R-program (version 2.15.0). The outcome variables of



**Fig. 1** A) A closed urinary drainage system (CDS).  
B) An open urinary drainage system (ODS).

open and closed urinary catheter drainage systems were compared using Fisher's exact test,  $X^2$ , the rank sum test, and the Student's t-test. Multiple linear regressions were performed with model building using the stepwise method. Statistical significance was considered at a probability of  $p < 0.05$ , unless otherwise specified.

## Results

There were 57 patients with 66 operations. The patients characteristics of CDS/ODS group included age of 0 to one year of 6 (18.8%)/6 (17.6%), age more than one year of 26 (81.25)/28 (82.4%), anterior hypospadias of 5 (15.6%)/9 (26.5%), middle hypospadias of 8 (25.0%)/7 (20.6%), posterior hypospadias of 19 (59.4%)/18 (52.9%), and ventral penile curvature of 25 (78.1%)/28 (82.4%), were not statistically significant. The surgical profiles of CDS/ODS group comprised of urethroplasty of 22 (68.8%)/28 (82.4%), redo-urethroplasty of 10 (31.2%)/11 (32.4%), neourethral length (interquartile range) of 2.2 (1.9 to 4.0)/2 (1.4 to 3.0) cm, operative time (SD) of 202.6 (60.1)/197.2 (62.5) minutes, post-operative oral antibiotic of 28 (87.5%)/27 (79.4%), duration of retaining urethral catheter (interquartile range) of 5 (3.8 to 7.0)/5 (5.0 to 9.8) days. Besides, the post-operative complications were wound infection of 5 (15.6%)/3 (8.8%), and urinary tract infection of 2 (6.2%)/none, and catheter problem of 4 (12.5%)/6 (17.6%), respectively. The distribution of study variables according to outcome was presented in Table 1. All of patient characteristics, surgical profiles, and post-operative complications were not statistically significant.

After multiple linear regressions for total cost of hospital stay, variables that remained in the model were length of stay (range 1 to 22 days) and operative time (range 80 to 325 minutes). The appropriate model of total cost (Baht) of hospital stay given by the stepwise method was calculated as follows: (estimated cost)<sup>1/3</sup> = 22.157 + 0.279X + 0.018Y, where X = length of hospital stay (day) and Y = total operative time (minute), by adjusted R-squared equal 0.799 and  $p < 0.001$ . Likewise, estimated cost = (22.157 + 0.279X + 0.018Y)<sup>3</sup> at that time 1 U.S. dollar was around 30 Thai Bahts.

The CDS/ODS group had median LOS (range) of 9 (1 to 22)/2 (1 to 6) days, and cost of hospitalization (SD) of 22,908 (4,455)/18,408 (3,848). Both had statistical significance,  $p < 0.001$ .

In subgroup analysis of 26 cases, posterior hypospadias and TIP urethroplasty, there were eight

(30.8%) catheter problems, four (15.4%) wound infections, and no urinary tract infection (UTI). The distribution of study variables according to outcome was presented in Table 2. The CDS/ODS group had median LOS (range) of 9 (8 to 12)/2 (1 to 3) days that had statistical significance,  $p = 0.002$ . The surgical profile of CDS/ODS group comprised of neourethral length (SD) of 3.7 (1.2)/3.3 (1.6) cm, operative time (SD) of 205.1 (78.3)/216.5 (63.3) minutes, post-operative oral antibiotic of 7 (77.8%)/14 (82.4%), duration of retaining urethral catheter (SD) of 6.6 (4.7)/8.5 (3.5) days. Furthermore, the post-operative complication were wound infection of 2 (22.2%)/2 (11.8%), and catheter problem of 3 (33.3%)/5 (29.4%), respectively. There were no statistical significances.

**Table 1.** Characteristics of hypospadias patient and profile outcomes

	CDS (n = 32) No. (%)	ODS (n = 34) No. (%)
Age		
0 to 1 year	6 (18.8)	6 (17.6)
More than 1 year	26 (81.2)	28 (82.4)
Hypospadias type		
Anterior	5 (15.6)	9 (26.5)
Middle	8 (25.0)	7 (20.6)
Posterior	19 (59.4)	18 (52.9)
Ventral penile curvature	25 (78.1)	28 (82.4)
Operation		
Urethroplasty	22 (68.8)	23 (67.6)
Redo-urethroplasty	10 (31.2)	11 (32.4)
Neourethral length (cm)		
Median	2.2	2
Interquartile range	1.9 to 4.0	1.4 to 3.0
Operative time (minute)		
Mean ± SD	202.6±60.1	197.2±62.5
Post-operative oral antibiotic	28 (87.5)	27 (79.4)
Duration of retaining urinary catheter (days)		
Median	5	5
Interquartile range	3.8 to 7.0	5.0 to 9.8
Length of stay (days)		
9		2*
Range	1 to 22	1 to 6
Cost of hospitalization (Baht)		
Mean ± SD	22,908±4,455	18,408±3,848*
Complication		
Wound infection	5 (15.6)	3 (8.8)
Urinary tract infection	2 (6.2)	-
Catheter problem	4 (12.5)	6 (17.6)

CDS = closed drainage system; ODS = open drainage system  
\* Statistical significance,  $p < 0.05$

**Table 2.** Subgroup outcomes of posterior hypospadias and TIP urethroplasty

	CDS (n = 9) No. (%)	ODS (n = 17) No. (%)
Neourethral length (cm)		
Mean ± SD	3.7±1.2	3.3±1.6
Operative time (minute)		
Mean ± SD	205.1±78.3	216.5±63.3
Post-operative oral antibiotic	7 (77.8)	14 (82.4)
Duration of retaining urinary catheter (days)		
Mean ± SD	6.6±4.7	8.5±3.5
Length of stay (days)	9	2*
Interquartile range	8 to 12	1 to 3
Cost of hospitalization (Baht)		
Mean ± SD	22,285±3,873	19,154±4,247
Complication		
Wound infection	2 (22.2)	2 (11.8)
Catheter problem	3 (33.3)	5 (29.4)

TIP = tubularized incised plate

\* Statistical significance,  $p < 0.05$

## Discussion

The type and timing of urinary diversion after a hypospadias repair depends on the degree of hypospadias and the surgical decision. Stent-free hypospadias repairs for distal and mid-shaft penile hypospadias have been reported in the literature<sup>(15-20)</sup>, while some hypospadias repairs involve post-operative stenting<sup>(9,10,14,21-24)</sup> or suprapubic cystostomy for urinary diversion<sup>(25,26)</sup>.

The present study showed the proportion of post-operative complications between a closed urinary drainage system and an open urinary drainage system, there was no difference in the wound infection, UTI, and catheter problem. Published rates of urinary tract infection following a hypospadias operation range between 1% and 29%<sup>(12,18)</sup>. In the series, the patients were left with an open urinary drainage system had no urinary tract infections, while patients fitted with a closed urinary drainage system had a rate of UTI infection of 6%.

Earlier studies<sup>(12,14)</sup> suggested that an open urinary drainage system should use the double diaper technique. However, in the present study, an open urinary drainage system with a single diaper was founded to be practical and safe. Furthermore, a short 2 cm catheter distal to the urethral meatus also minimizes the problem of catheter kinking. With an open system, the patient can ambulate as much as they can tolerate, and take baths that decrease the

discomfort normally experienced due to catheter restraints associated with the closed urinary drainage system.

The cost of hospital stay for a patient with an open urinary drainage system was lower than those with closed urinary drainage system, mainly because their length of hospital stay was usually shorter than a patient with a closed urinary drainage system. Patients with hypospadias after urethroplasty on an open urinary drainage system can be discharged early, and attend as day care or outpatient surgical patients<sup>(14)</sup>. Furthermore, patients with posterior hypospadias after TIP urethroplasty can be cared as day surgery.

In conclusion, an open urinary drainage system in post-operative catheterization for urethroplasty was founded to be feasible, safer, lower hospital cost per patient, with earlier discharge, and no difference in the rate of post-operative complications, than a closed urinary drainage system. Furthermore, based on subjective assessment, the study suggested that patients with hypospadias after urethroplasty could be treated as day care surgical patients by using an open urinary drainage system.

## What is already known on this topic?

The urethral stent uses to protect post-operative urinary obstruction. There are two urinary drainage systems, the closed drainage system and open drainage system. Published rates of urinary tract infection following a hypospadias operation range between 1% and 29%.

Previous studies suggested that an open urinary drainage system should use the double diaper technique.

## What this study adds?

The prevalence of urinary tract infection after post-operative urethroplasty in the hypospadias patients who left with an open urinary drainage and a closed urinary drainage system were 0% and 6%, respectively.

The findings support the open urinary drainage system with a single diaper was founded to be practical and safe.

## Acknowledgements

The first author (Chiengkriwate P) was supported by a researcher support grant from the Faculty of Medicine, Prince of Songkla University, Songkhla, Thailand. The authors thank Mr. Dave Patterson of the Office of International Affairs of the

Faculty of Medicine, Prince of Songkla University, for editing the manuscript for English usage.

#### Potential conflicts of interest

None.

#### References

1. Baskin LS, Ebbers MB. Hypospadias: anatomy, etiology, and technique. *J Pediatr Surg* 2006; 41: 463-72.
2. Kraft KH, Shukla AR, Canning DA. Proximal hypospadias. *ScientificWorldJournal* 2011; 11: 894-906.
3. Kass E, Kogan SJ. Timing of elective surgery on the genitalia of male children with particular reference to the risks, benefits, and psychological effects of surgery and anesthesia. *American Academy of Pediatrics. Pediatrics* 1996; 97: 590-4.
4. Schultz JR, Klykylo WM, Wacksman J. Timing of elective hypospadias repair in children. *Pediatrics* 1983; 71: 342-51.
5. Bhat A. General considerations in hypospadias surgery. *Indian J Urol* 2008; 24: 188-94.
6. Snodgrass WT, Lorenzo A. Tubularized incised-plate urethroplasty for proximal hypospadias. *BJU Int* 2002; 89: 90-3.
7. Snodgrass WT, Lorenzo A. Tubularized incised-plate urethroplasty for hypospadias reoperation. *BJU Int* 2002; 89: 98-100.
8. Snodgrass WT. Snodgrass technique for hypospadias repair. *BJU Int* 2005; 95: 683-93.
9. Snodgrass W, Bush N. Tubularized incised plate proximal hypospadias repair: Continued evolution and extended applications. *J Pediatr Urol* 2011; 7: 2-9.
10. El Sherbiny MT. Tubularized incised plate repair of distal hypospadias in toilet-trained children: should a stent be left? *BJU Int* 2003; 92: 1003-5.
11. Riccabona M. Current trends in the management of primary hypospadias: indication for surgery and surgical goal. *Urologe A* 2011; 50: 579-83.
12. Montagnino BA, Gonzales ET Jr, Roth DR. Open catheter drainage after urethral surgery. *J Urol* 1988; 140: 1250-2.
13. Gonzalez R, Vivas C. Pediatric urethral reconstruction without proximal diversion. *J Urol* 1986; 136: 264-5.
14. Ritch CR, Murphy AM, Woldu SL, Reiley EA, Hensle TW. Overnight urethral stenting after tubularized incised plate urethroplasty for distal hypospadias. *Pediatr Surg Int* 2010; 26: 639-42.
15. Aktug T, Akgur FM, Olguner M, Eroglu G, Hosgor M. Outpatient catheterless Mathieu repair: how to cover ventral penile skin defect. *Eur J Pediatr Surg* 1992; 2: 99-101.
16. Almodhen F, Alzahrani A, Jednak R, Capolicchio JP, El Sherbiny MT. Nonstented tubularized incised plate urethroplasty with Y-to-I spongioplasty in non-toilet trained children. *Can Urol Assoc J* 2008; 2: 110-4.
17. Braga LH, Lorenzo AJ, Suoub M, Bagli DJ. Is statistical significance sufficient? Importance of interaction and confounding in hypospadias analysis. *J Urol* 2010; 184: 2510-5.
18. Leclair MD, Camby C, Battisti S, Renaud G, Plattner V, Heloury Y. Unstented tubularized incised plate urethroplasty combined with foreskin reconstruction for distal hypospadias. *Eur Urol* 2004; 46: 526-30.
19. Samuel M, Capps S, Worthy A. Distal hypospadias: which repair? *BJU Int* 2002; 90: 88-91.
20. Turial S, Enders J, Engel V, Schier F. Stent-free tubularized incised plate (TIP) repair of distal and mid-shaft hypospadias irrespective of age. *Eur J Pediatr Surg* 2011; 21: 168-70.
21. el-Kassaby AW, Al Kandari AM, Elzayat T, Shokeir AA. Modified tubularized incised plate urethroplasty for hypospadias repair: a long-term results of 764 patients. *Urology* 2008; 71: 611-5.
22. Aslan AR, Yucebas E, Tekin A, Sengor F, Kogan BA. Short-term catheterization after TIP repair in distal hypospadias: who are the best candidates? *Pediatr Surg Int* 2007; 23: 265-9.
23. Arda IS, Mahmutoglu M. Urethral catheterization in hypospadias surgery: Should the device enter the bladder or be made a urethral stent? *J Pediatr Surg* 2001; 36: 1829-31.
24. Tonvichien L, Niramis R. Tubularized, incised plate urethroplasty in hypospadias repair: experience at Queen Sirikit National Institute of Child Health. *J Med Assoc Thai* 2003; 86 (Suppl 3): S522-30.
25. Elbakry A. Further experience with the tubularized-incised urethral plate technique for hypospadias repair. *BJU Int* 2002; 89: 291-4.
26. Demirbilek S, Atayurt HF. One-stage hypospadias repair with stent or suprapubic diversion: which is better? *J Pediatr Surg* 1997; 32: 1711-2.

---

บรรยายลักษณะผลที่ได้รับระหว่างระบบการระบายแบบปิดและแบบเปิดภายหลังการผ่าตัดตกแต่งท่อปัสสาวะ

ปิยวรรณ เชียงไกรเวช, วรรัตน์ ชำนาญนิยม, นพพร เกตุวิสัย

ภูมิหลัง: การใส่สายสวนระบายปัสสาวะหรือสายตรงท่อปัสสาวะเป็นวิธีการมาตรฐาน ภายหลังการผ่าตัดตกแต่งท่อปัสสาวะ เพื่อป้องกันภาวะปัสสาวะคั่งหลังผ่าตัด มีระบบการระบายปัสสาวะทั้งแบบปิดและแบบเปิด

วัตถุประสงค์: การศึกษาออกแบบเพื่อค้นหาผลที่ได้รับระหว่างระบบการระบายปัสสาวะแบบปิดและแบบเปิดภายหลังการผ่าตัด

วัสดุและวิธีการ: ประเมินการผ่าตัดตกแต่งท่อปัสสาวะในผู้ป่วยเด็กโรคท่อปัสสาวะเปิด 57 ราย 66 ครั้ง โดยกุมารศัลยแพทย์คนเดียวกัน ระหว่างการศึกษาช่วง 40 เดือน ประเมินผลที่ได้รับจากการผ่าตัดสัมพันธ์กับเทคนิคระบบการระบายปัสสาวะทั้งสองระบบ เกี่ยวกับระยะเวลาอนโรงพยาบาล ค่าใช้จ่ายโรงพยาบาล และภาวะแทรกซ้อนหลังผ่าตัด

ผลการศึกษา: ใช้ระบบการระบายปัสสาวะแบบปิด 32 ราย และใช้แบบเปิดระบายปัสสาวะ 34 ราย ลักษณะผู้ป่วย ล้วนฐานการผ่าตัด และภาวะแทรกซ้อนหลังผ่าตัดไม่มีความแตกต่างอย่างมีนัยสำคัญ กลุ่มระบายปัสสาวะแบบปิด/กลุ่มระบายปัสสาวะแบบเปิด มีมัธยฐานระยะเวลาอนโรงพยาบาล (พิสัย) เท่ากับ 9 (1 ถึง 22)/2 (1 ถึง 6) วัน และ ค่าใช้จ่ายโรงพยาบาล (ค่าเบี่ยงเบนมาตรฐาน) เท่ากับ 22,908 (4,455)/18,408 (3,848) บาท ทั้งสองมีความแตกต่างอย่างมีนัยสำคัญ (ค่า  $p < 0.001$ ) นอกจากนี้ยังได้ประเมินกลุ่มย่อย 26 ราย ของโรคท่อปัสสาวะเปิดตำแหน่งด้านหลังและได้รับการผ่าตัดตกแต่งท่อปัสสาวะแบบ tubularized incised plate (TIP)

สรุป: ผู้ป่วยเด็กโรคท่อปัสสาวะเปิดตำแหน่งด้านหลังการผ่าตัดตกแต่งท่อปัสสาวะ กลุ่มการใช้ระบบการระบายปัสสาวะแบบเปิดสามารถกลับออกจากโรงพยาบาลเร็วกว่า ค่าใช้จ่ายโรงพยาบาลถูกกว่า เช่นเดียวกับอัตราผลติดเชื้อต่ำกว่า

---