

# Prevalence and Echocardiographic Characteristics of Common Congenital Heart Disease in Adult Patients at Siriraj Hospital: 10-Year Study

Nithima Ratanasit MD\*

Khemajira Karaketklang MPH\*\*, Decho Jakrapanichakul MD\*, Maytinee Kittipovanonth MD\*, Kesaree Punlee BSc, MM\*\*\*, Wandee Rochanasiri BNS\*\*\*, Suteera Phrudprisan BNS\*\*\*.

\* Division of Cardiology, Department of Medicine, Siriraj Hospital, Mahidol University, Bangkok, Thailand

\*\* Department of Medicine, Siriraj Hospital, Mahidol University, Bangkok, Thailand

\*\*\* Her Majesty Cardiac Center, Siriraj Hospital, Mahidol University, Bangkok, Thailand

---

**Background:** The number of adult patients with congenital heart disease (CHD) has increased rapidly and represents a major challenge in cardiovascular medicine. Data regarding the prevalence and characteristics of adult CHD in Thai population over the past decade are lacking.

**Material and Method:** Patients who underwent comprehensive transthoracic echocardiographic study at Siriraj Hospital during January 2003 to May 2013 with the diagnosis of unrepaired CHD and complete data were enrolled in the study. Patients with uncertain diagnosis, prior cardiac intervention, bicuspid aortic valve, patent foramen ovale, mitral valve prolapse, isolated persistent left superior vena cava and congenital cardiomyopathies were excluded.

**Results:** Among 27,132 patients underwent transthoracic echocardiography, 1,082 (age 36.7±14.7 years, 75.3% female) had the diagnosis of CHD and the prevalence was 4.0% (95% confidence interval = 3.76-4.23%). The majority were isolated simple left-to-right shunt lesions: atrial septal defect (43%), ventricular septal defect (27%) and patent ductus arteriosus (11%). Eisenmenger syndrome was reported in 77 patients (age 39.1±10.8 years, 71.4% female). Pulmonic stenosis and Ebstein's anomaly were reported in 2.9% and 2.8% of patients, respectively. Tetralogy of Fallot was the most common cyanotic defect (3.5%). The combinations of shunts and/or right-sided obstructive lesions were reported in 4.8%.

**Conclusion:** The prevalence of adult CHD diagnosed by echocardiography at Siriraj Hospital was 4.0% and atrial septal defect was the most common form. Simple shunt lesions represent more than 80% of patients. Female predominance was reported in all common forms of CHD. Echocardiography is fundamental for the diagnosis and management of patients with CHD.

**Keywords:** Adult, Congenital heart disease, Echocardiography

*J Med Assoc Thai 2015; 98 (1): 7-13*

**Full text. e-Journal:** <http://www.jmatonline.com>

---

Congenital heart disease (CHD) is a term used to describe a variety of heart diseases that have been present since the time of birth. The live birth incidence of CHD is approximately 1% or less<sup>(1-3)</sup>. However, the number may vary according to the population studied as well as the timing and techniques used for the diagnosis. There is a wide variety of congenital heart defects with many different forms of severity, ranging from asymptomatic to life-threatening lesions. According to recent advances in cardiac imaging techniques, most of congenital defects can be detected in early life by pediatric cardiologists. However, not

uncommonly, some of CHD are undetectable during childhood but diagnosed later in adolescents or adults<sup>(1,4)</sup>. Among all adult patients with unrepaired CHD, the three commonest cardiac lesions are a simple lesion with left-to-right shunt: atrial septal defect (ASD), ventricular septal defect (VSD) and patent ductus arteriosus (PDA). These three common simple lesions constitute about one-third of adult patients with CHD, while less frequent lesions are complex cyanotic heart diseases. The prevalence of CHD in adults is continuously increasing<sup>(2,5)</sup> and even more difficult to determine. Advance in diagnosis and management of patients with CHD have led to the majority of such patients surviving into adulthood. Some of them are diagnosed as having CHD later in life without any symptoms; others have survived life-saving childhood surgery. It is important to note that the number of adults

---

**Correspondence to:**

Ratanasit N, Division of Cardiology, Department of Medicine, Siriraj Hospital, Mahidol University, Bangkok 10700, Thailand.

Phone: 0-2412-7000 ext. 6104, Fax: 0-2412-7412

E-mail: [nithima.cha@mahidol.ac.th](mailto:nithima.cha@mahidol.ac.th)

with CHD, both with repaired and unrepaired lesions, has grown rapidly, even more than that of children. This growing population represents a common and major challenge to health care as it includes a large number of diverse anatomical malformations of varying severities at various stages of their natural history and with different degrees of anatomic repair.

During the past two decades, there have been numerous advances in cardiac imaging techniques. Resulting from this emerging technology, the site of diagnosis of adult patients with CHD has been transformed from the catheterization laboratory to the imaging laboratory (such as the Echocardiography Laboratory). At Siriraj Hospital, the authors have a well-equipped Echocardiography laboratory with a complete data managing system. Almost all patients with CHD who present at Siriraj Hospital undergo the comprehensive Echocardiographic examination before making the diagnosis. Since there is an increasing concern about the problem of adult CHD and information about the prevalence and characters of CHD in Thai population is lacking, it is the aim of this study to provide essential information regarding the issue of adult CHD in Thai patients who underwent transthoracic echocardiography at Siriraj Hospital during January 2003 to May 2013. The focus will be the recognition of the problem in terms of the prevalence and some important echocardiographic characteristics of common adult CHD in the Thai population.

## **Material and Method**

### ***Study population***

Each patient underwent a comprehensive transthoracic echocardiographic examination with two-dimensional, M-mode, Doppler echocardiography and tissue Doppler imaging. The measurement of echocardiographic parameters was performed on 3-5 consecutive cardiac cycles and the average was used for the analysis. Cardiac sonographers, cardiology fellows and cardiologists performed the echocardiographic examinations at Siriraj echocardiographic laboratory. The studies performed by sonographers and fellows were confirmed by attending staff (NR, DJ and MK) before the final diagnosis was made. The echocardiographic findings of each patient were then entered into the electronic echocardiographic database.

Patients who underwent comprehensive transthoracic echocardiographic study at Siriraj Hospital during January 2003 to May 2013 with

the diagnosis of CHD were identified from the echocardiographic database and enrolled in the study. Eligible patients were patients (age >13) with unrepaired CHD who had complete echocardiographic data. If the definite diagnosis of CHD remained uncertain after the comprehensive echocardiographic study, the patients were excluded from the study. Patients who underwent prior cardiac surgery or percutaneous intervention, those with uncomplicated bicuspid aortic valve, patent foramen ovale, mitral valve prolapse, isolated persistent left superior vena cava and congenital cardiomyopathies were excluded. In patients with multiple echocardiographic studies, the most recent echocardiographic study before surgical or percutaneous intervention was included in the study. The institutional review board of Siriraj Hospital approved the study protocol.

### ***Statistical analysis***

Clinical and echocardiographic data were presented using descriptive statistics, including means, standard deviation, median, minimum and maximum or frequencies and percentage. Statistical analyses were performed using SPSS statistical package version 18.0.

## **Results**

There were 27,132 adult patients underwent transthoracic echocardiography at Siriraj Hospital during January 2003 to May 2013. Among these, 1,082 (4.0%, 95% confidence interval = 3.76-4.23%) were diagnosed as CHD and constituted the population study. Table 1 and Fig. 1 showed the distribution of adult CHD at Siriraj Hospital during study period. The mean age of patients with CHD was  $36.7 \pm 14.7$  years (range 13-84 years) and 75.3% were female. Fig. 2 showed the age distribution of patients with CHD in the present study. More than two-thirds of patients present in the 3<sup>rd</sup>-5<sup>th</sup> decade of life. Only 2.6% were at the age of 70 or more. The oldest patient reported in this study was an 84-year-old female with ASD secundum, left-to-right shunt and pulmonary artery systolic pressure of 49 mmHg.

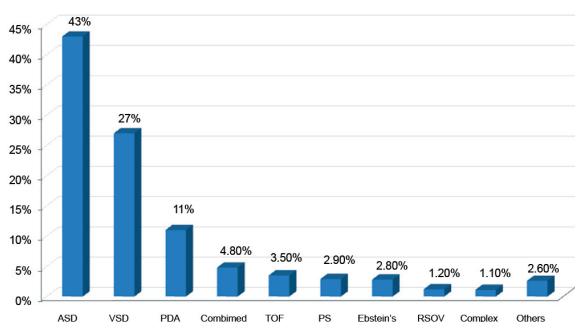
The most common types of CHD in adults were isolated left-to-right shunt lesions: ASD (43%), VSD (27%) and PDA (11%). These three simple shunt lesions represented the majority of adult patients with CHD (81%). Eisenmenger syndrome was reported in 77 (7.1%) patients with congenital simple shunt lesions. The mean age of patients with Eisenmenger syndrome was  $39.1 \pm 10.8$  years (range 16-69 years)

**Table 1.** Common congenital heart diseases in adult patients at Siriraj Hospital

Types of CHD	n (%)	Female:male	Age (years)
ASD	466 (43.0)	3.9:1	40.6±14.5
VSD	292 (27.0)	2.4:1	32.7±13.6
PDA	119 (11.0)	6.0:1	35.5±14.6
TOF	38 (3.5)	1.4:1	27.2±7.4
PS	32 (2.9)	2.6:1	32.4±14.8
Ebstein's anomaly	30 (2.8)	2.3:1	38.9±15.7

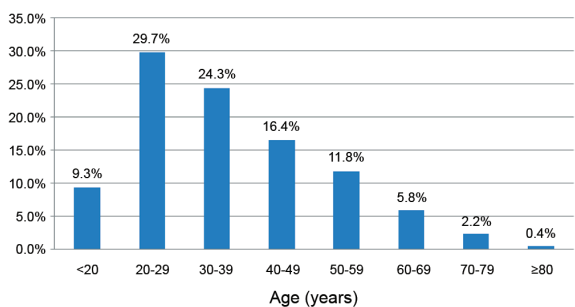
ASD = atrial septal defect; CHD = congenital heart disease; PDA = patent ductus arteriosus; PS = pulmonic stenosis; TOF = tetralogy of Fallot; VSD = ventricular septal defect  
Data are expressed as mean ± standard deviation and number (percentage)

and 71.4% were female. The mean pulmonary artery systolic pressure in patients with Eisenmenger syndrome was 94.8±30.0 mmHg. The oldest patient with Eisenmenger syndrome was a 69-year-old female



ASD = atrial septal defect; PDA = patent ductus arteriosus; PS = pulmonic stenosis; RSOV = rupture sinus of Valsalva; TOF = tetralogy of Fallot; VSD = ventricular septal defect

**Fig. 1** The distribution of adult congenital heart diseases at Siriraj Hospital during 2003-2013.



**Fig. 2** Age distribution of patients with congenital heart diseases at Siriraj Hospital during 2003-2013.

with large PDA and ASD secundum without the right-sided obstructive lesion. Her oxygen saturation and pulmonary artery systolic pressure were 77% and 111 mmHg, respectively. The most common obstructive lesion of the outflow tract was pulmonic stenosis (PS), which was found in 32 (3%) patients. Other isolated acyanotic lesions found in this study were ruptured sinus of Valsalva (13 patients, 1.2%), coronary arteriovenous fistula (6 patients, 0.6%), coarctation of aorta (6 patients, 0.6%), cor triatriatum (5 patients, 0.5%), parachute mitral valve (2 patients, 0.2%), subaortic membrane (2 patients, 0.2%) and Gerbode defect (1 patient, 0.1%).

Regarding cyanotic heart disease, Tetralogy of Fallot (TOF) was found to be the most common defect (3.5%) in this study. The mean age of patients with unrepaired TOF was 27.2±7.4 years (range 16-53) and 50.9% were male. Less common complex and/or cyanotic CHD were double outlet right ventricle (5 patients, 0.5%), double inlet left ventricle (3 patients, 0.3%), corrected transposition of great arteries (3 patients, 0.3%) and d-transposition of great arteries (1 patients, 0.1%). The combinations of shunt lesions (ASD, VSD, PDA) and/or right-sided obstructive lesion were VSD with PS (20 patients, 1.8%), VSD and PDA (12 patients, 1.1%), ASD and PDA (8 patients, 0.7%), ASD with PS (7 patients, 0.6%), ASD and VSD (5 patients, 0.5%). Complete atrioventricular canal defect was reported in five (0.5%) patients. Tricuspid stenosis/atresia was rare in adult patients and was found in combination with PS, ASD and PDA in one patient.

### Atrial septal defect

ASD was reported in 43% of patients and considered the most common adult CHD. It was more common in female than in male. The size of ASD was 2.3±0.8 cm (median 2.3, range 0.3-5.2). The largest diameter of isolated ASD measured by transthoracic echocardiography in this series was 5.2 cm associated with secundum type and bidirectional flow. The left ventricular ejection fraction and pulmonary artery systolic pressure were 65.5±12.3% and 55.8±24.8 mmHg, respectively. Table 2 shows the types and echocardiographic characteristics of ASD reported in this study. ASD secundum was the most common type of ASD. No coronary sinus type of ASD was reported in this study. Abnormalities of mitral valve were reported in 10.9% of patients. Among these, mitral valve prolapse was most common and the majority (94%) was associated with ASD secundum.

All patients with cleft mitral valve were associated with ASD primum. Luthembacher's syndrome, which is congenital ASD with rheumatic mitral stenosis, was reported in 12 (2.5%) patients with ASD.

#### **Ventricular septal defect**

VSD was the second most common form of adult CHD. The mean age at the diagnosis was 32.7±13.6 years (median 28.9, range 14-80). Adult patients with VSD presented at the younger age than those with ASD. Most VSD lesions in adult patients were small defects with the average size of 0.87±0.76 cm. The left ventricular ejection fraction and pulmonary artery systolic pressure were 65.4±9.5% and 46.9±26.6 mmHg, respectively. Table 3 showed the types and echocardiographic characteristics of VSD.

**Table 2.** Types and echocardiographic characteristics of atrial septal defect

	n (%)
ASD type	
ASD secundum	443 (92.9)
ASD primum	18 (3.9)
ASD sinus venosus	15 (3.2)
ASD shunt flow	
Left-to-right shunt	420 (90.1)
Balanced shunt	38 (8.2)
Right-to-left shunt	8 (1.7)
Mitral valve	
Prolapse	34 (7.3)
Rheumatic pattern	12 (2.6)
Cleft	5 (1.1)

ASD = atrial septal defect

Data are expressed as number (percentage)

**Table 3.** Types and echocardiographic characteristics of ventricular septal defect

	n (%)
VSD type	
Membranous	186 (63.7)
Subpulmonic	48 (16.4)
Subaortic	36 (12.3)
Subarterial	10 (3.4)
Muscular	9 (3.1)
VSD shunt flow	
Left-to-right shunt	263 (91.6)
Balanced shunt	18 (6.3)
Right-to-left shunt	2 (0.7)

VSD = ventricular septal defect

Data are expressed as number (percentage)

#### **Patent ductus arteriosus**

PDA was reported in 119 patients and the mean age was 35.5±14.6 years (median 32.1, range 15-77). Most patients with PDA (90.7%) demonstrated left-to-right shunt with the average size of 0.77±0.32 cm. The left ventricular ejection fraction and pulmonary artery systolic pressure were 64.3±8.8% and 47.5±28.4 mmHg, respectively.

#### **Discussion**

The present study reported the 10-year prevalence and type distribution of CHD in adult patients at Siriraj Hospital, Thailand. Echocardiography was used as the diagnostic tool and the prevalence of adult CHD in our population was 4.0%. In our adult population with unrepaired CHD, acyanotic lesions are much more common than cyanotic lesions. Simple shunt lesions such as ASD, VSD and PDA were the most prevalent CHD reported in this study, while TOF was reported to be the most common cyanotic CHD in adults.

#### **Comparison with previous studies from Siriraj Hospital**

There have been five studies, which reported the prevalence and type distribution of CHD in adult patients from Siriraj Hospital<sup>(6-9)</sup>, of which three studies were from the echocardiography laboratory (Table 4). The prevalence varies from 4.0% to 37.9%, depending on the study population and site of the study. The number of adult patients with CHD was more prevalent in the study conducted from cardiac catheterization laboratory or in those undergoing cardiac surgery. Among adult patients in the echocardiography laboratory, the prevalence of CHD varied from 4.0-7.3% and became less in the more recent reports. The decreasing prevalence of adult CHD in the recent report from our echocardiography laboratory may be explained by several reasons. There have been several progresses in our echocardiographic laboratory in the past decades and this contributes to an improvement in the productivity. In addition, the number of patients undergoing echocardiographic examination for any indications has progressively increased as compared to the number of patients with CHD. Furthermore, the magnitude of the problem of unrepaired CHD in adults may be difficult to determine since there are some different issues regarding the status of CHD (repaired or unrepaired). The prevalence of unrepaired congenital defects may become less, while that of repaired lesion may go higher. Many patients who underwent surgical correction for CHD since childhood are now grown-up

**Table 4.** Previous and present studies regarding congenital heart disease in adult patients at Siriraj Hospital

	Sahasakul et al. <sup>(6)</sup> (1983)	Pornvilawan et al. <sup>(7)</sup> (1997)	Sahasakul et al. <sup>(8)</sup> (1990)	Bunsiricomchai et al. <sup>(9)</sup> (2001)	Present study
Study period	1974-1981	1979-1995	1987-1990	1996-1999	2003-2013
Study duration (years)	8	17	3	4	10.4
Diagnostic tool	Catherterization	Surgery	Echocardiography	Echocardiography	Echocardiography
Age (years)	>12	24.1 (13-72)	>12	30.4 (12-82)	36.7 (13-84)
Number of patients	635	1,408	439	693	1,082
Prevalence (%)	37.9	18.2	7.3	6.2	4
Female:male	1.7:1	2:1	NA	1.9:1	3:1
Distribution	ASD (35.3%) VSD (20.0%) TOF (12.1%) PS (10.6%) PDA (7.6%)	ASD (41.1%) PDA (16.2%) TOF (14.1%) VSD (10.9%) PS (5.4%)	ASD (44.6%) VSD (21.2%) PDA (10.3%) PS (8.2%) TOF (4.1%)	ASD (40.8%) VSD (20.9%) PDA (10.4%) TOF (6.4%) PS (3.2%)	ASD (43.0%) VSD (27.0%) PDA (11.0%) TOF (3.5%) PS (2.9%)

ASD = atrial septal defect; NA = not available; PDA = patent ductus arteriosus; PS = pulmonic stenosis; TOF = tetralogy of Fallot; VSD = ventricular septal defect

and present to adult echocardiography laboratory in an increasing number<sup>(10)</sup>. In addition, recent advances in percutaneous therapeutic interventions for CHD leads more patients undergo these procedures to correct congenital defects. In the present study, we reported only patients with unrepaired CHD who presented to the echocardiography laboratory.

All these studies consistently showed female preponderance with female-to-male ratio ranged from 1.7:1 to 3:1. In contrast, previous studies from Europe reported no gender difference among adult patients with CHD<sup>(11,12)</sup>. The findings on gender difference are inconsistent among studies possibly due to different geographical areas and study populations. The top five types of CHD in adult patients were ASD, VSD, PDA, TOF and PS, consistently across all studies from our institution. In concordance with other reports in the literature, ASD was the most common CHD reported in adult patients<sup>(1,3)</sup>. The prevalence of ASD in our series was 43%, accounting for almost a half of all patients with CHD. This defect is benign with insignificant clinical findings during childhood and patients are usually asymptomatic which may obviate medical attention. Therefore, most patients with ASD survive into adulthood without any recognition or intervention of CHD and this leads to the highest prevalence of ASD in adult population. VSD is the second most common form of adult CHD and the majority had only a small defect. Regardless of the type and size of VSD, it is the most common CHD found in children. The loud murmur of small VSD is easily recognized by the physical examination and the

clinical findings of heart failure and/or pulmonary hypertension is predominant in patients with moderate-to-large VSD. These lead to early recognition of VSD since childhood and leaves small defects most prevalent in adults. Similar to other complex cyanotic CHD, unrepaired TOF in adults is uncommon. However, it is reliably considered the most common cyanotic CHD in adults with the prevalence of 3.5% in our series. Most patients with TOF are diagnosed and underwent surgical correction during childhood since the clinical signs and symptoms are obvious<sup>(10,13)</sup>. At our institution, most adult patients with TOF underwent total correction and were excluded from the study. Therefore, the prevalence of all TOF patients is not reported.

### Conclusion

During a 10-year period, the prevalence of adult CHD diagnosed by echocardiography at Siriraj Hospital was 4.0%. ASD was the most common CHD and TOF was the most common cyanotic CHD. ASD, VSD and PDA represent more than 80% of adult patients with CHD. Female predominance was reported in all common forms of CHD. Echocardiography is fundamental for the diagnosis and management of patients with CHD.

### Study limitation

Patients with some forms of CHD were not included in the present study for different reasons. Most of previously published articles regarding adult CHD excluded uncomplicated bicuspid aortic valve, mitral valve prolapse and congenital cardiomyopathies from

the studies, probably due to the extremely difference in prevalence and clinical significance. Transesophageal echocardiography is the essential tool for the diagnosis of most cases of patent foramen ovale, ASD coronary sinus type and isolated persistent left superior vena cava. Since the diagnosis of CHD in the majority of patients is established and confirmed primarily by transthoracic echocardiography and only the small number of patients undergoes transesophageal echocardiography, transesophageal echocardiographic findings are not available in the present study. Some forms of congenital abnormalities of the great vessels or coronary artery (such as coarctation of aorta, peripheral or branch pulmonary artery stenosis, coronary anomalies) and genetic syndromes (such as Marfan syndrome, congenital cardiomyopathies) may need other cardiac imaging tools and further specific investigations for the definite diagnosis. Therefore, such abnormalities were excluded from the study. Furthermore, the prevalence of some rare forms of CHD may be under-estimated since the present study depends largely only on transthoracic echocardiography for the diagnosis of CHD.

#### **What is already known on this topic?**

It has already been known from several previous reports on adult CHD that simple left-to-right shunt lesions, such as ASD, VSD and PDA, are the most prevalent congenital defects. Also, TOF is the most common form of cyanotic heart disease in adults. Accordingly, the present study reported the similar findings.

#### **What this study adds?**

Despite recent advances in cardiac imaging techniques and early detection of adult CHD, data regarding the prevalence and characteristic of common CHD in Thai adults in the past decade are limited. The present study shows the overall prevalence of adult CHD and also, the prevalence of specific defects. The characteristics of some common CHD are described in detail. These documents can be used as the reference in Thai population.

#### **Potential conflicts of interest**

None.

#### **References**

1. Warnes CA, Liberthson R, Danielson GK, Dore A, Harris L, Hoffman JI, et al. Task force 1: the changing profile of congenital heart disease in

- adult life. *J Am Coll Cardiol* 2001; 37: 1170-5.
2. Hoffman JI, Kaplan S. The incidence of congenital heart disease. *J Am Coll Cardiol* 2002; 39: 1890-900.
3. Marelli AJ, Mackie AS, Ionescu-Ittu R, Rahme E, Pilote L. Congenital heart disease in the general population: changing prevalence and age distribution. *Circulation* 2007; 115: 163-72.
4. Webb GD, Williams RG. Care of the adult with congenital heart disease: introduction. *J Am Coll Cardiol* 2001; 37: 1166.
5. Perloff JK. Congenital heart disease after childhood: an expanding patient population. 22<sup>nd</sup> Bethesda Conference, Maryland, October 18-19, 1990. *J Am Coll Cardiol* 1991; 18: 311-42.
6. Sahasakul Y, Chaithiraphan S, Thongtang V, Jootar P, Charoenchob N, Srivanasont N, et al. Congenital heart disease in the selected catheterized adolescents and adults at Siriraj Hospital. *J Med Assoc Thai* 1983; 66: 668-73.
7. Pornvilawan S, Sriyoschart S, Phanchaipheth T, Laksanabunsong P, Thongcharoeng P, Gherunpongsa C, et al. Surgical treatment for adult congenital heart disease. *Siriraj Hosp Gaz* 1997; 49: 21-31.
8. Sahasakul Y, Chaithiraphan S, Panchavinnin P, Charoenchob N, Jootar P, Thongtang V, et al. Role of echocardiography for diagnosis of congenital heart disease in adolescents and adults: 3 years experience in Siriraj hospital. *Thai Heart J* 1990; 3: 41-9.
9. Bunsiricomchai P, Jakrapanichakul D. Congenital heart disease in adolescents and adults at Siriraj hospital: an echocardiographic study. *Thai Heart J* 2001; 14: 97-107.
10. Baumgartner H, Bonhoeffer P, De Groot NM, de Haan F, Deanfield JE, Galie N, et al. ESC Guidelines for the management of grown-up congenital heart disease (new version 2010). *Eur Heart J* 2010; 31: 2915-57.
11. Engelfriet P, Mulder BJ. Gender differences in adult congenital heart disease. *Neth Heart J* 2009; 17: 414-7.
12. Verheugt CL, Uiterwaal CS, van der Velde ET, Meijboom FJ, Pieper PG, Vliegen HW, et al. Gender and outcome in adult congenital heart disease. *Circulation* 2008; 118: 26-32.
13. Deanfield J, Thaulow E, Warnes C, Webb G, Kolbel F, Hoffman A, et al. Management of grown up congenital heart disease. *Eur Heart J* 2003; 24: 1035-84.

---

**ความชุกและลักษณะสำคัญจากการตรวจคลื่นเสียงสะท้อนหัวใจในโรคหัวใจแต่กำเนิดในผู้ใหญ่ในโรงพยาบาลศิริราช: การศึกษา 10 ปีย้อนหลัง**

นิธิตา รัตนสิทธิ์, เขมจิรา การเกิดกลาง, เดโช จักรพานิชกุล, เมทินี กิตติไพวานนท์, เกษรี ปันลี, วันดี โรจนะสิริ, สุธีรา พงษ์ไพศาล

**ภูมิหลัง:** โรคหัวใจแต่กำเนิดในผู้ใหญ่เป็นโรคที่พบได้บ่อยมากขึ้นและเป็นปัญหาที่สำคัญอย่างหนึ่งในโรคหัวใจและหลอดเลือด ในช่วง 10 ปีที่ผ่านมา ยังไม่มีการรายงานข้อมูลเกี่ยวกับความชุกและลักษณะสำคัญต่างๆ ของโรคหัวใจแต่กำเนิดในผู้ป่วยที่เป็นผู้ใหญ่ในคนไทย ในโรงพยาบาลศิริราช

**วัตถุประสงค์และวิธีการ:** การศึกษานี้ได้ทำการสืบค้นข้อมูลจากฐานข้อมูลการตรวจคลื่นเสียงสะท้อนหัวใจในผู้ป่วยผู้ใหญ่ ในโรงพยาบาลศิริราช ตั้งแต่เดือนมกราคม พ.ศ. 2546 ถึง พฤษภาคม พ.ศ. 2556 โดยได้คัดเลือกผู้ป่วยที่ได้รับการวินิจฉัยเป็นโรคหัวใจแต่กำเนิดที่ยังไม่เคยได้รับการผ่าตัดแก้ไข และมีข้อมูลการตรวจคลื่นเสียงสะท้อนหัวใจครบถ้วน

**ผลการศึกษา:** ผู้ป่วยที่ได้รับการตรวจคลื่นเสียงสะท้อนหัวใจในช่วงเวลาดังกล่าว จำนวน 27,132 ราย เป็นผู้ป่วยโรคหัวใจแต่กำเนิด จำนวน 1,082 ราย คิดเป็นความชุกร้อยละ 4.0 (ช่วงความเชื่อมั่นร้อยละ 95 3.76 ถึง 4.23) อายุเฉลี่ย  $36.7 \pm 14.7$  ปี เพศหญิง ร้อยละ 75.3 ผู้ป่วยส่วนใหญ่มีรูรั่วที่ผนังกันห้องหัวใจหรือระหว่างหลอดเลือดใหญ่ โดยพบภาวะผนังกันห้องหัวใจรั่วที่ตำแหน่งเออเทรียมและเวนทริเคิล ร้อยละ 43 และ 27 ตามลำดับ ในผู้ป่วยที่มีภาวะผนังกันห้องหัวใจรั่วหรือมีท่อต่อระหว่างหลอดเลือดใหญ่ พบว่ามีกรไหลของเลือดย้อนทางจากขวาไปซ้าย จำนวน 77 ราย มีผู้ป่วยโรคลิ้นหัวใจพูลโมนารีตีบและโรคลิ้นหัวใจไตรคัสปิดเกาะต่ำ ร้อยละ 2.9 และ 2.8 ตามลำดับ

**สรุป:** ความชุกโรคหัวใจแต่กำเนิดในผู้ใหญ่ในโรงพยาบาลศิริราช พบได้ร้อยละ 4.0 ผู้ป่วยส่วนใหญ่มีรูรั่วที่ผนังกันห้องหัวใจหรือระหว่างหลอดเลือดใหญ่ ชนิดที่พบบ่อยที่สุดคือ ภาวะผนังกันห้องหัวใจห้องบนรั่ว

---