

## Case Report

# Rare Manifestations of *Streptococcus pneumoniae* Infection; The First Case Report in Thailand and Literature Review of Pneumococcal Endophthalmitis and Endocarditis

Peerapat Thaisiam MD\*,  
Pinyo Rattanaumpawan MD, MSCE, PhD\*

\* Division of Infectious Diseases and Tropical Medicine, Department of Medicine, Faculty of Medicine Siriraj Hospital, Mahidol University, Bangkok, Thailand

---

We report a case of endogenous endophthalmitis and endocarditis caused by a rare causative organism: *Streptococcus pneumoniae*. A 69-year-old woman with diabetes mellitus and pre-existing mitral regurgitation presented with acute fever and severe left eye pain. Ophthalmologic examination revealed bilateral endophthalmitis. Blood and vitreous fluid culture grew penicillin-susceptible *S. pneumoniae*. Transesophageal echocardiogram documented a 5-mm oscillating mass at right coronary cusp of aortic valve. After 4 weeks of combined ceftriaxone and levofloxacin therapy, the patient improved and was later discharged with blindness in her left eye.

**Keywords:** *Streptococcus pneumoniae*, Endogenous endophthalmitis, Endocarditis

*J Med Assoc Thai* 2014; 97 (12): 1364-9

Full text. e-Journal: <http://www.jmatonline.com>

---

Endophthalmitis is an inflammatory condition of intraocular cavity including the aqueous and/or vitreous humor. This condition can be further categorized into two groups based on its pathogenesis: endogenous (metastatic) endophthalmitis and exogenous endophthalmitis. Exogenous endophthalmitis results from direct inoculation of an organism from the outside while endogenous endophthalmitis results from hematogenous spreading of organisms from a distant source of infection.

Endogenous endophthalmitis comprises only 2-15% of all endophthalmitis<sup>(1)</sup>. This condition can affect any age group but has its peak in the first year of life and during middle age<sup>(2,3)</sup>. Although the endogenous endophthalmitis can be caused by a broad range of organisms including bacteria, fungi, and actinomyces, majority of cases are attributable to bacterial and fungal infections<sup>(4,5)</sup>. Common causative organisms of endogenous endophthalmitis are varied by patient's underlying diseases and demographics. A previous study conducted in East Asia reported

that the leading cause of endogenous endophthalmitis are *Klebsiella* spp. (77%), followed by *Escherichia coli* (5%) and *Staphylococcus aureus* (4%)<sup>(5,6)</sup>. Approximately 40% of cases had no obvious primary source of infection<sup>(4)</sup>.

*Streptococcus pneumoniae* is a lancet-shaped gram-positive diplococci organism, which is considered the major cause of infections of the middle ear, sinuses and lower respiratory tract. Infections occur by direct spreading of colonized organisms from the nasopharynx to upper and lower respiratory tracts. Infections of distant sites including central nervous system, heart valves, bones, and joints may occur after hematogenous spreading<sup>(7)</sup>. Endogenous endophthalmitis is considered an extremely rare complication of *S. pneumoniae* hematogenous spreading. The authors describe here a rare case of endogenous endophthalmitis and endocarditis caused by *S. pneumoniae*.

### Case Report

A 69-year-old Thai woman presented with one-day history of a high-grade fever, blurred vision and severe pain in her left eye. Her past medical history included diabetes mellitus and valvular heart disease (mitral regurgitation, aortic stenosis and aortic regurgitation). She also had a history of recurrent right otitis media with perforated tympanic membrane

---

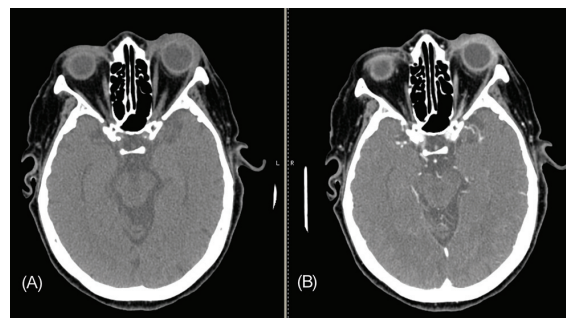
#### Correspondence to:

Rattanaumpawan P, Division of Infectious Diseases and Tropical Medicine, Department of Medicine, Faculty of Medicine Siriraj Hospital, Mahidol University, Bangkok 10700, Thailand.  
Phone: 0-2419-7784, Fax: 0-2419-7783  
E-mail: [pinyo.rat@mahidol.ac.th](mailto:pinyo.rat@mahidol.ac.th)

which required multiple courses of antibiotic therapy. She had otherwise been well until 3 days prior to the admission, when she developed low-grade fever, myalgia and anorexia. One day prior to the admission, her left eye became red and swollen. She also complained of blurring of vision and painful movement of her left eye. She denied a history of alcohol drinking, smoking, illicit drug use or any injuries to her left eye. She worked as a housekeeper and had resided in Nontaburi province over the past 10 years.

Physical examination was notable for low grade fever (body temperature 37.5°C), a grade-3 systolic ejection murmur at LUPSB and a grade-3 pansystolic murmur at apex radiated to the left axilla. Right tympanic membrane perforation without any sign of inflammation was noted on otoscopic examination. Results of ophthalmic examination are shown in Table 1. She was fully conscious and there was no evidence of embolic or vascular phenomenon.

Complete blood count showed hematocrit 38.4%, white blood cell 14,600 cells/mm<sup>3</sup> (with 90% of neutrophils) and platelet 93,000 cell/mm<sup>3</sup>. Blood chemistry showed BUN 28.4 mg/dl, Cr 1.34 mg/dl, Sodium 133 mmol/L, Potassium 2.6 mmol/L, Chloride 92 mmol/L, and Bicarbonate 27 mmol/L. Her liver function test was unremarkable. Her urine examination revealed marked proteinuria (3+) with 1-2 red cells and 50-100 white cells per low power field. Her chest radiograph and electrocardiogram were normal. Computed tomography (CT-scan) of head was performed to determine disease extension, The head CT-scan revealed soft tissue thickening with enhancement at bilateral periorbital regions, soft tissue enhancement at left optic nerve and posterior aspect of ocular area, poor pneumatization with fluid filling both middle ears and mastoid air cells indicating left



**Fig. 1** CT scan of head shows soft tissue thickening with enhancement at bilateral periorbital regions, episclera more severe in left side. (A) non-contrast, (B) contrast.

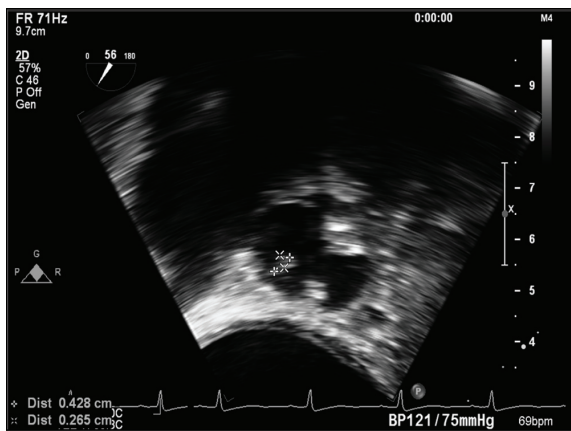
panophthalmitis, right endophthalmitis and bilateral chronic otomastoiditis (Fig. 1).

The diagnosis of bilateral endogenous endophthalmitis was made and bilateral vitreous tapping was performed. Gram stain of vitreous fluid from both eyes revealed numerous polymorphonuclear cells and gram-positive cocci in pair. The vitreous fluid culture later grew *S. pneumoniae* with a cefotaxime MIC of 0.012 mcg/ml and a penicillin MIC of 0.012 mcg/ml. *S. pneumoniae* with the same susceptibility patterns was also identified in two bottles of blood culture.

Because of her underlying valvular heart disease and evidence of Roth's spot in her right eye, transesophageal echocardiogram (TEE) was subsequently performed on Day 2 of admission. The TEE detected a 0.5-cm oscillating mass at right aortic cusp of aortic valve without evidence of perivalvular abscess (Fig. 2). Therefore, the patient's final diagnosis included pneumococcal bilateral endophthalmitis and endocarditis of aortic valve. She was treated

**Table 1.** Ophthalmologic findings upon admission

Parameters	Right eye	Left eye
Visual acuity	20/40	Perception of light
Intraocular pressure (mmHg)	14	17
Conjunctiva	Not injected	Mixed injected with chemosis
Cornea	Clear	Haze, stromal edema
Anterior chamber	Shallow	Shallow
Iris	No atrophy	No atrophy
Pupil	3 mm, reactive to light	3 mm, not reactive to light, relative afferent pupillary defect (RAPD)
Fundus	Disc swelling, perivascular infiltration, Roth's spots	Obscured



**Fig. 2** Transesophageal echocardiogram shows oscillating mass size 0.5 cm in diameter at aortic valve.

with intravenous antibiotics including ceftriaxone (4 grams/day) and levofloxacin (750 mg/day). Signs of intraocular inflammation progressed during the first few days of therapy but gradually improved after that. Due to a stable cardiac condition, she did not require any emergency valve replacement surgery. After a 4-week combination antibiotic therapy, she was later discharged from hospital with complete blindness in the left eye and light perception in the right eye.

## Discussion

Generally, common causative organisms of endogenous endophthalmitis are gram-negative bacteria including *Klebsiella* spp., followed by *E. coli* and *S. aureus*<sup>(5,6)</sup>. A Spanish study revealed that only 5.5% of endophthalmitis cases and 1.4% of endocarditis cases were caused by *S. pneumoniae*. Septic emboli to the eyes occurred about 8% in this setting such as retinal spots, conjunctival petechiae, and panophthalmitis<sup>(8,9)</sup>. However, cases with concurrent endogenous endophthalmitis and infective endocarditis were commonly caused by other causative organisms, including Viridans group streptococci, *Streptococcus equisimilis*, *Actinobacillus actinomycetemcomitans*<sup>(10-12)</sup>. In this paper, the authors narrated a case of endogenous endophthalmitis and infective endocarditis caused by an extremely rare causative organism: *Streptococcus pneumoniae*.

To our knowledge, there were only three reported cases of concurrent endophthalmitis and endocarditis caused by *S. pneumoniae*. Details of these patients are shown in Table 2. Case-1 was a 43-year white male with diabetes mellitus who presented with prolonged fever and painful brown spot in his left eye

for 2 days. His echocardiogram showed vegetation at aortic valve, aortic root abscess, and severe aortic regurgitation. Aortic valve replacement surgery was immediately performed. His blood culture and valve culture later grew *S. pneumoniae*<sup>(13)</sup>. He was treated with intravitreal ceftazidime plus vancomycin as well as systemic antibiotics including ceftriaxone, gentamicin and vancomycin. Unfortunately, the patient was later expired due to septic emboli to multiple organs.

Case-2 was a 55-year white male without any underlying disease. He presented with acute fever for 3 days and rapid deterioration of visual acuity bilaterally within 1 day. Physical examination revealed systolic murmur at the mitral valve area. Hemoculture and vitreous culture grew *S. pneumoniae*<sup>(14)</sup>. He received intravitreal ceftazidime plus vancomycin and intravenous PGS and gentamicin. He also underwent mitral valve replacement surgery at 5 weeks after admission. He was discharged home with some visual acuity deficit in both eyes.

Case-3 was a 50-year female without any underlying disease. She had a history of low-grade fever for 3 weeks. One day prior to admission, she complained that her right eye became red and swollen and had blurred vision. Severe mitral valve regurgitation with a vegetation was later documented. Her chest X-ray revealed left upper lung patchy infiltration. An isolate of *S. pneumoniae* was identified from her vitreous fluid and blood specimens<sup>(15)</sup>. She was treated with parenteral antibiotic therapy (unknown regimen) and underwent mitral valve replacement surgery. Unfortunately, she developed septic shock and later expired.

Majority of patients with *S. pneumoniae* bacteremia do not have obvious source of primary infection. Among those with identified primary source of infection, the most common source was pneumonia (21%), followed by middle ear infection (12%)<sup>(9)</sup>. Although our case did not have active ear infection, we believed that recurrent otitis media and chronic otomastoiditis were possible sources of persistent *S. pneumoniae* bacteremia, which subsequently caused endogenous endophthalmitis and endocarditis.

Based on the American Heart Association/ Infectious Diseases Society of America (AHA/IDSA) recommendation for treatment of infective endocarditis, the patients with endocarditis caused by highly penicillin-susceptible *S. pneumoniae* (penicillin MIC <0.1 mcg/ml) should receive 4 weeks of intravenous penicillin, cefazolin, or ceftriaxone monotherapy.

**Table 2.** Characteristics of all case reports

	Case 1	Case 2	Case 3
Age in years, sex	43, male	55, male	50, female
Underlying disease	DM type 2	None	None
Presentation	- 6 weeks: fever, sweat, myalgia, right-sided pleuritis chest pain - 2 days: brown spot, mild pain in left eye	- 3 days: fever, headache, malaise - 1 day: reduced bilateral visual acuity	- 3 weeks: fever, cough - 1 day: red eye, loss of vision in right eye
Physical examination	- Temp 39.7°C - Left eye: injected and endophthalmitis - Heart murmur - Crepitation left lung - Leg edema	- Periorbital edema, conjunctival injection, chemosis in both eyes - Eye motility was restricted - Heart murmur	- Temp 38°C - Conjunctival injection in right eye, bilateral endophthalmitis - Heart murmur - Crepitation left lung - Splinter hemorrhage - Janeway lesions - Leg edema
Investigation	- Chest X-ray: right lower lung infiltration with right pleural effusion - Transesophageal echo.: vegetation at aortic valve, aortic root abscess, moderate to severe aortic regurgitation - H/C: <i>S. pneumoniae</i> - Valve tissue gram stain: gram positive diplococci	- Ultrasound eye: dense opacities and membranes in vitreous both eyes - H/C: <i>S. pneumoniae</i> - Vitreous fluid gram stain: gram positive diplococci	- Chest X-ray: consolidation at left upper lung - Transthoracic echo.: vegetation at mitral valve with severe mitral regurgitation - H/C: no growth - Vitreous fluid and urine culture: <i>S. pneumoniae</i>
Diagnosis	Pneumococcal pneumonia, endocarditis and endophthalmitis	Pneumococcal endocarditis and bilateral panophthalmitis	Pneumococcal pneumonia with endocarditis and endophthalmitis
Treatment	- IT drugs including ceftazidime and vancomycin - Systemic antibiotic including ceftriaxone, gentamicin and vancomycin - Aortic valve replacement surgery	- IT drugs including ceftazidime, vancomycin and dexamethasone - Systemic antibiotic including PGS and gentamicin - Mitral valve replacement surgery	- Unknown systemic antibiotic(s) - Mitral valve replacement surgery
Outcome	Death from multiple septic emboli e.g. brain, intestine	Discharged with impaired vision	Death from septic shock

DM = diabetes mellitus; echo. = echocardiogram; H/C = hemoculture; IT drugs = intravitreal drugs

Vancomycin should be administered only in patients who are unable to tolerate beta-lactam therapy<sup>(16)</sup>. Given that our case was infected with penicillin and fluoroquinolone-susceptible *S. pneumoniae*, the authors prescribed ceftriaxone 2 gram IV every 12-hour plus levofloxacin 750 mg once daily. The parenteral levofloxacin was added in aiming to achieve a higher antibiotic concentration in vitreous fluid. The total duration of systemic antibiotic was 4 weeks. Intravitreal therapy with ceftazidime and

vancomycin were also administered during the first 2 weeks of hospitalization.

### Conclusion

The authors reported a case of endogenous endophthalmitis and endocarditis caused by *S. pneumoniae* - an extremely rare entity of *S. pneumoniae* infection. Based on data from a literature review, 2 out of 3 (67%) died despite aggressive medical and surgical interventions. Without

any surgical intervention, our patient was successfully treated with combination of intravitreal and parenteral antibiotics. Combined antibiotic therapy with good tissue penetration antibiotics may be necessary for better outcomes.

#### What is already known on this topic?

*Streptococcus pneumoniae* was considered as the major organism in sinopulmonary and central nervous system infection. Concurrent endocarditis and endogenous endophthalmitis caused by *S. pneumoniae* is an extremely rare condition with a very high case-fatality.

#### What this study adds?

Combined antibiotic therapy with good tissue penetration antibiotics may be necessary for better outcomes in cases with concurrent endocarditis and endogenous endophthalmitis caused by *S. pneumoniae*

#### Potential conflicts of interest

None.

#### References

1. Okada AA, Johnson RP, Liles WC, D'Amico DJ, Baker AS. Endogenous bacterial endophthalmitis. Report of a ten-year retrospective study. *Ophthalmology* 1994; 101: 832-8.
2. Puliafito CA, Baker AS, Haaf J, Foster CS. Infectious endophthalmitis. Review of 36 cases. *Ophthalmology* 1982; 89: 921-9.
3. Liang L, Lin X, Yu A, Lin A, Yuan Z. The clinical analysis of endogenous endophthalmitis. *Yan Ke Xue Bao* 2004; 20: 144-8.
4. Binder MI, Chua J, Kaiser PK, Procop GW, Isada CM. Endogenous endophthalmitis: an 18-year review of culture-positive cases at a tertiary care center. *Medicine (Baltimore)* 2003; 82: 97-105.
5. Jackson TL, Eykyn SJ, Graham EM, Stanford MR. Endogenous bacterial endophthalmitis: a 17-year prospective series and review of 267 reported cases. *Surv Ophthalmol* 2003; 48: 403-23.
6. Smith SR, Kroll AJ, Lou PL, Ryan EA. Endogenous bacterial and fungal endophthalmitis. *Int Ophthalmol Clin* 2007; 47: 173-83.
7. Musher DM. *Streptococcus pneumoniae*. In: Mandell GL, Bennett JE, Dolin R, editors. Principles and practice of infectious diseases. 7<sup>th</sup> ed. Philadelphia: Churchill Livingstone; 2010: 2623-42.
8. Soriano F, Perez-Trallero E, Pallares R, Meseguer MA, Fleites A, Gene A, et al. *Streptococcus pneumoniae* endophthalmitis: a study of 36 cases with special reference to antibiotic resistance and treatment options. *Clin Microbiol Infect* 2006; 12: 519-26.
9. Martínez E, Miró JM, Almirante B, Aguado JM, Fernandez-Viladrich P, Fernandez-Guerrero ML, et al. Effect of penicillin resistance of *Streptococcus pneumoniae* on the presentation, prognosis, and treatment of pneumococcal endocarditis in adults. *Clin Infect Dis* 2002; 35: 130-9.
10. Shah AN, Shah BN, Glover S, Herbert L. Bilateral foveal cysts secondary to *Streptococcus constellatus* endocarditis. *Int Ophthalmol* 2013; 33: 315-7.
11. Suemori S, Sawada A, Komori S, Mochizuki K, Ohkusu K, Takemura H. Case of endogenous endophthalmitis caused by *Streptococcus equisimilis*. *Clin Ophthalmol* 2010; 4: 917-8.
12. Lass JH, Varley MP, Frank KE, Speck WT. *Actinobacillus actinomycetemcomitans* endophthalmitis with subacute endocarditis. *Ann Ophthalmol* 1984; 16: 54-61.
13. Rubin RH, King ME, Mark EJ. Case record of the Massachusetts General Hospital. Weekly clinicopathological exercises. Case 7-2003. A 43-year-old man with fever, rapid loss of vision in the left eye, and cardiac findings. *N Engl J Med* 2003; 348: 834-43.
14. Christensen SR, Hansen AB, La Cour M, Fledelius HC. Bilateral endogenous bacterial endophthalmitis: a report of four cases. *Acta Ophthalmol Scand* 2004; 82: 306-10.
15. Ortiz P, Monivas V, Fuentes R, Toquero J. Endophthalmitis, pneumonia, and a heart murmur. *Heart* 2005; 91: 532.
16. Baddour LM, Wilson WR, Bayer AS, Fowler VG Jr, Bolger AF, Levison ME, et al. Infective endocarditis: diagnosis, antimicrobial therapy, and management of complications: a statement for healthcare professionals from the Committee on Rheumatic Fever, Endocarditis, and Kawasaki Disease, Council on Cardiovascular Disease in the Young, and the Councils on Clinical Cardiology, Stroke, and Cardiovascular Surgery and Anesthesia, American Heart Association: endorsed by the Infectious Diseases Society of America. *Circulation* 2005; 111: e394-434.



---

ลิ้นหัวใจอักเสบร่วมกับการติดเชื้อในนัยน์ตาจาก *Streptococcus pneumoniae*; รายงานผู้ป่วยรายแรกในประเทศไทย และการทบทวนวรรณกรรม

พีระพัชร ไทยสยาม, ภิญโญ รัตนอัมพวัลย์

ผู้ป่วยหญิงอายุ 69 ปี มีโรคประจำตัวเบาหวานและลิ้นหัวใจไมตรีร่วมมาด้วยอาการไข้และปวดตาข้างซ้าย ตรวจพบมีการติดเชื้อในนัยน์ตาทั้งสองข้าง ผลเพาะเชื้อจากเลือดและนัยน์ตาเป็นเชื้อ *Streptococcus pneumoniae* ผลการตรวจหัวใจด้วยคลื่นเสียงสะท้อนความถี่สูงพบมี oscillating mass ขนาด 5 มิลลิเมตร ที่ลิ้นหัวใจเอออดิก ผู้ป่วยได้รับการรักษาโดยยา ceftriaxone และ levofloxacin ชนิดฉีดเป็นเวลา 4 สัปดาห์ อาการผู้ป่วยดีขึ้นและสามารถกลับบ้านโดยตาซ้ายสูญเสียการมองเห็น

---