

Case Report

Successful Continuous Venovenous Hemofiltration in a Neonate with Hyperammonemia from Ornithine Transcarbamylase Deficiency

Kwanchai Pirojsakul MD*, Kanchana Tangnararatchakit MD*,
Jarin Vaewpanich MD**, Kanyapat Niyomvit RN****, Duangjai Chanhom RN****,
Rungnapa Udomchaisakul RN****, Wiwat Tapaneya-Olarn MD*, Duangrudee Wattanasirichaigoon MD***

* Division of Nephrology, Department of Pediatrics, Faculty of Medicine, Ramathibodi Hospital, Mahidol University, Bangkok, Thailand

** Division of Pediatric Critical Care, Department of Pediatrics, Faculty of Medicine, Ramathibodi Hospital, Mahidol University, Bangkok, Thailand

*** Division of Medical Genetics, Department of Pediatrics, Faculty of Medicine, Ramathibodi Hospital, Mahidol University, Bangkok, Thailand

**** Department of Nursing, Faculty of Medicine, Ramathibodi Hospital, Mahidol University, Bangkok, Thailand

Ornithine transcarbamylase (OTC) deficiency is the most common and severe form of abnormal urea synthesis. It can result in hyperammonemia, severe neurologic manifestation, brain edema, and early death. Rapid removal of ammonia by hemodialysis can decrease mortality and morbidity in the patients with severe increase of ammonia levels. However, hemodialysis (HD) in infants and young children are technically difficult to perform. Continuous venovenous hemofiltration (CVVH) is increasingly used as an alternative for HD, but performing CVVH in a neonate can be problematic due to small body size and difficult vascular access. The authors reported a successful CVVH using umbilical vein as a vascular access site for ammonia removal in a neonate with OTC deficiency with progressive elevation of plasma ammonia. Technical problems, pitfalls in performing the CVVH, and how the authors overcame the problems are discussed.

Keywords: Hemodialysis, Hemofiltration, Hyperammonemia, Neonate, Urea cycle disorder

J Med Assoc Thai 2013; 96 (11): 1512-7

Full text. e-Journal: <http://jmat.mat.or.th>

Ornithine transcarbamylase (OTC) deficiency is the most common enzymatic defect of the urea cycle^(1,2). It leads to an increase of plasma ammonia, vomiting, alteration of consciousness, brain edema, and early death. The disease is an X-linked disorder caused by mutation of the OTC gene, which is located on Xp21.1. In affected males, the onset of symptoms usually occurs early in neonatal period and most of them could not survive beyond their infancy or have severe neurologic damage as a consequence of prolonged hyperammonemia and brain edema. The minority of the affected males presents later in life and generally has a better outcome. Twenty percent of heterozygous females are symptomatic at a later onset and with less severe manifestation; however severe neurological damage and death can occur.

Treatments for urea cycle disorders include protein restriction, pharmacologic therapy, and toxin removal with various types of dialysis therapy. Rapid removal of ammonia by hemodialysis decreases mortality⁽³⁾. However, the use of hemodialysis (HD) in infants is often limited due to the small body size and vascular diameter. In some centers, continuous venovenous hemofiltration (CVVH) was performed in these patients to remove ammonia effectively⁽⁴⁾. The authors reported the first case, in Thailand, of successful CVVH in a hyperammonemic neonate with ornithine transcarbamylase (OTC) deficiency.

Case Report

The patient is the second child of an unrelated healthy Thai couple. The first child was female who died at three years of age with acute behavioral changes, altered consciousness, and severe brain edema. There is a history of multiple deaths of male neonates in the maternal family. The diagnosis of OTC deficiency in the present family was confirmed after the death of the patient's sister. A missense mutation

Correspondence to:

Pirojsakul K, Division of Nephrology, Department of Pediatrics, Ramathibodi Hospital, Mahidol University 270 Rama VI Road, Ratchathewi, Bangkok 10400, Thailand.
Phone: 0-2201-1497, Fax: 0-2201-1850
E-mail: kwanchai.pio@mahidol.ac.th

(p.S81P) of exon 3 of the OTC gene was identified in DNA of the deceased sister, the asymptomatic mother, and maternal grandmother. Prenatal diagnosis was offered to the couple for the second pregnancy, which antenatal ultrasonographic study revealed a male fetus. However, the intrauterine diagnosis was declined.

The patient was born at the 38 week of gestation, with birth weight 3,920 grams, length 53 cm, head circumference 36 cm, APGAR scores of 8 and 10 at 1 and 5 minutes, respectively. He was transferred to sick newborn care for close observation. While genetic testing was being conducted, prospective treatment with low protein formula was started. An oral feeding with 50% protein restriction (1 g/kg) and additional intravenous glucose were given to achieve normal daily fluid and caloric requirement. At 26 hours of age, the patient developed tachypnea and seizure. Blood glucose was 60 mg/dL and plasma ammonia (NH_3) 243 $\mu\text{mol/L}$ (normal range: 9-33 $\mu\text{mol/L}$). Arterial blood gases were as follows: pH 7.44, pCO_2 28 mmHg, pO_2 85 mmHg, HCO_3 19 mmol/L. The patient was transferred to neonatal intensive care unit, endotracheal-intubated, and put on a mechanical ventilator. Protein withdrawal, oral sodium benzoate (250 mg/kg/day), arginine hydrochloride (300 mg/kg/day) and 10% dextrose concentration of intravenous fluid were also prescribed (parenteral form of urea cycle medicines was not available in the country).

At 48 hours of age, the patient was deeply comatose. Plasma ammonia level was elevated to 474 $\mu\text{mol/L}$, with blood urea nitrogen 3 mg/dL, and serum creatinine 1.1 mg/dL. His vital signs were normal: T 37°C, BP 89/53 mmHg, PR 134 /min. Due to the rapid increase of plasma ammonia level despite of dietary, pharmacologic, and supportive management, the authors decided to initiate CVVH by employing the internal jugular veins and using 7-Fr diameter 16-cm length dual lumen catheter (Arrows, Arrows international, USA). The jugular veins were found too small to insert the catheter; therefore, the umbilical vein was approached. The CVVH was performed using Aquarius Platinum™ machine (Baxter/Edwards Life Sciences, USA) with pediatric Aqualine™ tubing set (Baxter/Edwards Life Sciences, USA) and 0.3 m² polyethersulfone hemofilter Aquamax™ HF 03 (Baxter/Edwards Life Sciences, USA). Replacement fluid with Acetar™ (Thai Otsuka pharmaceuticals, Thailand) was given at pre-dilution 100 mL/h (ultrafiltration rate was 25 mL/kg/h) with balance fluid strategy. A 100 ml of isotonic saline was flushed

into the tubing set every 30 minutes, and 40 units/h (10 units/kg/h) of heparin was infused at pre-dilution site to prevent clot formation in the tubing set as generally recommended, and the hemofilter⁽⁵⁾. Priming of the extracorporeal fluid with 5% albumin and heparin was given. Single connection with the catheter was used to prevent systemic heparinization. Packed red cell was given at the time of initiation of therapy. After connection, the patient's blood pressure dropped for few minutes and improved rapidly after packed red cell given, without administration of vasoactive agent. Blood flow was initiated at 28 mL/min (7 mL/kg/min) and could not be increased due to very high negative pressure of arterial line at -290 mmHg.

At 12 hours after initiation of CVVH, plasma ammonia level was still high at 442 $\mu\text{mol/L}$, probably due to ineffective CVVH as a result of clotting in the tubing set, slow blood flow rate, and small size of dual lumen catheter. Therefore, the catheter was replaced with larger sized 8-Fr diameter, 10-cm length dual lumen catheters (Mahurkar, Tyco Healthcare, USA). Apart from the pre-dilution fluid, replacement fluid (Acetar™) via post-dilution at a rate of 100 mL/h (total ultrafiltration rate was 50 mL/kg/h) was added in order to increase the clearance of plasma NH_3 . Subsequently, blood flow rate was increased up to 40 mL/min (10 mL/kg/min) and the CVVH ran smoothly. Plasma ammonia level decreased to 124 $\mu\text{mol/L}$ at 24 hours (h), and 101 $\mu\text{mol/L}$ at 48 hours after the initial CVVH (or at 12 and 36 hours after effective CVVH, respectively; Fig. 1). Partial thromboplastin time (PTT) was >200 seconds at 24 hours of CVVH initiation; so, heparin infusion rate was decreased to 20 units/hr (5 units/kg/h)

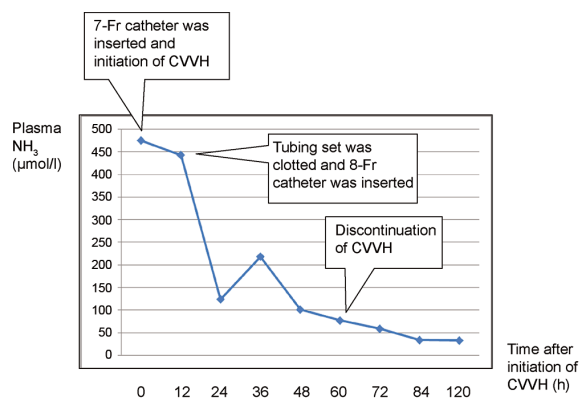


Fig. 1 Graphical representation of plasma NH_3 and time after initiation of continuous venovenous hemofiltration (CVVH).

Table 1. Laboratory parameters of the patients and continuous venovenous hemofiltration (CVVH) parameters after initiation of CVVH

Time (hour)	0	12	24	36	48	60	72	84	120
Laboratory parameters									
NH ₃ (μmol/L)	474	442	124	218	101	77	59	34	33
PTT ^s (seconds)	49	51	>200	47	63	>200	>200	56	55
Na (mmol/L)	144	-	141	-	141	-	143	-	-
K (mmol/L)	4	-	3.1	-	3.7	-	3	-	-
HCO ₃ (mmol/L)	24	-	17	-	13	-	15	-	-
Hematocrit (%)	51	-	44	-	38	-	39	-	-
Platelet (/cumm)	198,000	-	157,000	-	98,000	-	32,000	-	105,000
CVVH parameters									
BFR (mL/min)	28	32	36	40	40	40	-	-	-
UF rate (mL/kg/h)	25	50	50	50	50	50	-	-	-
Heparin (unit/h)	40	40	20	20	20	20	-	-	-

BFR = blood flow rate; HCO₃ = bicarbonate; K = potassium; Na = sodium; NH₃ = ammonia; PTT = partial thromboplastin time; UF = ultrafiltration

^s PTT reference range was 22-33 seconds

immediately. Fortunately, the patient had no systemic bleeding. The patient regained his consciousness dramatically at 12 hours after the effective CVVH. The CVVH was stopped after 60 hours (or 48 hours after effective CVVH) of running. The laboratory and CVVH parameters after initiation of CVVH are shown in Table 1.

The patient was discharged home on bottle feeding with low protein formula (protein 1.5 g/kg/day) and urea cycle medicines, on the twentieth day of life. No obvious neurologic consequence was noted at that time. His physical examination before discharge were within normal limits, including weight 4,300 g, length 54.3 cm, head circumference 37 cm, normal motor tone, and 2+ of deep tendon reflexes. Plasma ammonia level before discharge was 14 μmol/L. Genetic analysis revealed that the patient harbor the p.S81P mutation of the OTC gene, confirming the diagnosis of OTC deficiency.

Discussion

The authors have demonstrated technical difficulties in vascular accessing and selecting catheter, pitfalls in running CVVH and the prevention of clot/bleeding in a neonate with hyperammonemia, how to overcome the problems, as well as the successful removal of plasma ammonia shortly after effective CVVH.

Although affected males with neonatal onset of OTC deficiency often have fatal outcome or severe neurologic sequelae due to difficulty in controlling plasma ammonia levels; early control of the disease

can buy time until the patient is suitable for curative treatment such as liver transplantation⁽²⁾. Various modalities of dialysis such as peritoneal dialysis (PD), intermittent hemodialysis (IHD), and continuous renal replacement therapy (CRRT) including CVVH, continuous venovenous hemodialysis (CVVHD), and continuous arteriovenous hemofiltration (CAVH) have been used and reported to be beneficial in reduction of plasma ammonia level in neonates/children with urea cycle disorders and organic acidemias^(4,6-8). Donn et al suggested that IHD is preferred method, compared to exchange transfusion and PD, for treating hyperammonemia caused by urea cycle disorder⁽⁹⁾. HD clearance of ammonia is 10 times than that achieved with PD, and two to three times compared to CRRT⁽⁶⁾. The use of infant HD is limited because it requires very good vascular access, stable hemodynamic and infant HD is not available in many countries⁽⁴⁾. Recently, CVVH has been shown to have high efficacy in ammonia removal in neonates/young children with urea cycle disorders/organic acidemias and encouraged to be used as an alternative therapy for hyperammonemia, if HD is not available^(4,8). Although PD is simple and widely available to perform, the most common complication is fluid leakage through the exit site, which can lead to dialysis failure and infection. Pela et al demonstrated that PD maintained some effectiveness in less severe cases of hyperammonemia⁽⁷⁾. Given the severe disease of the present patient, despite lacking experience in performing CVVH in neonate at the center, we opted to perform CVVH in order to rescue the patient from hyperammonemic state as

soon as possible. The sooner the serum ammonia level is brought down to <200 $\mu\text{mol/L}$, the better brain function is preserved and the better candidate for liver transplantation the patient could be.

Vascular access for CVVH in neonates and small children can be problematic. Lai et al, were successful in using an 8-Fr double lumen catheter (DLC) into internal jugular vein in an 11-day old neonate (2.6 kg), and a smaller size of two central venous catheters (CVC) in other neonates/young children⁽⁴⁾. Westrope et al reported the favorable use of dual lumen catheters (5-Fr and 6.5-Fr diameter) designed specifically for use in CRRT; however, the sites of catheter insertion were not described⁽⁸⁾. In the absence of specially designed DLC and failure in access the patient's jugular veins, the authors had no choice but to try the umbilical vein. The femoral veins were not attempted in this case because its higher risk of kinking in moving the patient, which can lead to circuit clotting, and higher risk of contamination and infection, according to the experience at the center.

Umbilical vein is not commonly used for CVVH in neonate because it cannot be used for long time and in neonates older than four or five days of age. However, it is quite easy and safe to use⁽¹⁰⁻¹⁴⁾. Theoretically, the larger catheter is, the higher blood flow rate can be adjusted up to increase ammonia clearance. Umbilical catheters are not suitable for dialysis because of its small size, usually 5-Fr diameter, and 40 cm in length which create high flow resistance^(10,13). Instead, appropriate dialysis catheter should be inserted into umbilical vein for dialysis purpose, and the size of catheter can be up to 8- to 10-Fr diameter^(11,12,14). In the present case, after initiation of CVVH, blood flow rate was limited and partial clot formed due to small size of catheter. The authors overcame this problem by replacement with a larger sized catheter, in addition to increasing heparin infusion rate. Once the high blood flow and prevention of clot was achieved and smooth CVVH resulted, the patient's plasma ammonia level was effectively decreased in a short period of time.

Anticoagulant is essential to keep the tubing set free of clot. Systemic anticoagulant with heparin is the method of choice in pediatric CRRT, and PTT should be kept at about 1.5 to 2.0 times of upper normal limit⁽⁵⁾. Alternatively, activated clotting time (ACT) can be used as a bedside parameter to monitor heparin effect. Fortunately, in the present case, there was no systemic bleeding despite of prolonged PTT beyond the recommended safety range. Thrombocytopenia

from heparin effect persisted until 36 hours after the heparin withdrawal. An alternative anticoagulant for prevention of clot is regional citrate solution infused into the tubing set. It removes ionized calcium from the plasma while it is running into the tubing set resulted in decreased plasma ionized calcium for initiation of clotting system.

In the series described by Lai et al, ammonia 50% reduction time was 1.7 hour in HD and 2 to 14.5 hours in CVVH⁽⁴⁾. Westrope et al, described a median 50% reduction time 7.4 hours (range 4.5-14.3 h), and median decrease in serum ammonia levels at 12 hours of CVVH at 63%, and at 24 hours of CVVH at 75%⁽⁸⁾. In the present patient, 50% ammonia reduction was 8 hours and decrease in serum ammonia levels at 12 hours following effective CVVH was at 72%.

CVVH had some advantages over HD when applied to small children^(4,6). Firstly, it has a reduced risk of hemodynamic instability because of smaller amount of blood and slower blood flow taken through the tubing system. Secondly, it can act as a bridging therapy to metabolic control on dietary and pharmacologic treatment that can result in an avoidance of reinstitution of HD in case of rebound hyperammonemia following cessation of the HD.

At the center, CVVH has been performed in four to six pediatric cases each year since 2007 but all the cases were children weighted >10 kg. The use of CVVH in neonate with hyperammonemia from urea cycle disorder is challenging because of the rarity of the disease, problems in vascular access, difficulty in balancing between clot and bleeding tendency, and limited experience of the dialysis specialist/team. To our best knowledge, this is the first case report using hemofiltration to reduce plasma ammonia in the neonate with urea cycle defect in Thailand.

Mortality in neonates with hyperammonemia was associated with high PRISM score prior to CVVH, inotrope use, and severity of fluid overload⁽⁸⁾. Westrope et al, described survival from PICU and survival to hospital discharge at 64% and 50% in 14 hyperammonemic neonates, respectively⁽⁸⁾. However, long-term morbidity is associated with type of the underlying disease and its severity in individual cases.

Conclusion

CVVH is an effective modality of dialysis to remove ammonia in neonates with hyperammonemia. Umbilical vein is simple to access and can be used safely for CVVH in neonate, if the vein is still patent.

Acknowledgement

The authors wish to thank the staffs of pediatric intensive care unit for all their supports. The genetic analysis was financially supported by grants from Mahidol University to DW who is also a recipient of the Research Career Development Award, Faculty of Medicine Ramathibodi Hospital, Mahidol University.

Potential conflicts of interest

None.

References

1. Gordon N. Ornithine transcarbamylase deficiency: a urea cycle defect. *Eur J Paediatr Neurol* 2003; 7: 115-21.
2. Lanpher BC, Gropman A, Chapman KA, Lichter-Konecki U, Summar ML. Urea cycle disorders overview. In: Pagon RA, Bird TD, Dolan CR, Stephens K, editors. *GeneReviews* [Internet]. Seattle, WA: University of Washington; 1993 [updated 2011 Sep 1; cited 2012 Apr 19]. Available from: <http://www.ncbi.nlm.nih.gov/books/NBK1217>
3. Mathias RS, Kostiner D, Packman S. Hyperammonemia in urea cycle disorders: role of the nephrologist. *Am J Kidney Dis* 2001; 37: 1069-80.
4. Lai YC, Huang HP, Tsai IJ, Tsau YK. High-volume continuous venovenous hemofiltration as an effective therapy for acute management of inborn errors of metabolism in young children. *Blood Purif* 2007; 25: 303-8.
5. Gregory M, Bunchman TE, Brophy PD. Continuous renal replacement therapies for children with acute renal failure and metabolic disorders. In: Warady BA, Schaefer FS, Fine RN, Alexander SR, editors. *Pediatric dialysis*. Dordrecht: Kluwer Academic; 2004: 567-84.
6. McBryde KD, Kershaw DB, Bunchman TE, Maxvold NJ, Mottes TA, Kudelka TL, et al. Renal replacement therapy in the treatment of confirmed or suspected inborn errors of metabolism. *J Pediatr* 2006; 148: 770-8.
7. Pela I, Seracini D, Donati MA, Lavoratti G, Pasquini E, Materassi M. Peritoneal dialysis in neonates with inborn errors of metabolism: is it really out of date? *Pediatr Nephrol* 2008; 23: 163-8.
8. Westrope C, Morris K, Burford D, Morrison G. Continuous hemofiltration in the control of neonatal hyperammonemia: a 10-year experience. *Pediatr Nephrol* 2010; 25: 1725-30.
9. Donn SM, Swartz RD, Thoene JG. Comparison of exchange transfusion, peritoneal dialysis, and hemodialysis for the treatment of hyperammonemia in an anuric newborn infant. *J Pediatr* 1979; 95: 67-70.
10. Jouvét P, Schaefer F. Dialytic therapy of inborn errors of metabolism. In: Warady BA, Schaefer F, Alexander SR, editors. *Pediatric dialysis*. 2nd ed. New York: Springer; 2012: 765-74.
11. DiCarlo JV, Auerbach SR, Alexander SR. Clinical review: alternative vascular access techniques for continuous hemofiltration. *Crit Care* 2006; 10: 230.
12. Kato J, Nagaya M, Niimi N, Tanaka S. Venovenous extracorporeal membrane oxygenation in newborn infants using the umbilical vein as a reinfusion route. *J Pediatr Surg* 1998; 33: 1446-8.
13. Chadha V, Srivastava T. Management of acute renal failure with hemodialysis and peritoneal dialysis. In: Warady BA, Schaefer FS, Fine RN, Alexander SR, editors. *Pediatric dialysis*. Dordrecht: Kluwer Academic; 2004: 585-66.
14. Ronco C, Brendolan A, Bragantini L, Chiamonte S, Fabris A, Feriani M, et al. Treatment of acute renal failure in the newborn by continuous arteriovenous hemofiltration. *Trans Am Soc Artif Intern Organs* 1985; 31: 634-8.

การรักษาภาวะแอมโมเนียสูงในเลือดโดยวิธี *continuous venovenous hemofiltration* ในผู้ป่วยทารกแรกเกิดที่เป็นโรค *ornithine transcarbamylase deficiency*

ขวัญชัย ไพโรจน์สกุล, กาญจนา ตังนรารัชชกิจ, จรินทร์ แวพพานิช, กัลยพัทธ์ นิยมวิทย์, ดวงใจ จันทรหอม, รุ่งนภา อุดมชัยสกุล, วิวัฒน์ ตปนีย์โอพาร, ดวงฤดี วัฒนศิริชัยกุล

โรค *ornithine transcarbamylase deficiency* เป็นโรคที่พบบ่อยที่สุดในกลุ่มโรคความผิดปกติของวงจรรูเรีย และในรายที่มีอาการรุนแรงจะทำให้เกิดภาวะแอมโมเนียสูงในเลือด เกิดอาการทางสมองอย่างรุนแรงจนสมองบวม และเสียชีวิตได้ การลดระดับแอมโมเนียในเลือดโดยการฟอกเลือด (*hemodialysis*) จะลดอัตราการเสียชีวิตได้ อย่างไรก็ตาม การฟอกเลือดในทารกแรกเกิดและเด็กเล็กทำได้ยากเพราะต้องอาศัยความพร้อมของเครื่องมือ อุปกรณ์ และบุคลากรทางการแพทย์ วิธี *continuous venovenous hemofiltration (CVVH)* เป็นวิธีที่เริ่มนำมาใช้ทดแทนการฟอกเลือด แต่ก็ยังมีข้อจำกัดในผู้ป่วยที่มีน้ำหนักตัวน้อย ผู้นิพนธ์ได้รายงานผู้ป่วยทารกแรกเกิดที่ได้รับการทำ CVVH เพื่อลดระดับแอมโมเนียในเลือดโดยใช้ตำแหน่งใส่สายสวนที่หลอดเลือดดำ *umbilical* และได้อธิบายถึงปัญหาทางเทคนิค ข้อบกพร่อง และวิธีแก้ไขปัญหานั้นประสบความสำเร็จ
