

Case Report

Bilateral Atypical Femoral Fractures after Long-Term Alendronate Therapy: A Case Report

Tachchai Bamrungsong MD*,
Chatlert Pongchaiyakul MD**

* Department of Orthopedics, Phranakhon Si Ayutthaya Hospital, Phranakhon Si Ayutthaya, Thailand

** Division of Endocrinology and Metabolism, Department of Medicine, Faculty of Medicine,
Khon Kaen University, Khon Kaen, Thailand

Bisphosphonates therapy has been shown to decrease the risk of vertebral, non-vertebral, and hip fractures in postmenopausal women. However, the long-term safety of bisphosphonates use has been questioned. Recent reports have demonstrated the association between long-term alendronate therapy with low-energy subtrochanteric fracture or diaphyseal femoral fractures in a small number of patients. The author reported the first case of bilateral atypical femoral fractures in postmenopausal women with osteoporosis receiving long-term alendronate therapy.

Keywords: Atypical, Femoral fracture, Bisphosphonates, Alendronate

J Med Assoc Thai 2010; 93 (5): 620-4

Full text. e-Journal: <http://www.mat.or.th/journal>

Bisphosphonates are the most commonly used drugs and considered the first-line therapy for postmenopausal osteoporosis. Alendronate, a potent oral bisphosphonates and inhibitor of bone resorption, is now widely used in the treatment of postmenopausal osteoporosis in Thailand. Although a number of randomized controlled trials have shown that it significantly increases in lumbar spine and hip bone mineral density (BMD) and reduces the osteoporotic fractures in postmenopausal women⁽¹⁻⁹⁾, an increasing number of recent reports of atypical fractures in patients receiving bisphosphonates particularly alendronate⁽¹⁰⁻¹⁹⁾, have attracted much attention and have been concerned about the potential for the long-term suppression of bone remodeling to produce effects of bone strength.

In the present report, the authors presented the first case of bilateral atypical femoral fractures in postmenopausal Thai women receiving long-term alendronate therapy.

Case Report

A 66-year-old postmenopausal Thai woman presented to the emergency room in April 2009 after

falling from a standing height. She could not stand and walk. A deformity was found on her left leg. One month previously, the patient had discomfort and sharp pain on her thigh while walking. The patient was diagnosed with postmenopausal osteoporosis and treated with 10 mg alendronate per day since 1998. Her lumbar spine BMD T-score at the time of diagnosis was -2.5 (0.713 g/cm² using Hologic DQR 4500W) while total hip BMD T-score was -1.1 (0.721 g/cm²). After treatment, the lumbar spine and hip BMD increased when re-measured in June 2005 (1.4% in lumbar spine BMD and 1.8% in total hip BMD) and further increased in February 2009 for the lumbar spine (4.6%) but decreased for total hip (-3%).

In March 2007, the patient had a fracture at the mid-shaft of right femur after falling while walking. She also heard a snapping sound at the moment of fracture. She recalled experiencing pain and discomfort in the right thigh between three and four months before the injury. The open reduction and internal fixation with plate and screws was done and the postoperative result was good. After the first fracture, alendronate was switched to ibandronate since 2007 by an orthopedist in a different hospital and discontinued four months before the second fracture (December 2008).

Her physical examination showed marked tenderness at the left upper thigh without swelling.

Correspondence to: Pongchaiyakul C, Division of Endocrinology and Metabolism, Department of Medicine, Faculty of Medicine, Khon Kaen University, 40002, Thailand. Phone: 043-363-664, 363746, Fax: 043-347542 Email: pchatl@kku.ac.th

There was no neurovascular deficit. The radiograph revealed transverse fracture of the left femoral shaft with lateral cortical thickening and medial spiking (Fig. 1). The previous radiographs were reviewed (first fracture in 2007) and found the same pattern of the femoral shaft fracture as second fracture (Fig. 2).

The open reduction and internal fixation with plate and screws was done and the result was good. The radiograph repeated after operation at four months and showed normal fracture healing (Fig. 3A, B).

Discussion

Bisphosphonates have been widely used and recommended for the treatment of osteoporosis and the prevention of fragility fracture. However, in recent years, several authors have raised concerns over the potential harmful effects of prolonged bone turnover suppression, particularly for alendronate.

The authors reported that the patient received alendronate for nine years and switched to ibandronate for one year. The first low-energy femoral shaft fracture occurred during alendronate treatment. Moreover, subsequent atypical femoral fracture in contralateral limb occurred in the next two years, without concern about bisphosphonates treatment. However, in the present patient, the authors are not able to conclude if this propensity for atypical femoral fracture was a shared effect with ibandronate although the majority of patients in other series were on alendronate. The second fracture occurred during ibandronate treatment but prolonged suppression from alendronate remained after discontinued therapy. Although no causality or definite association has been confirmed, long-term alendronate therapy has been associated with low-energy subtrochanteric and femoral diaphyseal fractures in recent reports⁽¹⁰⁻¹⁹⁾. However, there is no report for the association between long-term ibandronate therapy and these fractures at the time of writing this manuscript.

The sequelae of long-term alendronate use on bone metabolism remain unclear. Studies in experimental animals treated with alendronate demonstrate reduced bony repair and accumulation of microdamage, leading to reduced bone toughness^(21,22). There have been an increasing number of reports regarding atypical femoral fractures in patients receiving long-term alendronate therapy⁽¹⁰⁻¹⁹⁾. Clinical presentation of these fractures has been similar. The patient, typically postmenopausal women, sustains a fracture in the subtrochanteric region or the femoral

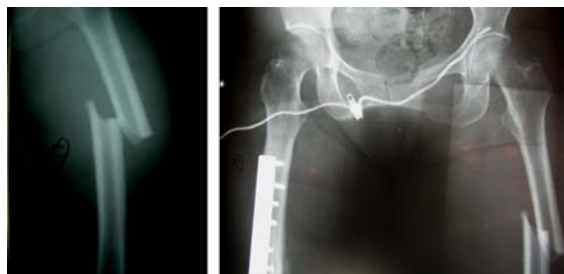


Fig. 1 Radiograph demonstrating a left femoral shaft fracture with a transverse pattern, cortical thickening and micortical spike (second fracture)

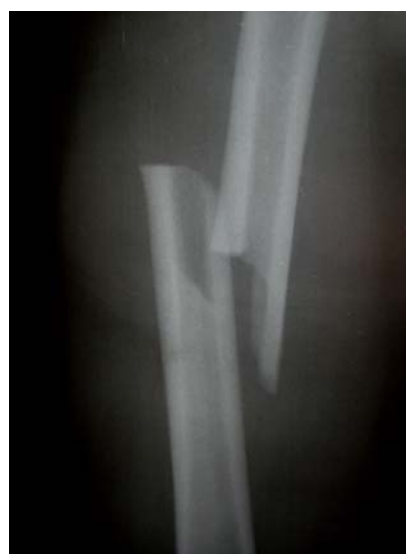

Fig. 2 Radiograph demonstrating a right femoral shaft fracture with similar pattern of Fig. 1

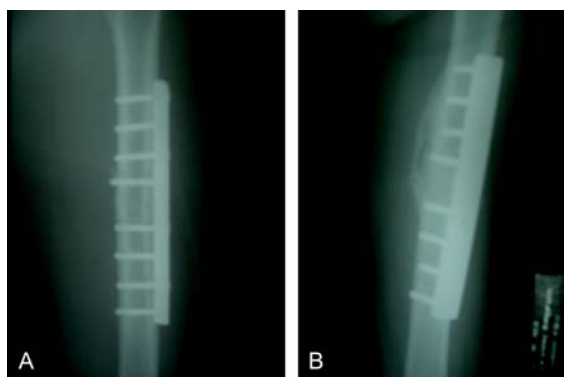


Fig. 3 After open reduction and internal fixation with plate and screws in left shaft of femur, after operation (A) and the fracture went on to union with abundant of callus formation at 4 month (B)

shaft after low-energy trauma such as a gentle fall or twisted movement as in the presented patient. Many of these patients experience prodromal pain in the affected limb a few or several months before the occurrence of these fractures. In 2005, Odvina et al⁽¹⁰⁾ reported nine patients on long-term (3-8 years) treatment with alendronate who suffered unusual, low-energy, non-spinal fractures. Five of these patients sustained femoral shaft fractures (two of them bilaterally). Bone biopsies and histomorphometric analysis in these patients showed excessive suppression of bone turnover reminiscent of adynamic bone, which presumably accounted for increased bone fragility resulting in atypical fractures. Increased microdamage accumulation has been reported in women with low bone mineral density that were treated with alendronate. Six of the nine patients displayed either delayed or absent fracture healing. Three similar patients on long-term alendronate therapy with severely suppressed bone turnover and metadiaphyseal femoral stress fractures were reported recently by Visekruna et al⁽²²⁾. Goh et al⁽¹¹⁾ in a case-control study, identified retrospectively 13 women with low-energy subtrochanteric fractures of whom nine were on long-term (2.5-5 years) alendronate therapy and four were not. Five of the patients on alendronate had prodromal pain in the affected thigh for several months preceding the fracture. In six patients, cortical hypertrophy was identified in the subtrochanteric region of the femur; whereas in three patients a similar hypertrophy could be seen in the contralateral femur. In another retrospective case-control study⁽¹²⁾, 70 aged patients were identified; 50 of them with a subtrochanteric and 20 with a femoral shaft fracture. Twenty-five (36%) had been treated with alendronate for a long time. Nineteen (76%) of these 25 patients demonstrated a simple, transverse fracture with a unicortical beak in an area of cortical hypertrophy.

The unique radiographic fracture pattern, including "simple with thick cortices", has been described in certain patients on long-term alendronate therapy⁽¹²⁻¹⁴⁾. Cortical thickening, a transverse or oblique (< 30°) fracture pattern, and cortical spiking or breaking are three characteristic features described in subtrochanteric⁽¹⁴⁾ and femoral shaft fracture^(12,13). In addition, the patient in the present report had typical features as description. Based on the findings of previous reports^(10,11), Neviasser et al⁽¹²⁾ hypothesized from the the unique radiographic pattern and prodromal pain that the complete femoral diaphyseal fracture in bisphosphonate users results from propagation of a

stress fracture unable to heal because of the excessive bisphosphonate bone turnover suppression^(10,22). Kwek et al⁽¹⁴⁾ described a similar pattern of fracture in 17 patients on alendronate therapy who suffered low-energy subtrochanteric fractures. In addition, 53% of the patients had bilateral findings of stress reactions or fractures. These authors emphasized the prodromal thigh pain or vague discomfort in 76% of these patients, a symptom that should lead to radiographic examination of the femur. In the event of a documented fracture, a radiographic examination of the contra- lateral femur should also be performed.

The question as to whether low-energy subtrochanteric or proximal femoral shaft fractures are more frequent in alendronate (or any other bisphosphonate) users compared to non-users cannot be answered at present with certainty. Prospective or cross-sectional studies including large numbers of patients are needed to resolve this issue. Subtrochanteric or proximal femoral shaft fractures are not commonly encountered in patients with untreated postmenopausal osteoporosis. In a study from Finland, some specific features of the low-energy femoral shaft fractures were described in 50 patients⁽¹⁶⁾. In this report, bisphosphonate therapy was not considered as a predisposing factor of this type of fracture and very likely no patient of this study was a bisphosphonate user. However, the majority of patients with low-energy femoral shaft fracture had one or more predisposing factors, such as diabetes mellitus, chronic corticosteroid treatment for pulmonary disease or rheumatoid arthritis, and severe osteoarthritis of the ipsilateral hip or knee.

In conclusion, the authors reported the first case of bilateral atypical femoral fracture in postmenopausal women received long-term alendronate (9 years) and one-year ibandronate. The presented case adds another report emphasizing a possible relationship between long-term bisphosphonates therapy and severely suppressed bone turnover resulting in insufficiency fractures. In patients receiving bisphosphonates, thigh pain should raise the suspicion of an insufficiency fracture and this type of fracture should be ruled out with radiograph or bone scan. Withdrawing bisphosphonates therapy should be considered if the investigations show early signs of fracture and prophylactic fixation should be considered for fracture prevention. However, the present report does not seek to diminish the important role of alendronate or other bisphosphonates therapy in osteoporosis, it only emphasizes the need for cautions administration of the drug, and close monitoring of

patients on long-term bisphosphonates is necessary, especially if a stress fracture is noted.

Acknowledgments

The authors wish to thank the Phranakhon Si Ayutthaya Hospital and Faculty of Medicine, Khon Kaen University, for their support.

References

1. Liberman UA, Weiss SR, Broll J, Minne HW, Quan H, Bell NH, et al. Effect of oral alendronate on bone mineral density and the incidence of fractures in postmenopausal osteoporosis. The Alendronate Phase III Osteoporosis Treatment Study Group. *N Engl J Med* 1995; 333: 1437-43.
2. Bone HG, Hosking D, Devogelaer JP, Tucci JR, Emkey RD, Tonino RP, et al. Ten years' experience with alendronate for osteoporosis in postmenopausal women. *N Engl J Med* 2004; 350: 1189-99.
3. Black DM, Cummings SR, Karpf DB, Cauley JA, Thompson DE, Nevitt MC, et al. Randomised trial of effect of alendronate on risk of fracture in women with existing vertebral fractures. Fracture Intervention Trial Research Group. *Lancet* 1996; 348: 1535-41.
4. Cummings SR, Black DM, Thompson DE, Applegate WB, Barrett-Connor E, Musliner TA, et al. Effect of alendronate on risk of fracture in women with low bone density but without vertebral fractures: results from the Fracture Intervention Trial. *JAMA* 1998; 280: 2077-82.
5. Black DM, Thompson DE, Bauer DC, Ensrud K, Musliner T, Hochberg MC, et al. Fracture risk reduction with alendronate in women with osteoporosis: the Fracture Intervention Trial. FIT Research Group. *J Clin Endocrinol Metab* 2000; 85: 4118-24.
6. Black DM, Schwartz AV, Ensrud KE, Cauley JA, Levis S, Quandt SA, et al. Effects of continuing or stopping alendronate after 5 years of treatment: the Fracture Intervention Trial Long-term Extension (FLEX): a randomized trial. *JAMA* 2006; 296: 2927-38.
7. Cranney A, Wells G, Willan A, Griffith L, Zytaruk N, Robinson V, et al. Meta-analyses of therapies for postmenopausal osteoporosis. II. Meta-analysis of alendronate for the treatment of postmenopausal women. *Endocr Rev* 2002; 23: 508-16.
8. Papapoulos SE, Quandt SA, Liberman UA, Hochberg MC, Thompson DE. Meta-analysis of the efficacy of alendronate for the prevention of hip fractures in postmenopausal women. *Osteoporos Int* 2005; 16: 468-74.
9. Wells GA, Cranney A, Peterson J, Boucher M, Shea B, Robinson V, et al. Alendronate for the primary and secondary prevention of osteoporotic fractures in postmenopausal women. *Cochrane Database Syst Rev* 2008; CD001155.
10. Odvina CV, Zerwekh JE, Rao DS, Maalouf N, Gottschalk FA, Pak CY. Severely suppressed bone turnover: a potential complication of alendronate therapy. *J Clin Endocrinol Metab* 2005; 90: 1294-301.
11. Goh SK, Yang KY, Koh JS, Wong MK, Chua SY, Chua DT, et al. Subtrochanteric insufficiency fractures in patients on alendronate therapy: a caution. *J Bone Joint Surg Br* 2007; 89: 349-53.
12. Neviasser AS, Lane JM, Lenart BA, Edobor-Osula F, Lorich DG. Low-energy femoral shaft fractures associated with alendronate use. *J Orthop Trauma* 2008; 22: 346-50.
13. Lenart BA, Lorich DG, Lane JM. Atypical fractures of the femoral diaphysis in postmenopausal women taking alendronate. *N Engl J Med* 2008; 358: 1304-6.
14. Kwek EB, Goh SK, Koh JS, Png MA, Howe TS. An emerging pattern of subtrochanteric stress fractures: a long-term complication of alendronate therapy? *Injury* 2008; 39: 224-31.
15. Kwek EB, Koh JS, Howe TS. More on atypical fractures of the femoral diaphysis. *N Engl J Med* 2008; 359: 316-7.
16. Salminen S, Pihlajamäki H, Avikainen V, Kyrö A, Böstman O. Specific features associated with femoral shaft fractures caused by low-energy trauma. *J Trauma* 1997; 43: 117-22.
17. Sayed-Noor AS, Sjödin GO. Subtrochanteric displaced insufficiency fracture after long-term alendronate therapy - a case report. *Acta Orthop* 2008; 79: 565-7.
18. Cheung RK, Leung KK, Lee KC, Chow TC. Sequential non-traumatic femoral shaft fractures in a patient on long-term alendronate. *Hong Kong Med J* 2007; 13: 485-9.
19. Schneider JP. Should bisphosphonates be continued indefinitely? An unusual fracture in a healthy woman on long-term alendronate. *Geriatrics* 2006; 61: 31-3.
20. Mashiba T, Mori S, Burr DB, Komatsubara S, Cao Y, Manabe T, et al. The effects of suppressed bone remodeling by bisphosphonates on microdamage accumulation and degree of mineralization in the

- cortical bone of dog rib. J Bone Miner Metab 2005; 23(Suppl): 36-42.
21. Mashiba T, Turner CH, Hirano T, Forwood MR, Johnston CC, Burr DB. Effects of suppressed bone turnover by bisphosphonates on microdamage accumulation and biomechanical properties in clinically relevant skeletal sites in beagles. Bone 2001; 28: 524-31.
22. Visekruna M, Wilson D, McKiernan FE. Severely suppressed bone turnover and atypical skeletal fragility. J Clin Endocrinol Metab 2008; 93: 2948-52.

กระดูกต้นขาหักนอกแบบ 2 ข้างภายหลังการรักษาด้วยยา alendronate ระยะยาว รายงานผู้ป่วย 1 ราย

ธัชชัย บำรุงสงฆ์, ฉัตรเลิศ พงษ์ไชยกุล

แม้ว่าบิสฟอสโฟเนต เป็นยารักษาโรคกระดูกพรุนที่มีประสิทธิผลในการป้องกันการเกิดกระดูกสันหลังหัก กระดูกตำแหน่งอื่น ๆ รวมทั้งกระดูกสะโพกหักในผู้หญิงวัยหมดประจำเดือนก็ตาม แต่ความปลอดภัยในการใช้ยา ระยะยาวยังคงถูกตั้งคำถามตลอดมา หลายการศึกษาได้เริ่มรายงานผู้ป่วยที่เกิดกระดูกต้นขาหักทั้งที่ตำแหน่ง subtrochanter และด้ามจากการกระแทกที่ไม่รุนแรง รายงานฉบับนี้ได้นำเสนอผู้ป่วย 1 ราย ที่เกิดกระดูกต้นขาหัก นอกแบบ 2 ข้าง ในผู้หญิงวัยหมดประจำเดือนที่เป็นโรคกระดูกพรุนและได้รับการรักษาด้วยยา alendronate ระยะยาว