

The Relationship between Plate and Screw to Ulnar Nerve in Distal Humeral Fracture: A Cadaveric Study

Pratchaya Manop MD¹, Parunyu Vilai MD¹

¹ Department of Orthopedics, Faculty of Medicine, Srinakharinwirot University, Nakhon Nayok, Thailand

Background: Plate and screw fixation during the treatment of distal humeral fracture in adults is considered to be a gold standard that makes anatomic and articular reduction. Injury of the ulnar nerve is a common condition that can be found in pre-operative, intraoperative, and post-operative. Intraoperative anterior subcutaneous transposition is still a controversial issue.

Objective: To understand the variation of distance of the ulnar nerve during elbow motion with the anatomical landmark of distal humeral bone and plate position after fixation.

Materials and Methods: The authors have studied ten fresh adult cadavers, who underwent autopsy at the Department of Forensic Medicine of Srinakharinwirot University.

Results: The results showed that in zone 2, the Center of the medial condyle was the position of the distal humeral bone with the most variation in position changing during elbow flexion/extension. In the sagittal plane (+2.56 to -4.58 mm), the mean difference equaled to 7.14 mm, while in the coronal plane (+1.70 to -5.14 mm), the mean difference equaled to 6.84 mm, with the highest percentage of irritation up to 70%. Furthermore, 14 cases of ulnar nerve subluxation were found in 20 studies (70%).

Conclusion: From the present study, the Medial condyle was the landmark with the most irritation and position changing of ulnar nerve during elbow flexion. The incidence of ulnar subluxation occurred after in situ release for plate fixation was also found higher than in previous studies.

Keywords: Plate and screw fixation; Ulnar nerve injury; Distal humeral fracture; Anterior subcutaneous nerve transposition; Cadaveric study; Anatomical bony landmark of distal humeral bone; Ulnar nerve subluxation

Received 18 December 2020 | Revised 9 April 2021 | Accepted 20 April 2021

J Med Assoc Thai 2021;104(6):911-5

Website: <http://www.jmatonline.com>

Plate and screw fixation remains the gold standard choice for dealing with an intraarticular distal humeral fracture in adults. Ulnar nerve neuropathy is a common complication associated with distal humeral fracture in around 50% of the patients⁽¹⁻³⁾ at the time of fracture from the direct impact of injury, intraoperative fixation by traction, nerve manipulation, or injured blood supply, and postoperative surgical scar formation or implant irritation⁽⁴⁾.

During the fixation, in situ release and mobilization of the ulnar nerve is necessary for fracture reduction and appropriate anatomical location

of the plate and screws. However, this procedure will increase the risk of neuropathy for the ulnar nerve.

Anterior subcutaneous transposition has the advantage of shifting the nerve away from the implants site, preventing subluxation of the nerve, avoiding the nerve kinking during elbow motion, and decreasing the chance of scar formation around the nerve. However, result of some studies shows that transposition will increase the risk of ulnar nerve neuritis by almost four times comparing to those without transposition⁽⁵⁾.

The purpose of the present study was to understand the variation of distance of the ulnar nerve during elbow motion with the anatomical landmark of distal humeral bone and plate position after fixation. There is a chance of the irritation of the ulnar nerve with plate and incidence of subluxation after in situ release of the ulnar nerve.

Correspondence to:

Manop P.

Department of Orthopedics Surgery, Faculty of Medicine, Srinakharinwirot University, 62 Moo 7 Rangsit-Nakornnayok Road, Ongkarak, Nakornnayok 26120, Thailand.

Phone: +66-37-395085

Email: pratchaya.mnop@gmail.com

How to cite this article:

Manop P, Vilai P. The Relationship between Plate and Screw to Ulnar Nerve in Distal Humeral Fracture: A Cadaveric Study. J Med Assoc Thai 2021;104:911-5.

doi.org/10.35755/jmedassocthai.2021.06.12321

Materials and Methods

The authors studied ten fresh adult cadavers that underwent autopsy at the Department of Forensic Medicine of Srinakharinwirot University. The authors received the permission of ethic consent from their

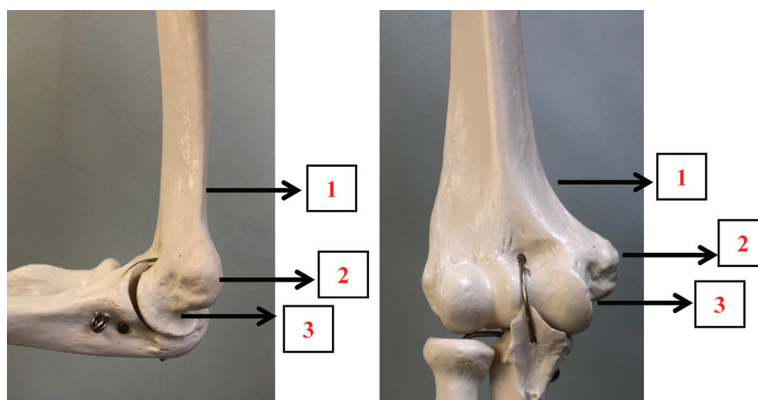


Figure 1. Anatomical landmarks.

Table 1. Anatomical landmarks in the sagittal plane and coronal plane

Landmark	Definition
Sagittal	
1	The midline of the medial supracondylar ridge above Landmark 2 about 2 cm
2	Center of the most medial point of medial condyle of distal humeral
3	The midline of the medial point of the humeral trochlea
Coronal	
1	The medial supracondylar ridge above Landmark 2 about 2 cm
2	The most medial point of medial condyle of distal humeral
3	The medial point of the humeral trochlea

relatives (SWUEC-374/2561E). All the cadavers were dead within 24 hours. There were 20 virgin elbows, with no deformity and no previous surgery, in which 16 of them were from eight males and four from two females with average age equal to 33 to 80 years old.

After the autopsy was done, the cadavers were changed into a prone position. The orthopedic surgeon had performed the posterior midline incision and retracted the triceps muscle to the radial side. The ulnar nerve was then completed in situ, released from the arcade of Struthers through the flexor-pronator aponeurosis and protected with white thread. The procedure was similar to the preparation of the medial side of the distal humeral bone with plate fixation. Finally, the cadavers were changed to supine position for better visualization and collection of data.

The authors had classified the landmark of distal humeral in three zones (Figure 1) for the sagittal and coronal view as shown in Tables 1. For the ulnar nerve, the authors used the anterior edge in the sagittal

plane and the medial edge in the coronal plane as reference points to measure the change in location of the ulnar nerve.

If there was an anterior or medial to the reference point, the authors would give a positive number. However, if there was a posterior or lateral, the authors would give a negative number.

Vernier caliper was used for measuring the distance of ulnar nerve comparing with the anatomical landmark of distal humeral bone in coronal and sagittal view in elbow deep flexion and full extension (Figure 2). The data would be presented in mean, minimum and maximum, standard deviation (SD), and mean difference (mm) together with the percentage of irritation and incidence of subluxation of the ulnar nerve (Figure 3). After that, the authors applied the medial plate and observed the area the ulnar nerve and plate irritated during elbow motion (Figure 4).

Statistical analysis

The distance of ulnar nerve comparing with the anatomical landmark of distal humeral bone in coronal and sagittal were measured in elbow deep flexion and full extension, and the differences between the elbow deep flexion and full extension were calculated. Descriptive statistics with mean, SD, minimum, and maximum were calculated for continuous variables. In addition, the results are presented as frequencies and percentages for categorical variables. All continuous variables were checked with the Shapiro-Wilk test. The statistical analysis was performed with Microsoft Office Excel 2010.

Results

The average age of cadavers was 52.89 years old (33 to 80) with an average time of death of 24

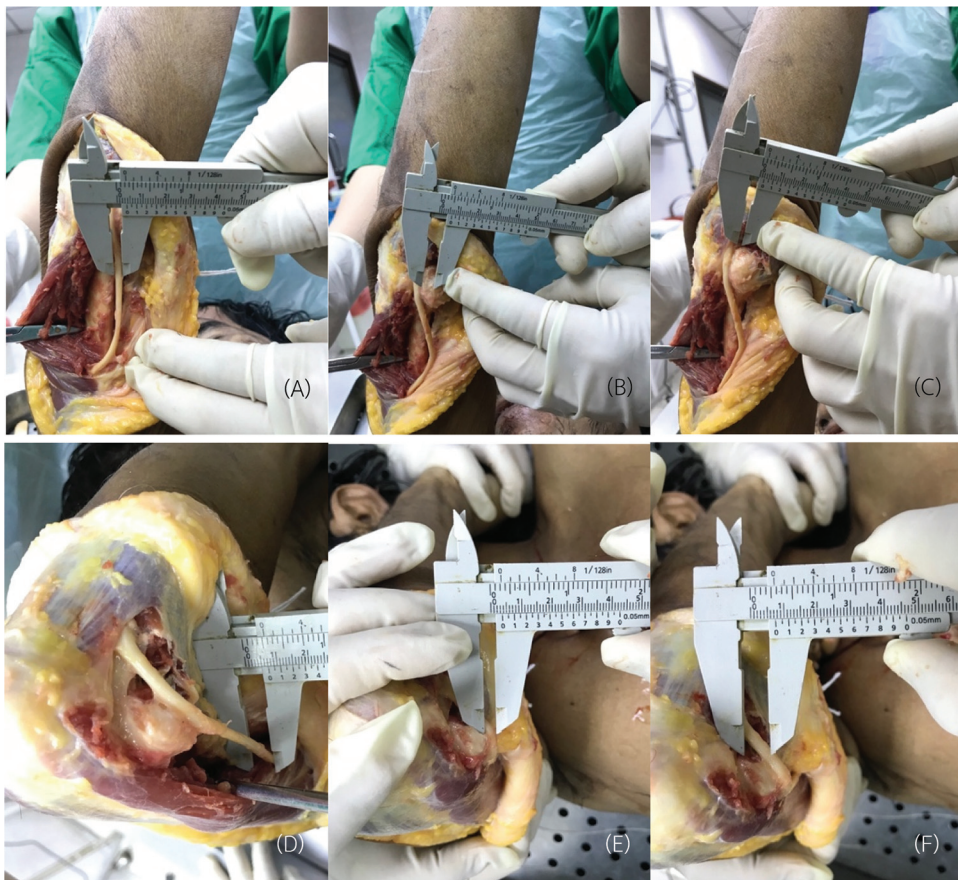

Figure 2. Measurement in the sagittal plane with Vernier caliper in 1/10 mm scale, Full elbow extension at Zone 1: The midline of the medial supracondylar ridge above Landmark 2 about 2 cm (A). Full elbow extension at Zone 2: Central of the most medial point of medial condyle of distal humeral (B). Full elbow extension at Zone 3: The midline of the medial point of the humeral trochlea (C). Measurement in the coronal plane, Full elbow flexion at Zone 1: The medial supracondylar ridge above Landmark 2 about 2 cm (D). Full elbow flexion at Zone 2: The most medial point of medial condyle of distal humeral (E). Full elbow flexion at Zone 3: The medial point of the humeral trochlea (F).

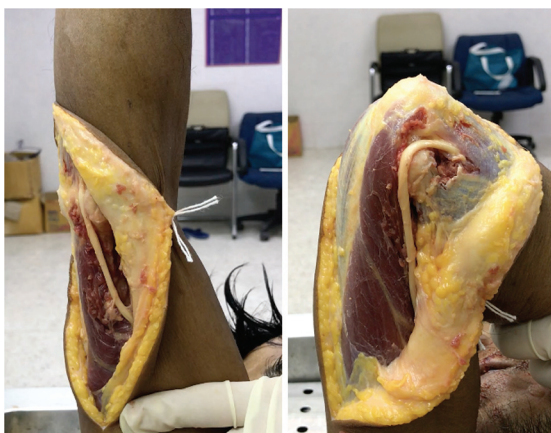

Figure 3. Tested for subluxation by passive elbow extension to full flexion.

hours. Twenty distal humeral bones were completely dissected and measured in both coronal and sagittal

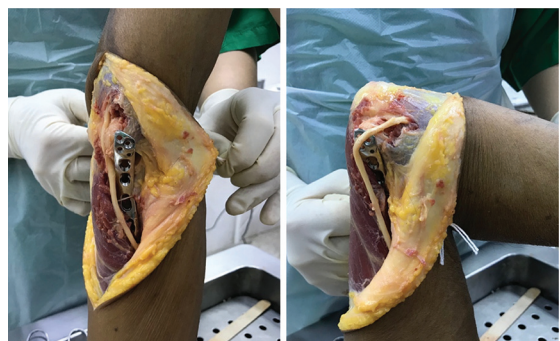

Figure 4. Tested for the area of irritation between plate and nerve by passive elbow extension to full flexion.

planes. The results showed that in zone 2, the center of the medial condyle was the position of the distal humeral bone with the most variation in position changing during elbow flexion or extension. In the

Table 2. Distance between ulnar nerve with anatomical landmarks and% of irritation area in the sagittal and coronal plane

Zone	Flexion (mm)					Extension (mm)					Mean difference (mm)	% Irritation
	Median	Min	Max	Mean	SD	Median	Min	Max	Mean	SD		
Sagittal plane												
1	1.80	-6.5	7.8	0.64	4.02	-2.70	-6.0	6.20	-2.74	2.52	3.38	0
2	2.50	-3.3	7.9	2.56	3.51	-4.00	-8.70	-0.90	-4.58	2.39	7.14	70
3	1.70	-3.30	11.10	2.40	4.08	-1.80	-5.10	6.30	-0.66	2.93	3.06	0
Coronal plane												
1	3.05	-3.90	9.90	3.89	3.37	-1.40	-7.50	4.60	-0.16	3.39	4.05	0
2	1.70	-4.70	6.90	1.70	3.11	-5.10	-11.20	3.70	-5.14	3.36	6.84	70
3	4.15	1.80	8.70	4.83	2.30	2.20	0.50	5.70	2.49	1.95	2.34	0

SD=standard deviation

Table 3. Incidence of ulnar nerve subluxation after in situ release

Total	Subluxation	No subluxation	%
20	14	6	70

sagittal plane (+2.56 to -4.58 mm), a mean difference was 7.14 mm, while in the coronal plane (+1.70 to -5.14 mm), a mean difference was 6.84 mm, with the highest percentage of irritation up to 70% (Table 2). Furthermore, 14 cases of ulnar nerve subluxation were found on 20 studies (70%) as shown in Table 3.

Discussion

From the present study, the authors found the variation in distance of ulnar nerve during elbow motion had changed as much as 7.14 mm with a percentage of irritation between ulnar nerve and plate of 70% in zone 2, which was the central point of the medial condyle. Moreover, the incidence of ulnar nerve subluxation after in situ release in the present study was 70%. Comparing to the previous studies, the incidence of ulnar subluxation from ultrasound, it was found that 49% of patients had ulnar nerve neuropathy⁽⁶⁾. The authors believed that the injury of the elbow at the time of fracture and in situ release for plate fixation around medial condyle may increase the damage to the soft tissue which will increase the chance of subluxation.

The recent meta-analysis reported that the overall incidence of ulnar nerve neuropathy was 19% postoperatively, in which columnar fractures were the only significant risk factor toward the symptoms. Meanwhile, heterotopic ossification and postoperative surgical scar formation are also risk factors that may cause delayed onset of ulnar neuropathy⁽⁷⁻⁹⁾. There are several studies regarding the treatment of ulnar

nerve that can prevent this complication. In the past, some surgeons believed that routine anterior subcutaneous nerve transposition can reduce the risk of postoperative ulnar nerve neuropathy⁽¹⁰⁾, but this issue is still controversial. Chen et al⁽⁵⁾ reported that 48 patients underwent open reduction internal fixation (ORIF) with transposition, and this increased the risk 4 times of postoperative ulnar nerve neuritis comparing to 89 patients who underwent ORIF without transposition. However, Wigger et al⁽⁸⁾ who followed 107 patients that underwent the surgical treatment of distal humeral fracture with ulnar nerve neuropathy for at least six months found that the handling of the ulnar nerve with or without transposition was not different.

The present study was the first cadaveric study about the location of ulnar nerve comparing to anatomical landmark and danger zone of implant position including incidence subluxation after release from fresh cadavers who were dead within 24 hours. Being fresh cadaver meant that the cadaver's structure would be in the condition closest to the living human anatomy.

The limitation of the present study was that the analyses were conducted from intact distal humeral bone, which the results may differ from the distort anatomy of the lesions from fracture. The avoidance of the danger zone and the examination of ulnar nerve subluxation after in situ release are essential procedures to reduce the chance of postoperative ulnar nerve neuropathy from implant irritation. The authors recommended that if it is necessary to apply an implant on the medial condyle, a low-profile implant should be used. Moreover, in the case of intraoperative ulnar nerve subluxation and implant irritation with the ulnar nerve, anterior transposition could be more beneficial.

Conclusion

Medial condyle was the landmark with the most irritation and position changing of ulnar nerve during elbow flexion. The incidence of ulnar subluxation occurred after in situ release for plate fixation was also found higher than in the previous studies. The orthopedic surgeons must be aware of this area after fixation in distal humerus fracture.

What is already known on this topic?

Plate and screw fixation during the treatment of distal humeral fracture in adults is a gold standard that makes anatomical and articular reduction. Injury of the ulnar nerve is a common condition that can be found in pre-operative, intraoperative, and post-operative. Intraoperative anterior subcutaneous transposition is still a controversial issue.

However, there is no study about the relationship between anatomy of the ulnar nerve, distal humeral bone, and plate fixation, and incidence of nerve subluxation after in situ release.

What this study adds?

To understand the variation of distance of the ulnar nerve during elbow motion with the anatomical landmark of distal humeral bone and plate position after fixation. The incidence of ulnar subluxation occurring after in situ release for plate fixation was also found higher than in the previous studies.

Acknowledgement

The authors would like to take this opportunity to sincerely express gratitude toward the cadavers for permission to study their bodies for medical purposes. May their merit lead them to comfort and peace. Our financial support for the present study was from the Faculty of Medicine, Srinakharinwirot University. This study does not involve any benefit or commitment to any commercial entity.

Conflicts of interest

The authors declare no conflict of interest.

References

1. Holdsworth BJ, Mossad MM. Fractures of the adult distal humerus. Elbow function after internal fixation. *J Bone Joint Surg Br* 1990;72:362-5.
2. Kundel K, Braun W, Wieberneit J, Rüter A. Intraarticular distal humerus fractures. Factors affecting functional outcome. *Clin Orthop Relat Res* 1996;200-8.
3. McKee MD, Jupiter JB, Bosse G, Goodman L. Outcome of ulnar neurolysis during post-traumatic reconstruction of the elbow. *J Bone Joint Surg Br* 1998;80:100-5.
4. Bucholz RW, Court-Brown CM, Heckman JD, Tornetta P 3rd. *Rockwood and Green's fractures in adults*. 7th ed. Philadelphia, PA: Wolters Kluwer Health/Lippincott Williams & Wilkins; 2010.
5. Chen RC, Harris DJ, Leduc S, Borrelli JJ Jr, Tornetta P 3rd, Ricci WM. Is ulnar nerve transposition beneficial during open reduction internal fixation of distal humerus fractures? *J Orthop Trauma* 2010;24:391-4.
6. Schertz M, Mutschler C, Masmajejan E, Silvera J. High-resolution ultrasound in etiological evaluation of ulnar neuropathy at the elbow. *Eur J Radiol* 2017;95:111-7.
7. Vazquez O, Rutgers M, Ring DC, Walsh M, Egol KA. Fate of the ulnar nerve after operative fixation of distal humerus fractures. *J Orthop Trauma* 2010;24:395-9.
8. Wiggers JK, Brouwer KM, Helmerhorst GT, Ring D. Predictors of diagnosis of ulnar neuropathy after surgically treated distal humerus fractures. *J Hand Surg Am* 2012;37:1168-72.
9. Shearin JW, Chapman TR, Miller A, Ilyas AM. Ulnar nerve management with distal humerus fracture fixation: A meta-analysis. *Hand Clin* 2018;34:97-103.
10. Wang KC, Shih HN, Hsu KY, Shih CH. Intercondylar fractures of the distal humerus: routine anterior subcutaneous transposition of the ulnar nerve in a posterior operative approach. *J Trauma* 1994;36:770-3.