

Case Report

A Case Report of Tumor-Induced Osteomalacia: Eight Year Followed-Up

Tanaporn Ratanasuwan MD*, Somchai Chetsurakarn MD*,
Boonsong Ongphiphadhanakul MD**, Somneok Damrongkitchaiporn MD**

* Internal Medicine Unit, Lerdsin Hospital, Department of Medical Service, Ministry of Public Health, Bangkok

** Department of Internal Medicine, Ramathibodhi Hospital, Mahidol University, Bangkok

Tumor-induced osteomalacia (TIO) is a rare but potentially curable disease. It is caused by excessive renal clearance of phosphate induced by a substance secreted from the tumor. Here, the authors report a Thai patient who presented with multiple pathologic fractures, low serum phosphorus, and low tubular maximum reabsorption of phosphorus/glomerular filtration rate (TmPO4/GFR). The clinical, biochemical and bone abnormalities improved 6 months after the surgery. Two years follow-up showed no recurrence of the disease. Physicians should be aware of this condition when encountering with adult onset osteomalacia.

Keywords: Tumor-induced osteomalacia, Oncogenic osteomalacia, Hypophosphatemic ricket, Hemangiopericytoma, Fibroblast growth factor 23

J Med Assoc Thai 2008; 91 (12): 1900-3

Full text. e-Journal: <http://www.medassocthai.org/journal>

Case Report

A 46-year-old Thai male had persistent bone pain for four years. Four years earlier he had a compression fracture of his L4-L5 spine. One year later, he developed incomplete fracture of his greater trochanter. At surgery, a non-union fracture of his left and right thoracic rib cage and a pseudofracture of his right fibula were noted.

One year after the second fracture, he developed a right femoral neck fracture. After the surgery, deep pain persisted in both his left and right groin, and back pain increased. He also complained of increasing proximal muscle weakness and noted a nine-cm loss of height.

Physical examination revealed a deformity of his thoracic cage, kyphoscoliosis, bowing and shortening of the right leg. A small painless, well-circumscribed soft tissue 2x2 cm tumor size with a soft consistency was identified at the medial aspect of his right ankle. Laboratory investigation showed bone mineral density (BMD) T score of -3.5 SD at L2-L4 spine. Serum phosphorus (P) ranged from 0.9 to

1.4 mg/dl (normal 2.5-4.5 mg/dl), serum alkaline phosphatase (ALP), ranged from 375-700 IU/L (normal 36-100 IU/L), and serum calcium and intact PTH levels were both normal. The patient showed 1+ glycosuria. The tubular reabsorption of phosphorus (TRP) was 75% (normal 80-98). The maximum renal tubular absorption of phosphate per glomerular filtration rate (TmPO4/GFR) was 1.3 mg/dL (normal 2.5-4.2 mg/dL). His serum 25 OH vitamin D3 level was low normal at 14.79 ng/ml (normal 15-80 ng/ml) while 1, 25 OH vitamin D3 level was low, 4.4 mmol/L (normal 12-40;). Iliac crest bone biopsy showed severe osteomalacia (Fig. 1).

The dissected mass at the right ankle was 3.4 x 4 x 6.5 cm and originated from the periosteum of the distal end of tibia. The cut surface was grayish red with some hemorrhage and a small area of calcification. No necrosis was observed. Histological diagnosis was hemangiopericytoma, with low-grade malignancy. Using the Enneking classification, he was surgical stage IB.

After removal of the tumor, the TMPO4/GFR and serum phosphorus returned to normal within one month (Fig. 2). The patient was treated with calcium carbonate tablets and phosphate solution 1 gram per day. Bone pain and muscular weakness were also

Correspondence to: Ratanasuwan T, Internal Medicine Unit Lerdsin Hospital, Department of Medical Service, Ministry of Public Health, Bangkok 10500, Thailand.

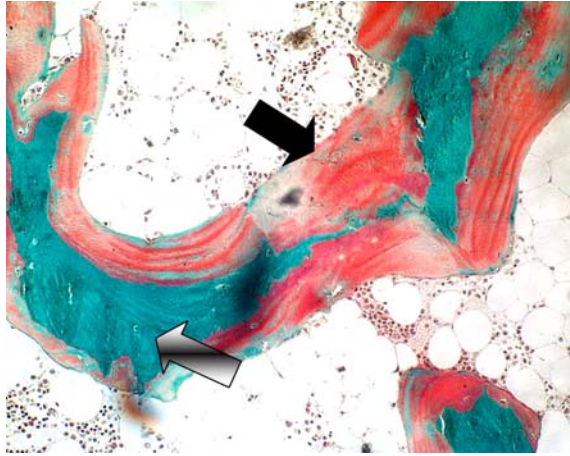


Fig. 1 Histologic section of bone from patient with TIO. Uncalcified iliac trabeculae bone (black arrow) is covered by excessive amount of osteoid (gradient arrow)

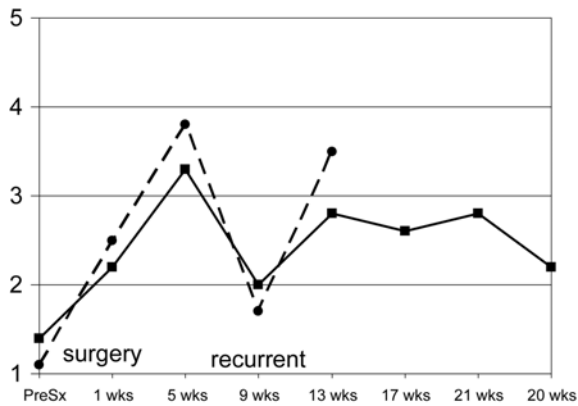


Fig. 2 Serum P (dot) and TmPO4/GFR (line) before and after excision of the tumor

improved. BMD increased from -3.5 SD to -2.1 SD in 8 weeks, and was normal at -1.5 SD after 16 weeks assessed by Lunar bone densitometer.

Nine weeks after surgery, the patient developed mild muscular weakness. His serum P and TmPO4/GFR decreased without recurrent lesion shown on the plain film x-ray. Local recurrence was assumed. This led to radioadjuvant therapy with the total dose of one-thousand cGy at the right ankle. Serum P and TmPO4/GFR returned to normal. The authors have followed him for one-year and found that his serum P maintained at 2.6 with normal TmPO4.

Using a DNA primer, the hemangiopericytoma tumor was shown to express fibroblast growth factor 23 (FGF 23). The patient comes back for a followed-up once a year. His serum phosphorus and chest x-ray are normal. There has not been any recurrence of the disease after eight years of treatment.

Discussion

Bone mineralization requires normal calcium, phosphorus, and vitamin D metabolism. Decreased serum phosphorus from any cause can result in osteomalacia. The clinical features of this case that are distinctive for osteomalacia include generalized bone pain and deformities. TIO is one of the most common causes of osteomalacia presenting in an adult. This syndrome should be considered when hypophosphatemia, high alkaline phosphatase and low plasma 1,25-dihydroxyvitamin D (1,25-(OH)₂D) are present.

It was postulated that the tumor released a substance that inhibited renal proximal tubule reabsorption of phosphorus. In fact, when a hemangiopericytoma was transplanted from a human to athymic nude mice, a clinical picture resembling a TIO patient can be reproduced⁽¹⁾. Hemangiopericytoma tumor extract has also shown to inhibit 25-hydroxyvitamin D 1 α -hydroxylase activity when added to a primary renal tubule cell culture⁽¹⁾. This could explain why serum 1,25-(OH)₂D was very low when 25 hydroxy vitamin D was only low normal in the presented patient.

Shimada et al demonstrated the expression of fibroblast growth factor 23 (FGF23) from cells cloned from a hemangiopericytoma. They also showed that after administering the recombinant FGF23 into mice, the serum phosphate was decreased⁽²⁾. Miyauchi et al implanted nude mice with Chinese hamster ovary cells expressing FGF23. These mice showed hypophosphatemia with increased renal phosphate clearance⁽¹⁾. Recently FGF 23 gene has been identified as the gene responsible for autosomal dominant hypophosphatemic rickets⁽³⁾. Increasing FGF23 expression in X-linked hypophosphatemic rickets is associated with a mutation of the PHEX gene, a phosphate-regulating gene with homologies to endopeptidases located on the X chromosome⁽⁴⁾. These results suggest that FGF23 might be the long sought after phosphatonin, the postulated substance that alters renal function and was responsible for the TIO clinical presentation in humans⁽⁵⁾.

Recommendations for treatment of adult onset osteomalacia include an extensive search for the tumor. Tumors are most likely to be in the meninges,

paranasal sinuses, retroperitoneal area, and peripheral extremity⁽⁶⁾. Almost all the tumors are mesenchymal in origin. Hemangiopericytoma, hemangioma, sclerosing fibroma, and non-ossifying fibroma are among the most common. There are reports that octreotide scan help locate some tumors⁽⁷⁾.

Treatment and prognosis of hemangiopericytoma is inconclusive due to the rarity of incidence. In one series from M.D. Anderson Cancer Center, in 36 patients who underwent complete resection and then followed-up to 57 months, 32% developed evidence of local recurrence. No tumor localized to an extremity recurred. Statistical analysis showed that tumors found in an extremity have a longer local recurrence-free survival compared to non-extremity tumors⁽⁸⁾. Five years survival rate of the entire group was 71%. Wide excision of the tumor is the treatment of choice in this potentially malignant tumor. Whether chemotherapy or radiotherapy adjuvant treatment improves long-term survival or symptom free survival is still a question⁽⁹⁾. Some investigators suggest that tumors with fewer than four mitotic cells per 10 on high power field, and tumor diameter less than 6.5 cm yield a better prognosis⁽¹⁰⁾.

As demonstrated in the presented patient, serum phosphorus and TmPO4/GFR can be used as tumor markers. Literature review revealed 30% of patients developed metastatic lung disease up to eight years after initial diagnosis⁽¹¹⁾. Based on the data, long-term follow-up is recommended in all patients.

TIO is a potentially curable disease. The bone mass density can improve tremendously as shown in the presented case. Bone morphology showing widening of osteoid seam, as the characteristic of osteomalacia, decreased drastically six months after the surgery.

In conclusion, the authors demonstrated a case of hemangiopericytoma-induced osteomalacia whose biochemical abnormalities, BMD and bone histomorphology were improved four months after removal of the tumor. The authors demonstrated that the serum phosphorus and TMPO4/GFR could be followed as tumor markers. In the presented case, local recurrence responded well to 1000 cGy radiotherapy. Two years follow-up of the presented patient showed no recurrence of tumor clinically or biochemically. The

tumor expressed FGF 23 as observed previously in the literature.

References

1. Miyauchi A, Fukase M, Tsutsumi M, Fujita T. Hemangiopericytoma-induced osteomalacia: tumor transplantation in nude mice causes hypophosphatemia and tumor extracts inhibit renal 25-hydroxyvitamin D 1-hydroxylase activity. *J Clin Endocrinol Metab* 1988; 67: 46-53.
2. Shimada T, Mizutani S, Muto T, Yoneya T, Hino R, Takeda S, et al. Cloning and characterization of FGF23 as a causative factor of tumor-induced osteomalacia. *Proc Natl Acad Sci U S A* 2001; 98: 6500-5.
3. ADHR Consortium. Autosomal dominant hypophosphataemic rickets is associated with mutations in FGF23. *Nat Genet* 2000; 26: 345-8.
4. Drezner MK. PHEX gene and hypophosphatemia. *Kidney Int* 2000; 57: 9-18.
5. Strewler GJ. FGF23, hypophosphatemia, and rickets: has phosphatonin been found? *Proc Natl Acad Sci U S A* 2001; 98: 5945-6.
6. Drezner MK. Tumor-induced rickets and osteomalacia. In: Favus MJ, editor. *Primer in the metabolic bone diseases and disorders of mineral metabolism*. Philadelphia: Lippincott-Raven; 1996: 319-25.
7. Rhee Y, Lee JD, Shin KH, Lee HC, Huh KB, Lim SK. Oncogenic osteomalacia associated with mesenchymal tumour detected by indium-111 octreotide scintigraphy. *Clin Endocrinol (Oxf)* 2001; 54: 551-4.
8. Spitz FR, Bouvet M, Pisters PW, Pollock RE, Feig BW. Hemangiopericytoma: a 20-year single-institution experience. *Ann Surg Oncol* 1998; 5: 350-5.
9. Enneking WF, Spanier SS, Goodman MA. A system for the surgical staging of musculoskeletal sarcoma. *Clin Orthop Relat Res* 1980; 153: 106-20.
10. Craven JP, Quigley TM, Bolen JW, Raker EJ. Current management and clinical outcome of hemangiopericytomas. *Am J Surg* 1992; 163: 490-3.
11. Billings KR, Fu YS, Calcaterra TC, Sercarz JA. Hemangiopericytoma of the head and neck. *Am J Otolaryngol* 2000; 21: 238-43.

รายงานการติดตามการรักษา ผู้ป่วยกระดูกอ่อนจากการสูญเสียฟอสเฟตในเลือดจากเนื้องอก
หลังได้รับการรักษาเป็นเวลา 8 ปี

ธนพร รัตนสุวรรณ, สมชาย เจตนสุรกานต์, บุญส่ง องค์กรพัฒนกุล, สมนึก ดำรงกิจชัยพร

โรคกระดูกอ่อนจากระดับฟอสเฟตในเลือดต่ำ ซึ่งมีสาเหตุจากเนื้องอกผลิตสารคัดหลังที่ยับยั้งการดูดกลับฟอสเฟตที่ไตนั้นพบได้น้อย โรคนี้เป็นโรคที่รักษาหายขาด ถ้าค้นหาเนื้องอกที่ผิดปกติพบและทำการผ่าตัด คณะผู้พิมพ์ได้รายงานผู้ป่วยโรคนี้ที่ได้รับการรักษาโดยการผ่าตัดและฉายรังสีเฉพาะที่ นำเสนออาการ ค่าทางห้องปฏิบัติการ ชี้นเนื้อกระดูก และการดำเนินโรค การติดตามผู้ป่วยหลังรักษา 8 ปีซึ่งยังไม่มีการกลับเป็นซ้ำ แพทย์ควรตระหนักถึงภาวะนี้เมื่อได้พบกับภาวะกระดูกอ่อนในผู้ใหญ่ ควรค้นหาเนื้องอกที่เป็นสาเหตุ เพราะจะทำให้ได้ผลการรักษาที่ดี
