

Case Report

Maternal Chickenpox in Peripartum Period: A Case Report and Review

Sumate Pattanasuttinont MD*

* Department of Obstetrics and Gynecology, HRH Maha Chakri Sirindhorn Medical Center,
Faculty of Medicine, Srinakharinwirot University, Nakornnayok

A 30-year-old pregnant woman had skin lesions at 38 weeks of gestation. She was diagnosed as primary varicella zoster infection. Her clinical symptoms were high fever and generalized vesicles eruption. No serious maternal complication was found. The patient delivered a male baby 4 days after she developed skin lesions. The neonatal blood IgM against varicella zoster was negative. The baby was given Varicella zoster immunoglobulin within 24 hours and isolated in a neonatal care unit. The baby developed skin lesions on day 11th post delivery. Intravenous acyclovir was administered for 7 days. Finally, the baby was found to be free of severe neonatal varicella infection.

Keywords: *Varicella zoster virus, Varicella zoster immunoglobulin, Pregnancy*

J Med Assoc Thai 2008; 91 (1): 110-6

Full text. e-Journal: <http://www.medassocthai.org/journal>

Varicella zoster virus (VZV) is one of the human DNA herpes viruses. Primary infection can cause chickenpox, an exanthematous disease, which usually occurs in childhood. VZV is a highly contagious infectious agent. Humans are the only known source. It is now evident that the disease is transmitted from person to person by direct contact with the vesicular fluid of the skin lesions or by secretions from the respiratory tract⁽¹⁾. The incubation period is 10 to 21 days. The most infectious period is usually 2 days before the onset of rash until the vesicles crust over, which take place 5 days after the onset of rash⁽²⁾. The prevalence of VZV infection in normal healthy Thai individuals ranged from 64.6 to 74.3%^(3,4). The increase in immune individuals was demonstrated with advancing age. The rate of maternal immunity to chickenpox is varied. Over 90% of pregnant women are immunized in the USA, while up to 50% remain susceptible in tropical countries⁽⁵⁾. There is strong correlation between a

reported history of chickenpox and serum immunity in pregnant women⁽⁶⁻⁹⁾.

Although uncommon in women of child-bearing age, varicella infection during pregnancy may lead to teratogenic effects to the fetus with potential serious sequelae to both the mother and the newborn. The true incidence of varicella infection in pregnancy is not known but it seems to reduce due to varicella vaccination programs in childhood and postpartum women⁽¹⁰⁾. This case is a pregnant woman who had primary VZV infection in the peripartum period with favorable outcome in both the mother and the neonate. The author will review the management of VZV exposure and infection in pregnancy and the newborn period.

Case Report

A 30-year-old woman, gravida 2, para 0, presented initially for prenatal care at 6 weeks of gestation. The first pregnancy was ended with spontaneous abortion. In this gestation, her antenatal care was uneventful. The routine serologic screenings were negative results. The obstetrics ultrasound scan was performed at 20 weeks of gestation. There was no abnormality detected. She was a previous healthy woman with no underlying disease. She had no history

Correspondence to : Pattanasuttinont S, Department of Obstetrics and Gynecology, HRH Maha Chakri Sirindhorn Medical Center, Faculty of Medicine, Srinakharinwirot University, 62, moo 7, Klong 16, Rangsit-nakornnayok road, Ongkharak district, Nakornnayok, 26120, Thailand. Phone: 037-395-085 ext 10803, Fax: 037-395-085 ext 10801 Mobile: 08-6511-4650 E-mail: sumate@swu.ac.th

of varicella infection in childhood. Before that time, she did not receive the varicella vaccination.

Until 38 weeks of gestation, she visited the antenatal clinic with a high-grade fever 2 days previously. She developed skin lesions distributed on her face and both forearms (Fig. 1). Lesions began as pruritic macules and progressed to papules and vesicles. The various stages in the same area of skin lesions were found. No respiratory symptoms were noted. She had been exposed to her friend who had chickenpox the week before. The diagnosis of primary varicella zoster infection was made on a clinical basis. The patient and her husband were counseled about the clinical course of disease, prognosis, mother to newborn transmission rate and the neonatal outcome. She was managed expectantly by prescribed anti-pyretics without antiviral agent and advised to observe her clinical symptoms at home. The fetal wellbeing was recorded daily. Three days later, she came to the labor room due to having clear fluid leakage from her vagina 14 hours previously. She had no labor pain or abnormal vaginal bleeding. She still had a high fever and new skin lesions had appeared on her abdomen. Her body temperature was 38°C, blood pressure 130/80 mmHg, pulse rate 102/min and respiratory rate 22/min. Physical examination showed generalized vesicular skin lesions on her face, trunk and extremities. The uterine fundus was \square above the umbilicus, no uterine contraction was detected. Otherwise were within normal limit. Speculum examination showed grossly amniotic fluid leak from

the uterine cervix. On the pelvic examination, the cervical opening was 1 centimeter and 90% of effacement. Induction of labor with intravenous oxytocin infusion was started. Fetal tachycardia was found from the continuous electric fetal monitoring. Two tablets of acetaminophen were given orally to diminish the febrile illness. Laboratory findings showed the following; complete blood count: hemoglobin 12.3 g/dL, hematocrit 37.2%, white blood count 9,600/mm³ (polymorphonuclear 83%, lymphocyte 12%, monocyte 3%, eosinophil 2%), platelet 187,000/mm³. Progression of labor was normal. Vacuum extraction was performed due to maternal exhaustion, thus the baby was delivered simultaneously. A normal male neonate weighed 3,240 g with Apgar scores 9 and 10 at 1 and 5 minutes, respectively. Physical examination revealed no skin lesions or evidence of central nervous system involvement. The baby was isolated from his mother in the neonatal intensive care unit. Varicella zoster immunoglobulin (VZIG) 125 u was given intramuscularly at 4 hours of life. The close observation of symptoms and signs of neonatal varicella was performed. The neonatal blood for varicella zoster IgM was negative result. There was no evidence of VZV infection until day 11th postpartum. The newborn had febrile illness followed by papules and vesicles appeared on his trunk. The intravenous acyclovir was started. The duration of treatment was 7 days. The diagnosis of neonatal varicella infection was made, but no severe complication was found.

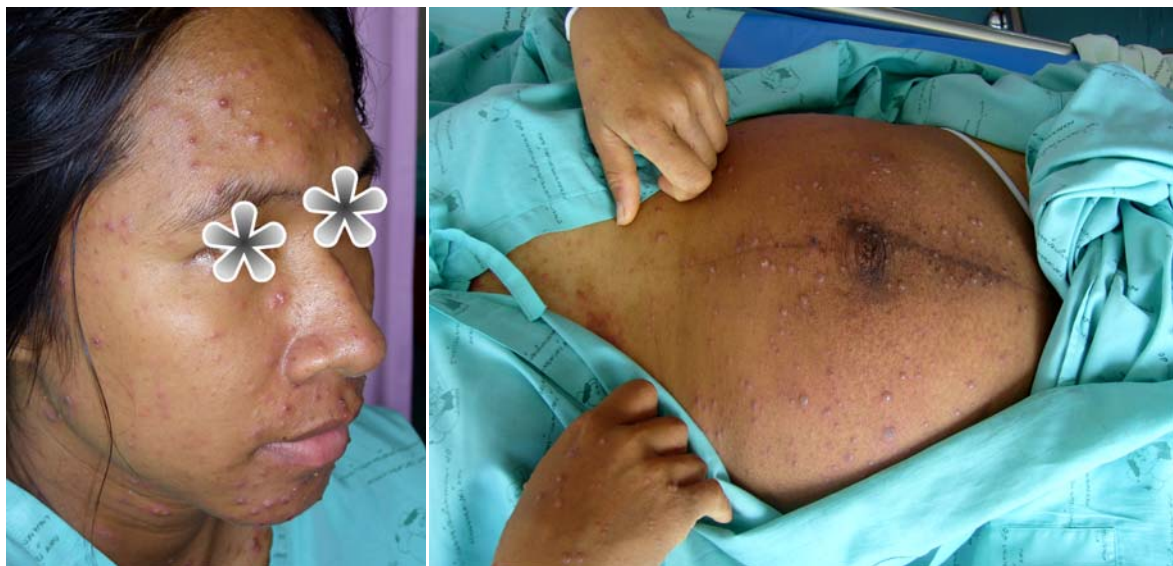

Fig.1 Pregnant woman with vesicular skin lesions at her face and abdomen

Maternal fever was gone within 2 days post-delivery. The vesicular skin lesions became crusted over and had no sign of secondary bacterial infection. There was no postpartum complication. She was not permitted to nurse her baby. Therefore, she continued to use a breast pump to collect breast milk for her baby. She was discharged home 6 days after her delivery. She and her baby were well throughout a 6-week period of follow-up.

Discussion

This is a case of success in expectant treatment of primary VZV infection in peripartum pregnant woman and prophylaxis use of VZIG in the newborn with favorable outcome. There are many controversial issues in the management of chickenpox in pregnancy that are waiting to be explored. However, chickenpox is not a serious illness in childhood but in pregnant

women, it can cause significant sequelae that are of public health concern. In Thailand, there is no national policy for the control of VZV infection especially in healthcare workers or pregnant women. This case was an example of failure to prevent VZV infection in pregnant women.

All women of childbearing age should be asked about their history of chickenpox. A positive history was a good predictor of immunity, but a negative history had no value as a predictor of susceptibility in adults⁽¹¹⁾. Women with no history can have serologic testing for varicella zoster IgG. If testing was done in the preconception period, women can be offered two doses of varicella vaccine at least 1 month apart. Pregnancy should be delayed 1 month after vaccination⁽¹²⁾. If blood test was done during pregnancy and found to be non-immune, pregnant women should be counseled to avoid exposure to chickenpox and to report exposure

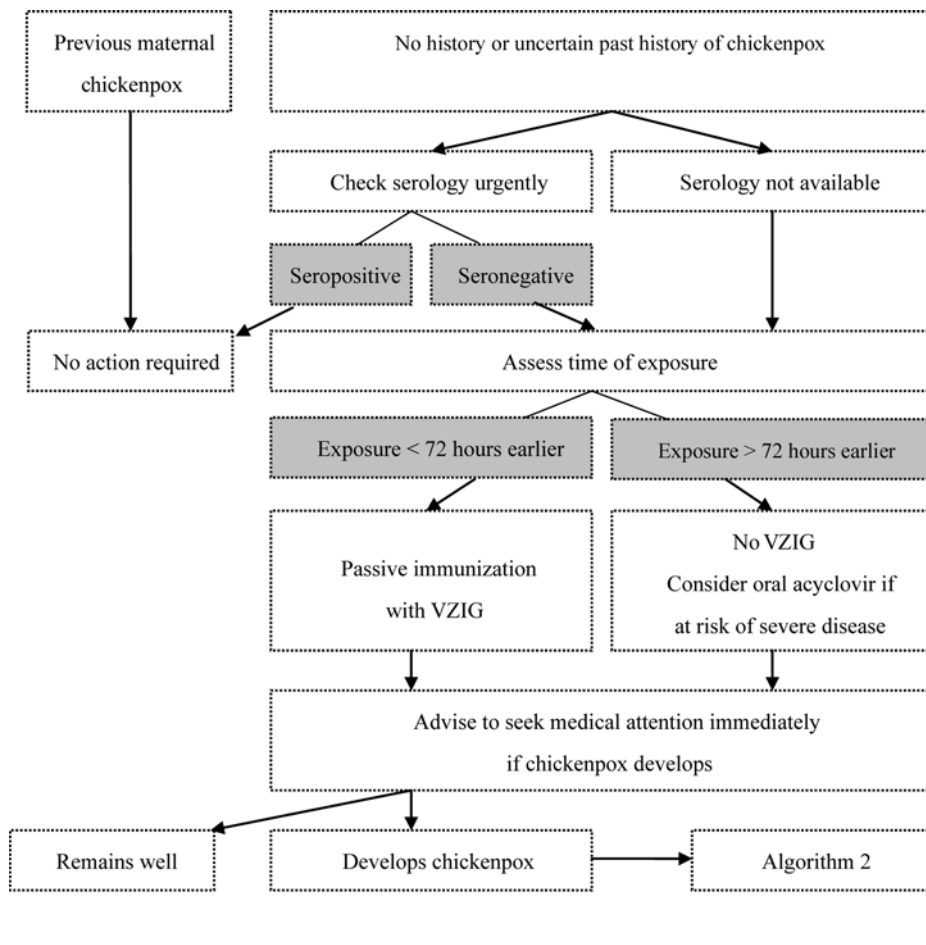


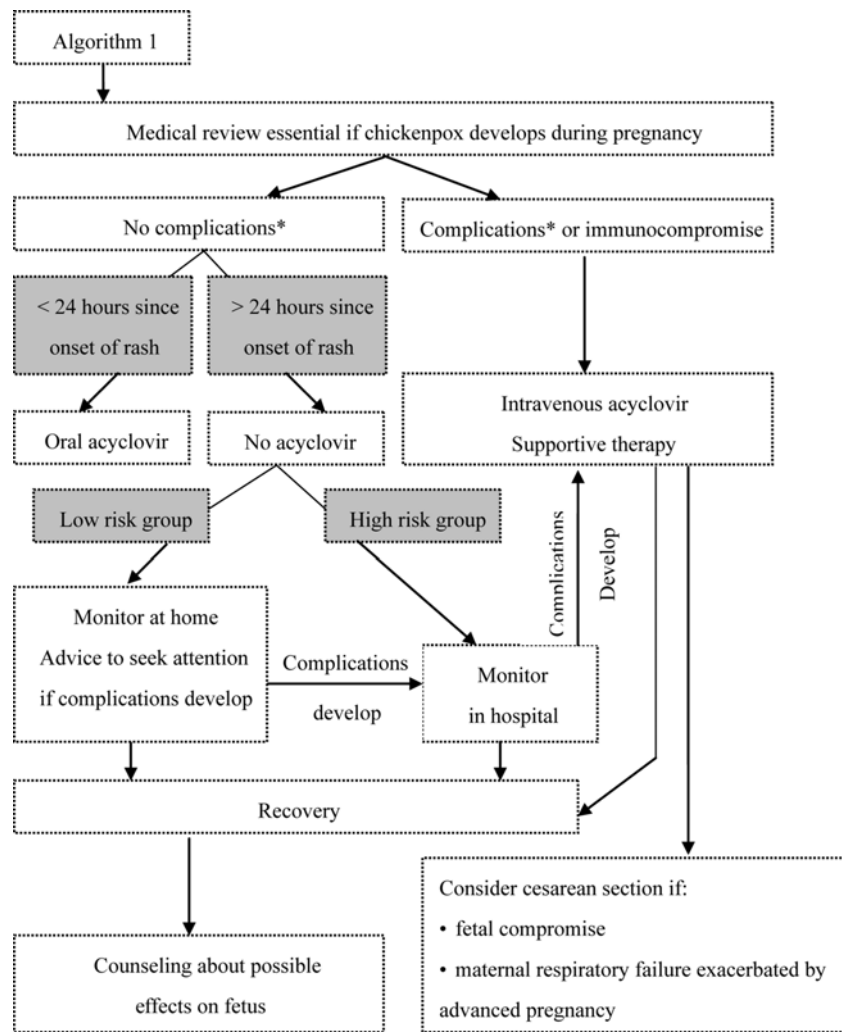
Fig. 2 Algorithm for the management of significant exposure to varicella zoster virus during pregnancy⁽¹⁴⁾

immediately. Mothers should receive varicella vaccine in the postpartum period with the second dose 4 to 8 weeks later⁽¹³⁾.

Susceptible pregnant women who have significant chickenpox exposure are candidates for VZIG therapy⁽¹⁴⁾. Post-exposure prophylaxis is recommended for those who do not have varicella immunity and who are likely to get severe varicella disease (Fig. 2). These include immunocompromised persons and pregnant women. VZIG is known to prevent or reduce the severity of chickenpox; it should be given within 72-96 hours. The recommended dose is 125 u/10 kg, up

to a maximum of 625 u or 5 vials, intramuscularly. VZIG is not indicated for pregnant women after varicella lesions develop.

In adults, the mortality and morbidity of primary VZV infection is greater than in children. The risk of adverse effects is greatest in the third trimester. If clinical illness develops in a mother, supportive care with fluids and analgesics is warranted. She should be observed for evidence of disseminated disease especially varicella pneumonitis. The administration of oral acyclovir within 24 hours of the onset of the rash could shorten the duration of illness (Fig. 3). There



* Complications: respiratory symptoms, hemorrhagic rash, persistent fever > 6 days, and new lesions developing > 6 days

Fig. 3 Algorithm for the management of chickenpox in pregnancy⁽¹⁴⁾

has been no sufficient evidence that treating pregnant women with acyclovir affects the course of fetal infection or reduces embryopathy⁽¹⁵⁾.

Chickenpox in the pregnant women during the first and second trimester can cause congenital varicella syndrome (CVS) with an incidence of 0.5 to 1.4%⁽¹⁶⁾. There are few case reports of CVS in the third trimester⁽⁵⁾. The CVS had been recovering in a newborn after maternal subclinical infection⁽¹⁷⁾. It shows that the severity of disease is not related to the occurrence of CVS. The pathogenesis of CVS is thought to be due to subsequent herpes-zoster reactivation in the uterus. The clinical features of the syndrome include cicatricial skin lesions, neurological and eye defects, limb hypoplasia, intrauterine growth retardation, and other manifestations. The mechanism of infection with VZV in utero is not known. During the viremic periods (days 4-6 and days 10-14), there may be transplacental transmission of the virus⁽¹⁸⁾. The second viremic period is thought to play a major role in fetal transmission. The prevention or amelioration of viremia with VZIG/acyclovir remains to be proven.

In late pregnancy, maternal varicella infection appears to be more virulent. They require contact isolation for at least 5 days after the onset of rash or until the vesicles have crusted over⁽¹⁹⁾. While the overall incidence of varicella pneumonia is not increased in pregnancy, mortality from maternal pneumonia was reported at 3-14% with the antiviral therapy^(20,21). Several risk factors have been identified for varicella pneumonia, including cigarette smoking, having greater than 100 skin lesions, history of chronic obstructive pulmonary disease, immunosuppression, history of household contact, and advanced gestational age⁽⁵⁾. The early symptoms are fever, dry cough, exertional dyspnea and mild hypoxemia. The mechanical respirator support is needed in severe conditions.

Other concern is that maternal varicella near term or immediately postpartum may lead to severe neonatal varicella. The increased peripartum severity is attributed to large transplacental inoculums of virus in the absence of protective maternal antibody. Disease may occur by ascending infection from the birth canal or direct contact with lesion during and after delivery. The timing of maternal infection in relation to delivery determines the risk to the infant⁽¹⁴⁾. If possible, delivery should be delayed until 5-7 days after the onset of maternal illness. Neonates born to mothers who contract chickenpox between 5 days before delivery and 2 days after delivery have a 17 to 30% chance of developing neonatal varicella⁽¹²⁾.

The severity of neonatal disease is dependent on the timing of maternal illness. The clinical illness typically develops within 5 to 10 days of delivery. Some infants have a rash, a cluster of skin lesions, and visceral involvement. The most common life-threatening complication is pneumonia. There was no death among babies who were given VZIG promptly. The baby should receive VZIG as early as possible after delivery, but must be within 72 hours. The recommended dose of the VZIG for the neonate is 125 u, intramuscularly⁽¹⁴⁾. Clinical follow up of infants is essential; approximately one-half of susceptible infants will acquire chickenpox despite VZIG therapy⁽¹⁹⁾. Intravenous acyclovir is commonly given to neonates showing signs of infection to prevent severe sequelae⁽²²⁾. The recommended intravenous dose for treating VZV infection is 10-15 mg/kg or 500 mg/m² every 8 hours for 7 days^(14,19). Routine acyclovir prophylaxis in conjunction with VZIG is not currently recommended in the neonatal population. In addition, there is no well-controlled study for prophylactic use of acyclovir for maternal varicella exposure near term or in exposed neonates to prevent neonatal varicella⁽²³⁾. Programs for preventing both maternal and fetal disease are the next step in management of varicella in pregnancy. Varicella vaccine may be an important and worthwhile solution to the problems of this disease, but it should not be given during pregnancy.

Conclusion

Pregnant women should be questioned about immunity to varicella during their first prenatal care. If they are in contact with individuals who have chickenpox, VZIG should be administered within 96 hours to prevent maternal infection. Neonatal varicella may occur as a result of infection in the peripartum period with an incidence of 17% to 30%. Varicella of the newborn is a life-threatening condition that may occur when a newborn is delivered within 5 days of the onset of maternal infection or after post-delivery exposure. Susceptible neonates should receive VZIG even with negative varicella zoster IgM. Close monitor should be extended to 14 days after delivery. Treatment with acyclovir is indicated in seriously ill adults and neonates.

References

1. Kido S, Ozaki T, Asada H, Higashi K, Kondo K, Hayakawa Y, et al. Detection of varicella-zoster virus (VZV) DNA in clinical samples from patients with VZV by the polymerase chain reaction. *J Clin*

- Microbiol 1991; 29: 76-9.
2. Centers for Disease Control and Prevention (CDC). A new product (VariZIG) for post exposure prophylaxis of varicella available under an investigational new drug application expanded access protocol MMWR Morb Mortal Wkly Rep 2006; 55: 209-10.
 3. Kowitdamrong E, Pancharoen C, Thammaborvorn R, Bhattarakosol P. The prevalence of varicella-zoster virus infection in normal healthy individuals aged above 6 months. *J Med Assoc Thai* 2005; 88(Suppl 4): S7-11.
 4. Bhattarakosol P, Chantarabul S, Pittayathikhun K, Mung-mee V, Punnarugsa V. Prevalence of anti-varicella zoster IgG antibody in undergraduate students. *Asian Pac J Allergy Immunol* 1996; 14: 129-31.
 5. Koren G. Congenital varicella syndrome in the third trimester. *Lancet* 2005; 366: 1591-2.
 6. Linder N, Ferber A, Kopilov U, Smetana Z, Barzilai A, Mendelson E, et al. Reported exposure to chickenpox: a predictor of positive anti-varicella-zoster antibodies in parturient women. *Fetal Diagn Ther* 2001; 16: 423-6.
 7. Holmes CN. Predictive value of a history of varicella infection. *Can Fam Physician* 2005; 51: 60-5.
 8. Alanen A, Kahala K, Vahlberg T, Koskela P, Vainionpaa R. Seroprevalence, incidence of prenatal infections and reliability of maternal history of varicella zoster virus, cytomegalovirus, herpes simplex virus and parvovirus B19 infection in South-Western Finland. *BJOG* 2005; 112: 50-6.
 9. Plourd DM, Austin K. Correlation of a reported history of chickenpox with seropositive immunity in pregnant women. *J Reprod Med* 2005; 50: 779-83.
 10. Bohlke K, Galil K, Jackson LA, Schmid DS, Starkovich P, Loparev VN, et al. Postpartum varicella vaccination: is the vaccine virus excreted in breast milk? *Obstet Gynecol* 2003; 102: 970-7.
 11. Vandersmissen G, Moens G, Vranckx R, de Schryver A, Jacques P. Occupational risk of infection by varicella zoster virus in Belgian healthcare workers: a seroprevalence study. *Occup Environ Med* 2000; 57: 621-6.
 12. Kirkham C, Harris S, Grzybowski S. Evidence-based prenatal care: part II. Third-trimester care and prevention of infectious diseases. *Am Fam Physician* 2005; 71: 1555-60.
 13. Campos-Outcalt D. Are you up to date with new immunization recommendations? *J Fam Pract* 2006; 55: 232-4.
 14. Heuchan AM, Isaacs D. The management of varicella-zoster virus exposure and infection in pregnancy and the newborn period. Australasian Subgroup in Paediatric Infectious Diseases of the Australasian Society for Infectious Diseases. *Med J Aust* 2001; 174: 288-92.
 15. Tan MP, Koren G. Chickenpox in pregnancy: revisited. *Reprod Toxicol* 2006; 21: 410-20.
 16. Harger JH, Ernest JM, Thurnau GR, Moawad A, Thom E, Landon MB, et al. Frequency of congenital varicella syndrome in a prospective cohort of 347 pregnant women. *Obstet Gynecol* 2002; 100: 260-5.
 17. Al Katawee YA, Al Hasoun YA, Taha MN, Al Moslem K. Congenital varicella-zoster virus infection. A rare case of severe brain and ocular malformations without limb or cutaneous involvement in a newborn after maternal subclinical infection. *Saudi Med J* 2005; 26: 869-71.
 18. Goldblatt D. The immunology of chickenpox. A review prepared for the UK Advisory Group on Chickenpox on behalf of the British Society for the Study of Infection. *J Infect* 1998; 36(Suppl 1): 11-6.
 19. Chapman SJ. Varicella in pregnancy. *Semin Perinatol* 1998; 22: 339-46.
 20. Lawal O, Nathan AT, Hartwell R, Dodd P. Varicella pneumonia complicating pregnancy. *J Obstet Gynaecol* 1997; 17: 166-7.
 21. Harger JH, Ernest JM, Thurnau GR, Moawad A, Momirova V, Landon MB, et al. Risk factors and outcome of varicella-zoster virus pneumonia in pregnant women. *J Infect Dis* 2002; 185: 422-7.
 22. Sauerbrei A, Wutzler P. Neonatal varicella. *J Perinatol* 2001; 21: 545-9.
 23. Mori T, Komori S, Fukuda Y, Naito S, Tanaka H, Koyama K. The primary varicella infection near term: a case report. *Arch Gynecol Obstet* 2003; 268: 128-30.

โรคอีสุกอีใสของมารดาในช่วงคลอด: รายงานผู้ป่วยและบททวนบทนิพนธ์

สุเมธ พัฒนาสุทธินนท์

หญิงตั้งครรภ์อายุ 30 ปี มีรอยโรคบริเวณผิวหนังขณะอายุครรภ์ 38 สัปดาห์ ได้รับวินิจฉัยว่ามีการติดเชื้อไวรัส varicella zoster ชนิดปฐมภูมิโดยมีไข้สูงและตุ่มน้ำใสตามบริเวณผิวหนังทั่วไป ไม่พบภาวะแทรกซ้อนที่รุนแรงในมารดา ผู้ป่วยคลอดบุตรชาย 4 วันหลังจากมีรอยโรคผิวหนัง การตรวจเลือดของทารกไม่พบภูมิคุ้มกันต่อเชื้อไวรัส varicella zoster ชนิดเอ็ม ทารกได้รับภูมิคุ้มกันต่อต้านเชื้อไวรัส varicella zoster ภายใน 24 ชั่วโมงแรก และคัดแยกในแผนกทารกแรกเกิด ทารกเริ่มมีรอยโรคผิวหนังในวันที่ 11 หลังคลอด และได้รับการฉีดยา acyclovir เข้าทางหลอดเลือดดำเป็นเวลา 7 วัน สุดท้ายทารกไม่มีอาการที่รุนแรงแต่อย่างใด
