

# Frontolateral Laryngectomy: Siriraj Experience

Piboon Sureepong MD\*,  
Choakchai Methetrairut MD\*

\* Department of OtoRhinoLaryngology, Faculty of Medicine Siriraj Hospital, Mahidol University, Bangkok, Thailand

**Objective:** To report the functional results and oncologic outcome of patients undergoing frontolateral laryngectomy in Siriraj Hospital.

**Material and Method:** A retrospective review of T1 and T2 glottic squamous cell carcinoma patients undergoing frontolateral laryngectomy in the department of Otolaryngology, Faculty of Medicine Siriraj Hospital between 1986 and 2006 with a minimum of five years follow-up period.

**Results:** Out of 55 patients who underwent frontolateral laryngectomy, 50 cases that fitted the criteria were recruited for the present study. After surgery, all patients but one had tracheotomy decannulation and recovered good respiratory function. Forty-three successfully decannulated patients (87.8%) had tube decannulation within 14 days. The mean duration of feeding via nasogastric tube was 11.4 days (ranged from 5 to 22 days). Forty-eight patients (96%) resumed oral feeding before discharge from the hospital and all but two had grade 1 subjective functional speech during hospitalization. The one, three, and five years overall survival rate in our study were 98%, 92%, and 92%, respectively. The 5-year tumor control rate was 97.1% for T1 and 75% for T2 tumors. The larynx preservation rate was 90%.

**Conclusion:** Frontolateral laryngectomy is one of the excellent therapeutic options for treatment of T1 and T2 glottic cancer, especially those with anterior commissure involvement. It conserves reasonable laryngeal function with short hospitalization. Its local tumor control rate was above other treatment modalities and the survival rates were impressive.

**Keywords:** Frontolateral laryngectomy, Early glottic cancer, Functional results and oncologic outcome

*J Med Assoc Thai* 2014; 97 (8): 841-9

Full text. e-Journal: <http://www.jmatonline.com>

Early glottic cancer is categorized as T1N0M0 or T2N0M0 according to the American Joint Committee on Cancer (AJCC) criteria. It is generally agreed that the prognosis of early-stage glottic carcinoma is excellent, but some controversial issue persists regarding treatment options. Recent treatment modalities include external radiotherapy (RT), endoscopic laser excision, and conventional open surgery such as laryngofissure, frontolateral laryngectomy, or supracricoid laryngectomy. All these therapeutic options demonstrate comparable oncologic outcome as well as functional voice preservation in general<sup>(1-3)</sup>.

A differentiation should be addressed between T1a, T1b, and T2 tumors since a diverse group of lesions responds differently to treatment<sup>(4-6)</sup>. T1 tumors confined to the membranous portion of the vocal cord respond well to primary radiation, which is considered the treatment of choice by many clinicians<sup>(4,5,7-10)</sup>. However, when tumor extends beyond the membranous

vocal cord to the anterior commissure or arytenoids, or had supraglottic or subglottic extension with restricted cord mobility, the risk of recurrence after radiotherapy is significantly increased<sup>(5,8-13)</sup>. In T1 glottic cancer, 50% of radiotherapy failures occurred at the anterior commissure<sup>(14)</sup>, and in T2 tumors, the local failure rate after RT is 32%, whereas surgical salvage would improve tumor control rate up to 94%<sup>(15)</sup>. In T1 lesions with and without anterior commissure involvement, the 5 years local control rates after treatment by primary radiotherapy are 84% and 94%, respectively; whereas in T2 lesions with and without impaired vocal cord mobility, the 5 years local control rate are 23% and 94%<sup>(5)</sup>.

Endoscopic laser excision is also a novel treatment modality for early glottic cancer. It leads to an excellent oncologic outcome and good functional voice preservation for membranous cord lesion comparable to external radiation<sup>(16-19)</sup>. Massive or infiltrative tumor at the anterior commissure region will also result in high rate of tumor recurrence after laser microsurgery due to either inadequate tumor exposure during surgery leading to incomplete excision or surgeon expertise in transoral laser microsurgery (TLM)<sup>(20-22)</sup>.

**Correspondence to:**

Methetrairut C, Department of Otorhinolaryngology, Siriraj Hospital, 2 Phrannok Road, Bangkoknoi, Bangkok 10700, Thailand.  
Phone: 0-2419-8040, Fax: 0-2419-8044  
E-mail: choakchai\_m@yahoo.com

Frontolateral laryngectomy is another effective therapeutic option for early glottic cancer. It offers better local control rates especially for lesions involving the anterior commissure and those with impaired cord morbidity<sup>(21)</sup>. The aim of the present study is to review the functional results and oncologic outcome of patients undergoing frontolateral laryngectomy in T1 involving anterior commissure and T2 glottic cancer from our hospital.

### **Material and Method**

Medical records of patients with glottic squamous cell carcinoma who had undergone frontolateral laryngectomy in the laryngology clinic, Department of Otolaryngology, Faculty of Medicine Siriraj Hospital, Mahidol University between 1986 and 2006 were reviewed to evaluate the immediate postoperative laryngeal function and demonstrate the comparable oncologic outcome from this surgical technique. All patients were diagnosed as having glottic squamous cell carcinoma by tissue biopsy and had tumor assessment with direct laryngomicrosurgery under general anesthesia. Frontolateral laryngectomy was indicated in those who had tumor extending beyond membranous vocal cord to the anterior commissure and/or vocal process of arytenoids with or without contralateral cord minimal involvement (less than 1/3) in T1 or had supra or subglottic invasion with normal or limited vocal folds movement in T2. All patients were periodically followed-up in the laryngology out-patient clinic for a minimum of five years after surgery.

For postoperative functional results, laryngeal functions such as phonation, respiration, and deglutition were assessed for all patients in the first postoperative week. The patient's speech was graded (after decannulation) as grade 1 (excellent subjective speech), grade 2 (communication with voice primarily), grade 3 (occasional word or syllable produced), and grade 4 (requires lip reading to understand sounds). The timing for successful decannulation was also recorded to confirm their ability of non-tracheotomy-dependent breathing. As soon as the tracheotomy tube was removed, patients were encouraged to swallow thick soft diet to evaluate their swallowing function. Those who were unable to tolerate aspiration would then be fed by nasogastric (NG) tube feeding or gastrostomy. Meanwhile, different type of diets such as regular, thick soft, or liquid diet was advised to evaluate their swallowing progression. Aspiration was graded as grade 1 (mild and rare aspiration, less than three times

a day), grade 2 (occasional aspiration, more than three times a day), grade 3 (persistent aspiration) and grade 4 (aspiration that lead to lungs complication such as pneumonia).

For oncologic outcomes, all patients were regularly followed for at least five years on a monthly basis in the first year, bimonthly in the second year, quarterly in the third year and biannually thereafter. Patients' well-being, delayed postoperative complication, and tumor recurrence were monitored. The tumor control rate, tumor free survival rate, laryngeal preservation rate, and overall five years survival rate for this group of patients were estimated.

### **Results**

Fifty-five patients underwent frontolateral laryngectomy in our department of Otolaryngology between 1986 and 2006. Only 50 patients met the criteria and were recruited for the present study. Three excluded cases were patients with non-squamous cell carcinoma that also had verrucous carcinoma, adenocarcinoma, or mucoepidermoid carcinoma. One patient, at the time of surgery, had stage III cancer and was therefore excluded from the present study. One T1b patient had frontolateral laryngectomy initially performed but the surgery was converted to supracricoid laryngectomy as soon as positive margin had been reported. Forty-seven patients were male and three were female. The mean age was 59.4 years (range: 36 to 80 years). Thirty-one cases were classified as T1aN0M0, three cases as T1bN0M0, and 16 cases as T2N0M0. Among those patients, ten (20%) underwent extended frontolateral laryngectomy with partial or total arytenoid removal. After tumor resection, most laryngeal defects were reconstructed with sternohyoid bipedical muscle flap. Epiglottic flap reconstruction was applied only to one case (Table 1). Pathological positive or uncertain resection margin was reported in four patients. Three cases were diagnosed as T2N0M0 tumors. The only T1N0M0 case that had positive margin had tumor at the anterior commissure. All cases with positive margin received additional postoperative radiotherapy for salvage treatment. However, three other cases that had cellular dysplasia or atypia at the margin also had postoperative radiotherapy due to physician preference or concerns.

### **Functional outcome**

Of all 50 patients who underwent frontolateral laryngectomy, 49 cases (98%) had tracheotomy tube decannulated successfully after surgery. The duration

**Table 1.** Demographic data for frontolateral laryngectomy patients (n = 50)

Patient characteristics	Number (%)
Sex	
Male	47 (94)
Female	3 (6)
Age (years)	
Range	36-80
Mean	59.4
Tumor	
T1aN0M0	31 (62)
T1bN0M0	3 (6)
T2N0M0	16 (32)
Type of laryngectomy	
Frontolateral laryngectomy	40 (80)
Extended frontolateral laryngectomy	10 (20)

of tracheotomy decannulation ranged from five to 510 days with the median duration of nine days. The only case that did not have successful decannulation involved T2 glottic cancer with positive surgical margin after tumor resection. This patient received additional postoperative RT treatment and suffered endolaryngeal persistent edema problem so that extubation was impossible. He later developed radiochondronecrosis and died from infection 15 months later.

In the group of successfully decannulated patients, 43 patients (87.8%) had tracheotomy decannulation within the first 14 days after surgery with an average duration of 8.8 days, and those delayed decannulation patients (n = 6) had successful extubation with the median duration of 139 days, (duration ranged from 120 to 510 days). Among the latter group, three patients (2 of T2N0M0 and 1 of T1N0M0 cases) had underwent extended frontolateral laryngectomy with partial or total arytenoid removal and encountered inadequate initial airway due to mucosal edema; decannulation had to be postponed until 17, 19, and 73 weeks post-operatively. Two patients underwent classical frontolateral laryngectomy with positive histological margin obtained additional postoperative RT, and extubation was successful at the end of the 20<sup>th</sup> and 22<sup>nd</sup> weeks after surgery. One T1N0M0 patient with previous RT failure underwent frontolateral laryngectomy for salvage treatment and developed postoperative wound infection and persistent laryngeal mucosal edema. His decannulation was delayed until 32 weeks after surgery.

For postoperative deglutition function, most patients (n = 48) could resume thick soft diet

swallowing well, except for one who had minute aspiration (grade 2) that lasted 60 days after NG tube removal. The patient who had previous RT failure and had difficult decannulation also encountered persistent aspiration (grade 3). Therefore, permanent gastrostomy tube was needed. The mean duration of nasogastric tube removal for most patients was 11.4 days (ranged from 5 to 22 days). The number of patients who were able to swallow thick soft diet before discharge was 48 (96%).

For phonatory function after surgery, 48 patients were evaluated subjectively as grade 1 speech immediately after successful decannulation, whereas two cases had some difficulty in voice phonation and were classified as grade 2.

Immediate postoperative complication by this surgical technique was low. Among them, one had wound infection and one had postoperative pneumonia. However, one patient who had postoperative RT salvage developed radiochondronecrosis as late complication. The mean hospitalization period for frontolateral laryngectomy patients was 20.7 days (ranged from 11 to 56 days). The only patient who had failed previous primary radiotherapy suffered postoperative wound infection and persistent laryngeal edema. Due to delayed tracheotomy decannulation and severe aspiration needing gastrostomy, his hospitalization period was 441 days.

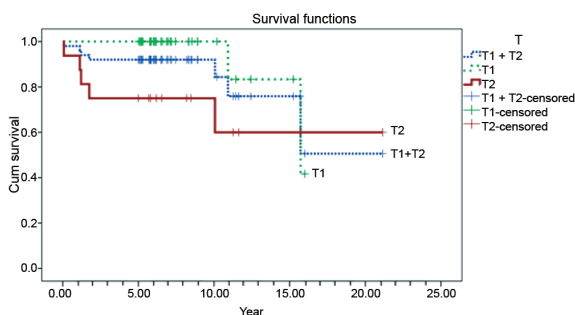
#### ***Oncologic outcome***

All patients were followed-up for at least five years with the median of seven years 11 months (ranged from five years two months to 21 years). Ten patients (20%) in the present study developed either local or locoregional recurrence including five patients (10%) that had recurrence within five years. In those 10 patients, eight had recurrence at the larynx (three cases occurred within five years and five had local recurrence after five years) and two developed neck metastasis. In the group experiencing laryngeal recurrence, five obtained definite radiation and all had good tumor control after salvage treatment except for one who had developed lung metastasis 7.3 years post radiation and died subsequently. Two patients received both total laryngectomy and postoperative radiation as salvage treatment, and all were alive without tumor recurrence. One who had laryngeal recurrence 3.5 years after frontolateral laryngectomy underwent total laryngectomy for salvage treatment. This patient had repeated relapsing tumor 11.5 years later and died from the tumor. In the group with neck metastasis, both

T2N0M0 tumor patients had positive surgical margin and receipt RT for salvage. One developed neck recurrence 15 months later and the other developed recurrence at larynx and neck seven months post-operation. Both of them died from tumor following palliative treatment (Table 2).

Therefore, the larynx preservation rate in the present study was 90% (n = 45) and the 5-year tumor control rate for T1N0M0 patients was 97.1% (33/34) and 75% (12/16) for T2N0M0 patients. The overall 5-year tumor control rate was 92% (n = 46).

Seven patients (14%) died before the last follow-up in February 2012. Causes of death were shown in Table 3. Kaplan-Meier analysis (as demonstrated in Fig. 1) revealed the 1, 3, and 5-year overall survival rate for frontolateral laryngectomy to be 98, 92, and 92% respectively. When patients were categorized by tumor staging, the 5-years actuarial survival of patients with T1 and T2 laryngeal lesions after frontolateral laryngectomy were 100 and 75%, respectively ( $p = 0.032$ ). The 5-year cause specific survival rate for T2N0M0 after surgery was 87.5%.



**Fig. 1** Kaplan-Meier survival curve for frontolateral laryngectomy in T1, T2 glottic cancer and the overall survival rate.

### Discussion

Early glottic (T1, T2) cancer comprises of a wide spectrum of lesions ranged from a small midcordal lesion, entire unilateral vocal cord lesion with anterior commissure and/or vocal process of arytenoids extension to bicordal full length horseshoe lesions in T1 tumor and those tumor that had ventricular fold or subglottic extension with normal or limited vocal cord movement in T2. Although it is generally accepted that modern treatments for this early cancer

**Table 2.** Local and locoregional recurrence (n = 10)

	Local recurrence	Locoregional recurrence	Salvage Rx	Results
Within 5-year				
T1N0M0	1	-	TLG + RT	Tumor free
T2N0M0	2	2	RT for 1° (2) Palliation for locoregional (2)	Tumor free (1), lungs metastasis (1) Death from tumor (2)
After 5-year				
T1N0M0	3	-	TLG (1) RT (2)	Stomal recurrence and death (1) Tumor free (2)
T2N0M0	2	-	TLG + RT (1) RT (1)	Tumor free (1) Tumor free (1)
Total	8	2		

TLG = total laryngectomy; RT = radiotherapy

**Table 3.** Causes of death after frontolateral laryngectomy (n = 7)

Causes of deaths	Within 5-year		After 5-year
	T2 tumor	T1 tumor	T2 tumor
Tumor - related deaths:			
Local recurrence	-	1	-
Neck recurrence	2	-	-
Distant metastasis	-	-	1
Intercurrent disease	1	1	-
Radiochondronecrosis/wound infection	1	-	-
Total	4	2	1

yield comparable functional and oncologic outcomes, the results of treatment are different to the diversified location or TNM staging.

Anterior commissure constitutes a thin mucosa with the absence of inner perichondrium over thyroid cartilage extending from the caudal end of the epiglottis to the proximity of the cricothyroid membrane. At the anterior end of vocal cords, it is replaced by Broyle's ligament, which is tightly adhered to thyroid cartilage. Tumor in this region can spread either to supraglottic or subglottic direction or may extend superficially in posterior direction to involve one or both vocal cords. In some patients, it may be localized and appear a small ulcerating or infiltrating lesion only. Due to early laryngeal ossification, deep infiltrated tumor through thyroid cartilage in anterior commissure region may be difficult to be delineated even with CT scan or MRI. Moreover, poor exposure or underexposure during endoscopy to this region will result in tumor down staging and incomplete excision during surgery, leading to high rate of recurrence. Therefore, the anterior commissure is considered a risk zone for tumor control by various treatment options<sup>(6,18,22-25)</sup>.

Radiotherapy is considered the treatment of choice for lesions mostly confine to membranous vocal cord with normal vocal cord movement. Biller et al indicated that glottic carcinoma with tumor extension beyond the membranous vocal cords are difficult to cure with RT<sup>(26,27)</sup>. The tumor control rate with primary radiotherapy in early glottic cancer in most studies ranged from 72 to 92%. For T1 tumor, it achieved a very satisfactory tumor control result of 85 to 90% but only 70 to 75% for T2 tumor<sup>(10,17,24,28-31)</sup>. The impact of anterior commissure involvement will result in higher rate of tumor recurrence<sup>(5,12,21,22,28,30)</sup> and surgical salvage is recommended for radiation failure<sup>(8,15)</sup>. Although radiotherapy can preserve the highest voice quality in patients, it may associate with debilitating complication such as radiochondronecrosis, mucosal radiation damage, and long-term side effects of xerostomia and prolonged duration (six to seven weeks) of treatment<sup>(28-32)</sup>.

TLM is a minimally invasive surgical treatment option for T1 and T2 glottic cancer. Excessive laryngeal mucosa scar can be avoided during surgery resulting in excellent phonetic function postoperatively<sup>(16-18)</sup>. Furthermore, it can be performed as an outpatient service, and tracheotomy or nasogastric tube insertion is unnecessary. TLM under experienced surgeons with advanced surgical

skill and proper instrument will provide an excellent oncologic result with the tumor control rate of 75 to 90%<sup>(17,18,21,22,28,33,34)</sup>. Many investigators concluded that in early glottic cancer treating with TLM, significant reduction of local tumor control has been associated the tumor involvement at the anterior commissure<sup>(21,22,30)</sup>. The 5-year local control rates for T1a tumor with or without anterior commissure involvement are 80% and 90%, 70% and 85% for T1b, and both 76% for T2, respectively<sup>(20-22)</sup>.

Frontolateral laryngectomy was first described by Leroux-Robert in 1948<sup>(24,35)</sup> and was popular in Europe in the 1970s<sup>(24)</sup>. The en-bloc resection of the involved larynx and immediate reconstruction by bipedicle sternohyoid muscle flap will create an impressive oncologic control and preserve most laryngeal functions. Most patients in the present study (87.8%) recovered good respiratory function within 14 days after surgery. Factors causing difficult decannulation in the present study were inadequate airway after extensive resection in extended frontolateral laryngectomy, mucosal edema due to previous or additional postoperative RT, and wound infection. Ninety-six percent of the patients resumed oral feeding with minute or no aspiration during hospitalization. For patients who failed RT and needed surgical salvage, this surgical technique is considered not suitable for salvage treatment as the unhealthy exposed cartilage after resection is prone to infection and developed persistent mucosal edema, which will lead to severe aspiration and delayed tracheotomy decannulation after surgery. Total laryngectomy is usually recommended by many authors<sup>(4,19,27)</sup>. Frontolateral partial laryngectomy is also safe with low complication rate<sup>(36)</sup>. The only severe late complication in the present series was radiochondronecrosis that occurred in a patient who obtained additional postoperative RT due to pathological positive margin. Radiochondronecrosis could be avoided by careful intraoperative specimen inspection by frozen section.

Although frontolateral laryngectomy may yield voice quality inferior to RT or laser microsurgery in comparison, it demonstrates a better tumor control capability especially at the anterior commissure region. The local recurrence rate following vertical partial laryngectomy from many studies varied from 2 to 17% in T1 and 4 to 25% in T2 tumor<sup>(6,26,37,38)</sup>. To reduce local recurrence in early glottic cancer with anterior commissure involvement, Bridger and Nasser had advised a wide subglottic surgical margin<sup>(6,39)</sup>. In the present study's result, 10 patients had recurrence

occurred over the entire period of follow-up. However, the 5-year tumor control rate was 97% in T1, and 75% in T2 tumor, which was similar to those reports in the literature. Million and Cassisi had mentioned in their book that the success rate for radiotherapy salvage in recurrence or residual tumor after partial laryngectomy was only 50% and surgery was recommended<sup>(36,40)</sup>. Among our recurrent cases, the larynx can be preserved by RT salvage for 55.6%, and therefore, the overall laryngeal preservation rate was 90% and in concordance with other studies as well<sup>(21,25,30)</sup>.

The 5-year survival rate after frontolateral laryngectomy is another indicator that proves that the technique is effective. In most studies, the 5-year survival rate after surgery for T1 is 91% and 86% for T2 tumor<sup>(4)</sup>, whereas the 5-year survival rate in RT is 85 to 92% for T1 and 71 to 78% for T2 tumor<sup>(11,31)</sup>. For the TLM option, the 5-year survival rate range from 81 to 93%<sup>(17,21)</sup>. All patients in the present study were followed in outpatient special clinic for a minimum of five years, and the 1, 3, and 5-year overall survival rate after frontolateral laryngectomy was 98, 92, and 92%, respectively, and the 5-years overall survival rates was 100% in T1N0M0 patients, and 75% for T2N0M0.

In addition to early glottic cancer, this surgical technique has recently been applied to include selected T3 glottic cancer by some surgeons for patient's better quality of life<sup>(1,36,41-44)</sup>, and a variety of modified partial laryngectomy and reconstruction technique had been proposed to improve the voice quality after tumor resection<sup>(4,23,24,26,27,32,35,36)</sup>.

## Conclusion

Frontolateral laryngectomy is one of the therapeutic options for treatment of T1 and T2 glottic cancer. It conserves reasonable laryngeal function with shorter hospitalization. Its local tumor control rate was comparable to other options and the survival rates were impressive.

## What is already known on this topic?

Frontolateral laryngectomy is one of the conservation surgery for early glottic cancer. Its functional results and oncologic outcome after surgery is comparable to other treatment options. However, when tumor approaches the anterior commissure, which is considered a dangerous zone, the tumor control rate after primary radiotherapy or endoscopic laser surgery is controversial.

## What this study adds?

As primary radiation is not widely accessible in Thailand and the treatment requires prolonged hospitalization or hospital visits. Frontolateral laryngectomy is another option for early glottic cancer patients and it is confirmed by the present study that it has reliable postoperative laryngeal functions and acceptable tumor control results. This surgical technique should be applied instead of radiotherapy to those T1 or T2 glottic cancer especially with anterior commissure involvement. It is not suitable to apply this technique as salvage treatment for those who failed primary radiotherapy since postoperative severe complication will be encountered and total laryngectomy is recommended.

## Acknowledgement

The authors would like to thank Jeerapa Kerdnoppakhun and Janchai Sanit for manuscript assistance, and also Dr. Jeerasook Chongkolwattana and Dr. Phawin Keschool for their cases support in the present study.

## Author's contribution

CM - Project design, data analysis, manuscript preparation, and editing

PS - Project co-design, data collection, literature reviews, and manuscript editing

All authors read and approved the final manuscript.

## Potential conflicts of interest

None.

## References

1. Mercante G, Grammatica A, Battaglia P, Cristalli G, Pellini R, Spriano G. Supracricoid partial laryngectomy in the management of t3 laryngeal cancer. *Otolaryngol Head Neck Surg* 2013; 149: 714-20.
2. Daly JF, Kwok FN. Laryngofissure and cordectomy. *Laryngoscope* 1975; 85: 1290-7.
3. Olsen KD, Thomas JV, DeSanto LW, Suman VJ. Indications and results of cordectomy for early glottic carcinoma. *Otolaryngol Head Neck Surg* 1993; 108: 277-82.
4. Giovanni A, Guelfucci B, Gras R, Yu P, Zanaret M. Partial frontolateral laryngectomy with epiglottic reconstruction for management of early-stage glottic carcinoma. *Laryngoscope* 2001; 111: 663-8.

5. Burke LS, Greven KM, McGuirt WT, Case D, Hoen HM, Raben M. Definitive radiotherapy for early glottic carcinoma: prognostic factors and implications for treatment. *Int J Radiat Oncol Biol Phys* 1997; 38: 1001-6.
6. Laccourreye O, Weinstein G, Brasnu D, Trotoux J, Laccourreye H. Vertical partial laryngectomy: a critical analysis of local recurrence. *Ann Otol Rhinol Laryngol* 1991; 100: 68-71.
7. Mendenhall WM, Parsons JT, Stringer SP, Cassisi NJ, Million RR. T1-T2 vocal cord carcinoma: a basis for comparing the results of radiotherapy and surgery. *Head Neck Surg* 1988; 10: 373-7.
8. Lederman M. Place of radiotherapy in treatment of cancer of the larynx. *Br Med J* 1961; 1: 1639-46.
9. Lederman M. Radiotherapy of cancer of the larynx. *J Laryngol Otol* 1970; 84: 867-96.
10. Boles R, Komorn R. Carcinoma of the laryngeal glottis: a five-year review at a university hospital. *Laryngoscope* 1969; 79: 909-20.
11. Dagan R, Morris CG, Bennett JA, Mancuso AA, Amdur RJ, Hinerman RW, et al. Prognostic significance of paraglottic space invasion in T2N0 glottic carcinoma. *Am J Clin Oncol* 2007; 30: 186-90.
12. Nozaki M, Furuta M, Murakami Y, Izawa Y, Iwasaki N, Takahashi H, et al. Radiation therapy for T1 glottic cancer: involvement of the anterior commissure. *Anticancer Res* 2000; 20: 1121-4.
13. Dickens WJ, Cassisi NJ, Million RR, Bova FJ. Treatment of early vocal cord carcinoma: a comparison of apples and apples. *Laryngoscope* 1983; 93: 216-9.
14. Rothfield RE, Myers EN, Johnson JT. Carcinoma in situ and microinvasive squamous cell carcinoma of the vocal cords. *Ann Otol Rhinol Laryngol* 1991; 100: 793-6.
15. Howell-Burke D, Peters LJ, Goepfert H, Oswald MJ. T2 glottic cancer. Recurrence, salvage, and survival after definitive radiotherapy. *Arch Otolaryngol Head Neck Surg* 1990; 116: 830-5.
16. Spielmann PM, Majumdar S, Morton RP. Quality of life and functional outcomes in the management of early glottic carcinoma: a systematic review of studies comparing radiotherapy and transoral laser microsurgery. *Clin Otolaryngol* 2010; 35: 373-82.
17. Lee HS, Chun BG, Kim SW, Kim ST, Oh JH, Hong JC, et al. Transoral laser microsurgery for early glottic cancer as one-stage single-modality therapy. *Laryngoscope* 2013; 123: 2670-4.
18. Pham TA, De Freitas R, Sigston E, Vallance N. Factors leading to the use of alternate treatment modalities following transoral laser excision of T1 and T2 glottic squamous cell carcinoma. *ANZ J Surg* 2012; 82: 720-3.
19. Huang J, Yu Z, Fang J, Chen X, Chen X, Huang Z. Salvage transoral laser microsurgery for early recurrent glottic carcinoma after primary laser treatment. *Acta Otolaryngol* 2013; 133: 531-7.
20. Hakeem AH, Tubachi J, Pradhan SA. Significance of anterior commissure involvement in early glottic squamous cell carcinoma treated with trans-oral CO2 laser microsurgery. *Laryngoscope* 2013; 123: 1912-7.
21. Steiner W, Ambrosch P, Rodel RM, Kron M. Impact of anterior commissure involvement on local control of early glottic carcinoma treated by laser microresection. *Laryngoscope* 2004; 114: 1485-91.
22. Rodel RM, Steiner W, Muller RM, Kron M, Matthias C. Endoscopic laser surgery of early glottic cancer: involvement of the anterior commissure. *Head Neck* 2009; 31: 583-92.
23. Alicandri-Ciufelli M, Molteni G, Mattioli F, Bergamini G, Tassi S, Monzani D, et al. Horizontal glottectomy: is it an out-of-date procedure? *Am J Otolaryngol* 2011; 32: 578-82.
24. Dispenza F, Saraniti C, Mathur N, Dispenza C. Modified fronto-lateral laryngectomy in treatment of glottic T1(a-b) cancer with anterior commissure involvement. *Auris Nasus Larynx* 2010; 37: 469-73.
25. Hartl DM, Landry G, Hans S, Marandas P, Casiraghi O, Janot F, et al. Thyroid cartilage invasion in early-stage squamous cell carcinoma involving the anterior commissure. *Head Neck* 2012; 34: 1476-9.
26. Biller HF, Ogura JH, Pratt LL. Hemilaryngectomy for T2 glottic cancers. *Arch Otolaryngol* 1971; 93: 238-43.
27. Biller HF, Som ML. Vertical partial laryngectomy for glottic carcinoma with posterior subglottic extension. *Ann Otol Rhinol Laryngol* 1977; 86: 715-8.
28. Jones DA, Mendenhall CM, Kirwan J, Morris CG, Donnan A, Holwerda S, et al. Radiation therapy for management of t1-t2 glottic cancer at a private practice. *Am J Clin Oncol* 2010; 33: 587-90.
29. Laskar SG, Bajjal G, Murthy V, Chilukuri S, Budrukkar A, Gupta T, et al. Hypofractionated radiotherapy for T1N0M0 glottic cancer: retrospective analysis of two different cohorts of dose-fractionation schedules from a single

- institution. *Clin Oncol (R Coll Radiol)* 2012; 24: e180-e186.
30. Marshak G, Brenner B, Shvero J, Shapira J, Ophir D, Hochman I, et al. Prognostic factors for local control of early glottic cancer: the Rabin Medical Center retrospective study on 207 patients. *Int J Radiat Oncol Biol Phys* 1999; 43: 1009-13.
  31. Nomiya T, Nemoto K, Wada H, Takai Y, Yamada S. Long-term results of radiotherapy for T1a and T1bN0M0 glottic carcinoma. *Laryngoscope* 2008; 118: 1417-21.
  32. Lei WB, Jiang AY, Chai LP, Zhu XL, Wang ZF, Wen YH, et al. Middle frontal horizontal partial laryngectomy (MFHPL): a treatment for stage T1b squamous cell carcinoma of the glottic larynx involving anterior vocal commissure. *PLoS One* 2013; 8: e52723.
  33. Lallemand B, Chambon G, Garrel R, Kacha S, Rupp D, Galy-Bernadoy C, et al. Transoral robotic surgery for the treatment of T1-T2 carcinoma of the larynx: preliminary study. *Laryngoscope* 2013; 123: 2485-90.
  34. Lucioni M, Bertolin A, Rizzotto G, Accordi D, Giacomelli L, Marioni G. CO(2) laser surgery in elderly patients with glottic carcinoma: univariate and multivariate analyses of results. *Head Neck* 2012; 34: 1804-9.
  35. Dong P, Li X, Xie J, Li L, Xu H. Modified frontolateral partial laryngectomy without tracheotomy. *Otolaryngol Head Neck Surg* 2009; 141: 70-4.
  36. Daniilidis J, Nikolaou A, Fountzilias G, Sombolos K. Vertical partial laryngectomy: our results after treating 81 cases of T2 and T3 laryngeal carcinomas. *J Laryngol Otol* 1992; 106: 349-52.
  37. Rucci L, Gallo O, Fini-Storchi O. Glottic cancer involving anterior commissure: surgery vs radiotherapy. *Head Neck* 1991; 13: 403-10.
  38. Sessions DG, Ogura JH, Fried MP. The anterior commissure in glottic carcinoma. *Laryngoscope* 1975; 85: 1624-32.
  39. Bridger GP, Nassar VH. Cancer spread in the larynx. *Arch Otolaryngol* 1972; 95: 497-505.
  40. Million RR, Cassisi NJ. Larynx. In: Million RR, Cassisi NJ, editors. *Management of head and neck cancer. A multi-disciplinary approach*. Philadelphia: JB Lippincott; 1984: 316-64.
  41. Harwood AR, Beale FA, Cummings BJ, Keane TJ, Rider WD. T2 glottic cancer: an analysis of dose-time-volume factors. *Int J Radiat Oncol Biol Phys* 1981; 7: 1501-5.
  42. Kessler DJ, Trapp TK, Calcaterra TC. The treatment of T3 glottic carcinoma with vertical partial laryngectomy. *Arch Otolaryngol Head Neck Surg* 1987; 113: 1196-9.
  43. Lesinski SG, Bauer WC, Ogura JH. Hemilaryngectomy for T3 (fixed cord) epidermoid carcinoma of larynx. *Laryngoscope* 1976; 86: 1563-71.
  44. Mendenhall WM, Million RR, Sharkey DE, Cassisi NJ. Stage T3 squamous cell carcinoma of the glottic larynx treated with surgery and/or radiation therapy. *Int J Radiat Oncol Biol Phys* 1984; 10: 357-63.



---

## ประสบการณ์การผ่าตัด frontolateral laryngectomy ในโรงพยาบาลศิริราช

ไพบุลย์ สุริยพงษ์, โชคชัย เมธีไตรรัตน์

**วัตถุประสงค์:** เพื่อศึกษาผลการผ่าตัดกล่องเสียงออกบางส่วน (frontolateral laryngectomy) ในโรงพยาบาลศิริราช โดยเน้นในเรื่องการทำงานของกล่องเสียงเพื่อดำรงชีวิต และการควบคุมมะเร็งกล่องเสียงภายหลังการผ่าตัด

**วัสดุและวิธีการ:** ทำการศึกษาผู้ป่วยที่เป็นมะเร็งกล่องเสียงระยะ T1 และ T2 ที่ได้รับการผ่าตัด frontolateral laryngectomy ที่ภาควิชาโสต นาสิก ลาริงซ์วิทยา คณะแพทยศาสตร์ศิริราชพยาบาล ตั้งแต่ปี พ.ศ. 2529 ถึง พ.ศ. 2549 โดยทำการศึกษาคิดตามย้อนหลังผู้ป่วยแต่ละรายอย่างน้อย 5 ปี

**ผลการศึกษา:** มีผู้ป่วยมะเร็งกล่องเสียงที่ได้รับการผ่าตัด frontolateral laryngectomy จำนวน 55 ราย พบว่าจำนวน 50 รายที่เข้าเกณฑ์คัดเข้าศึกษาในครั้งนี้ ผู้ป่วยที่ได้รับการผ่าตัดเกือบทุกราย สามารถถอดท่อ เจาะคอออก และหายใจเองได้ปกติ โดยมีผู้ป่วย 43 ราย (คิดเป็นร้อยละ 87.8) สามารถถอดท่อเจาะคอออกได้ใน 14 วัน หลังผ่าตัด ผู้ป่วยจำนวน 48 ราย (คิดเป็นร้อยละ 96) สามารถกินอาหารทางปากได้เอง ก่อนจำหน่ายออกจากโรงพยาบาล ระยะเวลาในการให้อาหารผ่านทาง nasogastric หลังผ่าตัดโดยเฉลี่ย 11.4 วัน (ช่วงเวลาระหว่าง 5 ถึง 22 วัน) และผู้ป่วยเกือบทุกรายภายหลังการผ่าตัด สามารถเปล่งเสียงพูดได้ดี ยกเว้นจำนวน 2 ราย ที่การพูดสื่อสารยังเป็นเสียงระดับเดียวกัน อัตราการรอดชีวิตภายหลังการผ่าตัดเท่ากับร้อยละ 98.5, 92, และ 92 ภายหลังการผ่าตัดปีที่ 1, 3 และ 5 ตามลำดับ เทคนิคการผ่าตัดนี้สามารถควบคุมมะเร็งไม่ให้เกิดเป็นซ้ำอีกภายใน 5 ปี สำหรับมะเร็งระยะที่ 1 ในอัตราร้อยละ 97 และระยะที่ 2 ในอัตราร้อยละ 75 นอกจากนี้เทคนิคการผ่าตัดดังกล่าวสามารถทำให้ผู้ป่วยเหลือกล่องเสียงเพื่อดำรงชีวิตปกติได้สูงถึงร้อยละ 90

**สรุป:** Frontolateral laryngectomy เป็นเทคนิคการผ่าตัดกล่องเสียงออกบางส่วนที่มีประสิทธิภาพในการควบคุมมะเร็งกล่องเสียงในระยะที่ 1 และ 2 โดยเฉพาะอย่างยิ่ง เมื่อพบว่ามะเร็งเกิดบริเวณ anterior commissure ได้ ระยะเวลาที่ผู้ป่วยต้องนอนโรงพยาบาลไม่นาน และให้ผลในการควบคุมมะเร็งที่ดี และมีอัตราการรอดชีวิตจากการเป็นมะเร็งซ้ำที่น่าประทับใจ

---