

## Case Report

# Endogenous *Klebsiella* panophthalmitis: Atypical Presentation<sup>†</sup>

Yanin Suwan MD\*,  
Passorn Preechawai MD\*

<sup>†</sup> This study was presented in part of the Cutting Edge 2007, meeting of Oculoplastics Association of India & Asia Pacific Society of Ophthalmic Plastic and Reconstructive Surgery, December, 14-16, 2007 Hyderabad, India

\* Department of Ophthalmology, Faculty of Medicine, Prince of Songkla University, Hat Yai, Songkhla, Thailand

---

Endogenous endophthalmitis caused by *K. pneumoniae* was considered to be a rare cause of endogenous endophthalmitis. Most of the patients had prior medical conditions, and diabetes is the most common underlying condition. Patients with a *K. pneumoniae* liver abscess are at risk of developing endogenous *Klebsiella pneumoniae* endophthalmitis (EKE). Clinical manifestation of *K. pneumoniae* endophthalmitis are unique with posterior chamber becomes full of pus while anterior segment seem quiet. The authors presented a case of extremely rare presentation of endogenous bacterial endophthalmitis, who presented with choroidal mass. After receiving pars plana vitrectomy and intravitreal antibiotic injection, clinical condition improved. Despite aggressive treatment, the final visual outcome was generally poor.

**Keywords:** Panophthalmitis, Endogenous *Klebsiella* endophthalmitis, Subretinal abscess, Metastatic endophthalmitis

*J Med Assoc Thai* 2012; 95 (6): 830-3

Full text. e-Journal: <http://jmat.mat.or.th>

---

Endogenous *Klebsiella pneumoniae* endophthalmitis (EKE) is a rare complication of gram-negative septicemia often seen in patients with comorbid medical conditions such as diabetes mellitus. Despite treatment with parenteral and intravitreal antibiotics, visual outcomes are generally poor, savagable vision is limited to eyes that receive early treatment. Mostly results in loss of light perception, evisceration, enucleation, or may eventually die<sup>(1-6)</sup>. One of severe manifestations of EKE is formation of subretinal abscesses. The primary sources of EKE infection are suppurative liver disease (68%) or urinary tract infection (16%)<sup>(7)</sup>. Metastasis EKE from prostatitis was reported<sup>(8)</sup>.

### Case Report

A 58-year-old man with underlying diabetes mellitus presented with left proptosis and blurred vision for 1 week. The patient had high-grade fever and diarrhea over the past 3 weeks. He was formerly hospitalized in a general hospital, and antibiotics were

administered to treat the infective diarrhea. After 10 days, the clinical conditions did not improve, and proptosis on the left eye developed. Subsequently, the patient was transferred to our center. Initial physical examination revealed a marked proptosis, which was confirmed by the Hertel exophthalmometer at base 100 mm was 13/22 mm, and erythematous skin on the left eye and severe inflammation of anterior segment but mature cataract obscure fundus finding (Fig. 1).

The visual acuity was 20/50 in the right eye and hand motion in the fellow eye. Reverse relative afferent papillary defect was present in his left eye. The ocular tension was 25 mmHg on the left eye while right ocular tension was in normal range. The right eye had yellowish subretinal mass with minimal sign of surrounding inflammation (Fig. 2).

The patient had full ocular-motility on right eye, but limited motility in all directions on the left eye. The septicemia developed, as well as the result of liver function tests showed transaminitis without jaundice, while abdominal ultrasound showed no space occupying lesion in the liver. A contact B scan ultrasound of the left eye, located at posterior pole, showed dome-shaped lesion (Fig. 3).

The CT orbit revealed left orbital cellulitis, no subperiosteal abscess and no abnormalities of cavernous sinus was seen (Fig. 4).

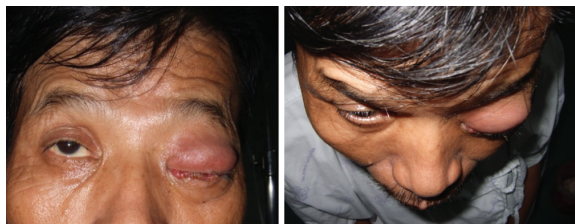---

### Correspondence to:

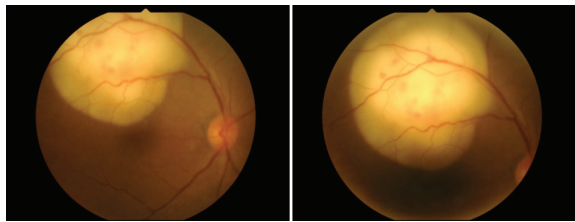
Suwan Y, Department of Ophthalmology, Faculty of Medicine, Ramathibodi Hospital, Mahidol University, Bangkok 10400, Thailand.

Phone: 0-2201-1526

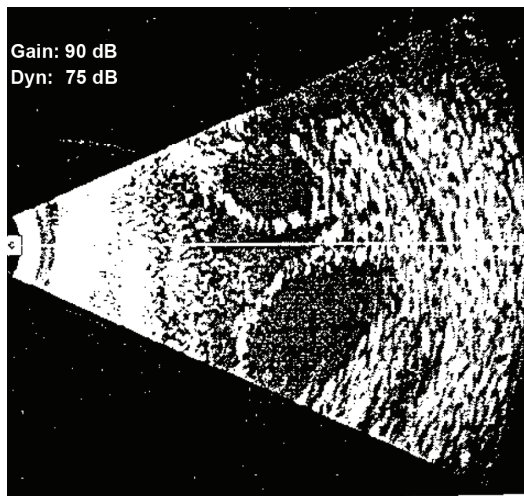
E-mail: yaninyona@hotmail.com



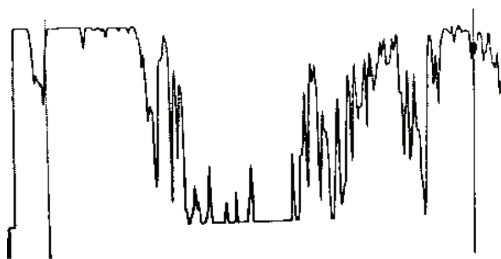
**Fig. 1** Clinical photograph showed proptosis, eyelid swelling and chemosis



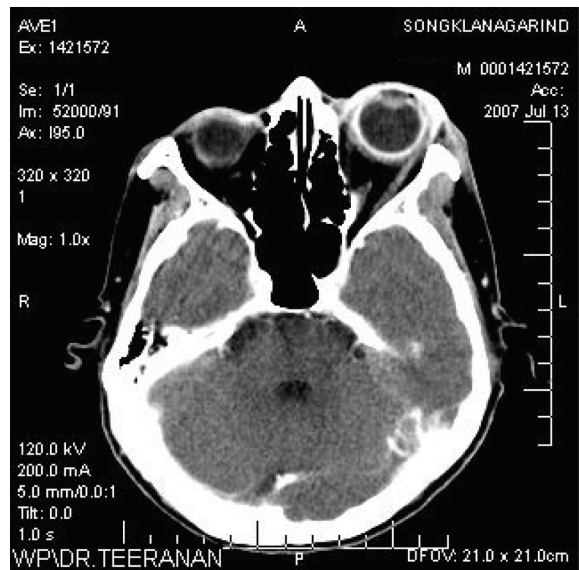
**Fig. 2** Photograph of the fundus of the right eye. Yellow, elevated choroidal mass is noted in superotemporal field



33.76 mm



**Fig. 3** A contact B scan ultrasound of the left eye, located at posterior pole, showed dome-shaped lesion



**Fig. 4** CT orbit revealed left orbital cellulitis, no subperiosteal abscess and no abnormalities of cavernous sinus was seen

The chest X-ray revealed bilateral multiple nodules predominated at periphery, and suspected septic emboli. The broad-spectrum antibiotics, ceftazidime and cloxacillin, were administered to cover suspected organisms in order to treat endogenous panophthalmitis. Clinical conditions of his left eye deteriorated, so diagnostic pars plana vitrectomy with intravitreal ceftazidime and vancomycin intravitreal injections were done. The hemoculture revealed *Klebsiella pneumoniae*, while vitreous culture showed no organism. The intravenous antibiotics were changed to ceftriazone according to sensitivity followed by intravitreal tapping and antibiotics injection on the left eye.

The patient underwent vitrectomy of the right eye, and repeated intravitreal antibiotics injection. Proptosis and inflammation on the left eye improved, and subretinal abscess on the right eye decreased in size as well. Prior to discharge the visual acuity was 20/200, projection of light.

#### Discussion

Endogenous endophthalmitis caused by *K. pneumoniae* was considered to be rare and account for only 3 to 5% of endogenous endophthalmitis, increasing in frequency up to 7.8% in cases with liver abscess having *Klebsiella* bacteremia<sup>(7,9-11)</sup>. Ninety percent of the patients had prior medical conditions,

including diabetes mellitus, gastrointestinal disorders, hypertension, cardiac disorders, and malignancy<sup>(11)</sup>. Diabetes is the most common underlying condition. Biliary tract disease, although the next most common underlying condition, was far less common<sup>(2,12)</sup>. Recently, there has been increasing frequency of *K. pneumoniae* endophthalmitis in East Asian countries, while gram-positive organisms from endocarditis or skin/joint infections are still common in Western countries<sup>(2-4,6,7,9,10,13-15)</sup>. In East Asian populations, *Klebsiella* was found to be responsible in approximately 90% of all endogenous bacterial endophthalmitis cases<sup>(14)</sup>.

Clinical manifestations of *K. pneumoniae* endophthalmitis are unique in several aspects. While conjunctival injection or anterior chamber reactions are mild, the posterior chamber becomes full of white pus. The progression is very rapid within a few days. Subretinal abscess of the present case is an extremely rare presentation of endogenous bacterial endophthalmitis<sup>(16)</sup>. This rarity is further enhanced by the infrequency of endogenous bacterial endophthalmitis itself. Previous reports have made distinctions in focal bacterial infections *e.g.* subretinal abscess, intraretinal abscess, septic retinal cyst, and choroidal abscesses<sup>(18)</sup>. Other organisms that can cause subretinal abscess, *Pseudomonas aeruginosa*, *Streptococcus viridans*, *Nocardia*, *Candida*, and *Aspergillus* have been reported<sup>(17)</sup>. Characteristic pupillary hypopyon was reported 54% in one case series, although this was not present in the present case report<sup>(2)</sup>.

Despite aggressive treatment with intravenous and intravitreal antibiotics, the final visual outcome was light perception or worse up to 89% in a large series<sup>(2)</sup>. Due to blood-ocular barrier, intravitreal drug concentrations are low after systemic administration. Strong antibiotic with good penetration into the vitreous humor are needed to obtain adequate bactericidal concentration<sup>(18)</sup>. Intravitreal injection of vancomycin, amikacin and dexamethasone had been reported<sup>(7)</sup>. Early vitrectomy may be considered in some patients with poor presenting visual acuity to remove the infecting organism and endotoxin. The endotoxin is partly responsible for inflammation and tissue destruction<sup>(6)</sup>. If subretinal abscess is present, drainage may be required<sup>(2,15)</sup>. Useful visual acuity was achieved with prompt vitrectomy, extensive retinectomy, transretinal removal of the subretinal abscess, endolaser photocoagulation and intravitreal antibiotics in cases of subretinal abscess with final visual acuity of 20/30 were reported<sup>(17)</sup>.

Early diagnosis and prompt treatment with proper intravenous and intravitreal antibiotics may improve visual outcome<sup>(18,19)</sup>.

#### Acknowledgment

The authors wish to thank Dr. Passorn Preechawai for his valuable advice in manuscript preparation.

#### Potential conflicts of interest

None.

#### References

1. Scott IU, Matharoo N, Flynn HW Jr, Miller D. Endophthalmitis caused by *Klebsiella* species. *Am J Ophthalmol* 2004; 138: 662-3.
2. Yang CS, Tsai HY, Sung CS, Lin KH, Lee FL, Hsu WM. Endogenous *Klebsiella* endophthalmitis associated with pyogenic liver abscess. *Ophthalmology* 2007; 114: 876-80.
3. Jackson TL, Eykyn SJ, Graham EM, Stanford MR. Endogenous bacterial endophthalmitis: a 17-year prospective series and review of 267 reported cases. *Surv Ophthalmol* 2003; 48: 403-23.
4. Liu YC, Cheng DL, Lin CL. *Klebsiella pneumoniae* liver abscess associated with septic endophthalmitis. *Arch Intern Med* 1986; 146: 1913-6.
5. Liao HR, Lee HW, Leu HS, Lin BJ, Juang CJ. Endogenous *Klebsiella pneumoniae* endophthalmitis in diabetic patients. *Can J Ophthalmol* 1992; 27: 143-7.
6. Hidaka T, Yokota T, Tamura K. A case of liver abscess associated with endophthalmitis caused by *Klebsiella pneumoniae*. *Kansenshogaku Zasshi* 1993; 67: 76-80.
7. Chou FF, Kou HK. Endogenous endophthalmitis associated with pyogenic hepatic abscess. *J Am Coll Surg* 1996; 182: 33-6.
8. Ebisuno S, Miyai M. A case of *Klebsiella pneumoniae* endophthalmitis metastasized from prostatitis. *Hinyokika Kyo* 1994; 40: 625-7.
9. Yoon YH, Lee SU, Sohn JH, Lee SE. Result of early vitrectomy for endogenous *Klebsiella pneumoniae* endophthalmitis. *Retina* 2003; 23: 366-70.
10. Chiu CT, Lin DY, Liaw YF. Metastatic septic endophthalmitis in pyogenic liver abscess. *J Clin Gastroenterol* 1988; 10: 524-7.
11. Okada AA, Johnson RP, Liles WC, D'Amico DJ, Baker AS. Endogenous bacterial endophthalmitis.

- Report of a ten-year retrospective study. *Ophthalmology* 1994; 101: 832-8.
12. Han SH. Review of hepatic abscess from *Klebsiella pneumoniae*. An association with diabetes mellitus and septic endophthalmitis. *West J Med* 1995; 162: 220-4.
  13. Chen YJ, Kuo HK, Wu PC, Kuo ML, Tsai HH, Liu CC, et al. A 10-year comparison of endogenous endophthalmitis outcomes: an east Asian experience with *Klebsiella pneumoniae* infection. *Retina* 2004; 24: 383-90.
  14. Wong JS, Chan TK, Lee HM, Chee SP. Endogenous bacterial endophthalmitis: an east Asian experience and a reappraisal of a severe ocular affliction. *Ophthalmology* 2000; 107: 1483-91.
  15. Margo CE, Mames RN, Guy JR. Endogenous *Klebsiella* endophthalmitis. Report of two cases and review of the literature. *Ophthalmology* 1994; 101: 1298-301.
  16. Yarnig SS, Hsieh CL, Chen TL. Vitrectomy for endogenous *Klebsiella pneumoniae* endophthalmitis with massive subretinal abscess. *Ophthalmic Surg Lasers* 1997; 28: 147-50.
  17. Harris EW, D'Amico DJ, Bhisitkul R, Priebe GP, Petersen R. Bacterial subretinal abscess: a case report and review of the literature. *Am J Ophthalmol* 2000; 129: 778-85.
  18. Wang FD, Wang LS, Liu YC, Liu CY, Lin CL, Wong WW. Successful treatment of metastatic endophthalmitis. Case reports. *Ophthalmologica* 1989; 198: 124-8.
  19. Chee SP, Ang CL. Endogenous *Klebsiella* endophthalmitis—a case series. *Ann Acad Med Singapore* 1995; 24: 473-8.

---

### ลูกต้ออักเสบแบบทั่วไปจากเชื้อเคร็ปเชลล่าแบบการติดเชื้อจากภายใน: การแสดงไม่เป็นแบบฉบับ

ญานิน สุวรรณ, ภัตสร ปรีชาไว

ลูกต้ออักเสบแบบทั่วไปแบบการติดเชื้อจากภายในจากเชื้อเคร็ปเชลล่าเป็นสาเหตุของลูกต้ออักเสบแบบทั่วไปที่หายาก ส่วนใหญ่ของผู้ป่วยมีภาวะทางการแพทย์อยู่ก่อนและเบาหวานเป็นภาวะพื้นฐานที่พบบ่อย ผู้ป่วยที่เป็นโพรงหนองคืบจากเชื้อเคร็ปเชลล่ามีความเสี่ยงในการพัฒนาเป็นลูกต้ออักเสบแบบทั่วไปจากเชื้อเคร็ปเชลล่าแบบการติดเชื้อจากภายใน อาการแสดงทางคลินิกของลูกต้ออักเสบแบบทั่วไปจากเชื้อเคร็ปเชลล่ามีลักษณะเฉพาะด้วยช่องหลังลูกตาเต็มไปด้วยหนองขณะที่ช่องหน้าลูกตาปราศจากสิ่งรบกวน คณะผู้นิพนธ์นำเสนอกรณีหายากมากของลูกต้ออักเสบแบบทั่วไปแบบการติดเชื้อจากภายในจากเชื้อแบคทีเรีย ผู้ป่วยมาด้วยอาการก่อนที่ชั้นคอร์อยด์ของตา หลังจากใส่แก๊สชนิดพิเศษเพื่อไปดันให้จอประสาทตาติดกลับไปแบบผนังลูกตาและการฉีดยาปฏิชีวนะเข้าในน้ำวุ้นตา ผู้ป่วยมีอาการทางคลินิกดีขึ้น แม้จะให้การรักษาเชิงรุก สุดท้ายแล้วผลที่ได้รับด้านการมองเห็นไม่ดี

---