

# Neuroendocrine Carcinomas of the Uterine Cervix: A Clinicopathological Study

Panitta Sitthinamsuwan MD\*, Napat Angkathunyakul MD\*,  
Tuenjai Chuangsuwanich MD\*, Perapong Inthasorn MD\*\*

\* Department of Pathology, Faculty of Medicine Siriraj Hospital, Mahidol University, Bangkok, Thailand

\*\* Department of Obstetrics Gynecology, Faculty of Medicine Siriraj Hospital, Mahidol University, Bangkok, Thailand

---

**Background:** Neuroendocrine carcinoma (NEC) is a rare entity of uterine cervical carcinoma. Most of them have a more aggressive course and worse prognosis than a common type squamous cell carcinoma. Therefore, precise diagnosis is very crucial.

**Objective:** To study clinicopathological correlation and immunohistochemistry of uterine cervical NEC

**Material and Method:** All primary uterine cervical carcinomas from a 51-month period were histopathologically reviewed. Suspicious NECs were retrieved and immunohistochemically studied for chromogranin, synaptophysin, non-specific esterase (NSE) and CD56. Clinical information including treatments and mean disease free survival time were obtained from chart review.

**Results:** Fourteen (3.5%) cases of NEC were identified from 389 primary uterine cervical carcinomas between October 1, 2002 and December 31, 2006 and classified into small cell neuroendocrine carcinoma (SNEC, 8 cases), large cell neuroendocrine carcinoma (LNEC, 3 cases), mixed SNEC and adenocarcinoma (2 cases), and mixed SNEC and squamous cell carcinoma (1 case). All NEC presented with abnormal vaginal bleeding. The median age was 44 years (34-75 years). Exophytic mass was noted in 11 patients (78.6%). Five patients (36%) had distant metastases. All cases were immunoreactive for at least two neuroendocrine markers. Nine cases (64.3%) were positive for chromogranin, 11 (78.6%) for synaptophysin, 12 (85.7%) for NSE, and 11 (78.6%) for CD56. CD56 was positive in eight of 11 SNEC cases. The mean disease free interval and overall survival time were 17.5 and 23.9 months, respectively.

**Conclusion:** Neuroendocrine carcinoma of the cervix is rare and has poor prognosis. In addition to histopathology, panel of immunohistochemistry is mandatory in the diagnosis of neuroendocrine carcinoma. Varying results of immunohistochemistry may be found.

**Keywords:** Neuroendocrine carcinoma, Cervical carcinoma, Small cell carcinoma, CD56

*J Med Assoc Thai* 2013; 96 (1): 83-90

Full text. e-Journal: <http://jmat.mat.or.th>

---

Uterine cervical carcinoma is the second most common female malignant neoplasm<sup>(1)</sup> and the most common malignant tumor of Thai women<sup>(2)</sup>, the most common type of which is squamous cell carcinoma. Neuroendocrine carcinoma (NEC) is rare, accounting for less than 5% of all cervical carcinomas<sup>(3)</sup>, but it has an aggressive biologic behavior. Previous reports of NEC of the uterine cervix revealed higher frequency of nodal metastases, lymphovascular invasion, recurrent rate, and poorer prognosis than other types. A comparative study of uterine cervical NEC and squamous cell carcinoma proposed by McCusker et al

revealed a tendency of nodal metastasis at the time of diagnosis of NEC<sup>(4)</sup>. In addition, overall median survival rate of NEC was 22 months, whereas that of squamous cell carcinoma was 10 years<sup>(4)</sup>. The survival rate of patients with NEC in all stages was lower than that of squamous cell carcinoma<sup>(4)</sup>. Furthermore, an association between NEC and human papilloma virus (HPV) types 16 and 18 has been mentioned, resembling the other types of uterine cervical carcinoma<sup>(5)</sup>.

Since 1997, neuroendocrine (NE) tumors have been classified by a workgroup sponsored by The National Cancer Institute and the College of American Pathologists into four categories: 1) carcinoid, 2) atypical carcinoid, 3) large cell neuroendocrine, and 4) small cell (oat cell) carcinomas<sup>(6)</sup>. These NE tumor subtypes are also used in the World Health Organization (WHO) Classification (2003) for tumors of the breast and female genital organs<sup>(7)</sup>. NE tumors can usually

---

**Correspondence to:**

Sitthinamsuwan P, Department of Pathology, Faculty of Medicine Siriraj Hospital, Mahidol University, 2 Prannok Road, Bangkok Noi, Bangkok 10700, Thailand.

Phone: 0-2419-6504-5

E-mail: panittasi@hotmail.com

be distinguished from squamous cell carcinoma and adenocarcinoma by histological features and subsequently confirmed by neuroendocrine immunophenotypes. As a result of its aggressive behavior, accurate diagnosis of this type of uterine cervical cancer is very important. Histopathologically, features of NE tumors encompass neuroendocrine growth patterns (such as orderly tubular, trabecular, organoid, and nuclear palisading patterns), uniformity of tumor cells, salt and pepper appearance of nuclear chromatin, nuclear molding, and tumor necrosis<sup>(7)</sup>.

The aim of the present study focused on NE neoplasms of the uterine cervix specifically on the histologic features, immunophenotypic findings, and clinicopathological correlations (prevalence, age, stage of tumor, tumor size, treatment modality, and survival of the patients).

#### **Material and Method**

Microscopic slides of all primary uterine cervical carcinomas diagnosed in Siriraj Hospital between October 2002 and December 2006 (a period of 51 months) were recruited. All of them were retrospectively reviewed by a general pathologist simultaneously with a trainee by using a binocular microscope to classify types of uterine cervical carcinoma and detect the microscopic features of the neuroendocrine carcinoma. All examined specimens showing some neuroendocrine features were recruited for immunohistochemical studies, including chromogranin A, synaptophysin, NSE, and CD56. Additional immunohistochemical stains were not performed if they were already done. All slides of primary uterine cervical carcinoma were confirmed by a gynecologic pathologist. The present study was ethically approved by Siriraj Institutional Review Board (SIRB); code 078/2551 (EC4).

All additional immunohistochemical markers were performed on 3  $\mu$ m-thick sections by using DAKO Clone BBS/NC/VI-H14 and Zymed Clone 123C3 for NSE and CD56, respectively, based on the EnVision immunohistochemical detection system as the secondary antibody. The slides were incubated overnight at room temperature with 3% hydrogen peroxide in distilled water for 10 minutes, followed by the primary antibody (dilution 1:800 for NSE) then the secondary antibody. CD56 staining was performed with Ventana Autostainer primary antibody (dilution 1:50). All slides were evaluated semiquantitatively into 0 and less than 10% as 'negative', and more than 10% as 'positive'. The intensity was graded as low and high.

The diagnosis of NEC required histomorphology together with results of an immunohistochemical study. The cases that showed negative staining for all immunohistochemical markers were considered non-neuroendocrine while those malignant tumors with positive staining for any of the 'neuroendocrine markers' and histological suspicion of NE features were considered NEC.

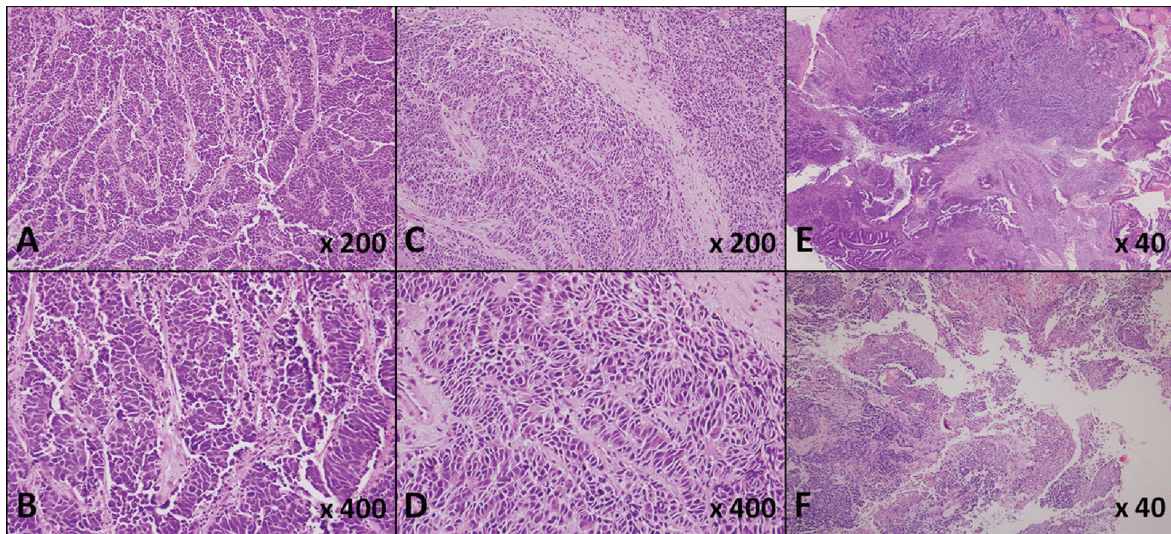
#### **Results**

Of 398 primary uterine cervical carcinomas, 246 were obtained from biopsy, 44 from LEEP, and 108 from hysterectomy. There were 335 squamous cell carcinomas (84.2%), 42 adenocarcinomas (10.5%), 14 NEC (3.5%), six carcinomas with NE differentiation (1.5%), and an undifferentiated carcinoma (0.3%). The NEC was subcategorized into eight small cell neuroendocrine carcinomas (SNEC) (Fig. 1A, B), three large cell neuroendocrine carcinomas (LNEC) (Fig. 1C, D), two cases of mixed SNEC and adenocarcinoma (Fig. 1E), and one case of mixed SNEC and squamous cell carcinoma (Fig. 1F). In addition, focal areas of carcinoma in situ (CIN) and adenocarcinoma in situ (AIS) were found in one case of mixed SNEC and adenocarcinoma.

Correlation between histopathologic findings and reports of gynecologic PAP smears revealed only one case with concordance of positive for adenocarcinoma and SNEC. Six cases had PAP smears that reported negative for intraepithelial lesion or malignancy. There was no gynecologic PAP smear report on the remaining seven cases. Unfortunately, review of the PAP smear to seek for pitfalls in diagnosis could not be done. Comparison between previous histopathological reports and final reviews are demonstrated in Table 1.

#### **Patient characteristics**

The median age of the patients was 44 years, ranging from 34 to 75. All presented with abnormal vaginal bleeding. Most of the tumors showed exophytic growth (78.57%) (Table 1). Of five patients (35.7%) with distant metastases, four had single organ metastasis in supraclavicular node, lung, liver, and pancreas. The other one had lung and brain metastases. Multimodalities of treatment were used in 10 patients (Table 1). The most common chemotherapeutic regimen was platinum-based chemotherapy. Except for two patients who refused treatment, four patients (33%) did not have clinical complete response after treatment. Of eight patients who had clinical complete



**Fig. 1** H&E stain of small cell neuroendocrine carcinoma (A, B), large cell neuroendocrine carcinoma (C, D) and mixed neuroendocrine carcinoma (E, F). (A) (x200) Small cell neuroendocrine carcinoma showing cohesive nests of small blue cells with nuclear molding. (B) (x400) Fine nuclear chromatin noted. (C) (x200) Large cell neuroendocrine carcinoma showing nest of neoplastic cells containing eosinophilic cytoplasm together with some area of rosette formation. (D) (x400) Fine nuclear chromatin noted. (E) Mixed small cell neuroendocrine carcinoma and adenocarcinoma. Two different areas consisted of areas containing small blue round cells (upper part) and area of gland-forming tumor (lower part). (F) Mixed squamous cell and small cell neuroendocrine carcinoma. Two distinctive areas included squamous cell carcinoma area that showed large neoplastic cells with abundant eosinophilic cytoplasm and keratinization (right upper part), and the other area demonstrated small blue round cell intervening with the squamous cell carcinoma (left lower part).

response after primary treatment, five (63%) had recurrent disease. Only three patients with stage IB who underwent surgery and received adjuvant treatment had long-term survival. However, two patients with stage IB died of the disease. Mean disease free interval and overall survival time for the 12 patients who received treatment was 17.5 and 23.92 months, respectively.

#### **Histological findings**

According to NE tumors, histopathological findings suggestive of NE features included uniformity of tumor cells (92.8%), neuroendocrine patterns (rosette formation, trabecular, organoid growth pattern and nuclear palisading) (92.8%), nuclear molding (42.8%), salt and pepper chromatin (28.5%). Nuclear molding was found only in six SNEC out of 11 cases. In addition, tumor necrosis was noted in 64.2% of poorly differentiated neuroendocrine carcinomas (Table 2).

#### **Immunohistochemistry**

At least two NE markers were positive in each case. Of 14 cases, nine were positive for chromogranin

(64.2%), 11 for synaptophysin (78.5%), 12 for NSE (85.7%), and 11 for CD56 (78.5%). CD56 was positive in the majority of SNEC, eight out of 11 cases and all three LNECs (Table 3). The intensity of each immunohistochemical antibody is shown in Table 3.

#### **Discussion**

NEC of the uterine cervix is a relatively rare tumor. In the present study, it comprised 3.5% of primary uterine cervical carcinomas. All cases presented with abnormal vaginal bleeding. The clinical manifestation as an exophytic growth was not different from that of other uterine cervical carcinomas. Pathological diagnosis of NEC is necessary because it has more aggressive behavior than that of the other types. From the study of Sevin et al<sup>(8)</sup>, only 36.4% of NEC had 5-year disease free survival compared with 71.6% for the other carcinomas. Moreover, markedly increased lymph node metastasis was found as it occurred in 45.5% of the patients with SNEC, whereas only 18.9% of the patients with other carcinomas developed lymph node metastasis. Viswanathan et al<sup>(9)</sup> also showed 29% and 43% of 2-year and 5-year survival rates of small cell carcinoma, respectively.

**Table 1.** Clinicopathological data of 14 NECs

No.	Age (years)	Previous pathology report	Histopathology	PAP reports	Stage	Size (cm)	Lesion	Treatment	DFI (months)	ST (months)	Last status
1	37	SNEC	SNEC	N/A	IIIB	14	Exophytic	CCR	0	4	DOD
2	35	SNEC	SNEC	NILM	IIB	8	Exophytic	CCR+CMT	0	11	DOD
3	34	SNEC	SNEC	N/A	IIB	3	Exophytic	CCR	6	26	DOD
4	37	ADC SCC	SNEC	N/A	IIB	8	Exophytic	Refuse treatment	-	-	LF
5	37	SNEC	SNEC	NILM	IB	1	Endophytic	RHND+CMT	13	17	DOD
6	44	SCC	SNEC	N/A	IB	3	Exophytic	RHND+CMT	50	50	AW
7	44	SNEC	SNEC	NILM	IIB	2	Exophytic	CCR+CMT	6	15	DOD
8	55	SNEC	SNEC	NILM	IB	2	Endophytic	RHND+CMT	33	33	AW
9	45	SNEC+ADC	SNEC+ADC	SNEC+ADC	IB	2	Exophytic	RHND+CMT	60	60	AW
10	47	SNEC+ADC	SNEC+ADC	N/A	IVB	7	Exophytic	CMT	0	11	DOD
11	47	SNEC+SCC	SNEC+SCC	N/A	IIB	8	Exophytic	RHND+CMT	0	6	ID
12	41	LNEC	LNEC	NILM	IB	3	Exophytic	RHND	38	45	DOD
13	75	SCC	LNEC	N/A	IIIB	5	Ulcerative	Refuse treatment	-	-	LF
14	61	LNEC	LNEC	NILM	IIB	4	Exophytic	CCR	4	9	DOD

SNEC = small cell neuroendocrine carcinoma; LNEC = large cell neuroendocrine carcinoma; SCC = squamous cell carcinoma; ADC = adenocarcinoma; AW = adenocarcinoma; ADC SCC = adenocarcinoma; N/A = not available; CCR = concurrent chemoradiation; CMT = chemotherapy; RHND = radical hysterectomy with pelvic node dissection; ST = survival time; AW = alive well; DFI = disease free interval; DOD = dead of disease; ID = intercurrent death; LF = lost to follow-up

**Table 2.** Types of NEC and histological findings

Types	Uniformity	NE Pattern	Nuclear molding	Salt & pepper chromatin	Tumor necrosis
SNEC	10/11	10/11	6/11	4/11	6/11
LNEC	3/3	3/3	0	0	3/3

NE = neuroendocrine; NEC = neuroendocrine carcinoma; SNEC = small cell neuroendocrine carcinoma; LNEC = large cell neuroendocrine carcinoma

**Table 3.** Types of NEC and immunoreactivities

Case	Diagnosis	Markers							
		Chromogranin		Synaptophysin		NSE		CD56	
		%	Intensity	%	Intensity	%	Intensity	%	Intensity
1	SNEC	+++	Intense	+++	Intense	+++	Intense	+++	Intense
2	SNEC	0	N/A	0	N/A	+	Weak	+++	Intense
3	SNEC	0	N/A	+++	Intense	+++	Intense	+++	Intense
4	SNEC	+++	Intense	++	Weak	++	Weak	+++	Intense
5	SNEC	+	Intense	++	Intense	+++	Intense	0	N/A
6	SNEC	++	Intense	+++	Weak	0	N/A	+++	Intense
7	SNEC	0	N/A	+++	Intense	+++	Intense	+++	Intense
8	SNEC	+++	Intense	+++	Intense	0	N/A	+++	Weak
9	SNEC+ADC	0	N/A	0	N/A	+++	Intense	+	Intense
10	SNEC+ADC	+++	Intense	+++	Intense	+++	Intense	0	N/A
11	SNEC+SCC	++	Intense	0	N/A	++	Intense	0	N/A
12	LNEC	+++	Intense	+++	Weak	+++	Intense	+	Weak
13	LNEC	+++	Intense	+++	Intense	+++	Intense	+++	Intense
14	LNEC	0	N/A	++	Weak	++	Intense	++	Intense

0 = negative; + = <10%; ++ = 10-50%; +++ = >50%; SNEC = small cell neuroendocrine carcinoma; LNEC = large cell neuroendocrine carcinoma; SCC = squamous cell carcinoma; ADC = adenocarcinoma

Their patients with stages over IB1 did not survive more than 30 months. Moreover, the survival rate of stage IB1 NEC was less than that of squamous cell carcinoma and adenocarcinoma of the same stage. This result indicated relatively poor prognosis of the tumor. Sixty-six percent of SNEC (14/21 cases) relapsed in 3.6 to 28 months and had a hematogeneous spread with distant metastasis. Abeler et al<sup>(5)</sup> reported three stage IV NEC patients who died within three months. In addition, survival rate depended on stage and size of the tumor. Chan et al<sup>(10)</sup> studied prognostic factors in small cell neuroendocrine carcinoma. They found that the survival rate of patients with tumor size less than 2 cm was significantly longer than those with the tumor larger than 2 cm (155 versus 14 months, respectively and p-value, 0.02) and the survival rate of the patients in the early stages (< IIB) was 31 months while in the advanced stages it was 10 months (p-value, 0.002). In the present study, the authors found that the patients tended to have poor prognosis. Only three of 14 patients (20%) had long-term survival. All had stage IB and received surgery plus adjuvant treatment, either chemotherapy or concurrent chemoradiation. Most of the remaining patients found staging more over than stage IB and died of the disease with a mean of survival rate of 16 months. Only one patient from

the remaining patient had stage IB. This patient did not receive adjuvant therapy after surgery and died of recurrent disease. Therefore, it is very important to give a correct diagnosis and accurate parameters necessary for staging and promptly giving adjuvant treatment.

Misdiagnosis of NEC often occurs. Sato et al<sup>(11)</sup> studied six cases of LNEC and found some cases misdiagnosed as poorly differentiated squamous cell carcinoma and poorly differentiated adenocarcinoma. In the present study, the authors also found two cases firstly diagnosed as SCC and one case diagnosed as adenosquamous carcinoma. Although vaginal Pap smear is an effective screening tool for uterine cervical cancer, NEC tumors might be missed or even be diagnosed as other types of uterine cervical carcinoma. Zhou et al<sup>(12)</sup> revealed six out of 13 SNEC cases were initially reported as negative cytology whereas the remaining seven cases were positive for malignant epithelial cells (3 cases were diagnosed 'malignant epithelial cells, not otherwise specified' and 3 cases were initially diagnosed 'adenocarcinoma'). Kim et al<sup>(13)</sup> studied cytologic diagnosis of SNEC of the uterine cervix and found all 13 cases were previously reported as the other types of primary uterine cervical carcinoma. In the present study, the authors found

negativity in PAP smears in most of the cases that might reflect some difficulty in diagnosing SNEC from vaginal PAP smears, since most of the patients had excophtic mass, which should be found atypical cells in PAP smears. However, there was some limitation in the present study as review of vaginal PAP smears could not be performed. Thus, recognition of neuroendocrine patterns in surgical specimens by pathologists and subsequent confirmation with neuroendocrine immunomarkers are essential.

In present study, the authors found only poorly differentiated NEC (SNEC and LNEC) with SNEC as the most common type and combination with adenocarcinoma (2 cases) and squamous cell carcinoma (1 case). These combinations of tumors are frequent<sup>(14,15)</sup>. Cetiner et al<sup>(14)</sup> reported a case of mixed LNEC and other primary carcinoma and found a separate CIN area and transition zone from adenocarcinoma in situ to LNEC. They supposed that a mixture of two types of carcinoma might be a divergent differentiation rather than a synchronous carcinoma. Chan et al<sup>(10)</sup> reported better prognosis in patients with mixed epithelial type and NEC than that of pure NEC, of which all patients with stages higher than IIB died within 3 years. The authors had only one case with stage IB who had 60 months' survival time and two patients with stage IVB and IIB who died with disease. In the present study, the authors cannot conclude the prognosis as the previous study because there were a few cases of mixed epithelial type, which had different staging in each case.

Although NEC has distinctive histologic features, it has to be confirmed by immunohistochemical study for neuroendocrine markers, especially in a small biopsy specimen. Other types of neoplasm should be distinguished, i.e., non-keratinizing squamous cell carcinoma, adenocarcinoma, undifferentiated carcinoma or malignant lymphoma. In the present study, the authors used a panel of immunohistochemical antibodies for chromogranin, synaptophysin, NSE, and CD56, there was no single immunohistochemical marker positive in all cases of neuroendocrine carcinoma; however, at least two markers were positive in each case. Most of the cases showed intense staining and positivity in more than 50% of neoplastic cells. Four cases showed positivity of all markers, eight cases displayed positivity of three, and three cases of two. Thus, exclusion or conclusion in diagnosis of neuroendocrine carcinoma of the uterine cervix should be performed by using panel markers. In the series of Albores-Saavedra et al<sup>(16)</sup>, 88% of SNEC of the

uterine cervix (22 of 25 cases) showed strong and diffuse membranous staining of CD56, so CD56 was suggested as an additional marker to chromogranin and synaptophysin. Additionally, CD56 shows diffuse membranous staining pattern, while chromogranin, synaptophysin, and NSE showed cytoplasmic staining. CD56 increases the possibility of diagnosis in a small biopsy with a crushed artifact. Kaufmann et al<sup>(17)</sup> studied SNEC of both pulmonary and extra pulmonary sites, they found the sensitivity of CD56 to SNEC was 0.99 while it was 0.44 from other NE markers (NSE, PGP9.5, synaptophysin, CGA and CD57) and it was useful even in decalcified tissue. In the present study, CD56 immunoreactivity varied from negative to positive (2 cases with less than 10%, 1 case with 10-50%, 7 cases with more than 50%, and negative in 3 cases). However, most cases showed more than 50% of tumor cells' reactivity. Impressively, CD56 was helpful in the diagnosis of NEC, but the immunohistochemical markers should be performed in panel (at least synaptophysin, chromogranin and CD56).

The recommendation of treatments in NEC of uterine cervix has not been well-established due to its rarity and only few studies have adequate data. Combined multiple treatment modalities including adjuvant chemotherapy and radiotherapy following surgery are used due to its aggressive behavior. Kasamatsu et al<sup>(18)</sup> reported that pelvic control by radical hysterectomy was ineffective and the operation should be limited to patients with an early stage without nodal metastasis. They also suggested non-radical hysterectomy followed by aggressive adjuvant chemotherapy in patients with later stages. Some previous studies stated that adjuvant chemotherapy in neuroendocrine carcinoma of uterine cervix did not have a significant improved outcome<sup>(9,11)</sup>. Boruta et al<sup>(19)</sup> suggested VAC (vincristine, adriamycin, and cyclophosphamide) or PE (platinum plus etoposide) chemotherapy regimen following surgery, which apparently improved survival. Similar to the study of Lee et al<sup>(20)</sup>, adjuvant chemotherapy slightly increased 5-year survival rate (48.9% versus 42.0%). However, in their study, the patients who were treated with neoadjuvant chemotherapy had a poor prognosis, equivalent to the same as those who received adjuvant radiation. In the present study, multimodality therapy was included. The commonly used chemotherapeutic agent was platinum based either chemotherapy alone or concurrent chemoradiation. Regarding to the high rate of distant metastasis, adjuvant systemic chemotherapy may play a key role in the treatment of

both early and advanced stage groups. However, an appropriate chemotherapeutic regimen as a part of multimodality treatment should be investigated further.

### Conclusion

NEC of the uterine cervix is rare. It has aggressive behavior and poor prognosis although multiple modalities of treatment were given. The diagnosis is accomplished by recognition of NEC histologic features and should be confirmed by an additional panel of immunohistochemical markers. Variability of immunoreactivity can be encountered.

### Acknowledgement

The authors want to thank Faculty of Medicine Siriraj Hospital's Grant for financial support and Thirapol Boonya-arunnate, MD and Somsak Laiwejpithaya, MD for contributing information of vaginal PAP smears.

### Potential conflicts of interest

None.

### References

1. Mohar A, Frias-Mendivil M. Epidemiology of cervical cancer. *Cancer Invest* 2000; 18: 584-90.
2. Vatanasapt V, Martin N, Sriplung H, Chindavijak K, Sontipong S, Sriamporn H, et al. Cancer incidence in Thailand, 1988-1991. *Cancer Epidemiol Biomarkers Prev* 1995; 4: 475-83.
3. Robboy SJ, Anderson MC, Russell P. Malignant tumors of the cervix. In: Robboy SJ, Anderson MC, Russell P, editors. *Pathology of the female reproductive tract*. London: Churchill Livingstone; 2002: 227-8.
4. McCusker ME, Cote TR, Clegg LX, Tavassoli FJ. Endocrine tumors of the uterine cervix: incidence, demographics, and survival with comparison to squamous cell carcinoma. *Gynecol Oncol* 2003; 88: 333-9.
5. Abeler VM, Holm R, Nesland JM, Kjorstad KE. Small cell carcinoma of the cervix. A clinicopathologic study of 26 patients. *Cancer* 1994; 73: 672-7.
6. Albores-Saavedra J, Gersell D, Gilks CB, Henson DE, Lindberg G, Santiago H, et al. Terminology of endocrine tumors of the uterine cervix: results of a workshop sponsored by the College of American Pathologists and the National Cancer Institute. *Arch Pathol Lab Med* 1997; 121: 34-9.
7. Wells M, Ostor AG, Crum CP, Franceschi S, Tommasino M, Nesland JM, et al. Epithelial tumours. In: Tavassoeli FA, Devilee P, editors. *World Health Organization Classification of tumours: pathology and genetics of tumours of the breast and female genital organs*. Lyon, France: IARC Press; 2003: 262-79.
8. Sevin BU, Method MW, Nadji M, Lu Y, Averette HA. Efficacy of radical hysterectomy as treatment for patients with small cell carcinoma of the cervix. *Cancer* 1996; 77: 1489-93.
9. Viswanathan AN, Deavers MT, Jhingran A, Ramirez PT, Levenback C, Eifel PJ. Small cell neuroendocrine carcinoma of the cervix: outcome and patterns of recurrence. *Gynecol Oncol* 2004; 93: 27-33.
10. Chan JK, Loizzi V, Burger RA, Rutgers J, Monk BJ. Prognostic factors in neuroendocrine small cell cervical carcinoma: a multivariate analysis. *Cancer* 2003; 97: 568-74.
11. Sato Y, Shimamoto T, Amada S, Asada Y, Hayashi T. Large cell neuroendocrine carcinoma of the uterine cervix: a clinicopathological study of six cases. *Int J Gynecol Pathol* 2003; 22: 226-30.
12. Zhou C, Hayes MM, Clement PB, Thomson TA. Small cell carcinoma of the uterine cervix: cytologic findings in 13 cases. *Cancer* 1998; 84: 281-8.
13. Kim MJ, Kim NR, Cho HY, Lee SP, Ha SY. Differential diagnostic features of small cell carcinoma in the uterine cervix. *Diagn Cytopathol* 2008; 36: 618-23.
14. Cetiner H, Kir G, Akoz I, Gurbuz A, Karateke A. Large-cell neuroendocrine carcinoma of the cervix associated with cervical-type invasive adenocarcinoma: a report of case and discussion of histogenesis. *Int J Gynecol Cancer* 2006; 16: 438-42.
15. Ishida GM, Kato N, Hayasaka T, Saito M, Kobayashi H, Katayama Y, et al. Small cell neuroendocrine carcinomas of the uterine cervix: a histological, immunohistochemical, and molecular genetic study. *Int J Gynecol Pathol* 2004; 23: 366-72.
16. Albores-Saavedra J, Latif S, Carrick KS, Alvarado-Cabrero I, Fowler MR. CD56 reactivity in small cell carcinoma of the uterine cervix. *Int J Gynecol Pathol* 2005; 24: 113-7.
17. Kaufmann O, Georgi T, Dietel M. Utility of 123C3 monoclonal antibody against CD56 (NCAM) for the diagnosis of small cell carcinomas on paraffin sections. *Hum Pathol* 1997; 28: 1373-8.

18. Kasamatsu T, Sasajima Y, Onda T, Sawada M, Kato T, Tanikawa M. Surgical treatment for neuroendocrine carcinoma of the uterine cervix. Int J Gynaecol Obstet 2007; 99: 225-8.
19. Boruta DM, Schorge JO, Duska LA, Crum CP, Castrillon DH, Sheets EE. Multimodality therapy in early-stage neuroendocrine carcinoma of the uterine cervix. Gynecol Oncol 2001; 81: 82-7.
20. Lee JM, Lee KB, Nam JH, Ryu SY, Bae DS, Park JT, et al. Prognostic factors in FIGO stage IB-IIA small cell neuroendocrine carcinoma of the uterine cervix treated surgically: results of a multi-center retrospective Korean study. Ann Oncol 2008; 19: 321-6.

---

### มะเร็งนิวโรเอนโดครินของปากมดลูก: การศึกษาทางคลินิกและพยาธิวิทยา

พนิตตา สิทธินามสุวรรณ, ฌภัทร อังคธัญกุล, เตือนใจ ช่วงสุนิช, พีรพงศ์ อินทสร

**ภูมิหลัง:** มะเร็งนิวโรเอนโดครินเป็นมะเร็งชนิดซึ่งพบได้น้อยในโรคมะเร็งปากมดลูก มะเร็งเอนโดครินส่วนใหญ่จะมีการดำเนินโรคที่รุนแรงและการพยากรณ์โรคเลวกว่ามะเร็งชนิดสแควมัสเซลล์ซึ่งเป็นชนิดที่พบบ่อยกว่าในมะเร็งปากมดลูก ดังนั้นการวินิจฉัยที่ถูกต้องจึงมีความสำคัญอย่างมาก

**วัตถุประสงค์:** เพื่อศึกษาความสัมพันธ์ระหว่างลักษณะทางคลินิกและพยาธิวิทยา รวมทั้งการตรวจทางอิมมูโนฮิสโตเคมีของมะเร็งปากมดลูกชนิดนิวโรเอนโดคริน

**วัสดุและวิธีการ:** ชิ้นเนื้อที่ได้รับการวินิจฉัยว่าเป็นมะเร็งปากมดลูกแบบปฐมภูมิทุกรายในช่วงเวลา 51 เดือนได้รับการตรวจทบทวนทางจุลพยาธิวิทยาในรายที่สงสัยมะเร็งนิวโรเอนโดครินจะได้รับการตรวจทางอิมมูโนฮิสโตเคมีที่มีแอนติบอดีจำเพาะต่อนิวโรเอนโดคริน ซึ่งได้แก่ โครโมแกรนิน ซินแนปโตไฟซิน เอ็นเอสอี และซีดี 56 ข้อมูลทางคลินิกซึ่งได้แก่การรักษาและระยะเวลาการรอดชีวิตเฉลี่ยโดยปราศจากโรคได้จากการทบทวนเวชระเบียน

**ผลการศึกษา:** ชิ้นเนื้อ 14 ราย (ร้อยละ 3.5) ซึ่งเป็นมะเร็งนิวโรเอนโดครินได้รับการค้นพบจากชิ้นเนื้อมะเร็งปากมดลูกแบบปฐมภูมิทั้งหมด 389 ราย ซึ่งได้รับการวินิจฉัยตั้งแต่วันที่ 1 ตุลาคม พ.ศ. 2545 ถึง 31 ธันวาคม พ.ศ. 2549 รายซึ่งเป็นมะเร็งนิวโรเอนโดครินแบ่งออกได้เป็นมะเร็งนิวโรเอนโดครินชนิดเซลล์ขนาดเล็ก (8 ราย) มะเร็งนิวโรเอนโดครินชนิดเซลล์ขนาดใหญ่ (3 ราย) มะเร็งชนิดผสมระหว่างมะเร็งนิวโรเอนโดครินและมะเร็งต่อม (2 ราย) และมะเร็งชนิดผสมระหว่างมะเร็งนิวโรเอนโดครินและมะเร็งสแควมัสเซลล์ (1 ราย) ผู้ป่วยทุกรายมีอาการนำคือเลือดออกผิดปกติทางช่องคลอด ค่ามัธยฐานของอายุผู้ป่วยเท่ากับ 44 ปี (34-75 ปี) ผู้ป่วย 11 ราย (ร้อยละ 78.6) ตรวจพบรอยโรคลักษณะเป็นก้อนยื่นออกมา ผู้ป่วย 5 ราย (ร้อยละ 36) มีการแพร่กระจายของมะเร็งไปยังอวัยวะที่อยู่ไกลออกไป ชิ้นเนื้อทุกรายให้ผลบวกต่อการตรวจทางอิมมูโนฮิสโตเคมีอย่างน้อยสองชนิด ชิ้นเนื้อ 9 ราย (ร้อยละ 64.3) ให้ผลบวกต่อโครโมแกรนิน 11 ราย (ร้อยละ 78.6) ให้ผลบวกต่อซินแนปโตไฟซิน 12 ราย (ร้อยละ 85.4) ให้ผลบวกต่อเอ็นเอสอี 12 ราย (ร้อยละ 85.7) และ 11 ราย (ร้อยละ 78.6) ให้ผลบวกต่อซีดี 56 เมื่อพิจารณาผลของ ซีดี 56 ในมะเร็งนิวโรเอนโดครินชนิดเซลล์ขนาดเล็กพบว่า ชิ้นเนื้อ 8 ใน 11 ราย ให้ผลบวกต่อซีดี 56 ส่วนระยะเวลาเฉลี่ยที่ปราศจากโรคเท่ากับ 17.5 เดือน ระยะเวลาการรอดชีวิตโดยเฉลี่ยเท่ากับ 23.9 เดือน

**สรุป:** มะเร็งนิวโรเอนโดครินของปากมดลูกเป็นชนิดที่พบบได้น้อยและมีพยากรณ์โรคที่ไม่ดี นอกจากการตรวจทางจุลพยาธิวิทยา การตรวจทางอิมมูโนฮิสโตเคมีโดยใช้แอนติบอดีที่มีความจำเพาะต่อ นิวโรเอนโดครินหลายชนิดพร้อมกันมีความจำเป็นในการวินิจฉัยมะเร็งชนิดนี้ เนื่องจากผลการตรวจทางอิมมูโนฮิสโตเคมีหรืออาจพบว่าผลบวกที่หลากหลาย

---