

Femoral Head-Neck Diameter and Ratio in Thais: A Cadaveric Study

Sukit Saengnipanthkul MD*,
Watchara Techasatien MD*

* Department of Orthopaedics, Faculty of Medicine, Khon Kaen University, Khon Kaen, Thailand

Objective: To report the femoral head and neck diameter in both coronal and sagittal planes, the femoral head-neck ratio, and the difference between sex in a normal Thai population.

Material and Method: One hundred two femoral bones without visible previous disease or deformity of the head, neck, and shaft that included 50 male donors and 52 female donors, with an average age of 58.8 years (range 25 to 85) were included in the present study. The measurement of the femoral head and neck diameters was performed by using Vernier calipers (scale 150 x 0.02 mm).

Results: The mean head and neck diameters in coronal and sagittal planes in male and female are 45.25, 45.23, 40.28, 40.13 mms ($p = 0.000$), and 30.80, 25.65, 27.79, 22.08 mms ($p = 0.000$), respectively. The head-neck ratio in each plane in both male and female are 1.47, 1.45 ($p = 0.257$), and 1.77, 1.83 ($p = 0.016$), respectively.

Conclusion: The very small average diameter of femoral head, especially in Thai females, should warn surgeons to carefully consider and then, perform hip resurfacing arthroplasty to avoid early complication from neck notching and mal-position. The head-neck ratio of the present study group is high enough to anticipate that postoperative anterior impingement of the neck and acetabulum or limiting hip flexion is unlikely to occur.

Keywords: Femoral head diameter; Femoral neck diameter; Femoral head-neck ratio

J Med Assoc Thai 2012; 95 (6): 790-4

Full text. e-Journal: <http://jmat.mat.or.th>

The morphology of femoral head, neck, and the normal head-neck offset or ratio is considered important to the normal hip motion or function. An abnormal relationship between the head and neck had been a speculated cause of impingement and osteoarthritis of the hip⁽¹⁻³⁾. The deficient concavity of the anterior head-neck junction or an insufficient anterior femoral head-neck offset may cause anterior femoroacetabular impingement (FAI) of the hip⁽⁴⁻⁶⁾, and cam impingement could occur in case of abnormal extension of femoral epiphysis⁽⁷⁾.

The femoral head, neck diameter and ratio have been becoming an interesting issue in the recent years following the report of the outcomes of hip resurfacing arthroplasty in many studies. As the femoral head and neck are preserved, the head and neck diameters and the head-neck ratio are more crucial for hip resurfacing. A larger diameter femoral component relative to the native femoral neck diameter

(higher head-neck ratio) resulted in a greater range of hip motion to impingement⁽⁸⁾. Small femoral component sizes have been reported by Amstutz et al⁽⁹⁾ to result in more radiographic evidence of loosening and a significantly worse survival rate. The influence of head size on the outcome of hip resurfacing has been emphasized by McBryde et al⁽¹⁰⁾ in their study including 2,123 hips (1,324 males and 799 females) with the diagnosis of osteoarthritis. The smaller head size could affect the accurate femoral component placement, and the position of the femoral component had been associated with the likelihood of neck fracture^(11,12). McBryde et al⁽¹⁰⁾ also suggested that caution should be exercised when planning a resurfacing in patients for whom the anticipated femoral head size is ≤ 42 millimeters.

The number of hip resurfacing arthroplasty for hip arthritis in young and active patients is increasing in many countries in South-East Asia, including Thailand. Asian people are known to have smaller skeletons. If small femoral heads are to be a factor affecting the outcome of hip resurfacing, data on the normal femoral head, neck diameters and femoral head-neck ratio might be beneficial to surgeons

Correspondence to:

Saengnipanthkul S, Department of Orthopaedics, Faculty of Medicine, Khon Kaen University, Khon Kaen 40002, Thailand.

Phone: 089-619-3319

E-mail: sukit@kku.ac.th

in this region to use and properly select patients for hip resurfacing in order to avoid early complications and revision. The purpose of the present study is to report the femoral head and neck diameters in coronal and sagittal planes, the femoral head-neck ratio and the difference between sexes, in a normal Thai population.

Material and Method

The present study was approved by the Khon Kaen University Ethics Committee for Human Research. One hundred and twenty dried cadaveric femoral bones of both sides and both sexes were obtained from the department of anatomy. One hundred and two bones without visible previous disease or deformity of the head, neck and shaft were included, fifty of which were from male donors and fifty-two from female donors. The average age of these donors was 58.8 years (range 25-85). The measurement of the femoral head and neck diameters was performed by using Vernier calipers (scale 150 x 0.02 mm.). The calipers were carefully placed at the middle of the head or neck, perpendicular to the neck axis in both coronal and sagittal planes, as shown in Fig. 1 and 2.

Statistical analysis

Mean, standard deviation, and 95% confidence interval of the femoral head and neck diameters in both coronal and sagittal planes were calculated by using

SPSS program (version 16). The femoral head-neck ratio in both planes was also calculated. Difference between male and female was analyzed using independent student t-test.

Results

Of all 102 femoral cadaveric bones, the mean femoral head and neck diameters, in coronal plane are 42.72 and 29.27 millimeters, and in sagittal plane are 42.63 and 23.84 millimeters, respectively. The femoral head-neck ratio in coronal and sagittal planes are 1.46 and 1.80 (Table 1).

The mean femoral head diameter in coronal and sagittal planes in male are 45.25 and 45.23 millimeters, which are significantly larger than 40.28 and 40.13 millimeters in female ($p = 0.000$). The mean femoral neck diameter in coronal and sagittal planes in male are 30.80 and 25.66 millimeters, which are also significantly larger than 27.79 and 22.09 millimeters in females ($p = 0.000$).

In coronal plane, the femoral head-neck ratio in males is 1.47 which is not significantly different from 1.46 in females ($p = 0.257$). This ratio in sagittal plane in males is 1.77 which is significantly different from 1.86 in females ($p = 0.016$).

Discussion

With the increasing popularity of hip resurfacing arthroplasty and good short to mid-term

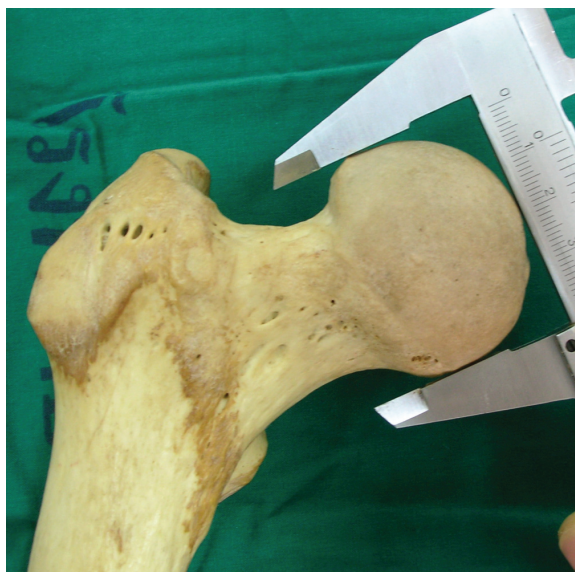

Fig. 1A Measurement of femoral head diameter in coronal plane

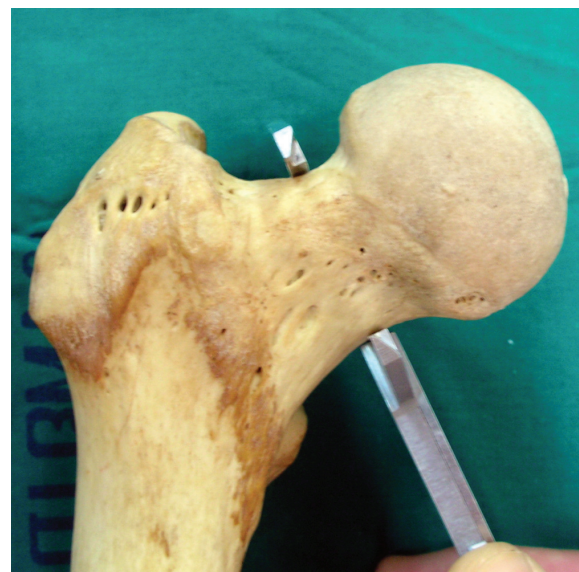

Fig. 1B Measurement of femoral neck diameter in coronal plane

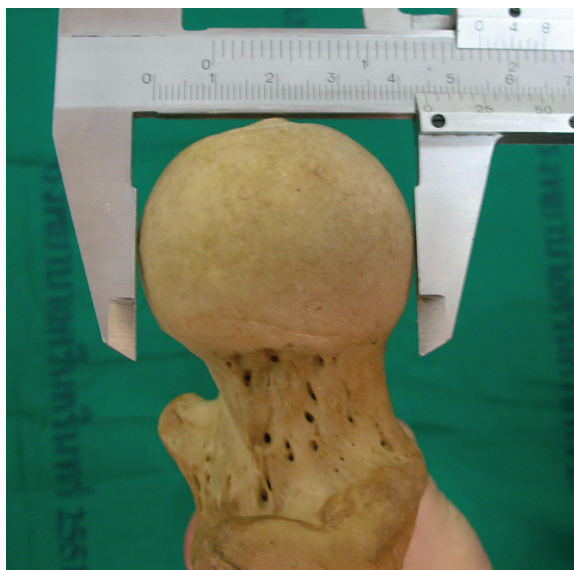

Fig. 2A Measurement of femoral head diameter in sagittal plane

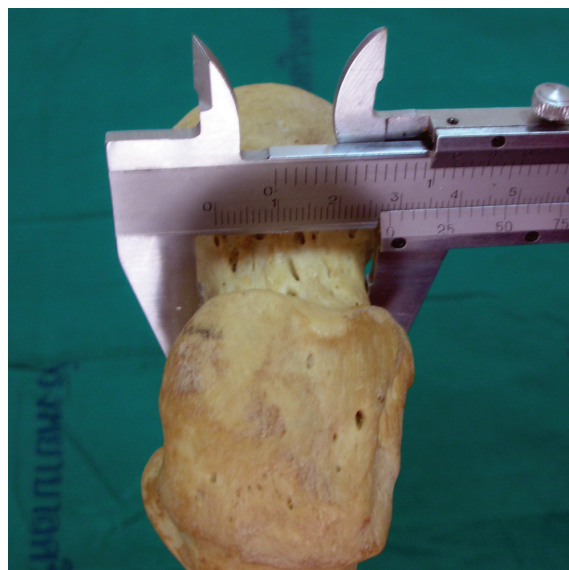


Fig. 2B Measurement of femoral neck diameter in sagittal plane

results with up to 96% prosthetic survival rates⁽¹³⁻¹⁵⁾, outcomes from recent studies demonstrated that preoperative head-neck offset, head-neck ratio^(16,17), postoperative head size, and femoral neck diameter ratio⁽¹⁸⁾ could affect the postoperative hip flexion, cause impingement of the femoral neck on the acetabular component, and is related to a higher risk of neck fracture. An increased rate of revision following hip resurfacing in women was noted in 2007 annual report of the National Joint Registry for England and Wales⁽¹⁹⁾. Furthermore, the Australian Orthopaedic Association National Joint Replacement Registry in 2008 reported that female patients had a significant rate of revision at five years, with the cumulative percentage of revision of 6.5% comparing with 2.6% in male patients⁽²⁰⁾. Attention was then brought to sex as a factor influencing the outcome of hip resurfacing. However, the

prospective study of McBryde et al⁽¹⁰⁾ demonstrated that the increased risk of revision after hip resurfacing in females with a diagnosis of osteoarthritis was related to differences in the female component size (head size) and was only indirectly related to sex.

Although it is well accepted that Asian people have a smaller skeleton, compared with Americans and Europeans, there has been no report in the medical literature about the size of the femoral head. The present study demonstrates that the mean femoral head diameter of Thai females is only 40 millimeters, which is quite small. Small femoral head size in hip resurfacing had a significantly worse survival rate at eleven years in the study of Mai et al⁽²¹⁾. More radiographic evidence of loosening in association with small component sizes was also reported by Amstutz et al⁽⁹⁾. Small femoral head size could also affect the

Table 1. Femoral head and neck diameters and ratio in coronal and sagittal planes

	Coronal plane mean (95% CI)			Sagittal plane mean (95% CI)		
	Head diameter (mm)	Neck diameter (mm)	Head-neck ratio	Head diameter (mm)	Neck diameter (mm)	Head-neck ratio
Both sex	42.72 (42.05-43.38)	29.27 (28.73-29.81)	1.46 (1.45-1.48)	42.63 (41.96-43.31)	23.84 (23.31-24.37)	1.80 (1.77-1.82)
Male	45.25 (44.60-45.90)	30.80 (30.25-31.35)	1.47 (1.45-1.49)	45.23 (44.59-45.87)	25.66 (25.14-26.17)	1.77 (1.74-1.80)
Female	40.28 (39.65-40.92)	27.79 (27.07-28.52)	1.46 (1.43-1.48)	40.13 (39.50-40.77)	22.09 (21.49-22.68)	1.86 (1.79-1.88)

accurate component placement. Notching of the neck was also more likely as the size of the femoral head decrease. Intraoperative notching of the femoral neck would increase the risk of neck fracture⁽²²⁾. To perform hip resurfacing for Thai female patients with hip arthritis, surgeons should give more consideration and be more careful. Although small size femoral head per se is not a contraindication to resurfacing, care should be taken to avoid notching and malposition of the femoral component. With the assumption that the skeletal size of people in many countries in Asia are of the same average size, result of the present study should be beneficial to surgeons in other countries. A prospective study comparing the result of hip resurfacing for patients in this region with different head sizes will give further information to this concern.

Despite the small femoral head diameter, the neck diameter of the present study samples in both sexes are proportionately small, resulting in a head-neck ratio of 1.4 in coronal plane and 1.7 to 1.8 in sagittal plane. There is no result from a previous study for comparison, but this ratio is considerably high enough to anticipate that postoperative anterior impingement of the neck and acetabulum or limiting hip flexion are unlikely to occur.

Potential conflicts of interest

None.

References

1. Elmslie RC. Remarks on aetiological factors in osteo-arthritis of the hip-joint. *Br Med J* 1933; 1: 1-46.
2. Murray RO. The aetiology of primary osteoarthritis of the hip. *Br J Radiol* 1965; 38: 810-24.
3. Solomon L. Patterns of osteoarthritis of the hip. *J Bone Joint Surg Br* 1976; 58: 176-83.
4. Notzli HP, Wyss TF, Stoecklin CH, Schmid MR, Treiber K, Hodler J. The contour of the femoral head-neck junction as a predictor for the risk of anterior impingement. *J Bone Joint Surg Br* 2002; 84: 556-60.
5. Ito K, Minka MA, Leunig M, Werlen S, Ganz R. Femoroacetabular impingement and the cam-effect. A MRI-based quantitative anatomical study of the femoral head-neck offset. *J Bone Joint Surg Br* 2001; 83: 171-6.
6. Halle B, Halle DM, Torfing T, Overgaard S. The role of acetabulum geometry and femoral head-neck ratio in the development of osteoarthritis in young men. *Hip Int* 2007; 17: 131-6.
7. Siebenrock KA, Wahab KH, Werlen S, Kalhor M, Leunig M, Ganz R. Abnormal extension of the femoral head epiphysis as a cause of cam impingement. *Clin Orthop Relat Res* 2004; 418: 54-60.
8. Williams D, Royle M, Norton M. Metal-on-metal hip resurfacing: the effect of cup position and component size on range of motion to impingement. *J Arthroplasty* 2009; 24: 144-51.
9. Amstutz HC, Beaulé PE, Dorey FJ, Le Duff MJ, Campbell PA, Gruen TA. Metal-on-metal hybrid surface arthroplasty: two to six-year follow-up study. *J Bone Joint Surg Am* 2004; 86: 28-39.
10. McBryde CW, Theivendran K, Thomas AM, Treacy RB, Pynsent PB. The influence of head size and sex on the outcome of Birmingham hip resurfacing. *J Bone Joint Surg Am* 2010; 92: 105-12.
11. Davis ET, Olsen M, Zdero R, Waddell JP, Schemitsch EH. Femoral neck fracture following hip resurfacing: the effect of alignment of the femoral component. *J Bone Joint Surg Br* 2008; 90: 1522-7.
12. Richards CJ, Giannitsios D, Huk OL, Zukor DJ, Steffen T, Antoniou J. Risk of periprosthetic femoral neck fracture after hip resurfacing arthroplasty: valgus compared with anatomic alignment. A biomechanical and clinical analysis. *J Bone Joint Surg Am* 2008; 90 (Suppl 3): 96-101.
13. Nishii T, Sugano N, Miki H, Takao M, Koyama T, Yoshikawa H. Five-year results of metal-on-metal resurfacing arthroplasty in Asian patients. *J Arthroplasty* 2007; 22: 176-83.
14. Steffen RT, Pandit HP, Palan J, Beard DJ, Gundle R, McLardy-Smith P, et al. The five-year results of the Birmingham Hip Resurfacing arthroplasty: an independent series. *J Bone Joint Surg Br* 2008; 90: 436-41.
15. Amstutz HC, Le Duff MJ. Eleven years of experience with metal-on-metal hybrid hip resurfacing: a review of 1000 Conserve Plus. *J Arthroplasty* 2008; 23: 36-43.
16. Beaulé PE, Harvey N, Zaragoza E, Le Duff MJ, Dorey FJ. The femoral head/neck offset and hip resurfacing. *J Bone Joint Surg Br* 2007; 89: 9-15.
17. Malviya A, Lingard EA, Malik A, Bowman R, Holland JP. Hip flexion after Birmingham hip resurfacing: role of cup anteversion, anterior femoral head-neck offset, and head-neck ratio. *J*

- Arthroplasty 2010; 25: 387-91.
18. Kluess D, Zietz C, Lindner T, Mittelmeier W, Schmitz KP, Bader R. Limited range of motion of hip resurfacing arthroplasty due to unfavorable ratio of prosthetic head size and femoral neck diameter. Acta Orthop 2008; 79: 748-54.
 19. National Joint Registry Steering Committee. National Joint Registry for England and Wales. 4th annual report [Internet]. 2007 [cited 2011 Nov 19]. Available from: <http://www.njrcentre.org.uk>
 20. Australian Orthopaedic Association. Annual report 2008 [Internet]. 2008 [cited 2011 Nov 19]. Available from: <http://www.aoa.org.au>
 21. Mai MT, Schmalzried TP, Dorey FJ, Campbell PA, Amstutz HC. The contribution of frictional torque to loosening at the cement-bone interface in Tharies hip replacements. J Bone Joint Surg Am 1996; 78: 505-11.
 22. Shimmin AJ, Back D. Femoral neck fractures following Birmingham hip resurfacing: a national review of 50 cases. J Bone Joint Surg Br 2005; 87: 463-4.

เส้นผ่าศูนย์กลางและสัดส่วนของหัวและคอของกระดูกฟีมอร์คนไทย: การศึกษาจากศพ

สุกิจ แสงนิพนธ์กุล, วัชระ เตชะเสถียร

วัตถุประสงค์: เพื่อรายงานเส้นผ่าศูนย์กลางและสัดส่วนของหัวและคอของกระดูกฟีมอร์ทั้งในระนาบหน้า-หลัง และซ้าย-ขวา และความแตกต่างระหว่างเพศของค่าที่ศึกษาในคนไทยปกติ

วัสดุและวิธีการ: การศึกษาใช้กระดูกฟีมอร์แห้งที่ไม่มีโรคหรือความผิดปกติบริเวณหัว คอ และลำกระดูกจำนวน 102 ชิ้น จากศพ ผู้บริจาคร่างเพศชาย 50 และเพศหญิง 52 ร่าง โดยมีอายุเฉลี่ย 58.8 ปี (พิสัย 25-85) ทำการวัดเส้นผ่าศูนย์กลางของหัวและคอกระดูกโดยใช้ คาลิเปอร์เวเนียร์ (สเกล 150 × 0.02 มม.)

ผลการศึกษา: ค่าเฉลี่ยของเส้นผ่าศูนย์กลางของหัวและคอของกระดูกฟีมอร์ ในระนาบหน้า-หลัง และซ้าย-ขวา ในเพศชาย และเพศหญิง คือ 45.25, 45.23 มม. 40.28, 40.13 มม. ($p = 0.000$) และ 30.80, 25.65 มม. 27.79, 22.08 มม. ($p = 0.000$) สัดส่วนของเส้นผ่าศูนย์กลางของหัวและคอในแต่ละระนาบสำหรับเพศชายและเพศหญิง คือ 1.47, 1.45 ($p = 0.257$) และ 1.77, 1.83 ($p = 0.016$) ตามลำดับ

สรุป: การที่พบว่าค่าเฉลี่ยเส้นผ่าศูนย์กลางของหัวกระดูกฟีมอร์ในคนไทย โดยเฉพาะเพศหญิงมีค่าน้อย เป็นข้อควรระวังที่ควรทราบสำหรับศัลยแพทย์ในการพิจารณาอย่างระมัดระวังที่จะทำการผ่าตัดเปลี่ยนผิวข้อสะโพกใหม่ เพื่อจะสามารถหลีกเลี่ยงการเกิดภาวะแทรกซ้อนจากการเกิดร่องที่คอ และการใส่ผิดตำแหน่ง สัดส่วนของหัวและคอในการศึกษากลุ่มนี้มีค่าสูงพอที่จะคาดว่าหลังการผ่าตัดการเกิดการกระทบของคอและข้อสะโพก หรือ การจำกัดการงอของข้อสะโพกไม่น่าจะเกิด