

The Accuracy and Safety for C2 Transpedicular Screw Placement by Freehand Using the Anatomical Visualization Technique Under Fluoroscopy

Thachnaronk Thanyasri, MD¹

¹ Division of Neurosurgery, Department of Surgery, Pathum Thani Hospital, Pathum Thani, Thailand

Background: The C2 transpedicular screw trajectory does not have an exact guideline for the screw placement because the anatomical variation in this region could result in injury to the vertebral artery during surgery.

Objective: To assess the accuracy and safety for C2 transpedicular screw placement by freehand under lateral fluoroscopy with an anatomical landmark using the direct visualization technique.

Materials and Methods: The present study was a retrospective data that reviewed 19 consecutive patients who underwent C2 transpedicular screw fixation by freehand placement with lateral fluoroscopic-guided and an anatomical landmark by direct visualization technique between March 2017 and February 2019 in Pathum Thani Hospital. The preoperative CT cervical spine was evaluated before the operation and postoperative CT angiogram images of the neck were taken in all patients after they were clinically stable to evaluate the vertebral artery and accuracy in the transpedicular screw placement.

Results: An anatomical landmark by direct visualization technique is accurate and safe for C2 transpedicular screw placement.

Conclusion: The C2 transpedicular screw insertion should be positioned using clear anatomical landmarks and determined by direct visualization to avoid vertebral artery injury during surgery.

Keywords: C2 transpedicular screw, Vertebral artery injury, Anatomical landmark, The anatomical visualized technique

Received 18 Nov 2019 | Revised 5 Mar 2020 | Accepted 6 Mar 2020

J Med Assoc Thai 2020;103(8): 767-76

Website: <http://www.jmatonline.com>

Although various posterior craniocervical spine screw placements have been developed to increase the ease and accuracy, there is still controversy over which is the safe surgical technique to evaluate the landmarks and measurements for C2 screw placement in the craniovertebral region. The C2 pedicle is the portion of posterolateral to the vertebral body and is located beneath the superior articular facet and anteromedial to the transverse foramen. However,

the C2 pars interarticularis is the narrowest portion of the neural arch and located between the superior and inferior articular processes. That being stated, the locations of the C2 pedicle and pars interarticularis are still controversial⁽¹⁻⁴⁾. The transpedicular C2 screw fixation is longer and has an angle that is more medial, thus, makes the transpedicular screws have a higher rate of successful fusion and be more biomechanically stable. However, there is a higher incidence to develop some vertebral artery injury than with the pars screw^(3,5-8).

The C1 to C2 vertebrae are called atypical vertebrae. They have unusual shapes and architecture that result in injury to the vertebral artery during surgery in this region⁽⁸⁾. The variation in the effectiveness and safety technique in preventing screws from breaching the cortical surface of the pedicle in the many studies is significant. The various entry points, angles, and trajectories described in those studies for these screws can act only as a rough guide^(3,7,9). The risk of injury can be reduced with the aid of preoperative imaging and a navigation system

Correspondence to:

Thanyasri T.

Division of Neurosurgery, Department of Surgery, Pathum Thani Hospital, Pathum Thani 12000, Thailand.

Phone: +66-2-5988888, **Fax:** +66-2-5810027

Email: thachnaronk@yahoo.com

How to cite this article:

Thanyasri T. The Accuracy and Safety for C2 Transpedicular Screw Placement by Freehand Using the Anatomical Visualization Technique Under Fluoroscopy. *J Med Assoc Thai* 2020;103:767-76. doi.org/10.35755/jmedassocthai.2020.08.10864

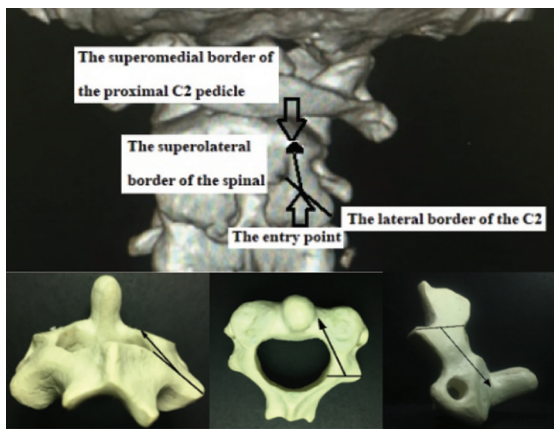


Figure 1. The entry point adjusted to place the screw at the middle point between the lateral border of the C2 and the superolateral border of the spinal canal. The screw trajectory to the superomedial border of the proximal C2 pedicle.

to improve screw accuracy. However, they are not routinely performed for all approaches because of the limited application due to its high cost and unavailable in all institutions^(10,11). The freehand placement of the cervical transpedicular screw under fluorography is used as a technique for transpedicular screw placement in the cervical spine⁽¹²⁾.

The aim of the present study was to assess the accuracy and safety for C2 transpedicular screw placement by freehand under lateral fluoroscopy with an anatomical landmark using the direct visualization technique. Although descriptions of the C2 transpedicular screw have been reported in many studies, the proposed screw trajectory is still different.

Materials and Methods

The present study was a retrospective data review of 19 consecutive patients with unstable or deformities in the occipitocervical spine that underwent C2 transpedicular screw fixation between March 2017 and February 2019 in Pathum Thani Hospital. Preoperative CT cervical spine evaluated before the operation and postoperative CT angiogram images of the neck (0.2 mm slice thickness) were taken in all patients after they were clinically stable, for evaluating vertebral artery and accuracy of the transpedicular screw placement. When the different three planes on the CT scan image were set-up, the superior and medial angulation were measured parallel to the medial and superior aspect of the C2 pedicle with the sagittal and axial planes, respectively (Figure 1)⁽²⁾. The length and diameter of the cervical screw was derived from the operative record.

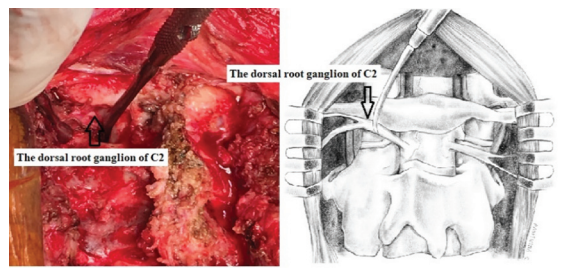


Figure 2. The dorsal root ganglion of C2 was retracted in a superomedial direction and guarding by Penfield retractor.

The present study was approved by the Institutional Review Board of the author's institution (no. 0032.203.3/21), which waived the requirement for informed consent due to the retrospective nature of the study.

Surgical technique

Under general anesthesia, the patient was placed in a prone position under the guidance of lateral fluoroscopy. The head was stabilized in a halo ring and the neck was held in alignment by skull tongs and maintained in a neutral position. A midline skin incision was made, and paravertebral muscles were retracted laterally to cover the pathologic lesion. The subperiosteal exposure was performed to expose the C2 lateral border of the lateral mass and facet joints. The soft tissue was removed to expose the dorsal root ganglion of C2. The superomedial border of the C2 pars interarticularis and pedicle was decorticated. The posterior surface of the lateral atlantoaxial articular capsule was dissected to identify atlantoaxial space and the superomedial border of proximal C2 pedicle that was an important landmark for screw trajectory and ability to control the point of directional drilling clearly (Figure 1)⁽³⁾.

The entry point was adjusted to place the screw at the middle point between the superolateral border of the spinal canal and the lateral border of the C2, then the high-speed 2-millimeter diamond head drill bit from the entry point and the trajectory parallel to superomedial border the spinal canal. The dorsal root ganglion of C2 was retracted in a superomedial direction and guarding by Penfield retractor (Figure 2). A pilot hole deep about 10 millimeters, a sounder was used to check whether there was no breaching out to either the spinal canal or the vertebral foramen.

When the cancellous channel of the pedicle was not perforated to the spinal canal or transverse foramen, the high-speed diamond burr drilled to the vertebral body. After tapping was done, the

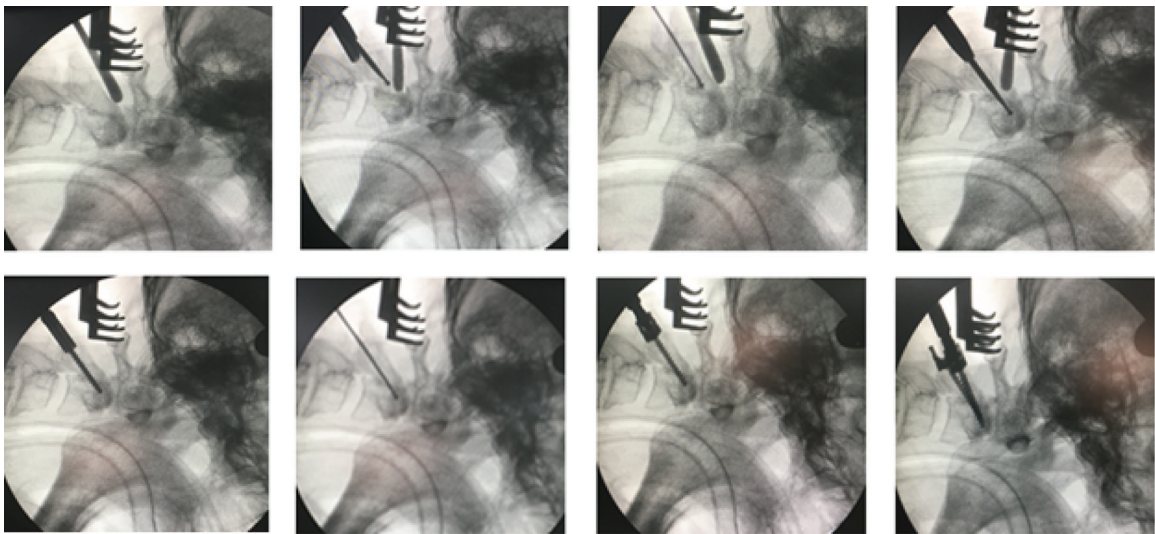


Figure 3. The high-speed diamond burr drill to C2 pedicle and deep about 10 millimeters, after a sounder was used to check then drill again to the vertebral body. After tapping was done the polyaxial titanium pedicular screw was inserted.

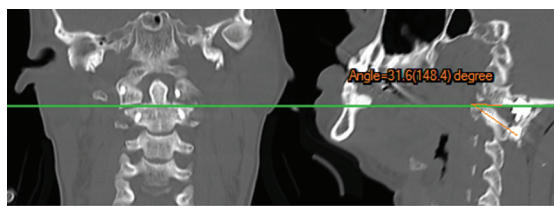


Figure 4. The superior angulation was measured as a superior aspect of the C2 pedicle and parallel to the superior facet in the coronal and sagittal planes.

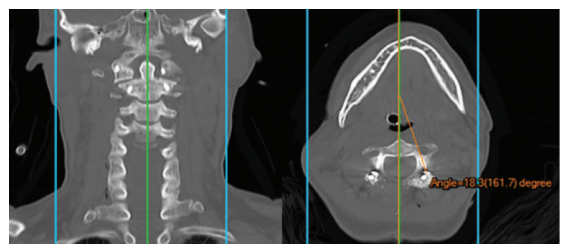


Figure 5. The medial angulation was measured parallel to the middle point of the odontoid in the coronal and axial planes.

created hole was checked again by a sounder and the polyaxial titanium screw 3.5 millimeters in diameter and appropriated 24 to 26 millimeters in length was inserted. The trajectory for the insertion of the C2 screw was guided by anatomic landmarks with lateral fluoroscopic imaging (Figure 3).

Measurement

When all different three planes on postoperative CT scan images were set-up. The superior angulation was measured a superior aspect of the C2 pedicle and parallel to the superior facet in the coronal and sagittal planes (Figure 4). The medial angulation was measured parallel to the middle point of the odontoid in the coronal and axial planes (Figure 5). However, measurement of the medial inclination of the pars interarticularis was difficult because of its relatively superior angulation⁽¹³⁾.

Accuracy of C2 screw placement was evaluated in the axial CT images and classified into three grades, grade 0 (G-0) correct placement, grade 1

(G-1) malposition by less than half screw diameter, grade 2 (G-2) malposition by more than half screw diameter⁽¹²⁾.

Statistical analysis

Descriptive statistics were used to describe demographic data of the patients and normality tests. The degrees of the superior and medial angulation of C2 transpedicular screw directions were determined by two spine surgeons. The randomized measurement performed in all patients prevented the selection and insured against the accidental bias from age, gender, and clinical presentation. The data were compared to the difference between the superior and medial angulation, and the right and left angulation measurements. The paired sample t-test will be used for comparing the difference between the first and second measurements and the right and left superior and medial angulation by one-way ANOVA test. All

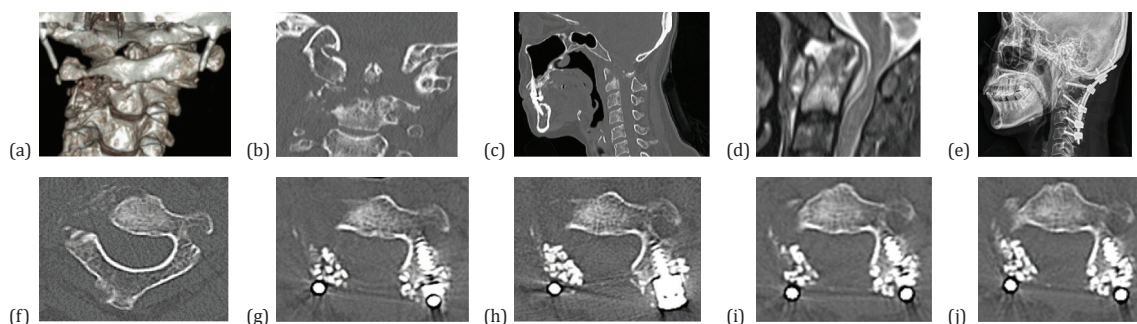


Figure 6. The 3D and coronal CT images illustrating the C1 to C2 tuberculous spondylitis with lytic destruction of the right portion of the vertebral body and pedicle (a-c) MRI show epidural abscess compress the cervicomedullary junction (d) post occipitocervical fixation (e) pre and post right C2 transpedicular screw and follow up at 1, 3, 6, 12 months (f-j).

Table 1. Demographic data of patients (n=19)

Characteristics	Operations	Value
Sex: male/female		15/4
Age (year); mean (min-max)		58.11 (20 to 82)
Indication of surgery		
Burst fracture C1 with transverse ligament rupture	Posterior C1 to C2 fixation	1
Atlantoaxial dislocation with transverse ligament rupture	Posterior C1 to C2 fixation	2
Irreducible C1 to C2 subluxation with cord compression	Transoral odontoidectomy with occipito-C2 to C3 fixation and C1 to C2 wiring	1
Unstable spondylolisthesis of axis	Anterior C2 to C3 and posterior C2 to C3 fixation	1
Spondylolisthesis of axis with facet dislocation	Posterior C1 to C3 fixation	1
Unstable fracture odontoid process	Posterior C1 to C2 fixation	5
Os odontoides	Posterior C1 to C2 fixation	4
Rheumatoid arthritis with cord compression	Posterior C1 to C2 fixation with laminectomy	1
Rheumatoid arthritis with cord compression	Posterior C1 to C3 fixation with laminectomy	1
Cervicomedullary junction tuberculosis and atlantoaxial dislocation with cord compression	Occipito-C1 to C4 fixation and laminectomy	1
Tuberculous epidural abscess C3 to C5 with cord compression	Posterior C2 to C5 fixation with laminectomy and pus drainage	1

statistical analyses were performed using IBM SPSS Statistics software, version 23.0 (IBM Corp., Armonk, NY, USA).

Results

The nineteen patients underwent posterior cervical fixation and 37 transpedicular screws were inserted. One tuberculous spondylitis patient could not have the screws placement because the right side of C1-2 was destroyed (Figure 6). Most of patients were male and averaged 58.11 (range 20 to 82) years old. Most of the indication for surgery was upper cervical trauma (Table 1). One patient had minimal lateral perforation grade 1 (G-1) at the right side and minimal medial perforation (Figure 7) and one

patient had partial tear right vertebral artery between dissected the lateral border of axis but could control bleeding by gel foam. In two patients, there were anterior and posterior surgical approaches, irreducible C1-2 subluxation was performed with the transoral odontoidectomy and occipitocervical screws fixation (Figure 8) and unstable C2 to C3 spondylolisthesis was performed with the anterior cervical plate and posterior C2-3 screws fixation (Figure 9). All the patients did not have neuro-vascular complications after surgery.

The mean of right superior angulation in first and second measurements was 31.39° and 30.33°, while the mean of left superior angulation in first and second measurements was 31.87° and 30.18°.

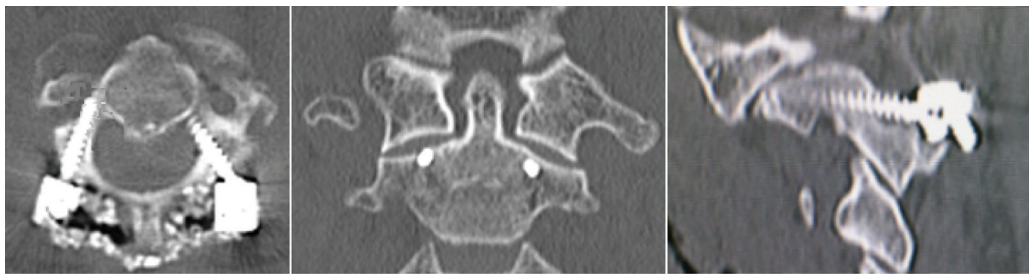


Figure 7. Minimal lateral perforation grade 1 (G-1) on the right side and minimal medial perforation.

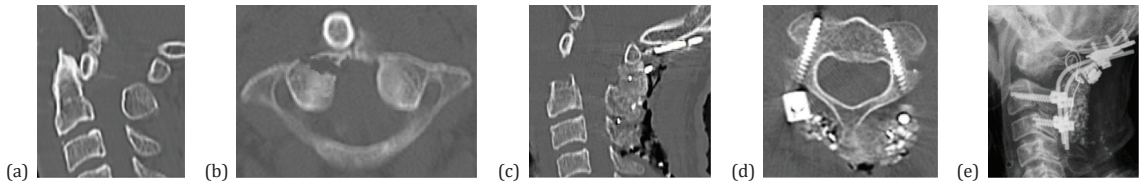


Figure 8. Irreducible C1-2 subluxation (a, b) and post transoral odontoidectomy with occipitocervical fixation (c-e).

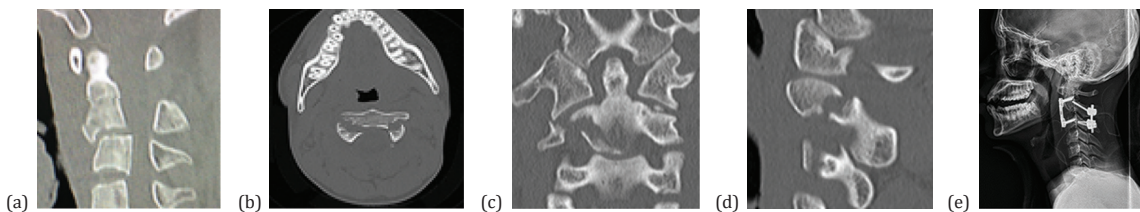


Figure 9. Traumatic C2 to C3 spondylolisthesis (a-d), post anterior and posterior C2 to C3 fixation (e).

Table 2. The paired sample t-test to determine the difference in mean of superior and medial angulation between the first and second measurements

	n	Mean±SD	Min-max	p-value
Right superior angulation				0.07
1st measurement	18	31.39°±8.97°	18.4° to 53.9°	
2nd measurement	18	30.33°±8.55°	16.5° to 48.3°	
Left superior angulation				0.06
1st measurement	19	31.87°±10.26°	16.6° to 53.9°	
2nd measurement	19	30.18°±9.03°	14.8° to 46.6°	
Right medial angulation				0.50
1st measurement	18	19.54°±6.74°	9.7° to 36.2°	
2nd measurement	18	18.96°±5.36°	10.4° to 30.2°	
Left medial angulation				0.32
1st measurement	19	22.00°±8.46°	11.8° to 37.8°	
2nd measurement	19	20.74°±7.55°	11.4° to 37.3°	

SD=standard deviation

The mean of right medial angulation in first and second measurements was 19.54° and 18.96°, while

the mean of left medial angulation in first and second measurements was 22.00° and 20.74°, respectively. The paired sample t-test revealed no significant difference between the first and second measurements (Table 2). Besides, the one-way analysis of variance revealed no significant difference between right and left superior and medial angulation (Table 3).

Discussion

The C2 transpedicular screw was described by Goel and Laheri in 1994 as part of a plate and screw construct that was utilized for posterior atlantoaxial fixation and later popularized by Harms and Melcher in 2001⁽¹⁴⁻¹⁶⁾. The transpedicular screw and rod constructs have gained popularity in cervical spine pathologies as it provides increased stability. Although the biomechanical study shows the C2 transpedicular screw generated a greater insertional torque and pull-out strength in comparison to lateral mass, pars, and laminar screws, the screw placement demands the precise and the exact three dimensional understanding of the anatomy in the atlantoaxial region^(5,17,18).

Table 3. The one-way analysis of variance to determine the difference between left and right angulation measurement

	df	Sum of squares	Mean square	F	p-value
Superior angulation					
Right: 1st measurement	3	96.07	32.02	0.36	0.78
Left: 1st measurement	70	6,162.85	88.04		
Right: 2nd measurement					
Left: 2nd measurement					
Total	73	6,258.92			
Medial angulation					
Right: 1st measurement	3	103.28	34.43	0.64	0.60
Left: 1st measurement					
Right: 2nd measurement	70	3,792.09	54.17		
Left: 2nd measurement					
Total	73	3,895.36			

Recently, differentiating between a pars screw and a transpedicular screw have been confusing, possibly because the C2 superior articular process is almost as anterior as the vertebral body^(1,2).

Xu et al studied dry pedicle C2 cervical vertebrae in American people and found that the medial angulation was 33° and the superior angulation was 20°⁽¹⁹⁾. Yuan et al study in the external morphologic dry C2 vertebrae in Chinese adults revealed that the mean the medial angulations were 41.8° and 43.4° on the right and left sides and the superior angulations

were 10.6° and 11.5° on the right and left sides, respectively⁽⁴⁾. Nitising et al studied the dry C2 vertebrae in Thai. The mean of the medial angulation was 29.88° and 29.55° on the right and left sides and the superior angulation were reported at 27.66° and 28.35° on the right and left sides, respectively⁽²⁾. Bunmaprasert et al studied the radiography in Thai adults. The mean of the medial angulation was 38.95° (28.07° to 52.85°) and the superior angulation was reported at 27.54° (20.65° to 33.95°)⁽¹³⁾.

Although the previous studies showed the medial and superior angulations of C2 anatomical study were different from the transpedicular trajectory, the multiple landmarks and measurements have been used by spine surgeons. These are often varied in the literature⁽²⁰⁾ (Table 4). However, the area of the entry point for screw insertion, the lateral masses and beneath the facets, as well as near the bony endplates suggests that having a good cancellous bone quality and a high density of trabecular bone is important⁽⁶⁾.

The entry point

Placement of screws into the C2 pedicle should be preceded by careful avoidance of complications such as vertebral artery injury because of the anatomic variation of the structures. The third part of the vertebral artery running within the C2 groove is a transitional segment that is variable and different from the other parts and the proximity of the C2 pedicle to the transverse foramen, which are considerable risks

Table 4. Overview of C2 pedicle screw techniques

Surgical technique	The entry point	Direction
Ebraheim, et al. 1996 ⁽²¹⁾	5 mm inferior to the lateral border of the C2 and 7 mm lateral to the lateral border of the spinal canal	30° toward the midline in the transverse plane and cephalad in the sagittal plane
Harms, et al. 2001 ⁽¹⁵⁾	The cranial and medial quadrant of the isthmus surface of C2	Approximately 20° to 30° in a convergent and cephalad direction
Mummaneni and Haid 2005 ⁽¹⁷⁾	5 mm rostral and 1 mm lateral to the inferior medial part of the inferior articular facet of C2	20° up angle and 15° to 25° medial from the entry point
Stulik, et al. 2007 ⁽²²⁾	2 mm from the medial border and 5 mm from the caudal border of the C2 inferior articular process	20° to 30° cranially and convergent direction at an angle of 20° to 25°
Chun and Bak 2011 ⁽²³⁾	4 mm lateral to and 4 mm caudal to from the superior line of the lamina to the isthmus of the pars interarticularis	Approximately 20° to 30° in a medial and 20° cephalad direction.
Ajayi, et al. 2016 ⁽¹⁸⁾	5 mm rostral and 1 mm medial to the inferomedial aspect of the inferior articulating surface of C2	15° to 25° of medial angulation
Tawfik, et al. 2018 ⁽⁹⁾	The nutrient foramen of the pedicle	15° to 25° with medial angulation and just lateral to the medial aspect of the spinal canal.
Sai Kiran, et al. 2018 ⁽³⁾	5 mm rostral and 1 mm lateral to the inferior medial part of the inferior articular facet of C2	Superior angulation of 20° and medial angulation of 15° to 25°
Marco, et al. 2018 ⁽²⁴⁾	Approximately 2 mm lateral to the medial wall of the pedicle and 3 mm cephalad to the C2 to C3 facet.	approximately 20° medial angulation and 30° cephalad angulation

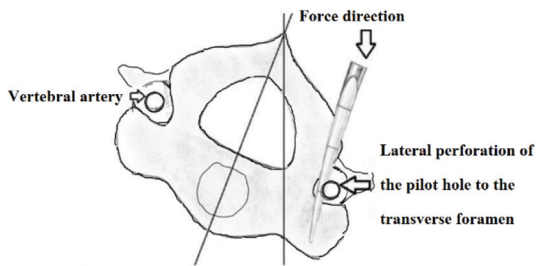


Figure 10. The drawing shows using a blunt pedicle probe results in the cervical spine deformation and lateral perforation of the pilot hole to the transverse foramen.

of intraoperative injury that may cause malposition of screw and catastrophic consequences. This is directly related to patient mortality and morbidity^(18,25).

The present study found that the entry point was not significantly different from the previous literature. However, the entry point measurement for the screw trajectory in Thai people might be different from Westerner because of the anatomy of the Asian⁽¹³⁾. The entry point could be the point that visualizes and simplifies identifying landmarks during the operation. Furthermore, the starting point should be generally more cephalad than the vertebral artery, thereby decreasing the risk of injury to the vertebral artery. The medial angulation should be set at an angle that minimizes the vertebral artery groove violation^(5,26).

The trajectory of screw

The transpedicular screw trajectory is still the rough guideline for the screw placement in the literature. The screw insertion should be dissecting the anatomical landmarks clearly and determined by direct visualization. A high-riding vertebral artery and narrow pedicles of C2 are the two anatomic variations that have been suggested to be associated to increase the risk of vertebral artery injury. The reduced risk of the vertebral artery for freehand technique requires visualization of the lateral atlantoaxial joint and the direction of the screw trajectory which coagulated the epidural venous plexus and retraction of the C2 nerve root were readily visible and widely exposed to facilitate transpedicular screw placement^(15,27). The decortication of the superomedial border of the C2 pars interarticularis and pedicle is the most important step in C2 pedicle screw placement because the angulation for screw placement was guided by direct visualization of the superomedial border of the pedicle used as reference plan through C1 to C2 joint space. There was possible irritation of the C2 ganglion by

retraction, but there was no instances of occipital neuralgia^(3,10,15).

The trajectory superomedial of the C2 pedicle along the strong medial cortex of the pedicle is thicker than the lateral cortex. The lateral cortical wall of the cervical pedicle is the thinnest, smaller dimension of the pedicle and the extreme medial angulation of the cervical pedicle probably explains why cervical transpedicular screw misplacement is more likely to happen laterally. Moreover, the high riding vertebral artery extends superiorly deeper into the undersurface of the superior articular facet in the vertebral artery cave and inadequate medial angulation that may result in vertebral artery injury and serious complications^(10,20,21). In the present study, the operation used the high-speed diamond head burr introduced into the cancellous core of the pedicle aided decreased the chances of lateral perforation of the pilot hole compared with the use of a blunt pedicle probe (Figure 10)^(11,15,28,29). Moreover, the high-speed drill reduced the force required to make the pilot hole and transmitted proper trajectory to the pedicle consequently decreased the deformation of the cervical spine during surgery⁽²⁹⁾.

The accuracy and safety for C2 transpedicular screw placement

Although the exact locations of the C2 pedicle and pars interarticularis are still controversial to the appropriate entry point and screw trajectory, there are no difference in bone density and trabecular bone between the pedicle and pars interarticularis^(1,2). The present study found that the measurement of the C2 pedicle revealed that the medial angulation was lesser than in some anatomic studies and that there was no significant difference between right and left superior and medial angulation^(2,4,13,19). However, the mean of the superior and medial, and the right and left angulation for the C2 transpedicular were similar in literatures^(9,15,17,18,22-24). In addition, to avoid catastrophic consequences of vertebral artery injury, using a small size, more cephalad in the entry point and direction of the screw is parallel the superomedial border of the C2 pedicle is considered for pedicle screw trajectory because it is far from the vertebral artery, which is located inferiorly and laterally to the C2 pedicle and might be decreasing risk of injury to the vertebral artery (Figure 11)⁽¹⁵⁾. Placement of a 3.5- or 4.0-millimeters screw in diameter was considered a low risk of injuring the vertebral artery and manipulation of polyaxial screws in C2 simplify the following reduction maneuver and fixation^(15,24).

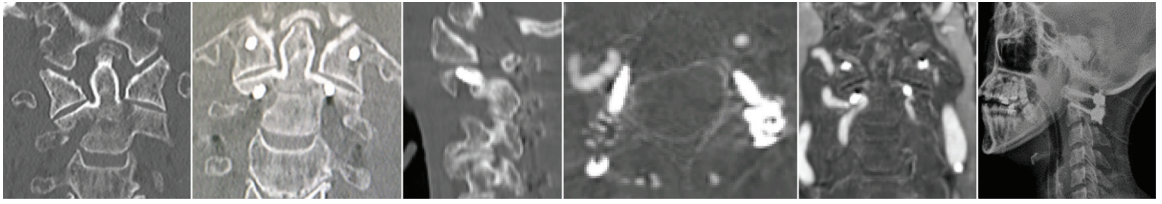


Figure 11. The polyaxial titanium screw 3.5 millimeter in diameter insert more cephalad than the vertebral artery is thereby decreasing the risk of vertebral artery injury in a high-riding vertebral artery and narrow pedicles of C2.

The appropriate position and angulation for the C2 screw fixation may not be identical as the 4.5 millimeters in diameter screws are not suitable for C2 fixation because of the increased risk of vertebral artery injury and nerve root injury⁽¹³⁾. However, the polyaxial titanium screw 3.5 millimeters in diameter and 24 to 26 millimeters in length (24 millimeters in female, 26 millimeters in male) might be suitable. The 4.0 millimeters in diameter cannot be routinely used in Thai people⁽²⁾.

The risk of injury can be reduced with the aid of preoperative angiogram imaging that expresses the distance of the lateral pedicle to the vertebral artery. The diameter of the transverse foramen compare the vertebral artery or occupation ratio, and the space available in the transverse foramen for the displacement of the vertebral artery, which helpful in determining screw insertion that does not lead to vascular injury^(10,20,30). The other way to avoid the risk of neurovascular injury is to make sure that the length of the screw should be less than the distance between the entry point and the transverse foramen in case that cannot be avoided⁽²⁾. However, the C2 transpedicular screws cannot be used in some patients due to various C2 anatomical deformation, the intralaminar screw, or pars screw that can also be an alternative effective surgical technique with lesser chances of injury to the vertebral artery and can usually be placed safely^(5,7).

Limitation

The present study was a retrospective study from a single institute that may cause unavoidable sample selection with limited sample size and pathological conditions. Moreover, the preoperative angiogram was not performed in all patients at the author institution.

Conclusion

The C2 transpedicular screw trajectory is still a rough guideline for the screw placement. The screw insertion should be cleanly dissected at anatomical landmarks and determined by direct visualization

to assure accuracy and safety. The high-speed drill with superior and medial angulation should be determined by direct visualization. It reduces the force transmitted, is the proper trajectory to the pedicle, and avoids the vertebral artery injury during the operation. The polyaxial titanium screw 3.5 millimeters in diameter and 24 to 26 millimeters in length might be suitable in Thai people. The risk of injury can be reduced with the aid of preoperative imaging and the navigation system to improve screw accuracy, but these procedures are not routinely performed in all institutions. However, when the C2 transpedicular screw cannot be used in some patients, the intralaminar screw or pars screw can be an alternative technique.

What is already known on this topic?

The C2 transpedicular screw trajectory has been a rough guideline for the screw placement. There are various entry points, angles, and trajectories described in literature. There is still no consensus on the accurate and safe technique to prevent catastrophic consequences.

What this study adds?

The study found that the measurement of the C2 pedicle revealed superior angulation is more cephalad than in the anatomic studies. Using a small screw size in diameter, more cephalad in the entry point, the direction of the screw is parallel to the superomedial border of the C2 and dissected anatomical landmarks clearly and determined by direct visualization lead to the greater accuracy and safety for C2 transpedicular screw placement by freehand using the anatomical visualization technique under fluoroscopy.

Acknowledgement

The author would like to express special thanks to Pathum Thani Hospital director Prasit Manacharoen MD for all the support to the neurosurgical and surgical spine team. In addition, the author would like to express special thanks to Miss Sattabongkoch

T Maneewong for her drawing. Finally, thanks to all relevant officials for their co-operation in the present study.

Conflicts of interest

The author declares no conflict of interest.

References

1. Ebraheim NA, Fow J, Xu R, Yeasting RA. The location of the pedicle and pars interarticularis in the axis. *Spine (Phila Pa 1976)* 2001;26:E34-7.
2. Nitising A, Charoontamwong K, Jetjumnong C, Phonwijit L, Sitthinamsuwan B. Anatomical study of C2 pedicle and pars interarticularis in thai population. *J Med Assoc Thai* 2017;100 Suppl 3:S117-21.
3. Sai Kiran NA, Sivaraju L, Vidyasagar K, Aryan S, Raj V, Rajagopal N, et al. Safety and accuracy of anatomic and lateral fluoroscopic-guided placement of C2 pars/pedicle screws and C1 lateral mass screws, and freehand placement of C2 laminar screws. *World Neurosurg* 2018;118:e304-15.
4. Yuan F, Yang HL, Guo KJ, Li JS, Xu K, Zhang ZM, et al. A clinical morphologic study of the C2 pedicle and isthmus. *Eur Spine J* 2013;22:39-45.
5. Lehman RA Jr, Dmitriev AE, Helgeson MD, Sasso RC, Kuklo TR, Riew KD. Salvage of C2 pedicle and pars screws using the intralaminar technique: a biomechanical analysis. *Spine (Phila Pa 1976)* 2008;33:960-5.
6. Heggness MH, Doherty BJ. The trabecular anatomy of the axis. *Spine (Phila Pa 1976)* 1993;18:1945-9.
7. Elliott RE, Tanweer O, Boah A, Smith ML, Frempong-Boadu A. Comparison of safety and stability of C-2 pars and pedicle screws for atlantoaxial fusion: meta-analysis and review of the literature. *J Neurosurg Spine* 2012;17:577-93.
8. Cacciola F, Phalke U, Goel A. Vertebral artery in relationship to C1-C2 vertebrae: an anatomical study. *Neurol India* 2004;52:178-84.
9. Tawfik T, Iwanaga J, Yilmaz E, Choi P, Wilson C, Simonds E, et al. Anatomic study of nutrient foramina of posterior axis with application to C2 pedicle screw placement. *World Neurosurg* 2018;113:e408-13.
10. Agrawal M, Devarajan LJ, Singh PK, Garg A, Kale SS. Proposal of a new safety margin for placement of C2 pedicle screws on computed tomography angiography. *World Neurosurg* 2018;120:e282-9.
11. Jo DJ, Seo EM, Kim KT, Kim SM, Lee SH. Cervical pedicle screw insertion using the technique with direct exposure of the pedicle by laminoforaminotomy. *J Korean Neurosurg Soc* 2012;52:459-65.
12. Hojo Y, Ito M, Suda K, Oda I, Yoshimoto H, Abumi K. A multicenter study on accuracy and complications of freehand placement of cervical pedicle screws under lateral fluoroscopy in different pathological conditions: CT-based evaluation of more than 1,000 screws. *Eur Spine J* 2014;23:2166-74.
13. Bunmaprasert T, Treenarong N, Khamkhad A. Appropriate size and angulation for axis screw placement. *J Med Assoc Thai* 2015;98:188-95.
14. Goel A, Laheri V. Plate and screw fixation for atlanto-axial subluxation. *Acta Neurochir (Wien)* 1994;129:47-53.
15. Harms J, Melcher RP. Posterior C1-C2 fusion with polyaxial screw and rod fixation. *Spine (Phila Pa 1976)* 2001;26:2467-71.
16. Huang DG, Hao DJ, He BR, Wu QN, Liu TJ, Wang XD, et al. Posterior atlantoaxial fixation: a review of all techniques. *Spine J* 2015;15:2271-81.
17. Mummaneni PV, Haid RW. Atlantoaxial fixation: overview of all techniques. *Neurol India* 2005;53:408-15.
18. Ajayi O, Moisi M, Chapman J, Oskouian RJ, Tubbs RS. C2 pedicle screw placement: a novel teaching aid. *Cureus* 2016;8:e630.
19. Xu R, Nadaud MC, Ebraheim NA, Yeasting RA. Morphology of the second cervical vertebra and the posterior projection of the C2 pedicle axis. *Spine (Phila Pa 1976)* 1995;20:259-63.
20. Tubbs RS, Granger A, Fisahn C, Loukas M, Moisi M, Iwanaga J, et al. The vertebral artery cave at C2: Anatomic study with application to C2 pedicle screw placement. *World Neurosurg* 2016;94:368-74.
21. Ebraheim N, Rollins JR Jr, Xu R, Jackson WT. Anatomic consideration of C2 pedicle screw placement. *Spine (Phila Pa 1976)* 1996;21:691-5.
22. Stulik J, Vyskocil T, Sebesta P, Kryl J. Atlantoaxial fixation using the polyaxial screw-rod system. *Eur Spine J* 2007;16:479-84.
23. Chun HJ, Bak KH. Targeting a safe entry point for c2 pedicle screw fixation in patients with atlantoaxial instability. *J Korean Neurosurg Soc* 2011;49:351-4.
24. Marco RAW, Phelps CI, Kuo RC, Zhuge WU, Howard CW, Kushwaha VP, et al. Radiologic analysis of C2 to predict safe placement of pedicle screws. *Int J Spine Surg* 2018;12:30-6.
25. Lee HJ, Kim JH, Kim IS, Hong JT. Anatomical evaluation of the vertebral artery (V2) and its influence in cervical spine surgery. *Clin Neurol Neurosurg* 2018;174:80-5.
26. Yeom JS, Buchowski JM, Kim HJ, Chang BS, Lee CK, Riew KD. Risk of vertebral artery injury: comparison between C1-C2 transarticular and C2 pedicle screws. *Spine J* 2013;13:775-85.
27. Patel AJ, Gressot LV, Boatey J, Hwang SW, Brayton A, Jea A. Routine sectioning of the C2 nerve root and ganglion for C1 lateral mass screw placement in children: surgical and functional outcomes. *Childs Nerv Syst* 2013;29:93-7.
28. Hlubek RJ, Bohl MA, Cole TS, Morgan CD, Xu DS, Chang SW, et al. Safety and accuracy of freehand versus navigated C2 pars or pedicle screw placement. *Spine J* 2018;18:1374-81.
29. Mahesh B, Upendra B, Mahan RS. The medial cortical pedicle screw--a new technique for cervical pedicle

screw placement with partial drilling of medial cortex.
Spine J 2014;14:371-80.

30. Misenhimer GR, Peek RD, Wiltse LL, Rothman SL,

Widell EH Jr. Anatomic analysis of pedicle cortical
and cancellous diameter as related to screw size. Spine
(Phila Pa 1976) 1989;14:367-72.