

Nasoalveolar Rhabdomyosarcoma Presenting as Traumatic Nasal Injury: A Rare Case Report Mimicking Organized Hematoma

Thunyarat Wiwattanaputit, MD¹, Vorawan Charoonratana, MD¹, Suchet Chinpairoj, MD², Usaporn Prapaisit, MD², Kanet Kanjanapradit, MD³

¹ Department of Radiology, Prince of Songkla University, Hat Yai, Songkhla, Thailand; ² Department of Otolaryngology, Prince of Songkla University, Hat Yai, Songkhla, Thailand; ³ Department of Pathology, Prince of Songkla University, Hat Yai, Songkhla, Thailand

The nasoalveolar region is an uncommon area of all rhabdomyosarcoma (RMS) cases. RMS has a bimodal distribution in children, occurring in those aged two to four years and 12 to 16 years. The authors presented an unusual case of alveolar RMS that presented at a young age, in an uncommon region, with an atypical presentation, and imaging findings mimicking organized hematoma and complicated nasoalveolar cyst. Confounding as a result of the presence of trauma can delay diagnosis and treatment.

Keywords: Nasoalveolar; Rhabdomyosarcoma; Hematoma

Received 7 November 2022 | Revised 11 June 2023 | Accepted 12 June 2023

J Med Assoc Thai 2023;106(7):743-6

Website: <http://www.jmatonline.com>

The nasoalveolar mass in children has a wide range of differential diagnoses, from benign to malignant⁽¹⁾. Rhabdomyosarcoma (RMS) is a common solid tumor in the pediatric population, accounting for 3% to 4% of all pediatric malignancies. It has a bimodal distribution in children, occurring in those aged two to four years and 12 to 16 years⁽²⁾. Although, about 35% to 40% of cases involve the head and neck, especially the nasopharynx, paranasal sinuses, middle ear, mastoid bones, and facial soft tissues, the nasoalveolar region is an uncommon area^(1,2). The authors reported an unusual case of alveolar RMS that presented at a young age, in an uncommon site, with an atypical presentation, and imaging findings mimicking organized hematoma and complicated nasoalveolar cyst (NC)⁽³⁻⁶⁾. Confounding as a result of the presence of trauma can delay diagnosis and

treatment.

Case Report

A 1-year-old male infant with a history of persistent right-sided nasal swelling presented with obstructive symptoms for two months after trauma to the same site. He had no underlying disease. On clinical evaluation, he had a painless right nasoalveolar swelling, no fluctuation, no alteration in color of the overlying skin, and the initial diagnosis was a hematoma. This present case report emphasized that persistent nasal swelling with nasal obstruction should be transferred to a specialist for the definitive diagnosis and appropriate treatment. Nasal endoscopy performed by an otolaryngologist found a bulging right inferior turbinate area with right-sided nasal obstruction, and computed tomography (CT) was requested to exclude the presence of a mass and NC.

A precontrast and contrast-enhanced CT study of the sinus showed a well-defined mass with heterogeneous enhancement and internal septate-like appearance involving the right nasoalveolar region with right anterior nasal obstruction and no adjacent organ invasion (Figure 1). Bone changes were seen as mild scalloping of the adjacent right-sided palatine process and minimal right maxillary process resorption with minimal erosion. There was no evidence of regional lymphadenopathy. Consequently, a mass excision with turbinectomy via

Correspondence to:

Charoonratana V.
Department of Radiology, Faculty of Medicine, Prince of Songkla University, Hat Yai, Songkhla 90110, Thailand.
Phone: +66-74-451501
Email: vorawan62@outlook.com

How to cite this article:

Wiwattanaputit T, Charoonratana V, Chinpairoj S, Prapaisit U, Kanjanapradit K. Nasoalveolar Rhabdomyosarcoma Presenting as Traumatic Nasal Injury: A Rare Case Report Mimicking Organized Hematoma. *J Med Assoc Thai* 2023;106:743-6.
DOI: 10.35755/jmedassocthai.2023.07.13866

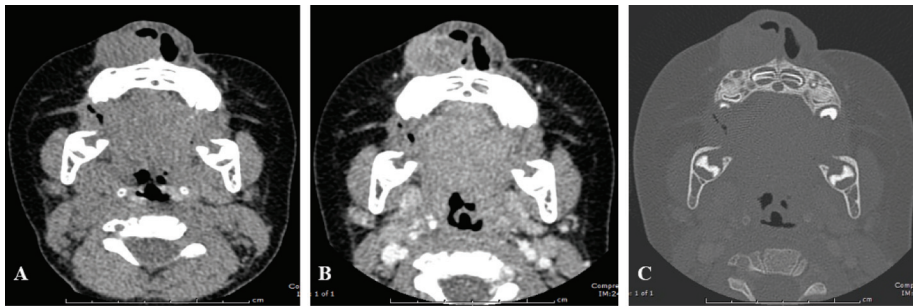


Figure 1. Axial CT images. (A) Non-contrast study demonstrated an isoattenuation mass at the right nasoalveolar region. (B) Enhanced-contrast study showed heterogeneous contrast enhancement prominent at the periphery. (C) Bone window showed a smooth scalloping of the adjacent bone.

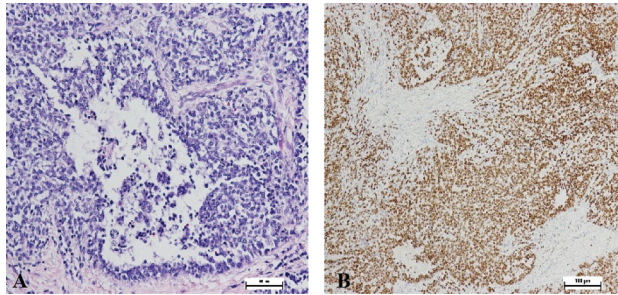


Figure 2. (A) Microscopic examination, H-E staining (x100) showed noncohesive cell aggregates arranged in an alveolar pattern with predominantly slit-like spaces surrounded by irregular, round to oval and spindle-shaped cells, separated by a fibrovascular septum. (B) Immunostaining demonstrated tumor cells positive for MyoD1.

lateral rhinotomy was performed. Intra-operatively, a large, well-defined, firm-consistency, lobulated mass occupying the right cheek and attached to the inferior turbinate was visualized. On immunohistochemical studies, the tumor cells resulted positive for desmin, MyoD1, and CD56. Based on the histopathology and immunohistostaining findings, alveolar RMS was diagnosed (Figure 2).

Management requires a multidisciplinary approach. Treatment is based on risk stratification, which includes histologic classification, presurgical staging, and postsurgical clinical grouping. Effective local treatment is also essential, and radical surgical excision is the treatment of choice, followed by the administration of chemotherapy, with or without radiotherapy. Specifically, in RMS of the nasoalveolar region, surgical treatment is already limited by functional and cosmetic considerations due to tumor location. In the present study, presurgical stage 1 and postsurgical clinical group 2 were noted. Postsurgery, the patient was referred to a pediatric oncologist and underwent chemotherapy with VAC (Vincristine, Dactinomycin, Cyclophosphamide). This was combined with 23 fractions (41.4 Gray) of external beam radiotherapy. The tumor was monitored by

magnetic resonance imaging (MRI) and CT revealed no recurrence and no metastasis.

Discussion

RMS is a highly aggressive, malignant neoplasm originating from the mesoderm, which has a profound tendency to differentiate into skeletal muscles. It accounts for 3% to 4% of all pediatric malignancies⁽²⁾. Although RMS can arise anywhere in the body, there are distinct age and type involvement patterns. Children and young adolescents have more head and neck involvement in 35% to 40% of cases, and these primarily confined to the orbit and parameningeal areas such as paranasal sinus and nasopharynx, which is usually of the embryonal type^(2,7-9). Extremity RMS is more common in adolescents, and it is usually of the alveolar type. The nasoalveolar site is the minority of all RMS despite the report that it is a second most common site in non-parameningeal RMS⁽⁸⁾. Prognosis depends on numerous factors such as age, site of involvement, tumor size, clinical staging, margin status, and the histopathological subtype. The embryonal subtype is more common and is associated with an intermediate prognosis, while the prognosis is poor for the alveolar type⁽⁷⁻⁹⁾. RMS is associated

with high rates of recurrence and common metastatic sites include the lung, bone marrow, and lymph nodes. Genetic abnormalities, familial predisposition, or trauma may induce its occurrence⁽⁹⁾. The history of trauma in the right nasal region might have acted as an inducing factor for the development of RMS.

The differential diagnosis of nasoalveolar region mass is based on the tumor location, characteristics, and clinical context. The organ of origin and the odontogenic lesions should be carefully evaluated. Any lesion appearing as a well-defined mass occurring beneath the alar base should raise the possibility of NC^(1,5). However, if there is an enhancing portion, the tumor should be included in the differential diagnosis, especially RMS in cases involving head and neck in a child. The radiological features of RMS are non-specific, and nasoalveolar involvement in RMS can mimic benign lesions. Although bone invasion or osseous destruction is common in RMS of the head and neck, nasoalveolar RMS may not show any bone destruction, which could be due to the lesion growing outside. It can appear as a homogeneous or heterogeneous enhancement⁽¹⁰⁻¹⁴⁾. Only a few cases of nasoalveolar RMS with CT images have been reported in children. The imaging findings of the two previously reported cases involved children that were older than the present patient. Ansari et al.⁽¹¹⁾ reported a homogeneous mass in the left nasoalveolar region with no osseous involvement. Another study⁽¹²⁾ reported a homogeneous expansive mass in the anterior region of the left maxilla. Their findings were different from that of the present case, which found heterogeneous enhancement with an internal septate-like appearance, isoattenuation to the muscle, and bone scalloping. The present case exhibited the clinical features and CT findings of nasoalveolar RMS in children that resembled an organized hematoma and complicated NC. A painless mass, progressive enlargement, and alveolar type were found in both earlier studies. According to a previous report on sinonasal organized hematoma, CT appearances are nonspecific. High attenuation on precontrast images, heterogeneous enhancement, and occasional bone erosion can be found^(3,4). The clinical history can serve as a clue to the diagnosis. However, most hematomas resolve spontaneously over time. A complicated NC may become swollen and tender. Lesion is usually unilateral and may be similar to tumor. It appears as well-circumscribed round cystic lesions with minimal rim enhancement. The internal content, sedimentation level, or superimposed infection can show heterogeneous enhancement with surrounding

inflammatory changes. It can have an expansile nature, and adjacent bone remodeling may occur after a long time owing to pressure from the mass^(2,5,6). Moreover, the expansion pattern is never invasive, as seen in malignancy. Frank bony destruction, rather than smooth erosion, associated with adjacent tissue invasion is a hallmark of carcinoma⁽¹⁵⁾.

The diagnosis typically requires tissue histological studies, and it cannot be made solely based on imaging findings. Varied clinical manifestations often misguide the clinician. The authors believe that radiology is useful in the evaluation of such masses as well as to look for the extent of invasion that may remain hidden to the otolaryngologist.

Multidrug, multicycle chemotherapy combined with radiotherapy, and wide surgical resection when feasible improves survival rates in children⁽¹⁶⁾. Studies show that patients treated by surgery alone have a favorable prognosis. This may be recommended as the initial treatment in young patients when the tumor is resectable⁽¹⁷⁾. In the present case, because the tumor was primary with no osseous involvement and postsurgical microscopic residual tumor, the treatment was based on chemotherapy with VAC combined with local radiotherapy.

Conclusion

Nasoalveolar rhabdomyosarcoma should be considered as a potential diagnosis in cases involving a mass with an enhancing portion and growing in size. A tumor may be mistaken for an organized hematoma and vice versa. Varied clinical manifestations often misguide the clinician, and the diagnosis typically requires tissue histological studies.

What is already known on this topic?

RMS is a common solid tumor in the pediatric population that involves the head and neck, especially the nasopharynx, paranasal sinuses, middle ear, mastoid bones, and facial soft tissues.

What this study adds?

The authors reported an unusual case of nasoalveolar RMS that presented at a young age, in an uncommon region, with a traumatic presentation, and imaging findings mimicking organized hematoma and complicated NC.

Acknowledgement

The authors would like to thank Edmond Subashi of the International Affairs, Faculty of Medicine, Prince of Songkla University, Thailand, for editing

the manuscript.

Ethics approval

The present case was approved by the Commission on Research Ethics, Faculty of Medicine, Prince of Songkla University, number REC.65-090-7-4

Informed consent

Written informed parental consent was obtained to publish this case report and the accompanying images.

Authors' contributions

Concepts: TW, VC, SC. Design: TW, VC. Definition of intellectual content: TW, VC, SC, UP, KK. Literature research: TW, VC. Clinical studies: TW, VC, SC, UP. Data acquisition: TW, VC, SC, UP, KK. Data analysis: TW, VC, KK. Manuscript preparation: TW, VC. Manuscript editing: TW, VC. Manuscript review: TW, VC. Guarantor: TW, VC, SC, UP, KK.

Conflicts of interest

The authors declare no conflict of interest.

References

1. Som PM, Norton KI. Lesions that manifest as medial cheek and nasolabial fold masses. *Radiology* 1991;178:831-5.
2. Rodriguez DP, Orscheln ES, Koch BL. Masses of the nose, nasal cavity, and nasopharynx in children. *Radiographics* 2017;37:1704-30.
3. Kim EY, Kim HJ, Chung SK, Dhong HJ, Kim HY, Yim YJ, et al. Sinonasal organized hematoma: CT and MR imaging findings. *AJNR Am J Neuroradiol* 2008;29:1204-8.
4. Lee HK, Smoker WR, Lee BJ, Kim SJ, Cho KJ. Organized hematoma of the maxillary sinus: CT findings. *AJR Am J Roentgenol* 2007;188:W370-3.
5. Iida S, Aikawa T, Kishino M, Sakai T, Nakano Y, Okura M, et al. Spheric mass beneath the alar base: MR images of nasolabial cyst and schwannoma. *AJNR Am J Neuroradiol* 2006;27:1826-9.
6. Yerli H, Cabbarpur C, Aydin E. CT findings of a nasoalveolar cyst. *Br J Radiol* 2009;82:e76-8.
7. Wu JM, Montgomery E. Classification and pathology. *Surg Clin North Am* 2008;88:483-520.
8. Glosli H, Bisogno G, Kelsey A, Chisholm JC, Gaze M, Kolb F, et al. Non-parameningeal head and neck rhabdomyosarcoma in children, adolescents, and young adults: Experience of the European paediatric Soft tissue sarcoma Study Group (EpSSG) - RMS2005 study. *Eur J Cancer* 2021;151:84-93.
9. Lahat G, Lazar A, Lev D. Sarcoma epidemiology and etiology: potential environmental and genetic factors. *Surg Clin North Am* 2008;88:451-81.
10. Nangalia R, Shah N, Sheikh MA, Pal M. Rhabdomyosarcoma involving maxilla mimicking gingival enlargement: A diagnostic challenge. *BMJ Case Rep* 2019;12:e230692.
11. Ansari A, Pastapur R, Mathew S. Nasolabial rhabdomyosarcoma: A rare case. *J Evol Med Dent Sci* 2014;3:4150-4.
12. Libório TN, Capuano AC, Mantesso A, Gatti A, Nunes FD, Pinto-Junior DS. Asymptomatic expansile lesion in the nasolabial region of a 10-year-old child. *Oral Surg Oral Med Oral Pathol Oral Radiol Endod* 2009;107:313-7.
13. Freling NJ, Merks JH, Saeed P, Balm AJ, Bras J, Pieters BR, et al. Imaging findings in craniofacial childhood rhabdomyosarcoma. *Pediatr Radiol* 2010;40:1723-38.
14. Zeng J, Liu L, Li J, Huang Q, Pi L, Jin K. MRI features of different types of sinonasal rhabdomyosarcomas: a series of eleven cases. *Dentomaxillofac Radiol* 2021;50:20210030.
15. Mistry P, Mittal A, Nagpal T. Spindle cell carcinoma of nasal cavity- a case report. *J Clin Diagn Res* 2016;10:MD01-2.
16. Pontes FS, de Oliveira JI, de Souza LL, de Almeida OP, Fregnani ER, Vilela RS, et al. Clinicopathological analysis of head and neck rhabdomyosarcoma: A series of 10 cases and literature review. *Med Oral Patol Oral Cir Bucal* 2018;23:e188-97.
17. Kumar P, Surya V, Urs AB, Augustine J, Mohanty S, Gupta S. Sarcomas of the oral and maxillofacial region: Analysis of 26 cases with emphasis on diagnostic challenges. *Pathol Oncol Res* 2019;25:593-601.