

Case Report

Rhino-Orbital Fungal Infection: Two Cases Report[†]

Yanin Suwan MD*,
Achara Punyawattanaporn MD*, Passorn Preechawai MD*

[†]This study was presented as poster in part of the World Ophthalmology Congress (WOC) Annual Meeting 2008, 28 June - 2 July, 2008; Hong Kong, China

* Department of Ophthalmology, Faculty of Medicine, Prince of Songkla University, Hat Yai, Songkhla, Thailand

Rhino-orbital fungal infections are serious and life threatening complications of immunocompromised host. The authors reported two cases of rapid progressive proptosis and eyelid necrosis of immunocompromised patients who suffered from highly malignant T-celled lymphoblastic leukemia/lymphoma and congenital heart disease with multiple anomalies. Although early diagnosis was made and prompt treatments including medical and surgical interventions were performed, both patients died.

Keywords: Rhino-orbital fungal infection, Aspergillosis, Mucormycosis, Orbital infection

J Med Assoc Thai 2012; 95 (5): 739-42

Full text. e-Journal: <http://www.jmat.mat.or.th>

Fungal infection of the orbit represents a small minority of orbital infection. However, rhino-orbital fungal infection is an often-devastating fungal disease. This opportunistic infection is most frequently seen in immunocompromised hosts such as uncontrolled diabetics, neutropenia, intravenous drug use, bone marrow transplantation, the use of corticosteroid and chemotherapy⁽¹⁾. Fungal infections of the orbit rarely occur spontaneously. The most common route is via extension from paranasal sinuses, because of intimate anatomical relationship between orbit and sinuses⁽¹⁾.

Case Report

Case 1

A 16-year-old man diagnosed with T-cell lymphoma stage III in May 2006. After good initial response to chemotherapy, he relapsed a year later. He developed neutropenia and fever. The patient was treated with the imipenem and vancomycin for *Pseudomonas aeruginosa* sepsis. In October 2007, the patient presented with left proptosis and eyelid necrosis for 4 days (Fig. 1).

Otolaryngologic and ophthalmologic consultations were held, and the amphotericin B was added. Initial physical examination revealed proptosis and eyelid necrosis on the left eye. The Computed Tomography (CT) scan of orbit demonstrated preseptal cellulitis of left orbit with evidences of left frontal, ethmoid, and maxillary sinusitis (Fig. 2). The functional endoscopic sinus surgery with eyelid debridement was performed, and the tissue pathology of the sinus showed T-cell lymphoblastic leukemia/lymphoma with invasive aspergillosis (Fig. 3). One week later, the sepsis and disseminated intravascular coagulopathy (DIC) were developed. Clinical conditions were deteriorated and the patient finally died.

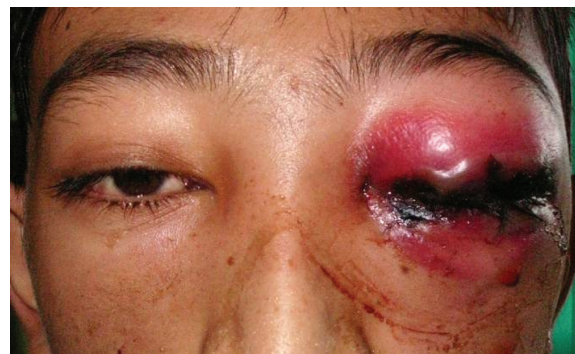

Fig. 1 Clinical photograph showed axial proptosis with eyelid necrosis

Correspondence to:

Suwan Y, Department of Ophthalmology, Faculty of Medicine, Ramathibodi Hospital, Mahidol University, Bangkok 10400, Thailand.

Phone: 0-2201-1526

E-mail: yaninyona@hotmail.com

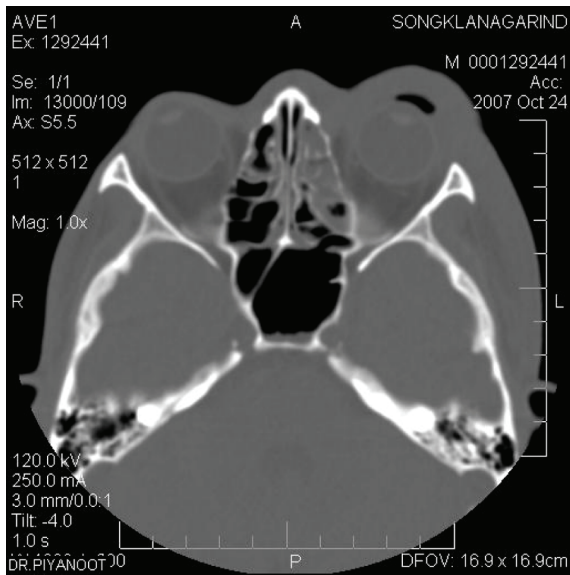

Fig. 2 Axial CT orbit and sinus showing ethmoidal sinusitis

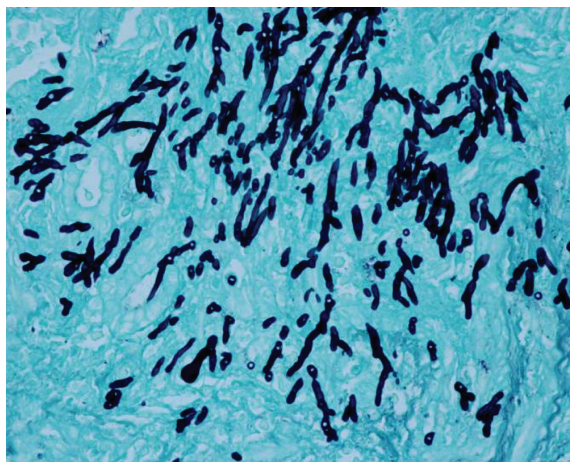


Fig. 3 Gomori methanamine silver (GMS) stain showed acute angle dichotomous branching, which is typical of *Aspergillus* spp.

Case 2

A 2-year-old boy with underlying left inguinal hernia, anorectal malformation, and Tetralogy of Fallot. He was hospitalized for total repair of Tetralogy of Fallot. Regarding intraoperative anoxic spells, the patient developed the multiorgan failure, myocardial ischemia, hypoxic brain, sepsis, and DIC postoperatively. The co-administration of meropenem with vancomycin was initiated. One week later, the

proptosis, loss of tarsal plate and conjunctiva at medial canthal area, and skin necrosis at left lateral nasal bridge were developed (Fig. 4).

The CT scan of the orbit revealed left ethmoid and maxillary sinusitis with thin subperiosteal collection (Fig. 5). Telescope was performed for tissue pathology and the report showed mucormycosis (Fig. 6). The patient's guardians denied wide excision and partial maxillectomy with orbital exenteration, however lateral rhinotomy was accomplished.

The patient had clinical deterioration of consciousness, and fever alternation with sub-temperature postoperatively, so the variconazole was

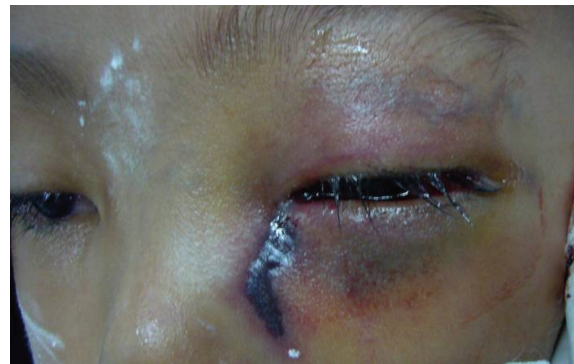

Fig. 4 Clinical photograph showed proptosis, eyelid swelling and skin necrosis

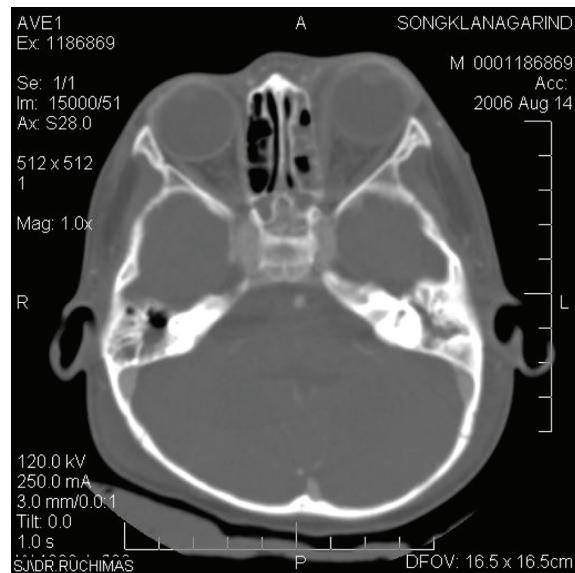

Fig. 5 Axial CT scan of orbit showed marked proptosis with ethmoidal sinusitis

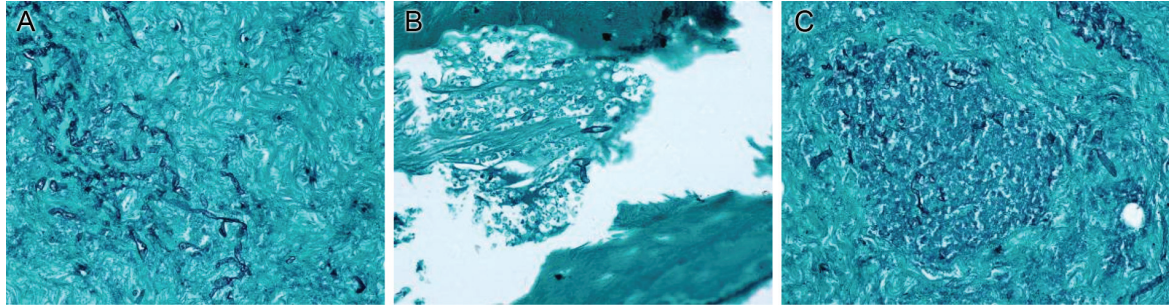


Fig. 6 A, GMS stain show characteristically branching at 90 degrees to the main stem
 B, Bony invasion
 C, Vascular invasion

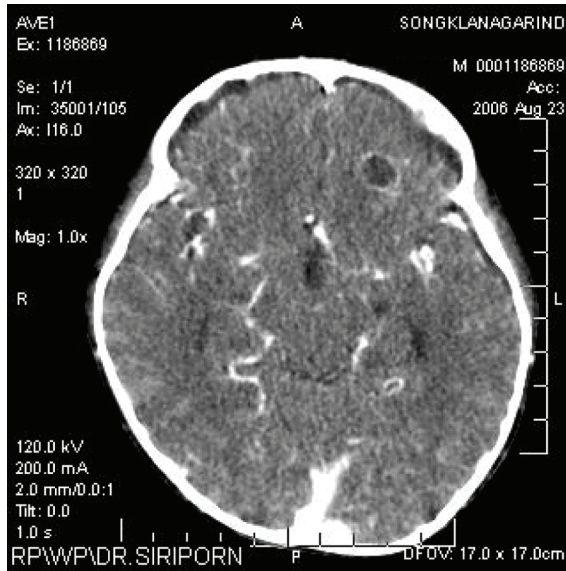


Fig. 7 Axial CT scan of brain showed multiple microabscesses within both cerebral hemisphere with bilateral frontal subdural collection

started for adjuvant therapy. The follow-up CT scan of brain revealed a few microabscesses of both cerebral hemispheres, and thin subdural collections along both frontal and parietal convexities (Fig. 7). In spite of aggressive medical treatments, the clinical condition never improved, and the patient then passed away.

Discussion

Rhino-orbital fungal infections caused by invasive *Aspergillus* and *Mucor* spp. are acutely fatal fungal infections in humans. Despite many advances

in diagnosis and treatment, the affected individuals still have high mortality⁽²⁾.

The family Mucoraceae includes the three genera *Mucor*, *Rhizopus*, and *Absidia*, which are considered to be the most common fungi responsible for mucormycosis⁽³⁾. These ubiquitous saprophytes in soil and hospital ventilation system can be cultured from the nose and nasopharynx. Sporangiospores are inhaled into the respiratory tract, but fail to germinate in healthy individuals. It is extremely difficult to culture. Biopsied tissue revealed broad, irregular, non-septate hyphae with right-angled branching, which best had seen with methenamine silver staining. Most abundant in necrotic areas surrounding obstructed blood vessels.

Human *Aspergillus* infection takes four forms, noninvasive colonization (mycetoma), Allergic fungal sinusitis, chronic invasive aspergillosis, and fulminant invasive aspergillosis. *Aspergillus* spp. typical appears as slender septate hyphae exhibit angular dichotomous branching⁽⁴⁾. Invasive aspergillosis, like mucormycosis, is characterized by rapid progressive fulminant gangrenous caused by fungal vascular invasion with coagulative necrosis of vessels resulting in mycotic thrombosis^(5,6). The necrotic black eschar typical of zygomycotic infection may be later sign of infection⁽¹⁾.

If suspicion for fungal infection is high, rapid biopsy and culture of suspicious lesions is essential. Care should be taken to biopsy a sufficient amount of tissue to avoid high rate of negative or inconclusive results. Urgent drainage and aeration of involved sinus is the first step in the treatment of rhino-orbital fungal infection, treatment should include reversal of the predisposing factor⁽¹⁾.

Advances in medical therapy for the treatment of rhino-orbital fungal infection have

allowed a less drastic surgical approach. Intravenous amphotericin B has been the mainstay of medical treatment for sino-orbital fungal infection. Recognized side effects of amphotericin B administration are fever, chills, headache, malaise, nausea, vomiting, phlebitis, and thrombophlebitis. Hypokalemia, azotemia, hyposthenuria, renal tubular acidosis, and anemia are also frequently encountered side effects⁽⁷⁾.

Effective surgical treatment requires adequate exposure to remove all devascularized tissue, and permits the penetration of the antifungal agent by the bloodstream. Orbital exenteration does not guarantee a cure. Although removing the orbital contents when they have been completely destroyed by the invasive process should be considered, lesser degrees of intraconal damage can be treated without exenteration.

Conclusion

Invasive fungal infections of the orbit remain a rare but devastating occurrence. Successful therapy depends on early recognition, complete removal of necrotic tissue, effective antifungal chemotherapy, and most importantly, improvement in the immunologic status of the host. Despite aggressive multimodal therapy, the prognosis remains poor in the setting of irreversible immunosuppression.

Acknowledgment

The authors wish to thank Dr. Passorn Preechawai for his great advice and support.

Potential conflict of interest

None.

References

1. Kirsztrot J, Rubin PA. Invasive fungal infections of the orbit. *Int Ophthalmol Clin* 2007; 47: 117-32.
2. Fairley C, Sullivan TJ, Bartley P, Allworth T, Lewandowski R. Survival after rhino-orbital-cerebral mucormycosis in an immunocompetent patient. *Ophthalmology* 2000; 107: 555-8.
3. Pelton RW, Peterson EA, Patel BC, Davis K. Successful treatment of rhino-orbital mucormycosis without exenteration: the use of multiple treatment modalities. *Ophthal Plast Reconstr Surg* 2001; 17: 62-6.
4. Hope WW, Walsh TJ, Denning DW. Laboratory diagnosis of invasive aspergillosis. *Lancet Infect Dis* 2005; 5: 609-22.
5. Adler SC, Isaacson G, Sasaki CT. Invasive aspergillosis of the paranasal sinuses and orbit: can you save the eye? *Am J Otolaryngol* 1997; 18: 230-4.
6. Robinson MR, Fine HF, Ross ML, Mont EK, Bryant-Greenwood PK, Hertle RW, et al. Sino-orbital-cerebral aspergillosis in immunocompromised pediatric patients. *Pediatr Infect Dis J* 2000; 19: 1197-203.
7. Talmi YP, Goldschmied-Reouven A, Bakon M, Barshack I, Wolf M, Horowitz Z, et al. Rhino-orbital and rhino-orbito-cerebral mucormycosis. *Otolaryngol Head Neck Surg* 2002; 127: 22-31.

การติดเชื้อราของจมูกและเบ้าตา

ญาณิน สุวรรณ, อัจฉรา ปัญญาวัฒนาภรณ์, ภััสสร ปรีชาไว

การติดเชื้อราของจมูกและเบ้าตาในผู้ป่วยที่มีภูมิคุ้มกันต่ำเป็นภาวะรุนแรงและถึงแก่ชีวิต ผู้นิพนธ์รายงานผู้ป่วย 2 ราย ที่มีภาวะตาไปนุกล้ำรวดเร็วและมีการตายของเปลือกตา ทั้งสองคนเป็นผู้ป่วยที่มีภูมิคุ้มกันต่ำจากมะเร็งเม็ดเลือดขาวชนิดทีเซลล์/มะเร็งต่อมน้ำเหลือง และโรคหัวใจแต่กำเนิดร่วมกับความผิดปกติหลายอวัยวะ แม้ว่าวินิจฉัยแต่แรกเริ่มและรักษาโดยพลัน รวมถึงการปฏิบัติทางยาและผ่าตัด แต่ผู้ป่วยทั้งสองรายเสียชีวิต
