

Case Report

Spontaneous Perforation of Pyometra in an Elderly Woman: A Case Report

Pattama Chaopotong MD*,
Mongkol Benjapibal MD*, Manopchai Thamkhantho MD*

* Department of Obstetrics and Gynecology, Faculty of Medicine Siriraj Hospital, Mahidol University, Bangkok, Thailand

Pyometra is an uncommon gynecologic condition that usually develops in elderly women. Most of the cases result from cervical occlusion by malignant or benign tumors, surgery, radiotherapy, or atrophic cervicitis. A spontaneous perforation of the uterus with generalized peritonitis is an extremely rare complication of pyometra and carries significant morbidity and mortality. Establishing a correct diagnosis preoperatively is not easy due to the non-specificity of the symptoms. The authors present a case report of peritonitis caused by spontaneously perforated pyometra that was diagnosed intraoperatively. The cervical canal was not occluded and the cause of perforation remains obscure.

Keywords: Elderly women, Mortality, Peritonitis, Pyometra, Spontaneous perforation

J Med Assoc Thai 2012; 95 (5): 723-6

Full text. e-Journal: <http://www.jmat.mat.or.th>

Pyometra, a collection of pus in the uterine cavity, is an uncommon condition that occurs mainly in postmenopausal women⁽¹⁾. A spontaneous perforation of the uterus and subsequent peritonitis is an extremely rare complication of pyometra^(2,3). Once ruptured, the symptoms become severe and acute abdomen often develops. Establishing a preoperative diagnosis of ruptured pyometra is usually difficult due to the nonspecific presenting symptoms and signs. It is therefore important to make a differential diagnosis from other causes of acute surgical abdomens. About 30 cases have been reported in English medical literature so far. The authors report herein a case of generalized peritonitis caused by the spontaneous perforation of pyometra with no associated malignancy and the cause of the perforation remains obscure.

Case Report

An 88-year-old woman with a 1-day history of abdominal pain and difficulty in urination was admitted to Siriraj Hospital in August 2009. The patient did not complain of fever or any change in bowel habits. Her gynecologic history was unremarkable

having undergone an uneventful menopause. She had no history of postmenopausal bleeding or increased vaginal discharge and had never had sexually transmitted diseases. Her obstetric history included three normal vaginal deliveries. She had a history of well-controlled diabetes mellitus and hypertensive disorder since the age of 52. Physical examination on admission revealed a poorly active woman weighing 68 kg. Her blood pressure and heart rate were 117/80 mmHg and 70 beats/min, respectively. Her body temperature was 37.2°C. Her lower abdomen was distended with tenderness and voluntary guarding in the middle. Cystic consistency was felt in her lower abdomen and urinary retention was suspected. Urinary catheterization was done and 1,000 ml of urine was drained. The abdominal pain was slightly relieved and the suprapubic distention disappeared. On the pelvic examination, a small amount of yellow discharge in the vaginal pool was detected. The cervix was small without any abnormal lesion and small round cervical os was seen. A round cystic mass, measuring 8 cm in diameter was palpable in her middle lower abdomen. Transvaginal ultrasonography demonstrated an 8.1 x 4.4-cm inhomogeneous cystic mass with irregular thickening border in the lower abdomen (Fig. 1). There was no ascitic fluid seen in the abdominal cavity. Although the uterus was not clearly visualized, ovarian tumor was highly suspected at that time. Her laboratory studies demonstrated a white cell count of

Correspondence to:

Chaopotong P, Department of Obstetrics and Gynecology, Faculty of Medicine Siriraj Hospital, Mahidol University, Bangkok 10700, Thailand.
Phone: 0-2419-7000 ext. 4777, 4888, Fax: 0-2418-2662
E-mail: sipattama_c@mahidol.ac.th

19,200 /mm³ with 85% neutrophilia and hemoglobin of 9 g/dL. Urine analysis demonstrated 3-5 white blood cells/LP and 3-5 red blood cell/LP, but otherwise appeared normal, including serum CA-125 (less than 35 U/ml).

Four hours after admission, she developed acute abdomen with vomiting and fever episode. On the physical examination, her abdomen was markedly tender, distended, and showed board-like rigidity. Bowel sounds were hypoactive. Her blood pressure was 160/80 mmHg, pulse rate was 116 beats/min, and the temperature rose to 38.5°C. She was diagnosed as having diffuse peritonitis due to a complication of the pelvic cystic mass. Emergent laparotomy was performed and 200 ml of purulent material was found in the peritoneal cavity. The uterus was slightly enlarged and thin-walled with a necrotic area of 15 mm in diameter on the uterine fundus, which was found to be perforated (Fig. 2). The fallopian tubes and the ovaries were normal. There were no abnormal findings in the alimentary tract, liver, or gallbladder. A total hysterectomy with bilateral salpingo-oophorectomy was performed and a diagnosis of generalized peritonitis due to the spontaneous perforation of pyometra was made. A histopathologic examination of the resected specimen revealed pyometra with acute transmural inflammation and the cervical canal was patent. There was no evidence of malignancy. A culture of the pus in the peritoneal cavity was negative. Postoperatively, she was observed in the intensive care unit. Unfortunately, she developed severe sepsis on the fourth postoperative day and her condition worsened gradually. Although intensive antibiotic therapy was performed, she developed multiple organ failure and died on the seventh day following surgery. No autopsy was performed in this patient.

Discussion

Pyometra, or the accumulation of pus in the uterus, is a rare event in the general population, but more common in elderly women. It has been reported to account for 0.2-0.5% in gynecologic patients and may rise to 13.6% among elderly patients^(2,3). It is thought to develop as a result of blockage of the natural drainage of the uterus, commonly caused by malignant or benign tumors, surgery, radiotherapy, atrophic cervicitis, puerperal infection, and congenital anomalies⁽⁴⁾. Pyometra develops gradually and progresses to enlarge the uterine size. It is a serious medical condition because its association with danger of spontaneous perforation of the uterus that carries

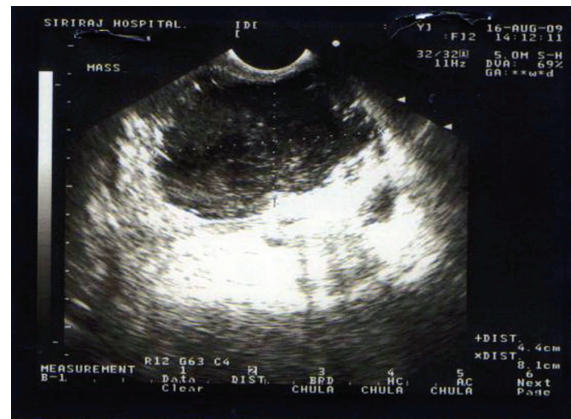

Fig. 1 Transvaginal ultrasonography demonstrated an inhomogeneous cystic mass with irregular thickening border. Scale on the left side represent in centimeter

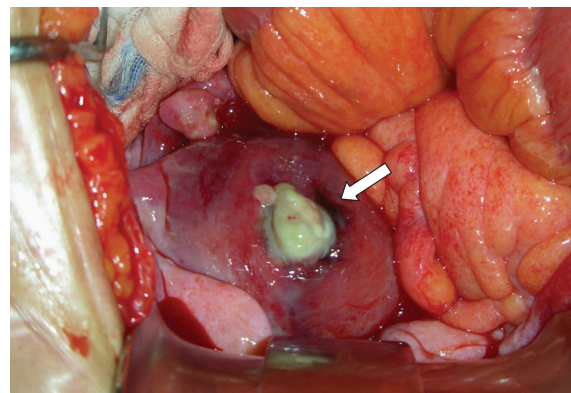


Fig. 2 Intraoperative photograph showed the perforated uterine fundus. White arrow showed the perforated point

significant morbidity and mortality⁽⁵⁻⁷⁾. More than 50% of patients with pyometra are asymptomatic⁽⁸⁾. The classic symptoms consist of postmenopausal bleeding, vaginal discharge, lower abdominal pain, and uterine enlargement⁽⁹⁾. Ou YC et al reported that fever was found in 45% of 20 patients in their study⁽¹⁰⁾. Only bleeding and discharge were more commonly reported in these cases⁽¹⁾ but this patient had no vaginal bleeding or discharge. A spontaneous perforation of pyometra and subsequent diffuse peritonitis is extremely rare, with the incidence of 0.01-0.05%^(2,3). Whatever the pathologic findings, it appears that cervical occlusion is so severe that the intrauterine pressure increases due to the accumulation of pus and results in over-distention of

the myometrium which eventually ruptures. Pyometra is associated with cervical occlusion in most cases. This case differs from those previously reported in that the cervical canal was not occluded. However, the perforation may have happened after increased external pressure by pelvic examination. The incidence of pyometra becomes much higher with age and decline in activity^(2,11,12). Other risk factors include incontinence^(2,12), diabetes^(7,13-16), and long-term IUD^(17,18). As the older population has been rising, peritonitis due to perforated pyometra may be encountered more frequently. The diagnosis of spontaneous perforation of pyometra is rarely made preoperatively because the common presenting symptoms such as abdominal pain, vomiting and fever are nonspecific and of short duration. High index of suspicion is required to make appropriate diagnosis. Preoperative diagnosis of perforated pyometra is essential because these patients are elderly, in poor general condition, and require prompt intervention⁽¹⁹⁾. Regardless of the clinical presentation, a perforated pyometra requires an emergent surgical exploration and broad-spectrum antibiotic therapy. However, the best way for management of the patients with pyometra is early recognition and appropriate treatment before it becomes rupture.

In conclusion, pyometra is an uncommon serious gynecologic condition and with spontaneous uterine perforation as a rare complication, it carries significant morbidity and mortality and should therefore be considered when elderly women suffer from acute abdominal pain. Its management is often difficult, and hysterectomy may be the best choice of procedure in such patients.

Potential conflicts of interest

None.

References

- Chan LY, Lau TK, Wong SF, Yuen PM. Pyometra. What is its clinical significance? *J Reprod Med* 2001; 46: 952-6.
- Sawabe M, Takubo K, Esaki Y, Hatano N, Noro T, Nokubi M. Spontaneous uterine perforation as a serious complication of pyometra in elderly females. *Aust N Z J Obstet Gynaecol* 1995; 35: 87-91.
- Gita R, Jain K, Vaid NB. Spontaneous rupture of pyometra. *Int J Gynaecol Obstet* 1995; 48: 111-2.
- Inui A, Nitta A, Yamamoto A, Kang SM, Kanehara I, Tanaka H, et al. Generalized peritonitis with pneumoperitoneum caused by the spontaneous perforation of pyometra without malignancy: report of a case. *Surg Today* 1999; 29: 935-8.
- Chan LY, Yu VS, Ho LC, Lok YH, Hui SK. Spontaneous uterine perforation of pyometra. A report of three cases. *J Reprod Med* 2000; 45: 857-60.
- Nuamah NM, Hamaloglu E, Konan A. Spontaneous uterine perforation due to pyometra presenting as acute abdomen. *Int J Gynaecol Obstet* 2006; 92: 145-6.
- Yildizhan B, Uyar E, Sismanoglu A, Gulluoglu G, Kavak ZN. Spontaneous perforation of pyometra. *Infect Dis Obstet Gynecol* 2006; 2006: 26786.
- Hansen PT, Lindholt J. Spontaneously perforated pyometra. A differential diagnosis in acute abdomen. *Ann Chir Gynaecol* 1985; 74: 294-5.
- Imachi M, Tanaka S, Ishikawa S, Matsuo K. Spontaneous perforation of pyometra presenting as generalized peritonitis in a patient with cervical cancer. *Gynecol Oncol* 1993; 50: 384-8.
- Ou YC, Lan KC, Lin H, Tsai CC, ChangChien CC. Clinical characteristics of perforated pyometra and impending perforation: specific issues in gynecological emergency. *J Obstet Gynaecol Res* 2010; 36: 661-6.
- Hosking SW. Spontaneous perforation of a pyometra presenting as generalized peritonitis. *Postgrad Med J* 1985; 61: 645-6.
- Iwase F, Shimizu H, Koike H, Yasutomi T. Spontaneously perforated pyometra presenting as diffuse peritonitis in older females at nursing homes. *J Am Geriatr Soc* 2001; 49: 95-6.
- Sussman AM, Boyd CR, Christy RS, Rudolph R. Pneumoperitoneum and an acute abdominal condition caused by spontaneous perforation of a pyometra in an elderly woman: a case report. *Surgery* 1989; 105: 230-1.
- Tsai MS, Wu MH. Images in clinical medicine. Pneumoperitoneum due to spontaneously perforated pyometra. *N Engl J Med* 2006; 354: e23.
- Geranpayeh L, Fadaei-Araghi M, Shakiba B. Spontaneous uterine perforation due to pyometra presenting as acute abdomen. *Infect Dis Obstet Gynecol* 2006; 2006: 60276.
- Tan LK, Busmanis I. Spontaneous uterine perforation from uterine infarction: a rare case of acute abdomen. *Aust N Z J Obstet Gynaecol* 2000; 40: 210-2.

17. Guler OT, Basaran A, Guven S, Ayhan A. Spontaneous uterine perforation in an immuno-compromised menopausal woman with pelvic actinomycosis. Int J Gynaecol Obstet 2007; 99: 134-5.
18. Li CH, Chang WC. Spontaneous perforated pyometra with an intrauterine device in menopause: a case report. Jpn J Infect Dis 2008; 61:477-8.
19. Nakao A, Mimura H, Fujisawa K, Ezawa K, Okamoto T, Iwagaki H, et al. Generalized peritonitis due to spontaneously perforated pyometra presenting as pneumoperitoneum: report of a case. Surg Today 2000; 30: 454-7.

การแตกทะลุของหนองในโพรงมดลูกซึ่งเกิดขึ้นเองในสตรีสูงอายุ: รายงานผู้ป่วย

ปัทมา เชาวโพธิ์ทอง, มงคล เบญจาทิบาล, มานพชัย ธรรมคันโธ

หนองในโพรงมดลูกเป็นโรคทางนรีเวชที่พบได้ไม่บ่อย โดยส่วนมากจะพบในสตรีสูงอายุ ซึ่งมีสาเหตุมาจากการที่มีการอุดตันบริเวณปากมดลูกเนื่องจากสาเหตุต่าง ๆ เช่น มะเร็งหรือเนื้องอกต่าง ๆ ของปากมดลูก การผ่าตัด การฉายรังสี หรือ การอักเสบของปากมดลูกเนื่องจากภาวะขาดฮอร์โมน สำหรับภาวะที่มีการแตกทะลุของหนองในโพรงมดลูกเข้าสู่ช่องท้อง และทำให้เกิดภาวะเยื่อช่องท้องอักเสบ โดยทั่วไปนั้นเป็นภาวะแทรกซ้อนที่พบน้อยมาก แต่เป็นภาวะแทรกซ้อนที่มีอันตรายสูงและรุนแรงถึงเสียชีวิตได้ ซึ่งการวินิจฉัยภาวะแทรกซ้อนดังกล่าวนี้ ก่อนการรักษาโดยการผ่าตัดไม่ใช่เรื่องง่าย เนื่องจากอาการไม่เฉพาะเจาะจงกับโรค ผู้นิพนธ์ได้นำเสนอประวัติผู้ป่วยที่มีอาการของเยื่อช่องท้องอักเสบโดยทั่วไป ซึ่งมีสาเหตุมาจากการแตกทะลุของหนองในโพรงมดลูกเข้าสู่ช่องท้อง โดยสามารถวินิจฉัยได้ขณะผ่าตัด เมื่อตรวจบริเวณคอมดลูกไม่พบว่ามีการอุดตัน ดังนั้นจึงไม่สามารถระบุสาเหตุของการแตกทะลุของหนองในโพรงมดลูกในผู้ป่วยรายนี้ได้