

Case Report

Induced Hypothermia in a Penetrating Trauma Patient with Cardiac Arrest from Exsanguination: The First Case Report

Supparerk Prichayudh MD*, Rattaplee Pak-art MD*,
Manasnun Kongwibulwut MD**, Komol Chaivanijchaya MD*, Suvit Sriussadaporn MD*,
Sukanya Sriussadaporn MD*, Kritaya Kritayakirana MD*, Pasurachate Samorn MD*

* Department of Surgery, Faculty of Medicine, Chulalongkorn University, Bangkok, Thailand

** Department of Anesthesiology, Faculty of Medicine, Chulalongkorn University, Bangkok, Thailand

The authors report the use of induced hypothermia in a stab wound patient with left common femoral artery injury who had cardiac arrest from exsanguination immediately after arriving at a private hospital. The patient was transferred to the authors' institution (a university hospital) after successful cardiopulmonary resuscitation, for vascular repair. The patient remained comatose five hours after the vascular repair. The induced hypothermia (target body temperature of 33°C) was initiated 10 hours post arrest after the bleeding control and physiologic derangement restoration had been achieved. The patient recovered uneventfully with good neurological outcome.

Keywords: Induced hypothermia, Cardiac arrest, Penetrating trauma

J Med Assoc Thai 2015; 98 (7): 709-12

Full text. e-Journal: <http://www.jmatonline.com>

Induced hypothermia (IH) in patients with cardiac arrest has been widely accepted as an adjunct treatment to help improve the neurological outcomes⁽¹⁻⁴⁾. The current recommendations are to consider IH in comatose adult patients with return of spontaneous circulation (ROSC) after out-of-hospital ventricular fibrillation cardiac arrest (Class I), after in-hospital cardiac arrest of any initial rhythm, or after out-of-hospital cardiac arrest with an initial rhythm of pulseless electrical activity or asystole (Class IIb)⁽⁵⁾. In contrast, IH in trauma patients has not been generally used since there is a theoretical disadvantage that IH may worsen coagulation and acid-base status⁽²⁾. A recent case series of adult patients with cardiac arrest after blunt trauma undergoing IH demonstrated varied neurological outcomes⁽⁶⁾. Although there are some animal researches showing possibility of IH in penetrating trauma, there has been no report using IH in penetrating trauma patient with cardiac arrest^(7,8). The authors reported a case with cardiac arrest from exsanguination after penetrating trauma who underwent IH with a favorable neurological outcome.

Case Report

A 19-year-old male victim was stabbed once at the left upper thigh during a robbery at a gas station. He was brought to the nearby private hospital 20 minutes after the incident. Initially, he was unresponsive and had significant bleeding from the left thigh wound. The patient developed cardiac arrest shortly after arrival at the hospital. Endotracheal intubation and cardiopulmonary resuscitation (CPR) were performed concurrently with fluid resuscitation and application of a homemade tourniquet at the left groin. After 30 minutes of CPR, the patient had ROSC and was transferred to the authors' institution (King Chulalongkorn Memorial Hospital, a 1,400-bed University Hospital in Bangkok, Thailand).

At our emergency department (two hours post-injury), the patient remained unresponsive with a Glasgow Coma Scale (GCS) of 5t (E1M4Vt) and pupil size of 4 millimeters, reactive to light bilaterally. His blood pressure was 110/80 mmHg and pulse rate was 110/minute. The bleeding from the left thigh wound was well controlled with the tourniquet. However, the left lower extremity was pale, cold, and pulseless. The diagnosis of left femoral artery injury was made and the patient was brought to the operating room. Upon vascular exploration, a complete transection of the left common femoral artery was identified and an end-to-end anastomosis was performed with

Correspondence to:

Prichayudh S, Department of Surgery, Faculty of Medicine, Chulalongkorn University, Rama4 Road, Bangkok 10330, Thailand.
Phone: +66-2-2564117, Fax: +66-2-2564194
E-mail: Supparerk.P@Chula.ac.th

polypropylene 6-0. The operative time was one hour with an estimated blood loss of 1,200 ml. The patient received seven units of packed red blood cell, four units of fresh frozen plasma, and 10 units of platelet transfusion intraoperatively. Subsequently, the patient was brought to the intensive care unit (ICU) for continuing resuscitation to correct hypothermia (initial body temperature 33°C), acidosis (initial pH 7.01, base excess -18, serum lactate 10.9 mmol/L), and coagulopathy (initial international normalized ratio-INR 1.65).

Five hours post-operatively, all physiologic derangements were corrected and there was no sign of bleeding from the left thigh wound. Nevertheless, the patient remained unresponsive with the same neurological findings despite a normal result of computed tomography of the brain. Hence, we started IH at 10 hours post ROSC using surface cooling method comprised cooling blanket and cold ice packs applied to the patient's forehead and anterior chest, and internal cooling method comprising 1.5 liter of cold (4°C) normal saline infusion and cold saline nasogastric tube irrigation (Fig. 1). The body temperature was measured and monitored continuously using rectal temperature probe. The target body temperature of 33°C was achieved at four hours after starting IH. It was maintained by using only cooling blanket for the next 24 hours. Propofol infusion (100 mg/hour) and cisatracurium infusion (4 mg/hour) were used for sedation and prevention of shivering, respectively. The patient had urine output of 100 to 200 ml/hour and normal blood sugar level throughout the treatment. Despite the decrease in platelet count from 179,000/mm³ to 61,000/mm³, the INR had been less than 1.3 and there was no bleeding from the wound during IH. No other blood component transfusion was required. The patient was then rewarmed 24 hours after achieving target body temperature using forced-air warming blanket (Bair Hugger™) at the rate of approximately 0.5°C/hour, reaching body temperature of 37°C at six hours.

Post-operative course was uneventful. The patient became responsive and was extubated 16 hours after rewarming with a GCS of 15. Neurologically, the patient experienced temporary weakness of the left upper and lower extremities, which resolved spontaneously and completely by the postoperative day 5. The cognitive function returned to normal except for loss of memory at the time of injury to the postoperative day 4. The patient spent another week in the hospital for rehabilitation and wound care and

was subsequently discharged on the postoperative day 16. At one-month follow-up, the patient was able to resume his normal daily activity and continued to have normal neurological function (Fig. 2).

Discussion

Based on current evidence available, mild hypothermia (32-34°C) has become an effective

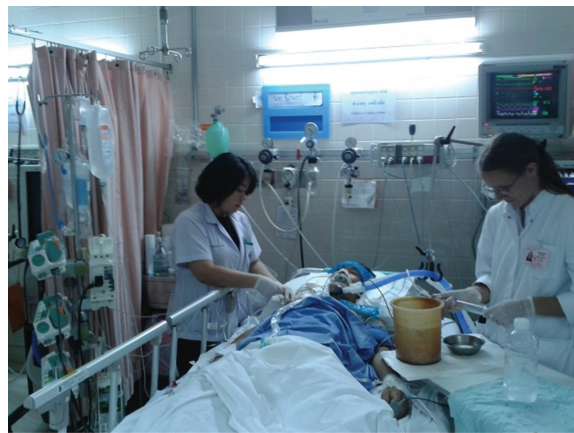


Fig. 1 Induction of induced hypothermia had been accomplished by surface cooling method (cooling blanket and cold ice packs); and internal cooling method (4°C normal saline infusion and nasogastric tube irrigation) until the target body temperature of 33°C was achieved 4 hours later in the present patient.

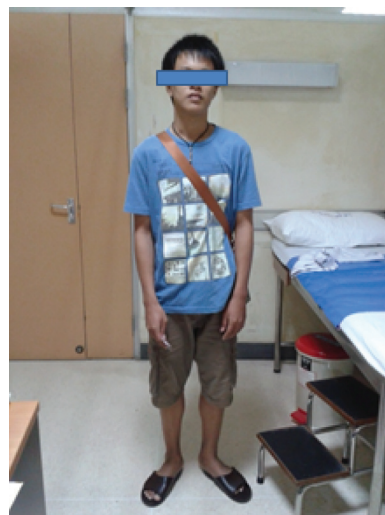

Fig. 2 Forty-nine days post injury, the present patient was able to resume his normal daily activity with good neurological functions.

neuroprotective procedure that should be offered to cardiac arrest patients who remain comatose after ROSC⁽¹⁻⁵⁾. Theoretically, trauma patients with cardiac arrest are not considered suitable candidates for IH due to the risk of bleeding and worsening acidosis^(2,9). This can be potentially harmful to bleeding trauma patient who have already developed coagulopathy from hypothermia and acidosis (the so-called “bloody vicious cycle”)⁽¹⁰⁾. However, animal studies have shown that IH could be done safely in injured animal models with little effect on coagulation and without increased risk of bleeding^(7,8).

The first clinical experience of IH in trauma patients was reported by Tuma et al in 2011, describing six blunt trauma patients with cardiac arrest who underwent IH⁽⁶⁾. Causes of cardiac arrest were mainly respiratory including tension pneumothorax and aspiration, except one patient who had cardiac arrest from cardiac cause. Cardiac arrest time ranged from five to 45 minutes and time to cooling after injury ranged from immediate to 29 hours. None of the patients experienced bleeding complication during IH. However, only two patients regained full consciousness (GCS of 15) and one patient who remained comatose eventually died from severe head injury. They concluded that IH may be helpful in selected trauma patients with cardiac arrest.

To our knowledge, the present report is the first to use IH in penetrating trauma patient with cardiac arrest from exsanguination. Unlike non-trauma cases with cardiac arrest that IH should be initiated as early as possible, we believe that in bleeding trauma patients with cardiac arrest, bleeding control and hemodynamic stabilization must be accomplished first. In the present case, the patient was acidotic, coagulopathic, and hypothermic after the ROSC requiring operative control of bleeding and a long period (7 hours) of resuscitation in the ICU prior to initiation of IH. Besides adequate sedation, muscle relaxation, blood sugar control, and fluid electrolyte optimization, monitoring of coagulation profiles and clinical signs of bleeding is mandatory during IH in trauma patients^(7,9). Fortunately, the present patient had no bleeding complication during IH and regained consciousness and neurologic function after rewarming. Nevertheless, the favorable neurological outcome in the present patient cannot be solely explained by the use of IH. Additionally, rapid CPR, prompt bleeding control, and optimal ICU care helped prevent secondary brain damage in this particular patient and should also be taken into consideration.

Conclusion

We believe that IH is a useful neuroprotective strategy in penetrating trauma patients with cardiac arrest from exsanguination, given that the bleeding and physiologic derangements have been controlled and corrected prior to the initiation. Further studies are required to determine the effectiveness and safety of IH in trauma patients with cardiac arrest, particularly those with the risk of bleeding.

What is already known on this topic?

IH in patients with cardiac arrest has been widely accepted as an adjunct treatment to help improve the neurological outcomes. However, IH in trauma patients has not been widely used since there is a theoretical disadvantage that IH may worsen coagulation and acid-base status. A recent case series of adult patients with cardiac arrest after blunt trauma undergoing IH demonstrated varied neurological outcomes. Nevertheless, the use of IH in cardiac arrest after penetrating trauma has not been reported. The authors reported a case with cardiac arrest from exsanguination after penetrating trauma who underwent IH with a favorable neurological outcome.

What this study adds?

The present study demonstrated that IH is a useful neuroprotective strategy in penetrating trauma patients with cardiac arrest from exsanguination, given that the bleeding and physiologic derangements have been controlled and corrected prior to the initiation.

Potential conflicts of interest

None.

References

1. Hypothermia after Cardiac Arrest Study Group. Mild therapeutic hypothermia to improve the neurologic outcome after cardiac arrest. *N Engl J Med* 2002; 346: 549-56.
2. Bernard SA, Gray TW, Buist MD, Jones BM, Silvester W, Gutteridge G, et al. Treatment of comatose survivors of out-of-hospital cardiac arrest with induced hypothermia. *N Engl J Med* 2002; 346: 557-63.
3. Holzer M, Bernard SA, Hachimi-Idrissi S, Roine RO, Sterz F, Mullner M. Hypothermia for neuroprotection after cardiac arrest: systematic review and individual patient data meta-analysis. *Crit Care Med* 2005; 33: 414-8.
4. Arrich J. Clinical application of mild therapeutic

- hypothermia after cardiac arrest. Crit Care Med 2007; 35: 1041-7.
5. Peberdy MA, Callaway CW, Neumar RW, Geocadin RG, Zimmerman JL, Donnino M, et al. Part 9: post-cardiac arrest care: 2010 American Heart Association Guidelines for Cardiopulmonary Resuscitation and Emergency Cardiovascular Care. Circulation 2010; 122 (18 Suppl 3): S768-86.
 6. Tuma MA, Stansbury LG, Stein DM, McQuillan KA, Scalea TM. Induced hypothermia after cardiac arrest in trauma patients: a case series. J Trauma 2011; 71: 1524-7.
 7. Finkelstein RA, Alam HB. Induced hypothermia for trauma: current research and practice. J Intensive Care Med 2010; 25: 205-26.
 8. Mohr J, Ruchholtz S, Hildebrand F, Flohe S, Frink M, Witte I, et al. Induced hypothermia does not impair coagulation system in a swine multiple trauma model. J Trauma Acute Care Surg 2013; 74: 1014-20.
 9. Soleimanpour H, Rahmani F, Golzari SE, Safari S. Main complications of mild induced hypothermia after cardiac arrest: a review article. J Cardiovasc Thorac Res 2014; 6: 1-8.
 10. Rotondo MF, Schwab CW, McGonigal MD, Phillips GR III, Fruchterman TM, Kauder DR, et al. 'Damage control': an approach for improved survival in exsanguinating penetrating abdominal injury. J Trauma 1993; 35: 375-82.

การรักษาด้วยวิธีลดอุณหภูมิภายในผู้ป่วยอุบัติเหตุที่ได้รับบาดเจ็บจากการโดนมีดแทงและมีภาวะหัวใจหยุดเต้นจากการเสียเลือด: รายงานผู้ป่วยรายแรก

ศุภฤกษ์ ปรีชายุทธ, รัฐพลี ภาคอรธร, มนต์นันท์ คงวิบูลยวุฒิ, โกมล ชัยวณิชยา, สุวิทย์ ศรีอัยฎาพร, สุภัญญา ศรีอัยฎาพร, กฤตยา กฤตยาภิรม, พสุรเชษฐ์ สมร

ผู้พิมพ์ได้รับรายงานการรักษาด้วยวิธีลดอุณหภูมิภายในผู้ป่วยที่ได้รับบาดเจ็บจากการถูกมีดแทงที่หลอดเลือดแดงพีมอโรลข้างซ้าย และมีการเสียเลือดมากจนหัวใจหยุดเต้นทันทีที่มาถึงโรงพยาบาลแรก ได้รับการช่วยเหลือกู้ชีพ (CPR) แล้วส่งต่อไปยังโรงพยาบาลมหาวิทยาลัย แต่ปรากฏว่า 5 ชั่วโมง ภายหลังการผ่าตัดซ่อมหลอดเลือด ผู้ป่วยยังไม่รู้สึกตัว ผู้พิมพ์จึงเริ่มทำการลดอุณหภูมิภายใน (ลงมาที่ 33 องศาเซลเซียส นาน 24 ชั่วโมง) เมื่อเวลา 10 ชั่วโมง หลังจากหัวใจหยุดเต้น ในขณะที่ผู้ป่วยมีระบบไหลเวียนเลือดปกติ และไม่มีภาวะเลือดออกแล้ว ผลปรากฏว่าผู้ป่วยสามารถกลับคืนสู่ภาวะปกติและรู้สึกตัวหลังจากทำการลดอุณหภูมิภายในไปแล้ว 16 ชั่วโมง