

Detection of Recurrent Colorectal Cancer by ¹⁸F-FDG PET/CT Comparison with Contrast Enhanced CT Scan

Sunanta Chiewvit MD*, Titiporn Jiranantanakorn MD*,
Piyaporn Apisarnthanarak MD**, Potjane Kanchanapiboon MSc*, Chompunoot Hannanthawiwat MSc*,
Kritaya Ubolnuch MNS*, Nopparat Phongsawat BSc*, Pipat Chiewvit MD**

* Division of Nuclear Medicine, Department of Radiology, Siriraj Hospital, Mahidol University, Bangkok, Thailand

** Division of Diagnosis, Department of Radiology, Siriraj Hospital, Mahidol University, Bangkok, Thailand

Objective: To evaluate diagnostic performance of ¹⁸F-FDG PET/CT in assessment of recurrence colorectal cancer after treatment in Siriraj Hospital.

Material and Method: The authors retrospectively studied 48 treated colorectal cancer patients with suspected recurrence who underwent ¹⁸F-FDG PET/CT and contrast-enhanced CT (CECT). Clinical information, image follow-up for at least one year, and pathological reports of the patients were reviewed for gold standard.

Results: Recurrent or metastatic disease was found in 36 of 48 patients. Calculated sensitivity, specificity, and accuracy of ¹⁸F-FDG PET/CT were 94.4%, 66.7%, and 87.5%. ¹⁸F-FDG PET/CT can reduce false positive results of CECT in six patients, thus specificity of ¹⁸F-FDG PET/CT was statistically significantly better than that of CECT. Using lesion-based analysis with 65 recurrent sites and 26 non-recurrent lesion, ¹⁸F-FDG PET/CT showed better sensitivity 87.7%, specificity 61.5%, and accuracy 80.2 than CECT without statistical significance.

Conclusion: ¹⁸F-FDG PET/CT overall showed higher sensitivity, specificity, and accuracy than CECT.

Keywords: ¹⁸F-FDG PET/CT, Recurrent colon cancer

J Med Assoc Thai 2013; 96 (6): 703-8

Full text. e-Journal: <http://jmat.mat.or.th>

Colorectal cancer (CRC) is the third most common type of cancer in men and women. Unfortunately, about 41% develop local recurrences between nine and 24 months post-operatively⁽¹⁾. The majority of recurrences in patients who previously have undergone resection are within five years, but most commonly within three years after surgery.

Early detection of recurrent CRC has become more important, as the treatment options for localized recurrence disease have improved significantly. However, aggressive locoregional interventions (e.g. partial liver resections, radiofrequency ablation (RFA) of liver metastases, resections of pulmonary metastases) are as of yet considered futile in the presence of metastases elsewhere⁽²⁾. Detection of residual tumor throughout the body with high sensitivity and specificity imaging technique is important for patient management with regard to invasive therapy.

Traditionally investigation for CRC recurrence performed using CEA tumor marker, anatomical imaging techniques such as ultrasound (US), contrast enhanced computed tomography (CECT) and magnetic resonance imaging (MRI).

Functional imaging may be of additional value. ¹⁸F-FDG PET has been shown to be highly accurate in the detection of recurrent and metastatic CRC⁽³⁻⁷⁾.

The purpose of the present study was to assess the diagnostic performance of ¹⁸F-FDG PET/CT scan in the detection of recurrent CRC, compared to contrast enhanced CT scan (CECT).

Material and Method

The authors collected 74 CRC patients, who underwent ¹⁸F-FDG PET/CT scan between November 2006 and December 2010. Exclusion was made on eight patients due to no definite diagnosis (i.e. coexistent with other malignancy), and 18 patients due to not enough information for definite diagnosis or no follow-up data after PET/CT study for at least one year. Finally, there were 48 patients included in the present study. Reading ¹⁸F-FDG PET/CT is positive

Correspondence to:

Chiewvit S, Division of Nuclear Medicine, Department of Radiology, Siriraj Hospital, Mahidol University, Bangkok 10700, Thailand.

Phone: 0-2419-6220

E-mail: sunanta.chi@mahidol.ac.th

by visual activity accumulation more than adjacent area.

The diagnosis of recurrent disease was made by pathological proven of malignancy, the progression of clinical or imaging follow-up, or the responsiveness of the lesion to the treatment with chemotherapy or radiation therapy.

The diagnosis of non-recurrent disease was made by the pathological proven of benign lesion, no interval change of the lesion without treatment on follow-up imaging for at least one year after ¹⁸F-FDG PET/CT scan or no abnormal finding on follow-up imaging for at least one year after ¹⁸F-FDG PET/CT scans.

Statistical analysis

Patient-based and lesion-based analysis were calculated by using the standard formula for sensitivity, specificity and accuracy of ¹⁸F-FDG PET/CT scan, compared to the gold standard (pathohistology, clinical or imaging follow-up for at least one year) and contrast-enhanced CT scan. Statistical significance between the two imaging modalities was calculated by McNemar's test, which p-value of less than 0.05 was considered statistically significant.

The study was approved by the Ethical Committee, Faculty of Medicine Siriraj Hospital, Mahidol University.

Results

Patient characteristics and demographic data are shown in Table 1.

Recurrent disease was found in 36 patients (75%), which 24 patients had pathological proven

Table 1. Forty-eight patient characteristic

Patient characteristics	Value
Gender	
Male	31
Female	17
Mean age (range)	
Male	63.4 (43-79)
Female	59.3 (35-87)
Primary lesion	
Colon	27
Rectum	21
Indication for ¹⁸ F-FDG PET/CT scan	
Elevated serum CEA >5 ng/ml or rising CEA level	11
Abnormal conventional imaging	17
Assessment of resectability	20

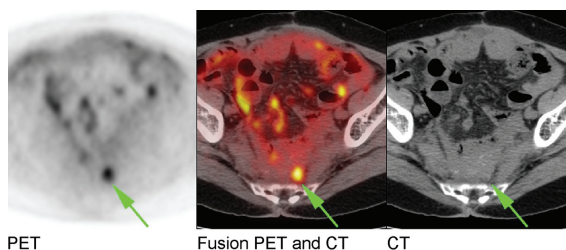


Fig. 1 A 69-year-old man with the diagnosis of adenocarcinoma of rectum post low anterior resection and rising CEA level. The CT image shows a presacral mass which is unclear to be fibrotic mass or tumor recurrence. The ¹⁸F-FDG PET/CT shows an evidence of increased glucose metabolism at presacral nodule compatible with local recurrence.

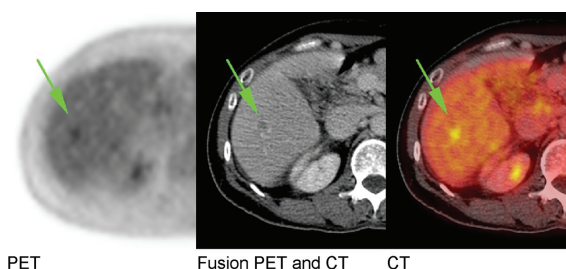


Fig. 2 A 50-year-old woman with the diagnosis of adenocarcinoma of rectum, the ¹⁸F-FDG PET/CT reveals increased glucose activity at a hypodensity lesion found by CT study. The pathological from wedge resection of liver confirmed the diagnosis of metastasis adenocarcinoma.

and 12 patients demonstrated disease progression or response to treatment on follow-up imaging. Forty-eight regions in 36 patients with recurrent disease are shown in Table 2.

The authors found that ¹⁸F-FDG PET/CT scan could reduce false positive result of CECT in six patients (chest, primary rectum, peritoneal nodule, and liver lesion), therefore the specificity of ¹⁸F-FDG PET/CT scan was better than CECT (p = 0.016). However, There was no significant difference between the sensitivity and the accuracy of these two modalities (p = 0.687 and 0.267).

There were 91 lesions detected by CECT or ¹⁸F-FDG PET/CT, 65 of which showed recurrence. Concordance findings are found in 43/65 lesions. ¹⁸F-FDG PET/CT scan can reduce false positive of CECT for 13 lesions (5 mediastinal lymph nodes, 3 local recurrence of rectal cancer, 1 peritoneal nodule, 3 intraabdominal lymph node, and 1 liver lesion).

Table 2. Regions of recurrences or metastases

Region	Number of patients
Local	7
Intraabdominal-extrahepatic	16
Liver	12
Chest	11
Bone	2

Table 3. CECT and ¹⁸F-FDG PET/CT result for recurrence by patient-based analysis and lesion based analysis

Study	Patient-based analysis (n = 48)	
	Positive by gold standard	Negative by gold standard
CECT		
Positive	32	10
Negative	4	2
¹⁸ F FDG PET/CT		
Positive	34	4
Negative	2	8
Lesion base analysis (n = 91)		
CECT		
Positive	50	18
Negative	15	8
¹⁸ F-FDG PET/CT		
Positive	57	10
Negative	8	16

Table 4. Diagnostic performance of CECT compares with ¹⁸F-FDG PET/CT by patient based analysis and lesion based analysis

Study by patient based analysis	Sensitivity	Specificity	Accuracy
CECT	88.9%	16.7%	70.9%
¹⁸ F-FDG PET/CT	94.4%	66.7%	87.5%
p-value*	0.687	0.016	0.267
Study by lesion based analysis			
CECT	76.9%	30.8%	63.7%
¹⁸ F-FDG PET/CT	87.7%	61.5%	80.2%
p-value*	0.189	0.096	1.000

* p-value <0.05 is considered statistically significant (McNemar's test)

However, ¹⁸F-FDG PET/CT scan also give false positive for five lesions (2 mediastinal lymph nodes, 2 local recurrence of rectal cancer, and 1 liver lesion). ¹⁸F-FDG PET/CT scan provided the better sensitivity,

specificity, and accuracy than that of CECT but did not reach the statistical significance.

Discussion

Anatomic imaging modalities, mainly computed tomography (CT), have an important role in the detection of early recurrence in patients with CRC. CT, however, is limited by a reliance on size criteria in the diagnosis of malignancy; for instance, metastases to regional lymph nodes are mostly diagnosed with size criteria. Conversely, although large masses are more likely to be malignant, some may be benign masses that are composed solely of fibrotic tissue. Limitation of the CT scan is also the incapability to differentiate between viable and nonviable tumor lesion. ¹⁸F-FDG PET/CT has been reported to have an important complementary role in the detection of distant metastases, local recurrence and in the differentiation of malignant and nonmalignant masses, by detecting the glucose metabolism of the cells.

Meta-analysis data of 11 articles by Huebner RH et al⁽⁸⁾ found overall sensitivity of 97% (95% confidence level, 95 to 99%) and an overall specificity of 76% (95% confidence level, 64 to 88%) for ¹⁸F-FDG PET in the detecting recurrent CRC throughout the whole body. Furthermore, the change-in-management data, an overall ¹⁸F-FDG PET directed change in management was calculated to be 29% (95% confidence level, 25 to 34%).

The previous study by Metser Uet al⁽⁹⁾ included 158 patients who had a history of CRC, elevated or increasing CEA levels, and conventional imaging that did not reveal an unequivocal explanation of the elevated CEA level. The sensitivities of PET/CT and CT for patient base were 97.3% (95% CI, 85 to 99%) and 70.3% (95% CI, 53 to 84%) (p = 0.002) and that the specificities for patient base were 94.4% (95% CI, 72 to 99%) and 94.4% (95% CI, 72 to 99%) (p = 1.0). The tumor site-based analysis showed the sensitivities of PET/CT and MDCT were 98.1% (95% CI, 90 to 99%) and 66.7% (95% CI, 52 to 78%) (p < 0.0001) and the specificities were 75% (95% CI, 34 to 96%) and 62.5% (95% CI, 24 to 91%) (p = 0.56). The specificity in Metser U study by PET/CT and CT was higher than this study.

The study by Mittal BR et al⁽¹⁰⁾ analyzed 73 (55 male, 18 female; age range 25 to 80 years) histopathologically proven patients with CRC underwent FDG PET/CT imaging for the detection of recurrence after the initial treatment. The lesions

detection by CT and PET/CT in relation to CEA levels present in Table 5.

Rising CEA level 51 patients, CT showed recurrence in 23 (45%) patients, whereas PET/CT was positive in 36 (71%) patients. Results of PET/CT and CT in each group are depicted in the Table. In 13 patients, CT was negative, whereas PET was positive (three patients – liver lesions, five patients – lymph nodes, two patients – bone metastases, one patient – local recurrence in urinary bladder wall, one patient – lymph node and liver metastases, and one patient – lymph node and bone metastases), thereby changing the management. The PET/CT was 100% positive in cases that had CEA level of more than 50 ng/ml.

The study by Chen LBet al⁽¹¹⁾ in 56 recurrence and/or metastasis CRC patients reveals sensitivity of PET/CT diagnosis of CRC recurrence and/or metastasis was 94.6%, and the specificity was 83.3%. The positive predictive value (PPV) was 96.4% and the negative predictive value (NPV) was 76.9%. PET/CT imaging detected one or more occult malignant lesions in eight cases where abdominal/pelvic CT and/or ultrasonography showed negative findings. Furthermore, it detected more lesions than CT or ultrasonography did in 30.4% (17/56) cases. Recurrence and/or metastasis were detected in 91.7% (22/24) cases with elevated serum CEA levels by ¹⁸F-FDG PET/CT imaging.

Table 5. Show the comparative results of CT and PET/CT positive cases in relation to CEA levels

CEA level in ng/ml (n = 73)	CT positive (n = 24) (%)	PET/CT positive (n = 39) (%)
>50 (n = 9)	6/9 (67)	9/9 (100)
20-50 (n = 9)	5/9 (55)	7/9 (77)
10-20 (n = 11)	5/11 (45)	7/11 (63)
5-10 (n = 9)	3/9 (33)	6/9 (67)
3-5 (n = 13)	4/13 (30)	7/13 (53)
Normal <3 (n = 22)	1/22 (4.5)	3/22 (13)

The abstract from Choi EK et al⁽¹²⁾ study to assess the value of ¹⁸F-FDG PET/CT for detecting local or distant recurrence in 269 CRC patients (289 PET/CT scans) patients operated for colorectal cancer and to compare the accuracy with conventional imaging studies. The overall sensitivity, specificity, accuracy, PPV, and NPV were 94.7%, 96.0%, 95.8%, 78.2%, and 99.2% for PET/CT, and 86.8%, 97.6%, 96.2%, 84.6%, and 98.0% for conventional imaging studies. On region-based analysis, PET/CT detected more lesions compared to conventional imaging studies in local recurrence (14/15 vs. 13/15) and peritoneal-carcinomatosis (4/4 vs. 3/4). PET/CT and conventional imaging studies detect the same number of lesions in abdominal lymph nodes (8/8) and hepatic (13/13) metastases. PET/CT additionally detected metastases to lung (n = 5) and bone (n = 1). Both PET/CT and conventional imaging studies showed false positive finding in a case for single spleen metastasis that was pathologically proven to be chronic inflammation. A PET/CT false positive lesion in supraclavicular lymph node was pathologically proven to be mycobacterial infection.

The study by Lee JH et al⁽¹³⁾ in 59 recurrence or a metastasis in postoperative patients suspected recurrent conditions and normal CEA level patients, 107 suspicious recurrent findings for 63 ¹⁸F-FDG PET/CT cases were included in this study. The result is in the Table 6.

The results of the present study have shown that ¹⁸F-FDG PET/CT is a useful method in postoperative patients with suspected recurrent colorectal cancerous lesions and a normal CEA level. When conventional imaging methods have shown equivocal findings, ¹⁸F-FDG PET/CT is effective and helpful to distinguish local recurrences or metastases from postoperative changes or benign disease findings that may not be meaningful.

Previous studies as described above have shown that ¹⁸F-FDG PET/CT to detect recurrent

Table 6. Diagnostic performance comparison between ¹⁸F-FDG PET/CT and conventional imaging

Study	Sensitivity (%)	Specificity (%)	Accuracy (%)
By lesion analysis (n = 79)			
PET/CT	94.7 (54/57)	86.4 (19/22)	92.4 (73/79)
Conventional imaging	98.2 (56/57)	4.5 (1/22)	72.2 (57/79)
By patient analysis (n = 39)			
PET/CT	96.0 (24/25)	92.9 (13/14)	94.9 (37/39)
Conventional imaging	100 (22/22)	0 (0/17)	56.4 (22/39)

McNemar's test p<0.05

disease gives better sensitivity and specificity when compared to that of CT scan and conventional imaging like the present study. With the use of that ¹⁸F-FDG PET/CT studies demonstrated more information of detect lesion and characterization, comparing CT, the present study also shows comparable overall sensitivity and accuracy (94.4% and 87.5%), but lower in specificity (66.7%) As with lesion-based analysis, the authors found that ¹⁸F-FDG PET/CT can reduce false positive results of CECT in 13 lesions, but also causes false positive results in five lesions.

Conclusion

¹⁸F-FDG PET/CT is a better method to evaluate post-operative CRC patients with suspected tumor recurrence or distant metastasis than CT especially the specificity.

Potential conflicts of interest

None.

References

- Huguier M, Houry S, Barrier A. Local recurrence of cancer of the rectum. *Am J Surg* 2001; 182: 437-9.
- Gayowski TJ, Iwatsuki S, Madariaga JR, Selby R, Todo S, Irish W, et al. Experience in hepatic resection for metastatic colorectal cancer: analysis of clinical and pathologic risk factors. *Surgery* 1994; 116: 703-10.
- Scott AM. Current status of positron emission tomography in oncology. *Intern Med J* 2001; 31: 27-36.
- Lai DT, Fulham M, Stephen MS, Chu KM, Solomon M, Thompson JF, et al. The role of whole-body positron emission tomography with [¹⁸F] fluorodeoxyglucose in identifying operable colorectal cancer metastases to the liver. *Arch Surg* 1996; 131: 703-7.
- Ogunbiyi OA, Flanagan FL, Dehdashti F, Siegel BA, Trask DD, Birnbaum EH, et al. Detection of recurrent and metastatic colorectal cancer: comparison of positron emission tomography and computed tomography. *Ann Surg Oncol* 1997; 4: 613-20.
- Flamen P, Stroobants S, Van Cutsem E, Dupont P, Bormans G, De Vadder N, et al. Additional value of whole-body positron emission tomography with fluorine-18-2-fluoro-2-deoxy-D-glucose in recurrent colorectal cancer. *J Clin Oncol* 1999; 17: 894-901.
- Akhurst T, Larson SM. Positron emission tomography imaging of colorectal cancer. *Semin Oncol* 1999; 26: 577-83.
- Huebner RH, Park KC, Shepherd JE, Schwimmer J, Czernin J, Phelps ME, et al. A meta-analysis of the literature for whole-body FDG PET detection of recurrent colorectal cancer. *J Nucl Med* 2000; 41: 1177-89.
- Metser U, You J, McSweeney S, Freeman M, Hendler A. Assessment of tumor recurrence in patients with colorectal cancer and elevated carcinoembryonic antigen level: FDG PET/CT versus contrast-enhanced 64-MDCT of the chest and abdomen. *AJR Am J Roentgenol* 2010; 194: 766-71.
- Mittal BR, Senthil R, Kashyap R, Bhattacharya A, Singh B, Kapoor R, et al. ¹⁸F-FDG PET-CT in evaluation of postoperative colorectal cancer patients with rising CEA level. *Nucl Med Commun* 2011; 32: 789-93.
- Chen LB, Tong JL, Song HZ, Zhu H, Wang YC. (¹⁸F)-DG PET/CT in detection of recurrence and metastasis of colorectal cancer. *World J Gastroenterol* 2007; 13: 5025-9.
- Choi EK, Yoo LR, Han EJ, Oo JH, Kim SH, Chung SK. Value of surveillance F-18 FDG PET/CT in colorectal cancer: comparison with conventional imaging studies. *J Nucl Med* 2010; 51 (Supplement 2): 1208 (abstract).
- Lee JH, Park SG, Jee KN, Park DG, Namgung H, Song IH. Performance of FDG PET/CT in postoperative colorectal cancer patients with a suspected recurrence and a normal CEA level. *Nucl Med Commun* 2010; 31: 576-82.

การตรวจ ^{18}F -FDG PET/CT เปรียบเทียบกับการตรวจ CT ในการตรวจพบรอยโรคมะเร็งลำไส้ใหญ่กลับเป็นซ้ำ

สุนันทา เชี่ยววิทย์, ธิติพร จิรนนทนากร, ปิยาภรณ์ อภิสารธนรักษ์, พจนีย์ กาญจนพิบูลย์, ชมพูนุช หาญนนทวิวัฒน์, กฤตยา อุบลนุช, นพรัตน์ พงษ์สวัสดิ์, พิพัฒน์ เชี่ยววิทย์

วัตถุประสงค์: เป็นการศึกษาความสามารถของการตรวจ ^{18}F -FDG PET/CT ในผู้ป่วยมะเร็งลำไส้หลังการรักษาที่สงสัยมะเร็งกลับเป็นซ้ำในโรงพยาบาลศิริราช

วัสดุและวิธีการ: การศึกษาย้อนหลังผู้ป่วยมะเร็งลำไส้หลังการรักษาที่สงสัยมะเร็งกลับเป็นซ้ำ 48 ราย ที่ได้รับการตรวจ ^{18}F -FDG PET/CT และการตรวจ CT ด้วยสารทึบรังสี มีการตรวจสอบและทบทวนประวัติผู้ป่วย, การตรวจติดตาม และผลชิ้นเนื้อเพื่อแสดงผลการวินิจฉัยมาตรฐาน

ผลการศึกษา: พบการกลับเป็นซ้ำและการแพร่กระจายมะเร็งลำไส้ในผู้ป่วย 36 ราย จากผู้ป่วย 48 ราย ความสามารถในการตรวจ ^{18}F -FDG PET/CT ในการวินิจฉัยการกลับเป็นซ้ำและการแพร่กระจายมะเร็งลำไส้มีความไวร้อยละ 94.4 ความจำเพาะร้อยละ 66.7 และความแม่นยำร้อยละ 87.5 การตรวจ ^{18}F -FDG PET/CT ทำให้สามารถวินิจฉัยผลบวกดวงจากการตรวจ CT รายได้ถูกต้อง 6 ราย และการตรวจ ^{18}F -FDG PET/CT มีความจำเพาะมากกว่าการตรวจ CT อย่างมีนัยสำคัญทางสถิติ เมื่อวิเคราะห์โดยรอยโรคพบว่ามีย่อยโรคที่เป็นการกลับเป็นซ้ำและการแพร่กระจายมะเร็งลำไส้ 65 รอยโรค และมีรอยโรคที่ไม่ใช่การกลับเป็นซ้ำและการแพร่กระจายมะเร็งลำไส้ 26 รอยโรค การตรวจ ^{18}F -FDG PET/CT มีความไวร้อยละ 87.7 ความจำเพาะร้อยละ 61.5 และความแม่นยำร้อยละ 80.2 ดีกว่าการตรวจ CT แต่ไม่มีความแตกต่างทางสถิติ

สรุป: การตรวจ ^{18}F -FDG PET/CT เป็นวิธีการตรวจที่ดีในผู้ป่วยมะเร็งลำไส้ใหญ่หลังการผ่าตัดที่สงสัยว่ามีมะเร็งกลับเป็นซ้ำ หรือมีการแพร่กระจายกว่าการตรวจ CT โดยเฉพาะค่าความจำเพาะ
