

Case Report

Necrotizing Fasciitis: A Rare Manifestation of Late-Onset Neonatal Group B Streptococcal Infection

Sariya Prachukthum MD*, Sudatip Kositamongkol MD*,
Pornumpa Bunjoungmanee MD*, Auchara Tangsathapornpong MD*

* Department of Pediatrics, Faculty of Medicine, Thammasat University, Pathumthani, Thailand

Preterm infants have a risk factor of developing late-onset group B streptococcal (GBS) infection. A 62-day-old infant who was a former 25-week male infant presented with fever and an erythematous, warm and tender, soft tissue swelling in the right submandibular region. He was diagnosed with cellulitis. Within 72 hours, his lesion had rapidly progressed to necrotizing fasciitis. His blood culture grew penicillin-sensitive GBS. This reported case illustrates necrotizing fasciitis as a rare manifestation of late-onset neonatal GBS infection.

Keywords: Necrotizing fasciitis, Group B streptococcal infection, GBS, Neonate, Late-onset, Manifestation

J Med Assoc Thai 2014; 97 (6): 669-72

Full text. e-Journal: <http://www.jmatonline.com>

A 720-g male infant was born at 25 weeks' gestation by cesarean section to a 33-year-old, Gravida 3 Para 2 now 3, woman whose group B *Streptococcus* (GBS) status was unknown. This pregnancy was complicated by prolonged premature rupture of membrane. The infant's mother had received ampicillin and dexamethasone 3 days prior to delivery. He was intubated and given surfactant at birth. His Apgar scores were 9 and 10 at 1 and 5 minutes, respectively.

He had been admitted to neonatal intensive care unit for respiratory distress syndrome. He was diagnosed with patent ductus arteriosus (PDA) and required PDA ligation on postnatal day 8. He received a 10-day course of cefotaxime and vancomycin on suspicion of neonatal sepsis. He was extubated to a nasopharyngeal continuous positive airway pressure when he was 45 days old. All was as anticipated.

Surprisingly, on the 62nd day after birth, he developed fever, lethargy and frequent oxygen desaturations. His physical examination showed an elevated temperature of 39°C, an accelerated heart rate of 200 beats per minute; however, his respiration and blood pressure were in normal limits. It was observed that his right submandibular region had an erythematous, warm, tender, soft tissue swelling, extending from his right ear to the upper neck (Fig. 1A). Other examinations were unremarkable.

His complete blood count (CBC) revealed a white blood cell (WBC) count of $4.2 \times 10^3/\mu\text{L}$, with 45% neutrophils, 53% lymphocytes and 1% monocytes, a hemoglobin level of 9.9 g/dl, and platelets at $397 \times 10^3/\mu\text{L}$. His C-reactive protein (CRP) result was 6.01 mg/L (normal <5) and increased to 210.21 mg/L on the next day. A cerebrospinal fluid (CSF) analysis exposed a count of 1,500 cells/ μL , including 2 leucocytes/ μL (of which were all lymphocytes), a protein level of 301.8 mg/dl, and a glucose level of 147 mg/dl. A computed tomography (CT) scan of the neck showed a diffuse soft tissue edema involving retropharyngeal space, bilateral pharyngeal mucosal spaces, parapharyngeal, parotid and carotid spaces in both cheeks and chin extending to the upper mediastinum, consistent with acute cellulitis (Fig. 2). He was treated empirically with vancomycin and meropenem.

Within 72 hours, his lesion had expanded to the right temporal-parietal scalp with discoloration

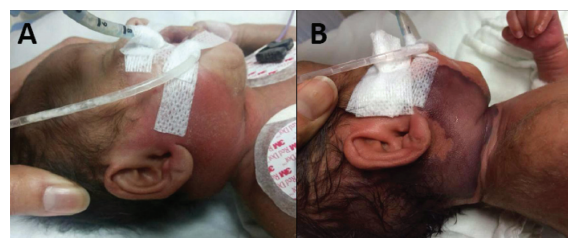

Fig. 1 A) Erythematous, warm, tender, soft tissue swelling in the right submandibular region, extending from his right ear to the upper neck. B) Expanded lesion to right temporal-parietal scalp with discoloration.

Correspondence to:

Prachukthum S, Department of Pediatrics, Faculty of Medicine, Thammasat University, Pathumthani 12120, Thailand.

Phone: 0-2926-9514

E-mail: sariyarpd238@yahoo.com

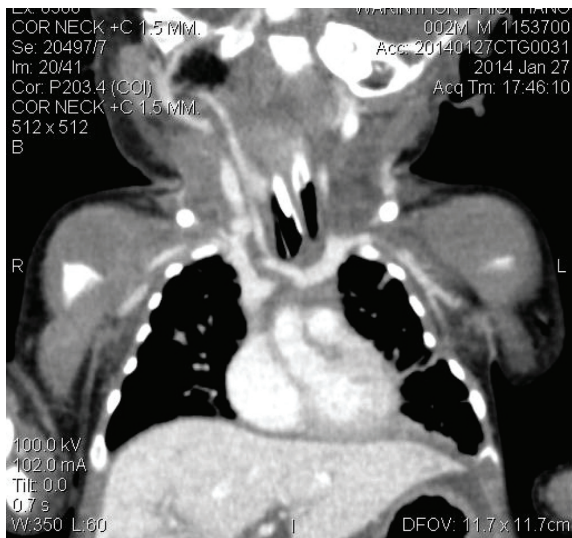


Fig. 2 CT scan of neck showing diffuse soft tissue edema involving retropharyngeal space, bilateral pharyngeal mucosal spaces, parapharyngeal space, consistent with acute cellulitis.

(Fig. 1B). Nevertheless, his vital signs remained normal. At this time, his hemoglobin concentration was 10.2 g/dl, WBC count $11.1 \times 10^3/\mu\text{L}$ with an elevated level of 85% neutrophils, 14% lymphocytes and 1% monocytes. Platelets were $87 \times 10^3/\mu\text{L}$, and peripheral blood smear showed disseminated intravascular coagulopathy (DIC). His blood culture grew penicillin-sensitive GBS, but the CSF culture did not grow any organisms. He appeared to be getting worse; therefore, clindamycin was added on an empirical treatment.

Despite all these interventions, his condition sufficiently deteriorated to the point where the decision was made to send him to surgery. During the operation, we found necrotizing fasciitis, so extensive debridement was performed. As a last resort, a 2-gm/kg dose of intravenous immunoglobulin (IVIG) was given. After his lesion ameliorated, the antibiotic regimen was switched to penicillin to complete a total of 3 weeks of antibiotics by intravenous administration. He was, then, discharged home when he was 137 days old.

Discussion

Group B *Streptococcus* is the most common cause of life-threatening infections in newborns. GBS is classified by disease onset: early-onset disease (occurs at 5 or 6 days of age), late-onset infection (occurs at 7 days to 3 months of age) and late late-onset infection (occurs at 3 to 6 months of age). Late late-onset is especially common in infants with a gestational

age of less than 28 weeks⁽¹⁾. Late late-onset infection accounted for 20% of cases of late-onset disease⁽²⁾. Most of these infants have a gestational age of less than 35 weeks. The need for prolonged hospitalization and the immature host status in these infants were two risk factors in developing an infection beyond the interval for term neonates. The incidence of late-onset disease is 0.3 per 1,000 live births⁽³⁾. Late-onset disease has a lower mortality rate (1 to 6%) than early-onset disease.

In late-onset group B *Streptococcus* infection, the principle effect is cellular invasion by bloodstream penetration. However, cellular damage seems to result largely from the actions of β -hemolysin/cytolysin, GBS by products. When GBS penetrates into the bloodstream, an immunologic response such as phagocytic cells including neutrophils and macrophages, is recruited to clear the organisms. Opsonization of the bacterium, by specific antibodies, then takes place in the presence of the complement.

Neonates are particularly prone to invasive GBS disease because of quantitative and/or qualitative, deficiencies in phagocytic cell function, specific antibodies, or classic and alternate complement pathways⁽⁴⁾. The GBS type III (51%) is the most common type causing late-onset infection followed by type Ia (24%) and V (14%)⁽⁵⁻⁸⁾. Clinical manifestations of late-onset disease include bacteremia without a focus of infection (65% of infants), meningitis (25%), bacteremic cellulitis (2% to 3%), osteoarthritis (2% to 3%), and pneumonia (3%)⁽¹⁾.

Necrotizing fasciitis is a rare manifestation of GBS infection^(9,10). Penicillin G is the drug of choice for treatment of GBS infections. Data from multiple studies show that 20-30% and 10-20% of isolates are erythromycin resistant, and clindamycin resistant, respectively⁽¹¹⁻¹³⁾. An empirical therapy should be penicillin, or ampicillin, and an aminoglycoside for preterm infants remaining hospitalized from birth. Parenteral therapy is given for 10 days for bacteremia, or with most soft tissue infections, 2 to 3 weeks for meningitis or arthritis, and 3 to 4 weeks for osteomyelitis or endocarditis.

The author's patient was a former 25-week male infant that was at risk to develop late onset GBS infection. He had not had intravenous devices placed in the 4 weeks before he got sick. Although we gave vancomycin, his cellulitis was rapidly progressing to necrotizing fasciitis, and he developed DIC. Therefore, empirical antibiotics were not enough, and early debridement was required to treat successfully the necrotizing fasciitis. There have been a few

reported cases of necrotizing fasciitis cause by GBS infection^(10,14,15), and most of them were preterm infants with lesions limited to the submandibular area. Penicillin and gentamicin were given as treatment for 3 weeks. They underwent debridement. The present case and previous studies illustrate typical cases of late onset GBS infection with necrotizing fasciitis that were located at head and neck in the preterm infants. In addition to antibiotics therapy, debridement is an essential procedure for successful treatment.

The infant also received a high dose of IVIG. In experimental models⁽¹⁶⁾ and septic neonates⁽¹⁷⁾, complement activation and chemotaxis as well as resolution of neutropenia, improved after giving IVIG. However, commercial IVIG products contain relatively low levels of specific antibodies to GBS polysaccharides, so large doses are required^(18,19). The use of IVIG, though, remains controversial because a meta-analysis of IVIG found that adjunctive IVIG did not reduce death or major disability in infants with bacterial infection⁽²⁰⁾. While he was improving, vancomycin was changed to penicillin in reference to the susceptibility result. He was treated for 21 days on a course of intravenous antibiotics and made a full recovery.

Conclusion

As noted on this case and other literatures, infants with a gestational age of less than 35 weeks, are at risk of developing late-onset infection. This infection can be bacteremia without a focus of infection, meningitis, bacteremic cellulitis, osteoarthritis and pneumonia. Necrotizing fasciitis is a rare manifestation of late-onset neonatal GBS infection. In the great majority of cases, this form of fasciitis is rapidly spreading, and usually located at the head and neck. Key factors in successful treatment should include antibiotic therapy and debridement.

Potential conflicts of interest

None.

References

1. Phares CR, Lynfield R, Farley MM, Mohle-Boetani J, Harrison LH, Petit S, et al. Epidemiology of invasive group B streptococcal disease in the United States, 1999-2005. *JAMA* 2008; 299: 2056-65.
2. Yagupsky P, Menegus MA, Powell KR. The changing spectrum of group B streptococcal disease in infants: an eleven-year experience in a tertiary care hospital. *Pediatr Infect Dis J* 1991; 10: 801-8.
3. Zangwill KM, Schuchat A, Wenger JD. Group B streptococcal disease in the United States, 1990: report from a multistate active surveillance system. *MMWR CDC Surveill Summ* 1992; 41: 25-32.
4. Lewis DB, Wilson CB. Developmental immunology and role of host defenses in neonatal susceptibility to infection. In: Remington JS, Klein JO, Wilson CB, Baker CJ, editors. *Infectious disease of the fetus and newborn infant*. 6th ed. Philadelphia: WB Saunders; 2005: 87-210.
5. Blumberg HM, Stephens DS, Modansky M, Erwin M, Elliot J, Facklam RR, et al. Invasive group B streptococcal disease: the emergence of serotype V. *J Infect Dis* 1996; 173: 365-73.
6. Zaleznik DF, Rench MA, Hillier S, Krohn MA, Platt R, Lee ML, et al. Invasive disease due to group B *Streptococcus* in pregnant women and neonates from diverse population groups. *Clin Infect Dis* 2000; 30: 276-81.
7. Harrison LH, Elliott JA, Dwyer DM, Libonati JP, Ferrieri P, Billmann L, et al. Serotype distribution of invasive group B streptococcal isolates in Maryland: implications for vaccine formulation. Maryland Emerging Infections Program. *J Infect Dis* 1998; 177: 998-1002.
8. Lin FY, Clemens JD, Azimi PH, Regan JA, Weisman LE, Philips JB III, et al. Capsular polysaccharide types of group B streptococcal isolates from neonates with early-onset systemic infection. *J Infect Dis* 1998; 177: 790-2.
9. Goldberg GN, Hansen RC, Lynch PJ. Necrotizing fasciitis in infancy: report of three cases and review of the literature. *Pediatr Dermatol* 1984; 2: 55-63.
10. Ramamurthy RS, Srinivasan G, Jacobs NM. Necrotizing fasciitis and necrotizing cellulitis due to group B *Streptococcus*. *Am J Dis Child* 1977; 131: 1169-70.
11. Biedenbach DJ, Stephen JM, Jones RN. Antimicrobial susceptibility profile among beta-haemolytic *Streptococcus* spp. collected in the SENTRY Antimicrobial Surveillance Program—North America, 2001. *Diagn Microbiol Infect Dis* 2003; 46: 291-4.
12. Manning SD, Foxman B, Pierson CL, Tallman P, Baker CJ, Pearlman MD. Correlates of antibiotic-resistant group B *Streptococcus* isolated from pregnant women. *Obstet Gynecol* 2003; 101: 74-9.

13. de Azavedo JC, McGavin M, Duncan C, Low DE, McGeer A. Prevalence and mechanisms of macrolide resistance in invasive and noninvasive group B *Streptococcus* isolates from Ontario, Canada. *Antimicrob Agents Chemother* 2001; 45: 3504-8.
14. Bomar WE Jr, Ferlauto JJ, Wells DH. An unusual presentation of a beta hemolytic group B streptococcal infection. *J Pediatr Surg* 1980; 15: 683-5.
15. Lang ME, Vaudry W, Robinson JL. Case report and literature review of late-onset group B streptococcal disease manifesting as necrotizing fasciitis in preterm infants: is this a new syndrome? *Clin Infect Dis* 2003; 37: e132-5.
16. Redd H, Christensen RD, Fischer GW. Circulating and storage neutrophils in septic neonatal rats treated with immune globulin. *J Infect Dis* 1988; 157: 705-12.
17. Christensen KK, Christensen P. Intravenous gamma-globulin in the treatment of neonatal sepsis with special reference to group B streptococci and pharmacokinetics. *Pediatr Infect Dis* 1986; 5 (3 Suppl): S189-92.
18. Kim KS. Effect of antimicrobial therapy for experimental infections due to group B *Streptococcus* on mortality and clearance of bacteria. *J Infect Dis* 1987; 155: 1233-41.
19. Kim KS. High-dose intravenous immune globulin impairs antibacterial activity of antibiotics. *J Allergy Clin Immunol* 1989; 84: 579-86.
20. Ohlsson A, Lacy JB. Intravenous immunoglobulin for suspected or proven infection in neonates. *Cochrane Database Syst Rev* 2013; 7: CD001239.

Necrotizing fasciitis: ภาวะแสดงที่พบน้อยมากในทารกที่ติดเชื้อ group B Streptococcus ที่มีอาการแสดงในระยะหลัง

ศรียา ประจักษ์ธรรม, สุดาทิพย์ โฆสิตะมงคล, พรอำภา บรรจงมณี, อัจฉรา ตั้งสถาพรพงษ์

ทารกเกิดก่อนกำหนดมีความเสี่ยงในการเกิดการติดเชื้อ group B streptococcal (GBS) ที่มีอาการแสดงในระยะหลัง ผู้ป่วยทารกเพศชายอายุ 62 วัน เกิดเมื่ออายุครรภ์ 25 สัปดาห์ มีอาการแสดงของไข้ และอาการบวมแดงร้อนของผิวหนังที่บริเวณกรามด้านขวาเข้าได้กับ cellulitis ภายใน 72 ชั่วโมง ถัดมาอาการทางผิวหนังได้เปลี่ยนแปลงไปเป็น necrotizing fasciitis อย่างรวดเร็ว ผลการเพาะเชื้อในเลือดพบว่าขึ้นเชื้อ GBS ซึ่งไวต่อยากลุ่มเพนิซิลลิน ซึ่งรายงานผู้ป่วยนี้แสดงถึง necrotizing fasciitis ซึ่งเป็นอาการแสดงที่พบน้อยมากในทารกที่ติดเชื้อ GBS ที่มีอาการแสดงในระยะหลัง
