

# Treatment Outcome of Ruptured Intracranial Aneurysms: A Retrospective Comparison Study, Clipping Versus Coiling

Gahn Duangprasert MD<sup>1</sup>, Raywat Noiphitak MD<sup>1</sup>, Vich Yindeedej MD<sup>1</sup>, Dilok Tantongtip MD<sup>1</sup>

<sup>1</sup> Division of Neurosurgery, Department of Surgery, Faculty of Medicine, Thammasat University Hospital, Pathum Thani, Thailand

**Background:** In deciding a treatment for aneurysm occlusion, surgical clipping had long been the main option. In recent years, the use of endovascular coiling technique has seen a substantial rise, leading to discussions on the topic of “clip versus coil” and debating which technique is more favorable.

**Objective:** To compare microsurgical clipping and endovascular coiling by investigating the ruptured intracranial aneurysm treatment outcomes in a real-world setting, in which the patients included in this study were heterogenous in nature.

**Materials and Methods:** A retrospective study of 331 patients. Of these, 229 patients underwent surgical clipping and 102 had endovascular coiling. The primary outcome was modified Rankin scale (mRS) at one year, and the secondary outcomes were rate of aneurysm recurrence, cerebral vasospasm, and shunt-dependent hydrocephalus.

**Results:** Statistically, the authors found no major difference between these two treatment procedures at one year (mRS 0 to 2). Favorable outcomes were 65.5% and 71.6% in clipping and coiling group, respectively ( $p=0.057$ ). From subgroup analysis of primary outcome, endovascular coiling achieved better results in patients with poor World Federation of Neurosurgical Societies Grading (WFNS) grade ( $p=0.017$ ) and posterior circulation aneurysms ( $p=0.018$ ). Coiling showed promising results in poor grade subarachnoid hemorrhage (SAH) patients with 43.8% favorable outcomes. In secondary outcomes, surgical clipping showed more favorable degree of aneurysm obliteration, but with tendency towards cerebral vasospasm. As for shunt-dependent hydrocephalus, there was no difference between the two groups.

**Conclusion:** Results showed similar clinical outcomes between the two treatment groups. However, endovascular coiling had a tendency to benefit patients with poor clinical grade and posterior circulation aneurysms. The treatment decision should be made with individual patient in mind.

**Keywords:** Intracranial aneurysms; Microsurgical clipping; Coiling embolization; Aneurysmal subarachnoid hemorrhage

Received 14 October 2021 | Revised 22 November 2021 | Accepted 23 November 2021

**J Med Assoc Thai 2022; 105(1): 6-14**

**Website:** <http://www.jmatonline.com>

Treatment of ruptured intracranial aneurysms has been significantly discussed regarding the safety and efficacy between neurosurgical clipping and endovascular coiling for decades. The advent of endovascular treatment is recognized as a less invasive technique compared with the standard surgical technique. In addition, the endovascular technique has been improved with emerging

technologies, such as techniques, materials, and devices resulting in the acceptance of this technique as an alternative to surgical clipping.

Recently, large randomized controlled trials comparing surgical clipping and endovascular coiling, including Barrow Ruptured Aneurysm Trial (BRAT)<sup>(1-3)</sup> and International Subarachnoid Aneurysm Trial (ISAT)<sup>(4)</sup>, demonstrated the advantage of endovascular coiling in term of better clinical outcome. However, this superior outcome only persisted to one year, and endovascular treatment had a higher recurrence rate, which often required re-treatment in the long term. In addition, these studies consisted of drawbacks, including potential selection bias, high cross-over rate from coiling to clipping, and lack of data for patients with poor clinical condition. Therefore, it is difficult to apply such conclusions to real-life clinical practice, especially in an institution with limited resources for endovascular treatment.

## Correspondence to:

Tantongtip D.

Division of Neurosurgery, Department of Surgery, Faculty of Medicine, Thammasat University Hospital, Pathum Thani 12120, Thailand.

**Phone:** +66-81-6621389

**Email:** dilok-t@hotmail.com

## How to cite this article:

Duangprasert G, Noiphitak R, Yindeedej V, Tantongtip D. Treatment Outcome of Ruptured Intracranial Aneurysms: A Retrospective Comparison Study, Clipping Versus Coiling. *J Med Assoc Thai* 2022; 105:6-14.

**DOI:** 10.35755/jmedassocthai.2022.01.13226

Here, the authors conducted the present study to compare the outcomes between surgical clipping and endovascular coiling for treating ruptured intracranial aneurysms based on the treatment protocol of the authors' single institution. The present study aimed to evaluate the effectiveness of the two treatment methods in routine practice conditions.

## Materials and Methods

The present study was approved by the local Institutional Review Board and Ethic Committee (MTU-EC-SU-0-173/63). The authors retrospectively reviewed the medical records of patients presenting with aneurysmal subarachnoid hemorrhage (SAH) at the present study institution between March 2014 and August 2019. The patients with the age of 18 to 80 years that underwent either surgical clipping or endovascular coiling for ruptured intracranial aneurysms in the present study institution and had complete follow-up for at least 12 months were included in the study. Exclusion criteria were the patients with complex aneurysms requiring procedure other than surgical clipping or endovascular coiling such as flow-diverter stent, or the patients with incomplete data.

### Patient evaluation

Patient demographic data including age, gender, aneurysm location, size, World Federation of Neurosurgical Societies Grading (WFNS), modified Fisher scores (MFS) were retrieved from medical records. Poor clinical grade was defined as patients with WFNS grade 4 and 5.

Modified Rankin scale (mRS) at 6 and 12 months after treatment were analyzed as primary outcome. The mRS was dichotomized into 0 to 2 and 3 to 6 to define as favorable and unfavorable outcomes, respectively. Secondary outcomes included the evaluation of the treatment results and complications that occurred in clipping and coiling groups. All patients were diagnosed as ruptured intracranial aneurysms with computed tomography (CT) angiography or cerebral angiography as appropriate.

### Treatment

All patients with ruptured intracranial aneurysms received the care under the protocol for ruptured intracranial aneurysm, including preoperative medical clearance, prophylaxis of vasospasm, and external ventricular drainage, if indicated. The treatment selection for ruptured intracranial aneurysm was based on patients' clinical status, aneurysm characteristics,

and surgeons' preference and availability with the consensus from the cerebrovascular surgery team. Patients with associating large intracerebral hematoma or clinical signs of brain herniation syndrome were preferred for surgical clipping, whereas endovascular treatment was chosen when surgery was considered high risk. In the present study, the procedures were performed by experienced neurosurgeons and neuro-interventionist. The surgical clipping was performed with different microsurgical approaches and various surgical techniques including simple clipping, clip reconstruction or trapping with or without bypass. Endovascular coil embolization was performed with platinum coils under conventional technique or additional supporting devices, such as balloon or stent assisted technique.

The postoperative care included evaluation of the patients' condition, examination of cerebral blood flow with transcranial Doppler ultrasound, and assessment of intracranial pressure if external ventricular drainage was performed. Triple-H therapy, intraarterial vasodilator, and angioplasty were performed for clinical vasospasm. The follow-up was scheduled at 3- or 6- and 12 months after the treatment, which all patients had taken at least one imaging either by cerebral angiography, computed tomography angiography (CTA), or magnetic resonance angiography (MRA) during that time.

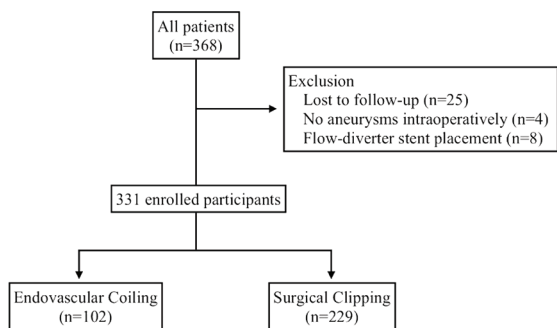
### Statistical analysis

Data were expressed as mean  $\pm$  standard deviation (SD) or number (percentage). Patients' characteristics, outcomes, and complications between groups were compared with t-test and chi-square or Fisher's exact test for numerical and categorical data, respectively. The predicting factors for favorable outcome were analyzed using univariate and multivariate logistic regression. Only p-value less than 0.2 were included in multivariate logistic regression analysis. Subgroup analysis was additionally performed to compare favorable outcome between treatment groups using the multivariate logistic regression model stratified by pre-operative WFNS, age, aneurysm location, timing to intervention, hydrocephalus, and aneurysm size. A p-value of less than 0.05 was considered to be statistically significant. All data were analyzed using IBM SPSS Statistics for Windows, version 25.0 (IBM Corp., Armonk, NY, USA).

## Results

### Patient demographic and baseline characteristics

Initially, 368 patients with aneurysmal SAH were



**Figure 1.** Patient selection and rationale for exclusion.

included in the present study. Among these, 37 patients were excluded as eight underwent flow-diverter stent placement, four had unidentifiable aneurysms, and 25 were lost to follow-up (Figure 1). Therefore, the data of 331 patients were then extracted for the analysis, comprising 229 patients in clipping and 102 patients in coiling group. The clinical characteristics of both treatment groups are summarized in Table 1. Mean age of patients in clipping group was 55.5±12.3 years, and 58.5±14.5 years in coiling group ( $p=0.08$ ). Female-to-male ratio was 2.3:1 and 2.6:1 in clipping and coiling group, respectively. There were 75 (32.8%) and 32 (31.4%) patients with poor clinical grade in clipping and coiling groups, respectively ( $p=0.64$ ). As for the location of aneurysm, in clipping group 211 (92.1%) and 18 (7.9%) located in anterior and posterior circulation, whereas coiling group were 66 (64.7%) in anterior and 36 (35.3%) in posterior circulation. Location of aneurysms in each group were significantly different ( $p<0.001$ ). Lastly, coiling group exhibited a longer timing to aneurysm treatment ( $p=0.009$ ).

### Primary outcome

Through univariate logistic regression analysis, baseline WFNS, age, and hydrocephalus were significant adverse predictor of an unfavorable outcome ( $p<0.001$ ). After adjusting for potential confounding variables, which further included treatment methods and timing to treatment in multiple logistic regression analysis, only WFNS ( $p<0.001$ , OR 2.25, 95% CI 1.74 to 2.90) and age ( $p<0.001$ , OR 1.04, 95% CI 1.02 to 1.07) remained significant (Table 2).

The primary outcome, focusing on mRS at one year, showed that the majority of patients (223, 67.4%) had favorable outcome (mRS 0 to 2), comprising 150 (65.5%) from clipping and 73 (71.6%) from coiling group (Table 3). The difference in favorable outcome

**Table 1.** Patients baseline characteristics among surgical clipping and endovascular coiling group

	Clipping (n=229)	Coiling (n=102)	Std. error difference	p-value
Age (year); mean±SD	55.5±12.3	58.5±14.5	1.655	0.076
Sex; n (%)			0.054	0.622
Male	69 (30.1)	28 (27.5)		
Female	160 (69.9)	74 (72.5)		
WFNS; n (%)			0.172	0.641
1	100 (43.7)	49 (48.0)		
2	30 (13.1)	16 (15.7)		
3	24 (10.5)	5 (4.9)		
4	61 (26.6)	21 (20.6)		
5	14 (6.1)	11 (10.8)		
MFS; n (%)			0.131	0.958
1	35 (15.3)	16 (15.7)		
2	15 (6.6)	9 (8.8)		
3	61 (26.6)	23 (22.5)		
4	118 (51.5)	54 (53.0)		
Location; n (%)			0.057	<0.001*
Anterior circulation	211 (92.1)	66 (64.7)		
• AcoA	81 (35.4)	21 (20.6)		
• ACA	11 (4.8)	1 (1.0)		
• MCA	33 (14.4)	4 (3.9)		
• ICA	18 (7.9)	6 (5.9)		
• IC-PcoA	57 (24.9)	29 (28.4)		
• IC-AchA	11 (4.8)	0 (0.0)		
• IC-SHA	6 (2.6)	5 (4.9)		
Posterior circulation	18 (7.9)	36 (35.3)		
• BA	6 (2.6)	18 (17.6)		
• PCA	3 (1.3)	4 (3.9)		
• SCA	1 (0.4)	1 (1.0)		
• AICA	0 (0.0)	1 (1.0)		
• PICA	3 (1.3)	4 (3.9)		
• VA	5 (2.2)	7 (6.9)		
Size (mm); median [IQR]	5.00 [3.3]	5.80 [3.5]	0.281	0.864
Hydrocephalus; n (%)	81 (35.5)	37 (36.3)	0.025	0.875
Timing to intervention (days); median [IQR]	2 [3]	4 [5]	0.466	0.009*

WFNS=world federation of neurosurgical societies; MFS=modified Fisher scale; AcoA=anterior communicating artery; ACA=anterior cerebral artery; MCA=middle cerebral artery; ICA=internal carotid artery; PcoA=posterior communicating artery; AchA=anterior choroidal artery; SHA=superior hypophyseal artery; BA=basilar artery; PCA=posterior cerebral artery; SCA=superior cerebellar artery; AICA=anterior inferior cerebellar artery; PICA=posterior inferior cerebellar artery; VA=vertebral artery; SD=standard deviation; IQR=interquartile range

\* Statistical significance

was not statistically significant ( $p=0.057$ ). In both groups, in patients with good clinical conditions, 189 (84.4%) showed favorable outcomes, while in patients with poor WFNS grade only had 34 (31.8%) favorable outcomes at one year.

**Table 2.** Primary outcome (favorable outcome: mRS 0 to 2) at 6 and 12 months. Cruded and adjusted analysis (adjusted for treatment modalities, age, WFNS grading, sex, timing to intervention, aneurysms size, hydrocephalus and location)

Predictor	Favorable outcome (mRS 0 to 2) at 6 months				Favorable outcome (mRS 0 to 2) at 12 months			
	Crude		Adjusted		Crude		Adjusted	
	OR (95% CI)	p-value	OR (95% CI)	p-value	OR (95% CI)	p-value	OR (95% CI)	p-value
Coiling	1.22 (0.68 to 2.20)	0.504	0.89 (0.45 to 1.78)	0.745	1.69 (0.89 to 3.22)	0.111	2.33 (0.98 to 5.57)	0.057
Age (years)	1.05 (1.02 to 1.07)	<0.001*	1.04 (1.01 to 1.06)	0.003*	1.04 (1.02 to 1.07)	<0.001*	1.04 (1.02 to 1.07)	0.001*
Male	0.97 (0.56 to 1.65)	0.896	0.77 (0.40 to 1.49)	0.443	1.22 (0.69 to 2.16)	0.488		
Timing (days)	0.95 (0.89 to 1.02)	0.143	0.97 (0.89 to 1.06)	0.496	0.93 (0.86 to 1.00)	0.056	0.92 (0.84 to 1.01)	0.085
WFNS	2.65 (2.12 to 3.31)	<0.001*	2.61 (2.06 to 3.33)	<0.001*	2.53 (2.03 to 3.17)	<0.001*	2.25 (1.74 to 2.90)	<0.001*
Hydrocephalus	0.21 (0.12 to 0.36)	<0.001*	0.69 (0.36 to 1.31)	0.253	0.20 (0.12 to 0.34)	<0.001*	0.64 (0.32 to 1.28)	0.209
Anterior circulation	1.66 (0.81 to 3.41)	0.169	0.95 (0.41 to 2.18)	0.905	1.76 (0.85 to 3.65)	0.130	2.30 (0.83 to 6.33)	0.109
Size (mm)	1.05 (0.98 to 1.12)	0.156	1.08 (0.99 to 1.18)	0.067	1.03 (0.97 to 1.10)	0.36		

WFNS=world federation of neurosurgical societies; mRS=modified Rankin scale; OR=odds ratio; CI=confidence interval

\* Statistical significance

**Table 3.** Secondary outcome (cerebral vasospasm, re-bleeding, shunt-dependent hydrocephalus)

	Clipping (n=229); n (%)	Coiling (n=102); n (%)	p-value	OR (95% CI)
Complete obliterated	223 (97.4)	94 (92.2)	0.039*	3.16 (1.07 to 9.37)
Recurrence	0 (0.0)	1 (0.01)	0.295	0.98 (0.96 to 1.01)
Symptomatic vasospasm	90 (39.3)	26 (25.5)	0.031*	1.81 (1.07 to 3.05)
Rebleeding	1 (0.4)	2 (2.0)	0.23	0.67 (0.11 to 4.03)
Re-treatment	4 (1.8)	8 (7.8)	0.01*	4.79 (1.41 to 16.28)
Shunt dependency	52 (22.7)	23 (22.6)	0.886	0.96 (0.55 to 1.70)

OR=odds ratio; CI=confidence interval

\* Statistical significance

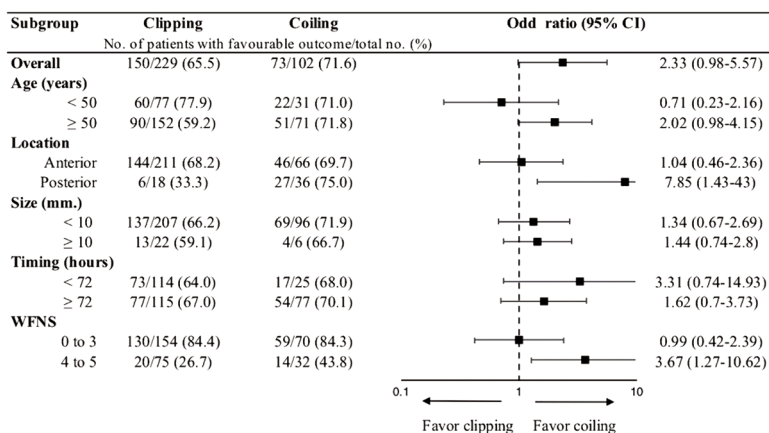
### Subgroup analysis

Among 107 patients with poor-grade SAH, 75 underwent surgical clipping and 32 received endovascular coiling embolization. At 1-year, favorable outcomes were achieved by 20 (26.7%) from the clipping group, compared to 14 (43.8%) from the coiling group. Multivariate analysis showed that favorable outcome was notably associated with coiling group ( $p=0.017$ , OR 3.67, 95% CI 1.27 to 10.62).

For 54 patients with posterior circulation aneurysm, 18 patients underwent surgical clipping and 36 patients received endovascular coiling embolization. At one year, 33 (61.1%) of these patients saw favorable outcomes with six (33.3%) from the clipping group, and 27 (75%) from the coiling group. Again, multivariate analysis associated favorable outcome with coiling group ( $p=0.005$ , OR 6.00, 95% CI 1.74 to 20.67). Results showed that coiling embolization significantly achieved favorable outcome for posterior circulation aneurysms ( $p=0.018$ , OR 7.85, 95% CI 1.43 to 43.0) after adjusted for potential confounding factors, which were age and WFNS (Figure 2).

### Secondary outcome

The coiling group had seen a higher rate of re-treatment ( $p=0.01$ ). One patient with posterior inferior cerebellar artery (PICA) aneurysm, which at first was obliterated totally by coiling, experienced a recurrence and had undergone surgical clipping for a second treatment. Rate of re-bleeding was not found to be significant between the groups ( $p=0.23$ ). Cases diagnosed with symptomatic cerebral vasospasm were 90 (39.3%) from the clipping group and 26 (25.5%) from the coiling group ( $p=0.031$ ). From the present study data, predictors for symptomatic cerebral vasospasm were surgical clipping ( $p=0.019$ , OR 2.22, 95% CI 1.14 to 4.33), and higher WFNS grade ( $p<0.001$ , OR 1.88, 95% CI 1.47 to 2.39) after adjusted for treatment, age, WFNS grade, MFS, placement of ventriculostomy, aneurysm location, and presence of acute hydrocephalus in multivariate analysis. Post-operative infarction, which could be caused by severe cerebral vasospasm and branch occlusion during the aneurysm occlusion procedure, was found in 36 (15.7%) cases from the clipping group, and eight (7.8%) cases



**Figure 2.** Subgroup analysis of favorable primary outcome (mRS 0 to 2) using multivariate analysis stratified by age, aneurysm location, aneurysm size, timing to intervention, and WFNS grade.

**Table 4.** Modified Rankin scale at 6 and 12 months in surgical clipping and endovascular coiling groups

Follow-up time	Treatment	Favorable outcome (mRS 0 to 2); n (%)	Poor outcome (mRS 3 to 6); n (%)
6 months	Clipping	138 (60.3)	91 (39.7)
	Coiling	62 (60.8)	40 (39.2)
12 months	Clipping	150 (65.5)	79 (34.5)
	Coiling	73 (71.6)	29 (28.4)

mRS=modified Rankin scale

**Table 5.** Complications

	Clipping (n=229); n (%)	Coiling (n=102); n (%)	p-value
Ischemic infarct	36 (15.7)	8 (7.8)	0.027*
Branches occlusion	20 (8.7)	3 (2.9)	0.012*
Mortality rate	34 (14.8)	16 (15.7)	0.87
Seizure	5 (2.2)	2 (2.0)	0.76

\* Statistical significance

from the coiling group ( $p=0.027$ ), as shown in Table 4.

There were patients who required permanent CSF diversion from post-subarachnoid hemorrhage hydrocephalus with 52 (22.7%) from the clipping group and 23 (22.6%) from the coiling group. The difference between the two groups was not significant ( $p=0.89$ ). For shunt-dependent hydrocephalus, the predictors were a presence of acute hydrocephalus ( $p<0.001$ , OR 19.10, 95% CI 5.77 to 63.23) after adjusted for treatment, age, WFNS, MFS, presence of acute hydrocephalus, placement of ventriculostomy, and aneurysm location in multivariate analysis (Table 5).

## Discussion

Data from the previously published Cochrane review consisted of three Randomize Control trial (RCTs). They showed the benefits from endovascular coiling over surgical clipping. However, the results were influenced by the largest RCT, the International subarachnoid aneurysm trial (ISAT)<sup>(5)</sup>. ISAT was criticized in its selection criteria with a large number of excluded patients, and a high cross-over rate. Additionally, over 90% were in good clinical conditions and were located in anterior circulation<sup>(1)</sup>. A meta-analysis was made, consisting of four RCTs and 23 observational studies. Data from the RCTs, which were influenced by the ISAT showed that coiling yielded better outcome at one year. Meanwhile, data from observational studies showed no benefit of coiling over clipping<sup>(6)</sup>. A more recent meta-analysis, consisting of four RCTs, still showed similar results as the previous RCTs<sup>(7)</sup>. Nevertheless, long-term data showed similar clinical outcome between the two modalities at 10 years follow-up, with durability and rate of re-treatment favoring surgical clipping<sup>(1)</sup>.

Overall, the majority of the authors' cohort (67.4%) found favorable outcome. There was no significant difference of clinical outcome between surgical clipping and endovascular coiling at 1-year follow-up. Results on treatment outcome were similar to long-term results from large trials, like BRAT and ISAT studies, despite a higher percentage of poor grade patients such as 32.3% in the authors' cohort compared to 19.3% and 12% in BRAT and ISAT, respectively. Favorable outcome was recognized in 189 (84.4%) patients with good pre-operative grade, in contrast to only 34 (31.8%) patients with poor grade SAH. Notably, favorable outcome appeared to



be increased with time, to 60% for both modalities at six months but trends toward coiling at 12 months.

### Poor-grade aneurysmal subarachnoid hemorrhage

Treatment modalities are still a controversial subject in specific patient populations, especially for poor pre-operative grade patients, where poor outcome appeared to be at 60% to 70%<sup>(8,9)</sup>. In a meta-analysis by Zhao et al comparing clipping and coiling treatments for poor-grade SAH, they found similar outcomes among both treatments, despite a higher mortality rate in coiling group<sup>(10)</sup>. They also found that early treatment within 48 hours after the onset associated with better neurological outcome.

For Poor WFNS grade SAH patients, despite selection bias based on aneurysm locations between the clipping and the coiling group, multiple logistic regression analysis still showed significant favorable outcome after adjusting for another potential confounder. The decision for treatment was with regards to the presence of large intracerebral hematoma or signs of brain herniation. The authors found that endovascular coiling was associated with more favorable outcome compared to surgical clipping. The explanation could be that surgical clipping was preferred in patients with increase intracranial pressure from large intracerebral hematoma, which had simultaneous clot evacuation. Nonetheless, patient with the so called “pseudo-poor grade SAH” where WFNS grade is improved after initial resuscitation, should not be overlooked since these could be the main confounders. As described by Ota et al, patients with signs of increased intracranial pressure such as obliteration of CSF cisterns, had poor outcome after surgical clipping<sup>(11)</sup>. Though, even in such conditions as reported by Hwang et al, coiling embolization followed by decompression may achieve better outcome than clipping with simultaneous decompression<sup>(12)</sup>. Hence, in poor grade patients without significant mass effect, the brain is susceptible to injury and may favor coil embolization as a less invasive treatment.

### Posterior circulation aneurysms

Posterior circulation aneurysms are more challenging, due to a complex microsurgical anatomy placed in difficult-to-reach area and close to the brainstem. It demands high surgical techniques with high possibility of rupture. Hence, coiling tends to benefit posterior circulation aneurysms with SAH more than clipping, even though coiling is associated with higher rate of re-treatment and lower

degree of aneurysm obliteration<sup>(1,5,13)</sup>. BRAT results showed better outcome with coiling embolization at one year follow-up, but not at three years, which the outcome was similar among treatment groups. However, long-term follow-up still showed benefits of coiling embolization over surgical clipping for posterior circulation aneurysm specifically<sup>(1,3)</sup>. Posterior circulation appeared to be confounding the relationship between treatment and outcome after adjusting for potential confounders, in which coiling showed more favorable. Recent meta-analysis also showed benefits of coiling for posterior circulation, in terms of less permanent neurological deficit, and still higher rate of re-intervention<sup>(13)</sup>. However, studies on specific aneurysm location should be made regarding difference anatomical consideration and relevant perforators.

### Age

Previously published data concerning age and outcome ruptured cerebral, aneurysm proposed that age more than 60 years old is a risk for poor outcome<sup>(14)</sup>. The Barrow ruptured aneurysm trial also showed that predictors for poor outcome included patients age more than 50 years old<sup>(2)</sup>. Brinjikji et al studied the effect of age on the outcome of unruptured cerebral aneurysm, and found relation of poor outcome to mortality rate and patients with age more than 50 years old, who underwent surgical clipping rather than coiling<sup>(15)</sup>. Despite finding a non-significant result in the authors’ subgroup analysis, comparing two modalities in patients with age more than 50 years, there was a tendency towards better outcome in the coiling group ( $p=0.07$ , OR 2.02, 95% CI 0.98 to 4.15).

### Secondary outcome

Cerebral vasospasm is one of the most important and devastating complications that could lead to poor outcome after SAH. Previous studies thought that occurrence of cerebral vasospasm was more related to surgical clipping than coiling embolization, due to the manipulation of brain and vasculature<sup>(16-19)</sup>. Although studies reported vasospasm as less common in surgical clipping than coiling due to aggressive clot removal or cisternal irrigation<sup>(20,21)</sup>. Two other studies also showed no difference in rate of cerebral vasospasm and outcome between clipping and coiling method<sup>(22,23)</sup>. In the present study, rates of symptomatic vasospasm were 39.8% in clipping and 26.7% in coiling group, similar to previous data at 17% to 40% varying among studies<sup>(17,18,24)</sup>. Meta-analysis by Oliveira et

al demonstrated no difference between techniques of aneurysm occlusion in cerebral vasospasm and consequences on outcome<sup>(25)</sup>. The incidence of vasospasm varied among studies was due to the different methods used to detect cerebral vasospasm. In the present study, clipping group showed higher rate of cerebral vasospasm and infarction, which might explain fewer rate of favorable outcome. Moreover, post-operative infarction could be caused by either severe vasospasm or branch occlusion during the surgery. Nonetheless, these results might be confounded by selection bias according to methods of diagnosis, which depended on clinical suggestions of vasospasm, such as neurological consequences or imaging diagnosis of cerebral ischemia, with cases that had increased blood flow velocity detected by trans-cranial doppler ultrasound or angiographic studies.

Hydrocephalus is a common complication after SAH, reported to be 20% to 30% from the recent studies<sup>(26-29)</sup>. Meta-analysis by Oliveira et al showed clipping as having lower incidence of hydrocephalus due to cisternal clot removal<sup>(30)</sup>. Risk factors were proposed by the recent meta-analysis to be predictors of shunt-dependent hydrocephalus, which were higher on the Fisher scale, presence of IVH, posterior circulation aneurysm, and being more than 60 years old<sup>(31)</sup>. The divergence in these results were from variations in treatment protocol among institutions and surgical techniques. The present study data demonstrated the rate of shunt-dependent hydrocephalus at 22.7% and 22.6% in clipping and coiling group, respectively. This was similar to previous reported data and found no significant difference among groups ( $p=0.89$ ).

Complete aneurysm obliteration was known to be better achieved with clipping, while coiling was thought to have higher rate of recurrence and re-treatment<sup>(1,4)</sup>. As demonstrated in the present study, where complete obliteration was found in 97.4% of clipping and 92.2% in coiling group, according to follow-up imaging at one year ( $p=0.04$ ). In addition, the results showed lower re-treatment rate of 1.8% in clipping, compared to 7.8% in coiling ( $p=0.01$ ). In terms of cross-over procedure, one patient in the clipping group had incomplete clipping and further received coiling for complete occlusion, while three patients in coiling group required surgical clipping for complete obliteration. In the coiling group, initial occlusion status was 81.4% for Raymond-Roy 1, 16.7% for Raymond-Roy 2, and 1.9% for Raymond-Roy 3. Results were similar to the previous

publications<sup>(32)</sup>. Only one case in the coiling group was found with aneurysm recurrence. Nevertheless, real recurrence rate after coiling will need to be collected after a longer follow-up period.

During coiling embolization, intraprocedural re-rupture was associated with significant periprocedural disability and death. Its incidence was higher in ruptured aneurysm (4.5%) according to the previous publications. From the present study, two (2%) patients suffered from intraprocedural aneurysm re-ruptured during coiling embolization. Both underwent emergency surgery for clipping. Unfortunately, the patients deceased despite successful obliteration. Three cases of post-operative re-bleeding were found. All were re-bleeding during hospitalization with one case in the clipping group and two cases in the coiling group. Nonetheless, there was no case of aneurysm re-bleeding during the 1-year follow-up in both treatment groups.

### Limitation

The limitations of the present study were its retrospective nature. In addition, being a single center study could lead to selection bias. However, the authors used a multivariate analysis to control confounding factors. The sample size was also relatively small, compared to other large trials conducted before, especially the number of patients that underwent surgical clipping for posterior circulation aneurysm. The treatment protocol was based on a single institution and were able to receive angiographic data for 85% of the patients at 1-year follow-up.

### Conclusion

The present study findings were from real-world practice conditions, in which patients were heterogeneous in nature. Endovascular coiling showed better outcome in patients with posterior circulation aneurysm, and patients with poor clinical grade with trend towards age of more than 50 years old. Surgical clipping was more favorable for durability and re-treatment. Therefore, the discussion of “clip versus coil” has ultimately become “when and who to clip or coil.” The best decision will be tailor-made, and the best result will be achieved in an institution where both surgical clipping and endovascular coiling are feasible.

### What is already known on this topic?

Regarding of growing evidence on “clip versus coil”, which superiority of coiling embolization on

long-term outcome is still debated, the posterior circulation aneurysms have more favorable outcome for those who received coiling embolization. Nevertheless, clipping yield better for durability and lower re-treatment rate.

### What this study adds?

This study demonstrated results of the “real-life” practice where the data were based on patient’s heterogeneity. The results are comparable to previously large trials. In addition, this study results support better outcome for coiling embolization in poor pre-operative grade patients, which data in literature is lacking and this is still a topic of controversy. This study is also the first where outcome of surgical clipping and coiling embolization are compared in Thailand.

### Conflicts of interest

All authors declare no conflicts of interest.

### References

1. Spetzler RF, McDougall CG, Zabramski JM, Albuquerque FC, Hills NK, Nakaji P, et al. Ten-year analysis of saccular aneurysms in the Barrow Ruptured Aneurysm Trial. *J Neurosurg* 2019;132:771-6.
2. McDougall CG, Spetzler RF, Zabramski JM, Partovi S, Hills NK, Nakaji P, et al. The Barrow Ruptured Aneurysm Trial. *J Neurosurg* 2012;116:135-44.
3. Spetzler RF, McDougall CG, Zabramski JM, Albuquerque FC, Hills NK, Russin JJ, et al. The Barrow Ruptured Aneurysm Trial: 6-year results. *J Neurosurg* 2015;123:609-17.
4. Molyneux AJ, Kerr RS, Yu LM, Clarke M, Sneade M, Yarnold JA, et al. International subarachnoid aneurysm trial (ISAT) of neurosurgical clipping versus endovascular coiling in 2143 patients with ruptured intracranial aneurysms: a randomised comparison of effects on survival, dependency, seizures, rebleeding, subgroups, and aneurysm occlusion. *Lancet* 2005;366:809-17.
5. Lindgren A, Vergouwen MD, van der Schaaf I, Algra A, Wermer M, Clarke MJ, et al. Endovascular coiling versus neurosurgical clipping for people with aneurysmal subarachnoid haemorrhage. *Cochrane Database Syst Rev* 2018;8:CD003085.
6. Li H, Pan R, Wang H, Rong X, Yin Z, Milgrom DP, et al. Clipping versus coiling for ruptured intracranial aneurysms: a systematic review and meta-analysis. *Stroke* 2013;44:29-37.
7. Shao B, Wang J, Chen Y, He X, Chen H, Peng Y, et al. Clipping versus coiling for ruptured intracranial aneurysms: a meta-analysis of randomized controlled trials. *World Neurosurg* 2019;127:e353-65.
8. Zhao B, Yang H, Zheng K, Li Z, Xiong Y, Tan X, et al. Preoperative and postoperative predictors of long-term outcome after endovascular treatment of poor-grade aneurysmal subarachnoid hemorrhage. *J Neurosurg* 2017;126:1764-71.
9. Liu J, Xiong Y, Zhong M, Yang Y, Guo X, Tan X, et al. Predicting long-term outcomes after poor-grade aneurysmal subarachnoid hemorrhage using decision tree modeling. *Neurosurgery* 2020;87:523-9.
10. Zhao B, Rabinstein A, Murad MH, Lanzino G, Panni P, Brinjikji W. Surgical and endovascular treatment of poor-grade aneurysmal subarachnoid hemorrhage: a systematic review and meta-analysis. *J Neurosurg Sci* 2017;61:403-15.
11. Ota N, Noda K, Hatano Y, Hashimoto A, Miyazaki T, Kondo T, et al. Preoperative predictors and prognosticators after microsurgical clipping of poor-grade subarachnoid hemorrhage: a retrospective study. *World Neurosurg* 2019;125:e582-92.
12. Hwang US, Shin HS, Lee SH, Koh JS. Decompressive surgery in patients with poor-grade aneurysmal subarachnoid hemorrhage: clipping with simultaneous decompression versus coil embolization followed by decompression. *J Cerebrovasc Endovasc Neurosurg* 2014;16:254-61.
13. Tsianaka E, Al-Shawish A, Potapov A, Fountas K, Spyrou M, Konovlov N. Clipping versus coiling in posterior circulation intracranial aneurysms: a meta-analysis. *Chin Neurosurg J* 2019;5:16.
14. Lanzino G, Kassell NF, Germanson TP, Kongable GL, Truskowski LL, Torner JC, et al. Age and outcome after aneurysmal subarachnoid hemorrhage: why do older patients fare worse? *J Neurosurg* 1996;85:410-8.
15. Brinjikji W, Rabinstein AA, Lanzino G, Kallmes DF, Cloft HJ. Effect of age on outcomes of treatment of unruptured cerebral aneurysms: a study of the National Inpatient Sample 2001-2008. *Stroke* 2011;42:1320-4.
16. Gross BA, Rosalind Lai PM, Frerichs KU, Du R. Treatment modality and vasospasm after aneurysmal subarachnoid hemorrhage. *World Neurosurg* 2014;82:e725-30.
17. Hohlrieder M, Spiegel M, Hinterhoelzl J, Engelhardt K, Pfausler B, Kampfl A, et al. Cerebral vasospasm and ischaemic infarction in clipped and coiled intracranial aneurysm patients. *Eur J Neurol* 2002;9:389-99.
18. Natarajan SK, Sekhar LN, Ghodke B, Britz GW, Bhagawati D, Temkin N. Outcomes of ruptured intracranial aneurysms treated by microsurgical clipping and endovascular coiling in a high-volume center. *AJNR Am J Neuroradiol* 2008;29:753-9.
19. Rabinstein AA, Pichelmann MA, Friedman JA, Piepgras DG, Nichols DA, McIver JI, et al. Symptomatic vasospasm and outcomes following aneurysmal subarachnoid hemorrhage: a comparison between surgical repair and endovascular coil occlusion. *J Neurosurg* 2003;98:319-25.
20. Gruber A, Ungersböck K, Reinprecht A, Czech T, Gross C, Bednar M, et al. Evaluation of cerebral vasospasm after early surgical and endovascular



- treatment of ruptured intracranial aneurysms. *Neurosurgery* 1998;42:258-67; discussion 67-8.
21. Ota N, Matsukawa H, Kamiyama H, Tsuboi T, Noda K, Hashimoto A, et al. Preventing cerebral vasospasm after aneurysmal subarachnoid hemorrhage with aggressive cisternal clot removal and nicardipine. *World Neurosurg* 2017;107:630-40.
  22. Alaraj A, Wallace A, Mander N, Aletich V, Charbel FT, Amin-Hanjani S. Outcome following symptomatic cerebral vasospasm on presentation in aneurysmal subarachnoid hemorrhage: coiling vs. clipping. *World Neurosurg* 2010;74:138-42.
  23. Hoh BL, Topcuoglu MA, Singhal AB, Pryor JC, Rabinov JD, Rordorf GA, et al. Effect of clipping, craniotomy, or intravascular coiling on cerebral vasospasm and patient outcome after aneurysmal subarachnoid hemorrhage. *Neurosurgery* 2004;55:779-86; discussion 86-9.
  24. Charpentier C, Audibert G, Guillemin F, Civit T, Ducrocq X, Bracard S, et al. Multivariate analysis of predictors of cerebral vasospasm occurrence after aneurysmal subarachnoid hemorrhage. *Stroke* 1999;30:1402-8.
  25. de Oliveira JG, Beck J, Ulrich C, Rathert J, Raabe A, Seifert V. Comparison between clipping and coiling on the incidence of cerebral vasospasm after aneurysmal subarachnoid hemorrhage: a systematic review and meta-analysis. *Neurosurg Rev* 2007;30:22-30; discussion 30-1.
  26. Chen S, Luo J, Reis C, Manaenko A, Zhang J. Hydrocephalus after subarachnoid hemorrhage: pathophysiology, diagnosis, and treatment. *Biomed Res Int* 2017;2017:8584753.
  27. Germanwala AV, Huang J, Tamargo RJ. Hydrocephalus after aneurysmal subarachnoid hemorrhage. *Neurosurg Clin N Am* 2010;21:263-70.
  28. Varelas P, Helms A, Sinson G, Spanaki M, Haccin-Bey L. Clipping or coiling of ruptured cerebral aneurysms and shunt-dependent hydrocephalus. *Neurocrit Care* 2006;4:223-8.
  29. Yamada S, Ishikawa M, Yamamoto K, Ino T, Kimura T, Kobayashi S. Aneurysm location and clipping versus coiling for development of secondary normal-pressure hydrocephalus after aneurysmal subarachnoid hemorrhage: Japanese Stroke DataBank. *J Neurosurg* 2015;123:1555-61.
  30. de Oliveira JG, Beck J, Setzer M, Gerlach R, Vatter H, Seifert V, et al. Risk of shunt-dependent hydrocephalus after occlusion of ruptured intracranial aneurysms by surgical clipping or endovascular coiling: a single-institution series and meta-analysis. *Neurosurgery* 2007;61:924-33; discussion 33-4.
  31. Wilson CD, Safavi-Abbasi S, Sun H, Kalani MY, Zhao YD, Levitt MR, et al. Meta-analysis and systematic review of risk factors for shunt dependency after aneurysmal subarachnoid hemorrhage. *J Neurosurg* 2017;126:586-95.
  32. Mascitelli JR, Moyle H, Oermann EK, Polykarpou MF, Patel AA, Doshi AH, et al. An update to the Raymond-Roy Occlusion Classification of intracranial aneurysms treated with coil embolization. *J Neurointerv Surg* 2015;7:496-502.