

# The Outcomes of Superficial Parotidectomy with Intraoperative Facial Nerve Monitoring: Experience in Sawanpracharak Hospital 2020 to 2022

Sawitree Jirawatthanaanan, MD<sup>1</sup>

<sup>1</sup> Department of Otolaryngology, Sawanpracharak Hospital, Nakhon Sawan, Thailand

**Objective:** To determine the outcomes of patients undergone parotidectomy with or without facial nerve monitoring.

**Materials and Methods:** The present study was a retrospective study that included 35 patients underwent superficial parotidectomy with pathologic findings of benign parotid tumor. The patients were divided into two groups. Intraoperative facial nerve monitoring was performed in 15 patients and did not monitor in 20 patients. Data were compared between the surgical groups with intraoperative facial nerve monitoring and the groups without intraoperative facial nerve monitoring using the chi-square test and independent t-test.

**Results:** Patients who underwent parotidectomy between January 1, 2020 and December 31, 2022, whose pathologic findings were benign, a total of 35 cases were divided into 15 patients underwent surgery with intraoperative facial nerve monitoring and 20 patients underwent surgery without intraoperative facial nerve monitoring. There was no statistical difference in operation time and saliva leakage. However, there was a statistical difference in intraoperative blood loss, postoperative facial nerve weakness rate, and postoperative earlobe numbness.

**Conclusion:** The most common complication of parotidectomy is paralysis of the facial nerve. The present study showed that intraoperative facial nerve monitoring can reduce facial nerve paralysis, blood loss during surgery and postoperative earlobe numbness.

**Keywords:** Intraoperative facial nerve monitoring; Parotidectomy; Parotid tumor

Received 11 May 2023 | Revised 7 June 2023 | Accepted 9 June 2023

**J Med Assoc Thai 2023; 106(6): 595-600**

**Website:** <http://www.jmatonline.com>

The incidence of parotid salivary gland tumors in Thailand is approximately 1 to 3 cases per 100,000 population per year. According to the previous reports, Sawanpracharak Hospital<sup>(1)</sup> had an average of 11 cases per year, of which 83.6% were benign. The primary treatment is surgery. The most common postoperative complications are facial weakness which can occur in 37% to 54%<sup>(1-3)</sup> which causes suffering to the patients. The use of intraoperative nerve monitoring can reduce this complication<sup>(4)</sup>. Sawanpracharak Hospital has started intraoperative facial nerve monitoring due to neuromuscular monitoring equipment purchased in 2022. The present

study aimed to evaluate and compare the outcomes of patients undergoing parotidectomy with pathologic findings suggestive of benign parotid gland tumors using intraoperative facial nerve monitoring (study group) and non-instrumental group (control group). The present study had not been done before in Sawanpracharak Hospital.

## Materials and Methods

The present study was a retrospective, descriptive study conducted at Sawanpracharak Hospital between January 2020 and December 2022, and the samples included all patients underwent superficial parotidectomy and in whom pathology confirmed benign salivary gland tumors. The present study was approved by the Human Research Ethics Committee of Sawanpracharak Hospital (COA 40/2565). Data were collected by reviewing data from the inpatient medical records, outpatient medical records, surgical record forms, and postoperative pathology record forms with information on sex, age, symptoms, pathological findings after surgery, surgical method, time of surgery, amount of blood loss during surgery, and complications after surgery (Figure 1). Statistical

### Correspondence to:

Jirawatthanaanan S.

Sawanpracharak Hospital, 43 Attakawee Road, Pak Nam Pho Subdistrict, Mueang Nakhon Sawan District, Nakhon Sawan 60000, Thailand.

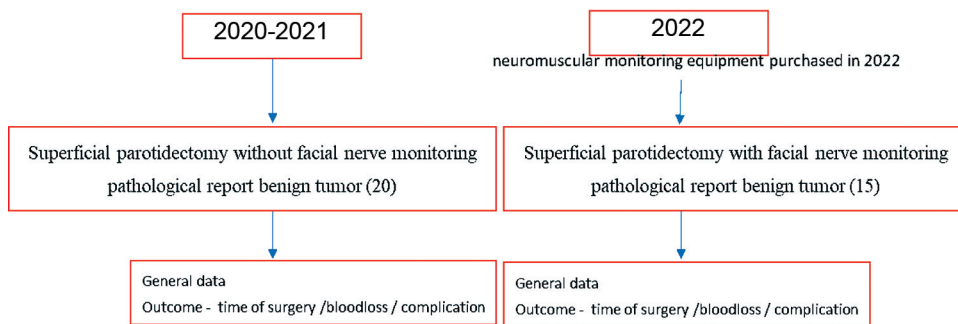
**Phone:** +66-97-9213257

**Email:** [poopaypoopay@gmail.com](mailto:poopaypoopay@gmail.com)

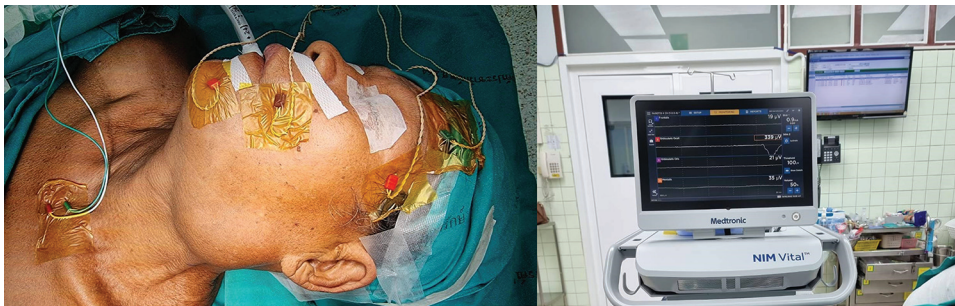
### How to cite this article:

Jirawatthanaanan S. The Outcomes of Superficial Parotidectomy with Intraoperative Facial Nerve Monitoring: Experience in Sawanpracharak Hospital 2020 to 2022. *J Med Assoc Thai* 2023;106:595-600.

DOI: 10.35755/jmedassocthai.2023.06.13861



**Figure 1.** Installation of group collection



**Figure 2.** Installation of intraoperative facial nerve monitoring during parotid tumor surgery.

analysis was performed using IBM SPSS Statistics for Windows, version 26.0 (IBM Corp., Armonk, NY, USA). Data were analyzed using descriptive statistics. The percentage for group data and mean with standard deviation for quantitative data. Data were compared between surgical groups with intraoperative facial nerve monitoring (Figure 2) and groups without intraoperative facial nerve monitoring using the chi-square test and independent t-test. A p-value of less than 0.05 was considered statistically significant.

### Statistical analysis

1. Quantitative data presented as mean and standard deviation (mean±SD), comparing two groups by independent t-test.

2. Group data were presented as numbers, percentages, and comparisons between the two groups by the chi-square test.

### Results

Patients underwent parotidectomy between January 1, 2020 and December 31, 2022, whose pathologic findings were benign. A total of 35 cases were divided into 15 patients underwent surgery with intraoperative facial nerve monitoring and 20 patients underwent surgery without intraoperative

facial nerve monitoring.

In the group with intraoperative facial nerve monitoring, there were 11 male and 4 female, with a mean age of 47.33 years. There were 12 cases below the earlobe and 3 cases of preauricular mass. There were 7 cases on the right side and 8 cases on the left side. The average operation time was 128.67 minutes. The average blood loss during surgery was 62 cc. The average size of the parotid tumor was 3.98 cm. No facial nerve paralysis was noted. Postoperative sialocele was noted in 1 case (Table 1).

In the group without the intraoperative monitoring of the facial nerve. There were 10 male and 10 female, mean age 53.35 years. There were 11 cases of mass below the earlobe and 9 cases of preauricular mass. There were 9 cases on the right side and 11 on the left. The average operation time was 137.25 minutes. The average blood loss during surgery was 129 cc. The average size of the parotid tumor was 4.08 cm. Paralysis of the facial nerve was noted in 10 cases. Numbness of the operated ear in 5 cases and postoperative saliva leakage (sialocele) in 1 case (Table 2).

### Discussion

In parotidectomy, surgeons have used anatomic knowledge, direct visualization, clinical experience,

**Table 1.** Information of patients using the intraoperative facial nerve monitoring (Treatment group)

| No. | Age (year) | Sex | Symptom | Site | Operation time (minutes) | Intraoperative blood loss (cc) | Tumor size (cm) | Pathological report | Postoperative complication |
|-----|------------|-----|---------|------|--------------------------|--------------------------------|-----------------|---------------------|----------------------------|
| 1   | 33         | M   | B       | R    | 80                       | 20                             | 3.5             | Pleomorphic adenoma | 0                          |
| 2   | 60         | F   | B       | L    | 110                      | 100                            | 2.2             | Pleomorphic adenoma | 0                          |
| 3   | 50         | F   | B       | L    | 115                      | 150                            | 0.8             | Pleomorphic adenoma | 0                          |
| 4   | 43         | M   | A       | R    | 135                      | 50                             | 4.6             | Warthin tumor       | Sialocele                  |
| 5   | 29         | M   | B       | L    | 160                      | 50                             | 4.0             | Pleomorphic adenoma | 0                          |
| 6   | 44         | F   | B       | R    | 115                      | 50                             | 4.5             | Pleomorphic adenoma | 0                          |
| 7   | 30         | F   | B       | L    | 135                      | 20                             | 3.0             | Pleomorphic adenoma | 0                          |
| 8   | 63         | M   | B       | L    | 170                      | 20                             | 4.0             | Warthin tumor       | 0                          |
| 9   | 59         | M   | A       | L    | 130                      | 100                            | 4.5             | Warthin tumor       | 0                          |
| 10  | 78         | M   | A       | L    | 165                      | 100                            | 5.5             | Myoepithelioma      | 0                          |
| 11  | 28         | M   | B       | R    | 130                      | 100                            | 4.5             | Pleomorphic adenoma | 0                          |
| 12  | 22         | M   | B       | R    | 140                      | 20                             | 5.4             | Pleomorphic adenoma | 0                          |
| 13  | 28         | M   | B       | R    | 180                      | 50                             | 5.0             | Pleomorphic adenoma | 0                          |
| 14  | 71         | M   | B       | R    | 85                       | 50                             | 3.7             | Warthin tumor       | 0                          |
| 15  | 72         | M   | B       | L    | 80                       | 50                             | 4.5             | Warthin tumor       | 0                          |

M=male; F=female; A=pre-auricular mass; B=mass below ear lobule; R=right; L=left

**Table 2.** Information of patients who did not use the intraoperative facial nerve monitoring (control group)

| No. | Age (year) | Sex | Symptom | Site | Operation time (minutes) | Intraoperative blood loss (cc) | Tumor size (cm) | Pathological report   | Postoperative complication |
|-----|------------|-----|---------|------|--------------------------|--------------------------------|-----------------|-----------------------|----------------------------|
| 1   | 80         | M   | B       | L    | 105                      | 20                             | 5.8             | Lymphoepithelial cyst | -                          |
| 2   | 62         | M   | B       | R    | 145                      | 150                            | 1.8             | Pleomorphic adenoma   | FN palsy, numbless         |
| 3   | 58         | M   | B       | R    | 90                       | 50                             | 4               | Warthin tumor         | Numbless                   |
| 4   | 66         | M   | A       | R    | 135                      | 50                             | 3               | Warthin tumor         | FN palsy, numbless         |
| 5   | 40         | F   | A       | L    | 115                      | 100                            | 2.2             | Pleomorphic adenoma   | Numbless                   |
| 6   | 74         | F   | B       | R    | 165                      | 100                            | 4               | Lymphoepithelial cyst | FN palsy                   |
| 7   | 58         | F   | A       | R    | 175                      | 100                            | 2.7             | Pleomorphic adenoma   | -                          |
| 8   | 31         | M   | B       | R    | 175                      | 100                            | 4.5             | Pleomorphic adenoma   | FN palsy                   |
| 9   | 46         | M   | A       | L    | 130                      | 200                            | 4.5             | Warthin tumor         | FN palsy, numbless         |
| 10  | 43         | F   | B       | R    | 215                      | 250                            | 6.5             | Warthin tumor         | FN palsy                   |
| 11  | 65         | M   | B       | L    | 90                       | 50                             | 5.5             | Warthin tumor         | FN palsy                   |
| 12  | 20         | F   | B       | R    | 165                      | 100                            | 7               | Lymphoepithelial cyst | -                          |
| 13  | 52         | M   | A       | L    | 110                      | 250                            | 4               | Warthin tumor         | -                          |
| 14  | 53         | F   | B       | L    | 180                      | 200                            | 3               | Lymphoepithelial cyst | FN palsy                   |
| 15  | 65         | M   | A       | R    | 100                      | 100                            | 3.5             | Basal cell adenoma    | -                          |
| 16  | 52         | M   | A       | L    | 110                      | 250                            | 4               | Warthin tumor         | -                          |
| 17  | 21         | F   | A       | L    | 285                      | 400                            | 3.7             | Pleomorphic adenoma   | FN palsy                   |
| 18  | 86         | F   | B       | L    | 115                      | 50                             | 4.5             | Lymphoepithelial cyst | -                          |
| 19  | 26         | F   | A       | L    | 110                      | 50                             | 3               | Pleomorphic adenoma   | FN palsy                   |
| 20  | 69         | F   | B       | L    | 30                       | 10                             | 4.5             | Pleomorphic adenoma   | Sialocele                  |

M=male; F=female; A=pre auricular mass; B=mass below ear lobule; R=right; L=left; FN=facial nerve

and electrical nerve stimulation to identify and preserve the facial nerves during surgery<sup>(5)</sup>. The objective of facial nerve monitoring during parotidectomy is to better identify and preserve the facial nerve. Monitoring provides real time to reduce

trauma to the facial nerve.

All patients underwent parotid gland surgery and in whom pathology confirmed benign salivary gland tumors were studied. Between January 2020 and December 2022, a total of 35 patients were

**Table 3.** Comparison of general data between groups

|                          | Treatment (n=15)<br>Intraoperative facial nerve monitoring group | Control (n=20)<br>No intraoperative facial nerve monitor group | p-value |
|--------------------------|--|--|---------|
| Age (year); mean±SD      | 47.33±18.75  | 53.35±18.84  | 0.356   |
| Sex; n (%)               |  |  | 0.163   |
| Female                   | 4 (26.7)   | 10 (50.0)  |         |
| Male                     | 11 (73.3)  | 10 (50.0)  |         |
| Tumor size (cm); mean±SD | 3.98±1.24  | 4.08±1.35  | 0.815   |
| Symptom; n (%)           |  |  | 0.123   |
| Pre auricular mass       | 3 (20.0)   | 9 (45.0)   |         |
| Mass below ear lobule    | 12 (80.0)  | 11 (55.0)  |         |
| Site; n (%)              |  |  | 0.922   |
| Left                     | 8 (53.3)   | 11 (55.0)  |         |
| Right                    | 7 (46.7)   | 9 (45.0)   |         |

SD=standard deviation

Independent t-test and chi-square test

**Table 4.** Comparison of outcome between groups

|   | Treatment (n=15)<br>Intraoperative facial nerve monitoring group | Control (n=20)<br>No intraoperative facial nerve monitor group | p-value |
|---|--|--|---------|
| Operation time (minutes); mean±SD       | 128.67±31.87   | 137.25±54.2  | 0.589   |
| Intraoperative blood loss (cc); mean±SD | 62±39.13   | 129±100.05   | 0.011*  |
| Facial nerve injury; n (%)              | 0 (0.0)  | 10 (50.0)  | 0.001*  |
| Earlobe numbness; n (%)                 | 0 (0.0)  | 5 (25.0)   | 0.037*  |
| Salivary leakage; n (%)                 | 1 (6.7)  | 1 (5.0)  | 0.834   |

SD=standard deviation

Independent t-test and chi-square test, \* p-value less than 0.05 is considered statistically significant

found, representing an average of approximately 11 to 12 cases per year. The proportion of males was closed to that of females. The left side tumors were closed to right side tumors. Most patients came to the doctor with a preauricular mass and a mass below the earlobe. The main symptoms of the patients visited the physician were similar to those in the previous studies<sup>(1,3)</sup>. The most common benign parotid tumors were pleomorphic adenomas, followed by Warthin's tumors, as reported in the previous studies<sup>(1-3,6)</sup>. The mean age of the group with intraoperative facial nerve monitoring was 47.33±18.75 years and the control group was 53.35±18.84 years. There was no statistically significant difference between the groups, p=0.356. From the present study, benign parotid tumors were more common in middle-aged and elderly, as in the previous studies. The mean tumor size of patients in the group with intraoperative facial nerve monitoring was 3.98±1.24 cm. In the other group, it was 4.08±1.35 cm. There was no statistically significant difference between the groups, p=0.815. From the present study, the two groups of

patients did not differ in the distribution of baseline data such as age, sex, tumor size, symptom, and site of tumor (Table 3).

In comparison, the average operation time in the group with intraoperative facial nerve monitoring was 128.67±31.87 minutes, whereas in the control group, it was 137.25±54.2 minutes. When comparing the data between the groups, there was no statistically significant difference, p=0.589 (Table 4). Although Wolf et al.<sup>(7)</sup> reported shorter operative times in patients underwent parotidectomy with facial nerve monitoring, the present study mean operative time did not differ between the two groups. It should depend on the surgeons' experience to find the main trunk of the facial nerve. Monitoring may or may not prove significant in terms of surgical time.

The group's estimated intraoperative blood loss (EBL) with intraoperative facial nerve monitoring was 62±39.13 cc. In the other group, it was 129±100.05 cc, when comparing the data between the groups, the estimated blood loss was higher in the group that did not use intraoperative facial

nerve monitoring, statistically significant with a  $p=0.011$  (Table 4). Accurate nerve localization may result in less injury to surrounding tissues and less intraoperative blood loss.

In facial nerve injury, there was a difference in the ratio between the two groups. In the group with intraoperative facial nerve monitoring, postoperative nerve injury was not prevalent. In the groups without intraoperative facial nerve monitoring, the prevalence of postoperative nerve injury was 50%. When comparing between groups, there was a statistically significant difference,  $p=0.001$  (Table 4). The group that used intraoperative facial nerve monitoring had fewer postoperative nerve injuries than the other group, as in the previous study<sup>(4,8,9)</sup>. During facial nerve monitoring, electromyography (EMG) activity of 4 muscles innervated by the facial nerve (frontalis muscle, orbicularis oculi muscle, orbicularis oris muscle, and mentalis muscle) were recorded during surgery. The use of intraoperative facial nerve monitoring may help surgeons during parotid gland surgery by better identifying the main trunk of the facial nerve and any small distal branches with minimal nerve trauma during surgery, as the audible warning encourages surgeons to be more careful during dissection.

Numbness of the earlobe after surgery, there was a difference in the ratio between the two groups. No prevalence of postoperative numbness was noted in the group with intraoperative facial nerve monitoring. The other group, the prevalence of earlobe numbness was 25%. When comparing the two groups, there was a statistically significant difference,  $p=0.037$  (Table 4). The great auricular nerve, which supplies sensation in the earlobe, sometimes needs to be removed to reach the parotid gland, resulting in numbness in the earlobe. Some authors recommend preservation of the posterior branches of the greater auricular nerve to achieve faster and more complete recovery of sensory function<sup>(10)</sup>. Most patients with intraoperative facial nerve monitoring underwent surgery in 2022, and the groups of patients without intraoperative facial nerve monitoring underwent surgery in 2020 to 2021. This is due to the surgeons in 2022 had more experience preserving the branch of the great auricular nerve. The statistical significance of the present study might be due to the surgical technique.

Saliva leakage after surgery was 6.7% in the group with intraoperative facial nerve monitoring and 5% in the other group, there was no statistically significant difference,  $p=0.834$  (Table 4). This

problem results from saliva leakage from the remaining salivary gland tissue collects under the flap or drains from the wound<sup>(11)</sup>. Herbert and Morton suggested that using surgical could increase the risk of postoperative sialocele formation<sup>(12)</sup>.

## Conclusion

The most common complication of parotidectomy is paralysis of the facial nerve. The present study showed that intraoperative facial nerve monitoring can reduce facial nerve paralysis, blood loss during surgery and postoperative earlobe numbness.

## Limitation

Due to the number of cases per year is relatively small and the outbreak of Covid 19 infection; non-emergency surgeries were postponed, causing the number of patients decreased. Moreover, the present research found limitations in data collection which was the retrospective data.

## What is already known on this topic?

Like the previous study, the most common postoperative complications are facial weakness which causes suffering to the patients. The use of intraoperative nerve monitoring can reduce this complication.

## What this study adds?

This study shows intraoperative facial nerve monitoring can reduce the postoperative facial nerve paralysis, blood loss during surgery and postoperative earlobe numbness. These could assist the surgeon during operation and the patient was satisfied with the results of surgery.

## Funding disclosure

The present study received a grant from Sawanpracharak Medical Education Center.

## Conflicts of interest

The authors declare no conflict of interest.

## References

1. Jirawatthanaanan S. Parotid tumor in Sawanpracharak Hospital 2007-2019. *Sawanpracharak Med J* 2019;16: 103-10.
2. Uengarporn M, Chintrakarn C. Parotidectomy for parotid masses in Ramathibodi Hospital [Internet]. Bangkok: Mahidol University, Ramathibodi Hospital; 2009 [cited 2022 Feb 9]. Available from: <https://www.rama.mahidol.ac.th/ent/sites/default/files/public/>

- images/banner/pdf/Mathee.pdf.
3. Jongsatitpaiboon J, Peeravut S. Parotidectomy for parotid masses in Songklanagarind Hospital: 17-year analysis. *Songklanagarind Med J* 2004;22:185-93.
  4. Terrell JE, Kileny PR, Yian C, Esclamado RM, Bradford CR, Pillsbury MS, et al. Clinical outcome of continuous facial nerve monitoring during primary parotidectomy. *Arch Otolaryngol Head Neck Surg* 1997;123:1081-7.
  5. Sood AJ, Houlton JJ, Nguyen SA, Gillespie MB. Facial nerve monitoring during parotidectomy: a systematic review and meta-analysis. *Otolaryngol Head Neck Surg* 2015;152:631-7.
  6. Califano J, Eisele DW. Benign salivary gland neoplasms. *Otolaryngol Clin North Am* 1999;32:861-73.
  7. Wolf SR, Schneider W, Suchy B, Eichhorn B. Intraoperative facial nerve monitoring in parotid surgery. *HNO* 1995;43:294-8.
  8. López M, Quer M, León X, Orús C, Recher K, Vergés J. Usefulness of facial nerve monitoring during parotidectomy. *Acta Otorrinolaringol Esp* 2001;52:418-21.
  9. Chiesa-Estomba CM, Larruscain-Sarasola E, Lechien JR, Mouawad F, Calvo-Henriquez C, Diom ES, et al. Facial nerve monitoring during parotid gland surgery: a systematic review and meta-analysis. *Eur Arch Otorhinolaryngol* 2021;278:933-43.
  10. Hui Y, Wong DS, Wong LY, Ho WK, Wei WI. A prospective controlled double-blind trial of great auricular nerve preservation at parotidectomy. *Am J Surg* 2003;185:574-9.
  11. Zedan A, Rezk K, Elshenawy AA, Nabih O, Atta H. Complications of parotid surgery-10 years' experience. *J Cancer Ther* 2020;11:306-23.
  12. Herbert HA, Morton RP. Sialocele after parotid surgery: assessing the risk factors. *Otolaryngol Head Neck Surg* 2012;147:489-92.