

Chest Radiograph Findings Monitoring with Time Course of COVID-19 Pediatrics Patients

Niracha Atanavanich, MD¹, Sutiporn Khampunnip, MD¹, Suvicha Khampunnip, MD¹

¹ Department of Radiology, Phramongkutklao Hospital, Bangkok, Thailand

Objective: To study image findings in covid pediatric patients, both in the first diagnosis images and follow-up images to see disease progression over time.

Materials and Methods: The present research was conducted in all pediatric patients aged 0 to 18 years diagnosed as Covid-19 infection and admitted at Phramongkutklao Hospital during the study period. Image findings were retrospectively reviewed by an experienced pediatric radiologist and Brixia score was given. The maximum severity score and timing to reach this score were calculated and recorded in all patients.

Results: During the study period, 428 films were collected from 170 patients. Most patients were male with a mean age of 9.89 years. Most common presenting symptom was fever. One-fourth of the studied patients had underlying illnesses. Most patients were symptomatic patients with 156 of 170 (91.8%). The first X-ray showed abnormalities in 64.7% of symptomatic group and 42.9% in asymptomatic group. Common lobes of lungs involved were middle and lower lobes, which was slightly right-side predominate. Mean Brixia score was 2.79 (0 to 12) and 2.97 (0 to 14) in asymptomatic and symptomatic patients, respectively, which was not statistically significant. Time to reach maximum severity score was phase 1 (0 to 4 days) for symptomatic patients and phase 2 (5 to 8 days) for asymptomatic ones. For patients with normal first X-ray, abnormalities could be detected on later films, mostly in phase 1 and 2.

Conclusion: Screening X-ray at the first diagnosis had high rates of abnormality detection regardless of symptom. For patients with normal first X-ray, abnormalities could be detected on later films, mostly in phase 1 and 2. Therefore, even with the fear of unnecessary exposure to radiation in children, X-ray should be performed at the first diagnosis regardless of symptom. Appropriate timing to follow-up X-ray was phase 2, at day 5 to 8 of disease.

Keywords: Covid 19 X-ray; Covid in children; X-ray of pediatric covid

Received 3 October 2022 | Revised 27 April 2023 | Accepted 2 May 2023

J Med Assoc Thai 2023;106(6):572-7

Website: <http://www.jmatonline.com>

Covid-19 infection has been spread world-wide and has been a leading health problem of all age groups in many countries since 2019. The World Health Organization (WHO) considered this infection as pandemic since 2019⁽¹⁻⁴⁾. For infected patients, symptoms can vary from fever, cough, pneumonia, severe respiratory failure, or even death⁽⁵⁻⁷⁾. In Thailand, there have been 4,605,609 cumulative cases diagnosed as Covid-19 infection since the outbreak (data at August 7, 2022 from CCSA)⁽⁸⁾. The Republic of China reported a fatality rate of 3.17 and

transmission rate of 2.2 for each patient⁽⁹⁾. Among these, 1.7% were pediatric patients.

In children, Covid-19 infection was different from adults. Clinical manifestation was less severe and sometimes asymptomatic.

Chest X-ray is helpful in diagnosis, monitoring after treatment, and provide prognosis of the disease⁽¹⁰⁾. Chest X-ray guideline has been established in some countries, to help clinician decide when to order X-ray for diagnosis and to follow-up the treatment. However, these guidelines were usually made based on the pattern of disease progression in adult patients. However, in children, while patterns of disease progression may be different from adults, the appropriate guideline in chest X-ray has never been investigated. The present study was performed to evaluate X-ray finding in pediatric covid patients to see common findings and appropriate timing for X-ray.

Correspondence to:

Khampunnip S.

Department of Radiology, Phramongkutklao Hospital, 315 Ratchawithi Road, Tung Phayathai, Ratchathewi, Bangkok 10400, Thailand.

Phone: +66-2-3547600

Email: canjang@hotmail.com

How to cite this article:

Atanavanich N, Khampunnip S, Khampunnip S. Chest Radiograph Findings Monitoring with Time Course of COVID-19 Pediatrics Patients. *J Med Assoc Thai* 2023;106:572-7.

DOI: 10.35755/jmedassocthai.2023.06.13854

Materials and Methods Patients

The present research was conducted as an

observational retrospective study at Phramongkutklao Hospital between December 2021 and April 2022. All pediatric patients aged 0 to 18 years who had real-time polymerase chain reaction (RT-PCR)-proven Covid-19 infection and admitted at the hospital were included. The patients were excluded if the images were not available for review or RT-PCR was not performed to confirm diagnosis.

Sample size estimation

Sample size was calculated based on the study of Yasin and Gouda⁽¹¹⁾, that maximum severity score (MSS) was reached at day 0 to 4 at 38%, using an equation: $n = Z_{\alpha/2}^2 p(1-p) / d^2$. While n was sample size, p was 0.38, d was 10% error and $Z_{\alpha/2}$ were standard values from table Z at $\alpha=0.05$ (1.96), then number of patients studied should be 91.

Evaluation

After the study protocol obtained approval for research by the Ethics Committee at Institutional Review Board Royal Thai Army Medical Department (IRBRTA 1643/2021), permission to assess the medical records were given by the director of the hospital. Personal data were collected including age, gender, date of diagnosis, presenting symptoms, presence of underlying illness, and image findings.

Images were retrospectively reviewed by a pediatric radiologist with more than 10 years-experience. Image findings were scored using Brixia scoring system⁽¹²⁾. The Brixia scoring system uses different terminology to score disease severity in each zone with a score of 0 representing normal lung parenchyma, a score of 1 indicating interstitial changes only, a score of 2 indicating non-confluent airspace consolidation +/- interstitial changes, and a score of 3 indicating confluent consolidation +/- interstitial changes. Score was given at 0 to 3 for each lung zones (Figure 1), which were defined as upper zones (above the inferior border of the aortic arch, zone A was on right and zone D was on left), mid zones (below the inferior border of the aortic arch to above the inferior margin of the right inferior pulmonary vein, zone B was on right and zone E was on left), and lower zones (below the inferior wall of the right inferior pulmonary vein, zone C was on right and zone F was on left). Then, the total score was calculated in each patient using the summation of all zones ranging from 0 to 18.

The maximum score of each patient was recorded as MSS and time to reach the MSS was also recorded. The timing to reach the MSS was further divided

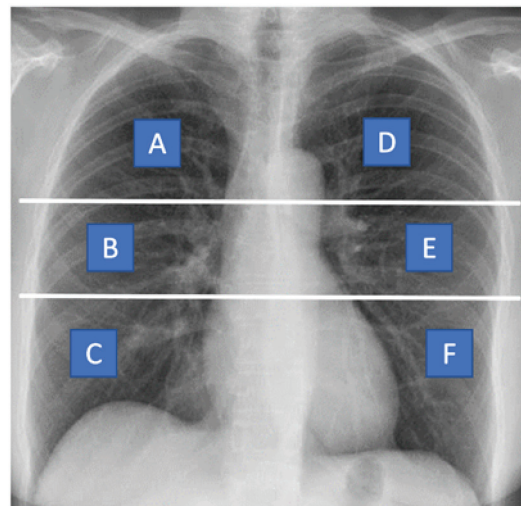


Figure 1. Division of both lungs into 6 zones on frontal chest radiograph. Upper line is drawn at the level of inferior wall of the aortic arch and lower line is drawn at the level of the inferior wall of the right inferior pulmonary vein. A and D: upper zones, B and E: middle zones, C and F: lower zones.

into four phases. Phase 1 was day 0 to 4 of disease, phase 2 was day 5 to 8, phase 3 was day 9 to 13, and phase 4 was day 14 or later. Day 0 of disease was defined as the first day of having symptoms in symptomatic patients or first day of positive RT-PCR in asymptomatic ones.

Statistical analysis

All statistical analysis was conducted by Stata, version 12 (StataCorp LP, College Station, TX, USA). General data analyses used descriptive statistics with percentage, mean, and standard deviation. The independent t-test or Mann-Whitney U test was used to compare the continuous date at the level of confidence of 95%.

Ethical consideration

All patients' personal data was protected by using a code instead of their names or hospital number (HN) throughout data collection. No intervention was done to the patients.

Results

During the present study period, 170 patients (428 films) were diagnosed as Covid-19 infection at Phramongkutklao Hospital. No patient met an exclusion criterion, so, all were included in analyses. Among these patients, 156 (91.8%) were symptomatic and 14 (8.2%) were asymptomatic patients. Most of the patients were male at 60% with

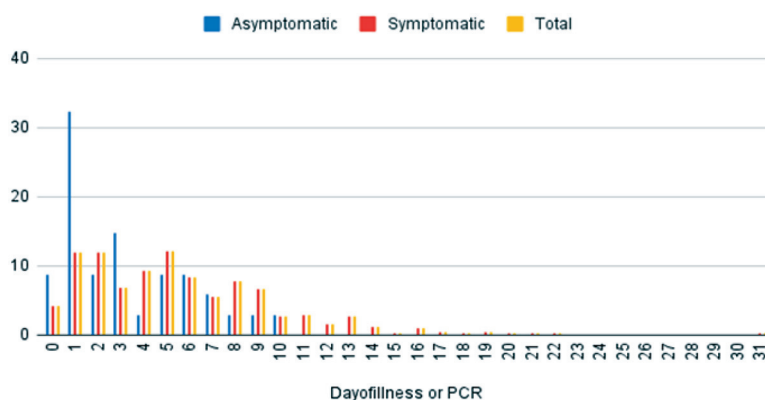


Figure 2. Trend of CXR investigation in each day of disease.

a mean age of 9.89 years. Most common presenting symptoms were fever (75.3%), cough (47.6%), and rhinorrhea (28.2%). Forty-four patients (25.9%) had an underlying illness. Characteristics of the patients are shown in Table 1.

Timing of X-ray

Among these 170 patients, 428 films were taken. In the 14 asymptomatic patients, all chest X-rays (34 films) were performed within the first ten days of disease. In the 156 symptomatic patients, 394 films were taken during the day 0 to 31 of disease. Distribution of timing of X-ray investigation is shown in Figure 2.

Among 14 asymptomatic patients, eight patients (57.1%) had normal initial X-ray and the remaining six patients (42.9%) had positive findings on initial films. In these initial-negative finding cases, one case had abnormal finding in the follow-up film at phase 1. For symptomatic patients, 114 out of 156 (73.1%), had positive findings, which was mostly found on initial X-ray films in 101 out of 114 patients (88.6%). For the 13 remaining symptomatic patients who had positive findings only on follow-up films, the positive phase was phase 1 in four patients, phase 2 in seven patients, and phase 3 in two patients which accounted for 3.5%, 6.1%, and 1.8%, respectively. Timing of positive findings are summarized in Figure 3 and 4.

Image findings

Regarding the X-ray finding, abnormalities could be found in any lobes. Abnormalities were predominantly found at both middle and lower lungs regardless of the symptoms. Both upper lungs were rarely involved by the disease. Distribution of the lobes involved are shown in Figure 5.

Most common abnormality found on chest X-ray

Table 1. Patient characteristics

Characteristics	Total (170 patients)
Sex; n (%)	
Male	102 (60.0)
Female	68 (40.0)
Age (years)	Median 10 (min 0, max 18)
Presenting symptom(s); n (%)	
Fever	128 (75.3)
Cough	81 (47.6)
Rhinorrhea	48 (28.2)
Anosmia	2 (1.2)
Sorethroat	26 (15.3)
Dyspnea	8 (4.7)
Headache	7 (4.1)
Vomit	12 (7.1)
Diarrhea	14 (8.2)
Rash	1 (0.6)
Seizure	5 (2.9)
Length of stay (days)	3 to 226 (mean 10.6, median 9)
Underlying disease; n (%)	44 (25.9)
Hematologic disease	7
Malignancy	1 (lymphoma)
Cardiovascular disease	3
Respiratory disease	3
Neurological disorder	8
Psychological disease	2
Renal disease	4
Multiple/systemic disease	2 (1 VACTERL, 1 LOWE)
Gastrointestinal disease	2
Immunologic disease	9 (allergic rhinitis)
Others	2

was interstitial opacity (score=1) which was seen in 79% of patients. Combined interstitial and alveolar opacity were also seen, which 8.5% was interstitial predominance and 7.9% was alveolar predominance.

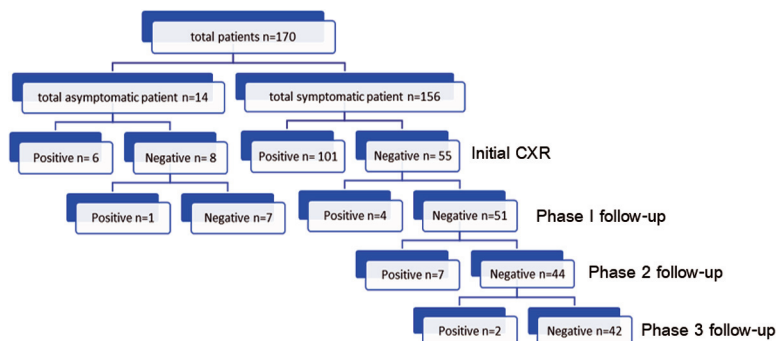


Figure 3. Timing of positive findings.

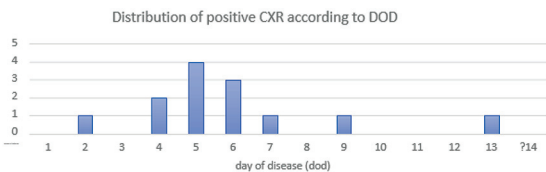


Figure 4. Timing of positive findings in symptomatic patients who had normal initial X-rays.

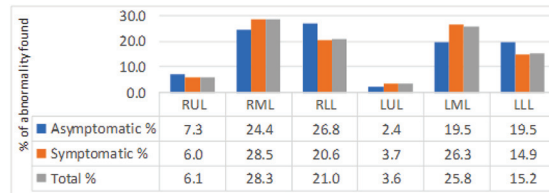


Figure 5. Distribution of the lobes involved.

Table 2. Pattern of radiographic abnormality

Score	Asymptomatic patients (%)	Symptomatic patients (%)	All patients (%)
1: Interstitial opacity	70.7	80.0	79.0
2: Interstitial & alveolar opacities with interstitial predominance	14.6	13.0	8.5
3: Interstitial & alveolar opacities with alveolar predominance	14.6	7.5	7.9

Table 3. Maximum severity score

Group	Score	p-value
Symptom		0.583**
Asymptomatic (n=14)	0 to 12 (median 1.5, min 0, max 12)	
Symptomatic (n=156)	0 to 14 (median 2.0, min 0, max 14)	
Finding		<0.001*
Negative finding (n=42)	0 (median 0, min 0, max 0)	
Positive on initial films (n=101)	1 to 14 (median 4, min 1, max 14)	
Positive on follow-up films (n=13)	1 to 5 (median 2, min 1, max 5)	
Asymptomatic (n=14)	2 to 12 (median 3.56, min 2, max 12)	

* Mann-Whitney U test, ** Kruskal Wallis test

These findings rate was similar in symptomatic and asymptomatic patients, as shown in Table 2.

When the abnormalities were assessed using severity score and compared using the presence or absence of symptoms, symptomatic patients had a mean score of 2.97 (range 0 to 14, median 2) and asymptomatic patients had a mean score of 2.79 (range 0 to 12, median 1.5), which was not significantly different ($p=0.583$). When the score

was analyzed according to the finding, it was found that the patients with positive findings on initial films tended to have higher MSS than the patients with positive finding on follow-up films, which was 1 to 14 (mean 4.25), and 1 to 5 (mean 2.62), respectively. MSS as shown in Table 3.

An example finding of asymptomatic patient is shown in Figure 6. It was a 17-year-old boy with underlying disease of acute lymphoblastic leukemia

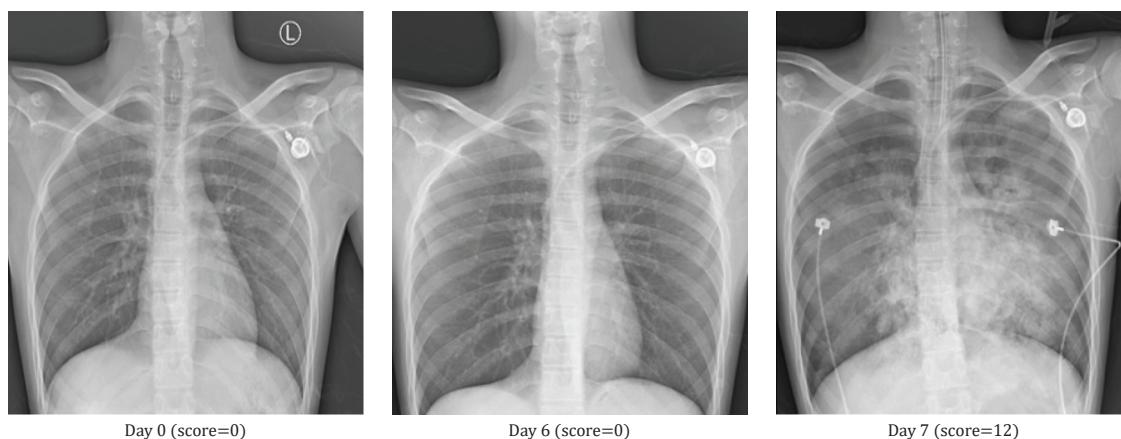


Figure 6. Asymptomatic patient who had positive finding on a follow-up film.

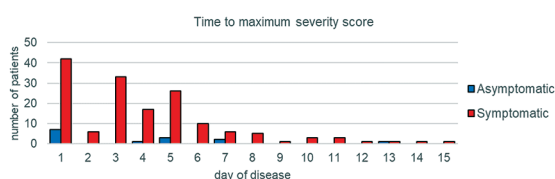


Figure 7. Time to maximal severity score.

(ALL) admitted for bone marrow biopsy but PCR for covid was positive. Chest X-rays were normal on day 0 and day 6 but he developed respiratory failure on day 7 and chest X-ray was abnormal.

For the timing that MSS was found, in symptomatic patients, it was mostly seen in phase 1 in 77 out of 114 patients (67.5%). The others were in phase 2 in 29 patients (25.4%), and phase 3 in eight patients (7.0%). No abnormality was further detected in phase 4. In asymptomatic patients, MSS was also seen mostly in phase 1 in six out of seven patients (85.7%), and the other one in phase 2 in one patient (14.3%). No abnormality was further detected in phase 3 or 4. Time to maximal severity score is summarized in Figure 7.

Discussion

It was known that chest X-ray is helpful in Covid-19 patients, both in diagnosis, follow-up, and providing the prognosis. However, in pediatric patients, unnecessary radiation exposure has always been a major concern. Justification for using X-ray should be made in every pediatric patient. In Thailand, there has been no established guideline for appropriate X-ray use in children with Covid-19 infection. The present study was performed to evaluate findings on chest X-ray of admitted pediatric patients.

Most common presenting symptoms were fever (75.3%), cough (47.6%), and rhinorrhea (28.2%). These presenting symptoms were similar to what was reported on the previous study by Chen et al.⁽¹³⁾, which stated that the most common presenting symptoms in children were cough (42.9%) and rhinorrhea (14.3%). In Chen's study, fever could be found in children but at a lower rate than adults (around 42% in children and 83% in adult). In the systematic review of Hoang et al. in 2020⁽¹⁴⁾, the children usually have milder symptoms with the most common presenting symptoms of fever (59.1%), cough (55.9%), and rhinorrhea (20%). In the present study, fever (75.3%) of the patients could be seen at a higher rate than the other studies, maybe because of the in-patient setting with large number of patients with underlying illness, which was about one-fourth of all patients.

In adults, the most frequent findings are airspace opacities, whether described as consolidation or, less commonly, ground glass opacity (GGO)^(15,16). The distribution is most often bilateral, peripheral, and lower zone predominant^(15,16). In the present study, distribution is most often middle-to-lower lung zones with slightly right lung predominant and interstitial opacity were more common.

When the Brixia scoring was calculated, MSS was found to be significantly higher in symptomatic patients having abnormalities found since the first X-ray than in symptomatic patients who just had abnormalities on follow-up films (median MSS 4.25 and 2.62, $p < 0.001$). Time to MSS was within phase 1 in symptomatic patients and phase 2 for asymptomatic patients. Apart from these, it was found that at the first diagnosis, abnormality could be seen in as high as 42.9% in asymptomatic patients and 64.7% of symptomatic patients. In the patients that first

X-rays were normal, their follow-up films usually showed abnormality during phase 1 and 2. Thus, regardless of symptom, all admitted patients should be sent for chest X-ray and follow-up X-ray should be done not later than during the phase 2 period.

In the previous study by Yasin and Gouda⁽¹¹⁾, it was reported that both maximum RALE score and time to MSS had a correlation with mortality rate.

Conclusion

Screening X-ray at the first diagnosis had high rates of abnormality detection regardless of symptom. For patients with normal first X-ray, abnormalities could be detected on later films, mostly in phase 1 and 2. Therefore, even with the fear of unnecessary exposure to radiation in children, X-ray should be performed at the first diagnosis regardless of symptom. Appropriate timing to follow-up X-ray was phase 2, at day 5 to 8 of disease. Chest X-ray abnormalities were found mostly on middle and lower lobes and most common findings were interstitial infiltration.

What is already known on this topic?

Covid-19 infection in pediatric patients had different courses of the disease compared with adult patients, so X-ray finding and timing for appropriate X-ray investigation may be different.

What this study adds?

Chest X-ray is necessary in every Covid-19 pediatric patient. Screening chest X-ray should be done regardless of symptom and follow-up X-ray should be done not later than phase 2 period. Finding of chest X-ray of pediatric patients were different to adults.

Conflicts of interest

The authors declare no conflict of interest.

References

1. Sun P, Lu X, Xu C, Sun W, Pan B. Understanding of COVID-19 based on current evidence. *J Med Virol* 2020;92:548-51.
2. Oterino Serrano C, Alonso E, Andrés M, Buitrago NM, Pérez Vígara A, Parrón Pajares M, et al. Pediatric chest x-ray in covid-19 infection. *Eur J Radiol* 2020;131:109236.
3. Li W, Cui H, Li K, Fang Y, Li S. Chest computed tomography in children with COVID-19 respiratory infection. *Pediatr Radiol* 2020;50:796-9.
4. Rostad BS, Shah JH, Rostad CA, Jaggi P, Richer EJ, Linam LE, et al. Chest radiograph features of multisystem inflammatory syndrome in children (MIS-C) compared to pediatric COVID-19. *Pediatr Radiol* 2021;51:231-8.
5. Huang C, Wang Y, Li X, Ren L, Zhao J, Hu Y, et al. Clinical features of patients infected with 2019 novel coronavirus in Wuhan, China. *Lancet* 2020;395:497-506.
6. Zhu N, Zhang D, Wang W, Li X, Yang B, Song J, et al. A novel coronavirus from patients with pneumonia in China, 2019. *N Engl J Med* 2020;382:727-33.
7. Guan WJ, Ni ZY, Hu Y, Liang WH, Ou CQ, He JX, et al. Clinical characteristics of coronavirus disease 2019 in China. *N Engl J Med* 2020;382:1708-20.
8. Department of Disease Control Ministry of Public Health, Thailand. Daily COVID-19 Report Thailand Information [Internet]. 2022 [updated 2022 Aug 7; cited 2022 Aug 7]. Available from: <https://ddc.moph.go.th/covid19-dashboard/>.
9. National Health Commission of the People's Republic of China. National Health Commission's briefing on the pneumonia epidemic situation (in Chinese) [Internet]. 2020 [cited 2022 Aug 7]. Available from: <http://www.nhc.gov.cn/yjb/s7860/202001/9614b05a8cac4ffabac10c4502fe517c.shtml>.
10. Foust AM, Phillips GS, Chu WC, Daltro P, Das KM, Garcia-Peña P, et al. International expert consensus statement on chest imaging in pediatric COVID-19 patient management: Imaging findings, imaging study reporting, and imaging study recommendations. *Radiol Cardiothorac Imaging* 2020;2:e200214.
11. Yasin R, Gouda W. Chest X-ray findings monitoring COVID-19 disease course and severity. *Egypt J Radiol Nucl Med.* 2020;51:193.
12. Warren MA, Zhao Z, Koyama T, Bastarache JA, Shaver CM, Semler MW, et al. Severity scoring of lung oedema on the chest radiograph is associated with clinical outcomes in ARDS. *Thorax* 2018;73:840-6.
13. Chen A, Huang JX, Liao Y, Liu Z, Chen D, Yang C, et al. Differences in clinical and imaging presentation of pediatric patients with COVID-19 in comparison with adults. *Radiol Cardiothorac Imaging* 2020;2:e200117.
14. Hoang A, Chorath K, Moreira A, Evans M, Burmeister-Morton F, Burmeister F, et al. COVID-19 in 7780 pediatric patients: A systematic review. *EclinicalMedicine* 2020;24:100433.
15. Rodrigues JCL, Hare SS, Edey A, Devaraj A, Jacob J, Johnstone A, et al. An update on COVID-19 for the radiologist - A British Society of Thoracic Imaging statement. *Clin Radiol* 2020;75:323-5.
16. Wong HYF, Lam HYS, Fong AH, Leung ST, Chin TW, Lo CSY, et al. Frequency and distribution of chest radiographic findings in patients positive for COVID-19. *Radiology* 2020;296:E72-8.