

Open-Assisted Laparoscopic Radical Cystectomy Using an Ileal Neobladder with Intracorporeal Urethra-Neobladder Anastomosis: Technique and Early Experiences

Premsant Sangkum MD*,
Suthep Patcharatrakul MD*, Wisoot Khongchareonsombat MD*

* Division of Urology, Department of Surgery, Ramathibodi Hospital, Mahidol University, Bangkok, Thailand

Objective: Laparoscopic radical cystectomy is now widely performed in cases of muscle-invasive bladder cancer. The present study experience with laparoscopic radical cystectomy using an ileal neobladder in which urethra-neobladder anastomosis was successfully performed intracorporeally.

Material and Method: Between March and November 2009, five patients underwent laparoscopic radical cystectomy using an ileal neobladder with urethra-neobladder anastomosis. Preoperative characteristics, operative data, and results were analyzed.

Results: The operation was successful for all patients. The mean operative time was 6 hours and 30 minutes. Mean estimated blood loss was 560 ml. No intraoperative complications occurred. Mean hospital stay was 19.6 days. Mean Foley catheter indwelled time was 18 days. Return of bowel function took 4.8 days. Mean time to remove silastic drain was 14.2 days. After Foley catheter removal, all patients spontaneously voided without difficulty.

Conclusion: Laparoscopic radical cystectomy of ileal neobladders using intracorporeal urethra-neobladder anastomosis is technically feasible. This technique takes advantage of laparoscopic surgery, good visualization, additional stitches, and more secure anastomosis.

Keywords: Radical cystectomy, Intracorporeal urethra-neobladder anastomosis, Laparoscopic

J Med Assoc Thai 2013; 96 (5): 564-8

Full text. e-Journal: <http://jmat.mat.or.th>

Radical cystectomy is the standard treatment for muscle-invasive bladder cancer⁽¹⁾. Laparoscopic radical cystectomy and orthotopic ileal neobladder were performed completely intracorporeally in 2002⁽²⁾. The benefits of laparoscopic radical cystectomy included decrease in blood loss and blood transfusion rate, postoperative pain, and length of hospital stay. It also resulted in quicker recovery and lower morbidity, compared with open surgery⁽³⁻⁶⁾. However, especially when bowel surgery was done intracorporeally, operative times were longer^(3,5), and surgical complications were usually due to urinary diversion⁽⁷⁾. Some authors have reported doing laparoscopic radical cystectomy and urinary diversion completely extracorporeally via minilaparotomic incision⁽⁴⁻⁶⁾. The benefits of this technique are shorter

operative time and decreased bowel complications, while the benefits of laparoscopic surgery are retained^(7,8). The authors performed laparoscopic radical cystectomy using an ileal neobladder in which urethra-neobladder anastomosis was successfully done intracorporeally. The authors report here some early results for this procedure.

Material and Method

Five patients underwent laparoscopic radical cystectomy using an ileal neobladder using intracorporeal urethra-neobladder anastomosis, at Ramathibodi Hospital, between March and November 2009. Inclusion criteria were muscle-invasive bladder cancer or large urothelial carcinomas that could not be completely removed by transurethral resection. No patients had contraindications for laparoscopic surgery. All operations were performed by one surgeon with extensive open and laparoscopic experience. Demographic data, previous medical history, perioperative data, postoperative data, and follow-up data were retrospectively collected.

Correspondence to:

Khongchareonsombat W, Division of Urology, Department of Surgery, Ramathibodi Hospital, Mahidol University 270, Rama VI Road, toong Phayathai, Ratchathewi, Bangkok 10400, Thailand.
Phone: 0-2201-1315, Fax: 0-2201-1316
E-mail: Wisoot2002@hotmail.com

Techniques

Each patient underwent preoperative mechanical bowel preparation and received broad-spectrum intravenous prophylactic antibiotics. Under general anesthesia, patients were placed in supine, modified lithotomy abducted-thigh position. A nasogastric tube and Foley catheter were indwelled. An intermittent pneumatic compression stocking was applied to prevent deep vein thrombosis. Then the operating table was put in the Trendelenburg position.

A 12 mm Hudson trocar was placed supraumbilical using the Hassan technique, and the pneumoperitoneum was established with a 15 mmHg pressure limit. Two other 12 mm trocars were placed transperitoneally in each lower pararectus area, and two 5 mm trocars were placed in each lower abdominal area (Fig. 1). The laparoscopic radical cystectomy was started on the bladder posterolaterally. The peritoneum was incised and dissected along the plane of the vasa deferentia and seminal vesicles. Each vas deferens was clipped and cut. The plane between the bladder and rectum was entered. The Denonvilliers' fascia was incised to expose perirectal fat and entered to separate the plane between the prostate gland and rectum. Once freed, the bilateral vascular pedicles of the bladder and prostate were controlled with a Hem-o-lok clip and harmonic scalpel. Both ureters were meticulously dissected until reaching the bladder, and were clipped with Hem-o-lok clips. Both distal ends of the ureters were sent for pathological evaluation.

Anterior dissection started with urachal dissection along to the anterior Retzius space. The urachus was divided high near the umbilicus. The anterior bladder was dissected freely, extending laterally to both medial umbilical ligaments. The obliterated umbilical arteries were clipped. The endopelvic fascia and puboprostatic ligament were divided bilaterally. The dorsal vein complex was controlled in figure-eight fashion with a CT-1 polyglactin suture. Then the urethra was completely dissected, freed from surrounding tissues. The anterior urethra was partially incised. To prevent spillage of urine, a Hem-o-lok clip was applied at the prostatourethral junction when the Foley catheter was slowly pulled back. The urethra was transected. Cystoprostatectomy was completely done.

A small low-midline skin incision was created. The specimen was delivered en bloc using minilaparotomy incision. Then a bilateral extended pelvic lymphadenectomy was performed. The ileal neobladder (Studer) was constructed extracorporeally.

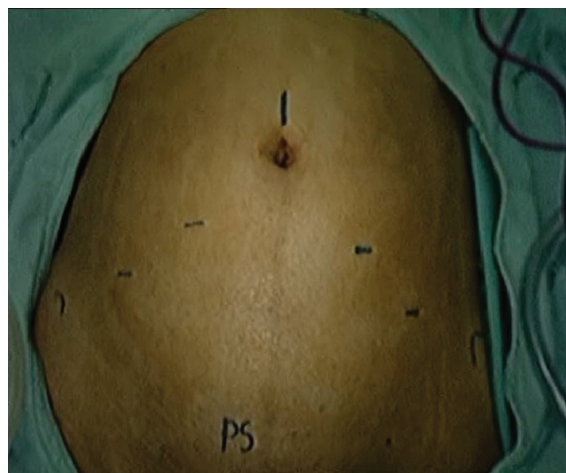


Fig. 1 Location of port insertion (PS, pubic symphysis).

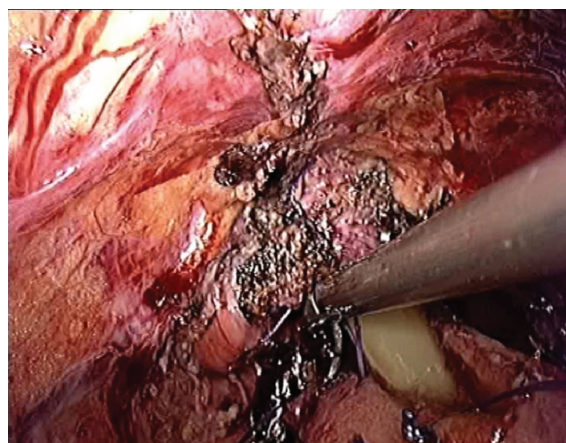


Fig. 2 A good laparoscopic view of the urethra-neobladder anastomosis.

Ureteroileal anastomosis was done using the Bricker technique. A feeding tube, No. 6 Fr., was used as an internal stent. A four-wing catheter was inserted in the neobladder pouch for suprapubic drainage of urine. The enteral opening of the neobladder pouch was tied with silk as a landmark before being dropped back into the abdominal cavity. The pneumoperitoneum was re-established. Enterourethral anastomosis was performed using a laparoscopic-free hand-suturing technique until the procedure was completed. The suturing technique used a continuously run 2/0 polyglactin suture. The Foley catheter was indwelled when the suturing procedure was near completion. Leakage was checked by laparoscopic viewing for watertight anastomosis. Then silastic drain, 5 mm, was placed in the pelvis. The pneumoperitoneum was released, and the abdominal wall was closed.

Postoperatively, patients received bladder irrigation via Foley and suprapubic catheters to release mucus after one week. A cystogram was obtained after two weeks, before removing the Foley catheter. Before being discharged home, all patients were taught clean intermittent catheterization for adequate bladder emptying. The suprapubic cystostomy was removed when patients came to their follow-ups to see whether they had no urinary tract infections or metabolic complications from the ileal neobladder.

Results

Between March and November 2009, five patients underwent laparoscopic radical cystectomy using an ileal neobladder with intracorporeal urethra-neobladder anastomosis. The demographic data are shown in Table 1. All patients were men with the mean age of 62.2 years (range: 45-78 years). Their average BMI was 22.4. Two patients had underlying disease: one with allergic rhinitis and the other with gout and adrenal insufficiency needing exogenous steroid replacement. Four patients had muscle-invasive bladder cancer, and one patient had large, high-grade non-muscle-invasive bladder cancer that could not be completely removed by transurethral resection.

An orthotopic ileal neobladder was successfully created in all patients; the operative and postoperative data are shown in Table 2. The mean total operative time was 390 minutes (360-420 min). The mean laparoscopic cystectomy time was 84 minutes (50-135 min). The mean hospital stay was

19.6 days (12-25 d). The mean Foley catheterization time was 28 days (11-28 d). One patient needed a new Foley catheter indwelled by cystoscopy due to its spontaneous dislodgement on postoperative day 9. One patient needed reoperative repair of his small bowel because of enteroenteral anastomosis leakage on postoperative day 7. No patient needed reoperative procedures because of enterourethral anastomosis leakage.

Discussion

Radical cystectomy is the standard treatment for muscle-invasive bladder cancer⁽¹⁾. Laparoscopic cystectomy was first reported by Parra et al in 1992⁽⁹⁾. In Thailand, laparoscopic radical cystectomy with ileal conduit diversion was first reported at Ramathibodi Hospital in 2005⁽¹⁰⁾. Laparoscopic cystoprostatectomy is now widely performed in many series. Laparoscopic radical cystectomy and orthotopic ileal neobladder were performed completely intracorporeally in 2002⁽²⁾. The recent data show oncological outcomes for this new procedure that are similar to outcomes for the open technique. It has the advantages of less blood loss and postoperative pain, and shorter recovery times and hospital stays⁽³⁻⁷⁾. Based on our literature search, this is the first report in Thailand of laparoscopic radical cystectomy using an ileal neobladder with intracorporeal urethral neobladder anastomosis.

The main concern about the laparoscopic approach is its longer operative time, higher rate of complications, and higher reoperative rate, especially when it involves intracorporeal urinary diversion⁽⁷⁾. Thus, the modern series use extracorporeal urinary diversion via a small laparotomic incision to lower both operative times and bowel complications, while retaining the benefits from laparoscopic surgery^(5,6). Even with a robotic approach, most urinary diversion still uses an extracorporeal technique⁽¹¹⁻¹³⁾. The authors therefore used extracorporeal urinary diversion via minilaparotomy incision to decrease both the operative time and complications from urinary diversion. The laparoscopic radical cystectomy technique has been previously discussed⁽¹⁰⁾. The authors' results, compared to international series, indicate shorter operative times (than those for the open technique) and nearly the same frequency of complications (as that for the laparoscopic-assisted technique)^(3,4). The mean laparoscopic cystectomy time was 84 minutes; most of the operative time was spent on ileal neobladder reconstruction. Blood loss was less when compared to older laparoscopic series and a little bit more

Table 1. Patient characteristics

	Mean	SD
Age (years)	62.2	15.3
Weight (kg)	59.7	13.4
BMI	22.4	2.9
ASA score	2.6	0.9

Table 2. Operative and postoperative data

	Mean	SD
Total operative time (min)	390.0	30.0
Cystectomy time (min)	84.0	31.9
Blood loss (milliliters)	560.0	391.2
Oral intake (day)	4.8	0.5
Foley catheter (day)	18.0	6.5
Drain (day)	14.2	4.1
Hospital stay (day)	19.6	5.2

when compared to modern series^(3,4). Bilateral pelvic lymphadenectomy was done via minilaparotomy incision, even though it could have been done using the laparoscopic technique, but the authors think the laparoscopic approach would have taken longer and would not have been much more beneficial. The authors found the drain removal time to be quite long because we waited for confirmation of no leakage, by cystogram, after two weeks. Without waiting for the cystogram, our patients could have removed the drain earlier, on postoperative day 6, given that no postoperative complications had occurred.

The authors used intracorporeal enterourethral anastomosis. The anastomosis was deep in the pelvis, which cannot be seen when using the open approach. This technique showed good visualization from the laparoscopic view. The authors were able to suture from the posterior of the urethra and neobladder with a continuous running suture until reaching the anterior site of the anastomosis. This is usually a weak point, because this stitch is located deep in the pelvis, so that the posterior region of the ileal pouch is hidden when using the open technique. In contrast, our technique allowed indwelling of the Foley catheter to be viewed directly for proper positioning, thereby allowing more stitching, and more secure anastomosis. The authors' results showed no cases of anastomosis leakage.

Recent robot-assisted laparoscopic radical cystectomy series showed similar short-term oncological outcomes when compared to the open technique, while retaining the benefits from a minimally invasive approach⁽¹¹⁻¹³⁾. Robot-assisted techniques make laparoscopic suturing easier because enterourethral anastomosis requires a high degree of laparoscopic skill. In the authors' opinion, the robotic approach is overly expensive; regardless, only a few medical centers in Thailand have the necessary robot technology available.

The one disadvantage of a minimally invasive technique is its longer operative time, including that for a robotic approach. There are novel techniques that try to decrease the operative time such as using staples for neobladder construction. There have been studies that successfully used non-absorbable titanium staples for neobladder construction, but data on the long-term outcomes is still needed^(14,15). There is a novel enterourethral anastomosis sutureless device that has been successfully used in swine. This device can reduce the suturing anastomosis time from 46 minutes to 6 minutes, which significantly decreases the time needed to complete the neobladder procedure⁽¹⁶⁾. This

device is appealing, but more data is still needed for its further development.

Conclusion

Laparoscopic radical cystectomy using an ileal neobladder with intracorporeal urethra-neobladder anastomosis is technically feasible. This technique takes advantage of laparoscopic surgery, good visualization, additional stitches, and more secure anastomosis. This technique still requires experienced laparoscopic surgeons, and robotic assistance will make it easier. The authors expect even better outcomes and greater acceptance of this technique with more experience and improved enterourethral anastomosis devices.

Potential conflicts of interest

None.

References

1. Dalbagni G, Genega E, Hashibe M, Zhang ZF, Russo P, Herr H, et al. Cystectomy for bladder cancer: a contemporary series. *J Urol* 2001; 165: 1111-6.
2. Gill IS, Kaouk JH, Meraney AM, Desai MM, Ulchaker JC, Klein EA, et al. Laparoscopic radical cystectomy and continent orthotopic ileal neobladder performed completely intracorporeally: the initial experience. *J Urol* 2002; 168: 13-8.
3. Basillote JB, Abdelshehid C, Ahlering TE, Shanberg AM. Laparoscopic assisted radical cystectomy with ileal neobladder: a comparison with the open approach. *J Urol* 2004; 172: 489-93.
4. Haber GP, Campbell SC, Colombo JR Jr, Fergany AF, Aron M, Kaouk J, et al. Perioperative outcomes with laparoscopic radical cystectomy: "pure laparoscopic" and "open-assisted laparoscopic" approaches. *Urology* 2007; 70: 910-5.
5. Guillotreau J, Game X, Mouzin M, Doumerc N, Mallet R, Sallusto F, et al. Radical cystectomy for bladder cancer: morbidity of laparoscopic versus open surgery. *J Urol* 2009; 181: 554-9.
6. Chade DC, Laudone VP, Bochner BH, Parra RO. Oncological outcomes after radical cystectomy for bladder cancer: open versus minimally invasive approaches. *J Urol* 2010; 183: 862-9.
7. Haber GP, Gill IS. Laparoscopic radical cystectomy for cancer: oncological outcomes at up to 5 years. *BJU Int* 2007; 100: 137-42.

8. Hemal AK, Kolla SB, Wadhwa P, Dogra PN, Gupta NP. Laparoscopic radical cystectomy and extracorporeal urinary diversion: a single center experience of 48 cases with three years of follow-up. *Urology* 2008; 71: 41-6.
9. Parra RO, Andrus CH, Jones JP, Boullier JA. Laparoscopic cystectomy: initial report on a new treatment for the retained bladder. *J Urol* 1992; 148: 1140-4.
10. Kijvikai K, Patcharatrakul S, Kongchareonsombat W, Dissaranan C. Laparoscopic radical cystectomy with ileal conduit diversion: the first case report in Thailand. *J Med Assoc Thai* 2005; 88: 1947-51.
11. Guru KA, Kim HL, Piacente PM, Mohler JL. Robot-assisted radical cystectomy and pelvic lymph node dissection: initial experience at Roswell Park Cancer Institute. *Urology* 2007; 69: 469-74.
12. Nix J, Smith A, Kurpad R, Nielsen ME, Wallen EM, Pruthi RS. Prospective randomized controlled trial of robotic versus open radical cystectomy for bladder cancer: perioperative and pathologic results. *Eur Urol* 2010; 57: 196-201.
13. Kasraeian A, Barret E, Cathelineau X, Rozet F, Galiano M, Sanchez-Salas R, et al. Robot-assisted laparoscopic cystoprostatectomy with extended pelvic lymphadenectomy, extracorporeal enterocystoplasty, and intracorporeal enterourethral anastomosis: initial Montsouris experience. *J Endourol* 2010; 24: 409-13.
14. Abreu SC, Araujo MB, Silveira RA, Regadas RP, Pinheiro DG, Messias FI, et al. Laparoscopic-assisted radical cystectomy with U-shaped orthotopic ileal neobladder constructed using nonabsorbable titanium staples. *Urology* 2006; 68: 193-7.
15. Hruby G, Weld KJ, Marruffo F, Collins S, Durak E, Mitchell R, et al. Comparison of novel tissue apposing device and standard anastomotic technique for vesicourethral anastomoses. *Urology* 2007; 70: 190-5.
16. Durak E, Hruby GW, Okhunov Z, Sprenkle P, Mirabile G, Marruffo F, et al. Complete ileal neobladder intracorporeal construction with standard sutured technique and novel technology. *J Urol* 2010; 183: 1227-31.

การผ่าตัดส่องกล้องร่วมกับแบบเปิดของมะเร็งกระเพาะปัสสาวะกับการสร้างกระเพาะปัสสาวะใหม่โดยใช้ลำไส้เล็ก ส่วนปลายและการเย็บกระเพาะปัสสาวะใหม่ต่อกับท่อปัสสาวะโดยการส่องกล้อง: เทคนิคและผลการรักษาเบื้องต้น

เปรมสันต์ สังข์คุ้ม, สุเทพ พัทธระกุล, วิสูตร คงเจริญสมบัติ

วัตถุประสงค์: รายงานประสบการณ์การผ่าตัด ตัดกระเพาะปัสสาวะโดยการส่องกล้องร่วมกับการผ่าตัดแบบเปิดเพื่อสร้างกระเพาะปัสสาวะใหม่โดยใช้ลำไส้เล็ก และการเย็บต่อท่อปัสสาวะและกระเพาะปัสสาวะใหม่ผ่านการส่องกล้องในผู้ป่วยมะเร็งกระเพาะปัสสาวะ **วัสดุและวิธีการ:** ระหว่างเดือนมีนาคม พ.ศ. 2552 ถึงเดือนพฤศจิกายน พ.ศ. 2552 ผู้ป่วยจำนวน 5 ราย ได้รับการผ่าตัด ตัดกระเพาะปัสสาวะโดยการส่องกล้องร่วมกับการผ่าตัดแบบเปิดเพื่อสร้างกระเพาะปัสสาวะใหม่โดยใช้ลำไส้เล็ก และการเย็บต่อท่อปัสสาวะและกระเพาะปัสสาวะใหม่ผ่านการส่องกล้อง ข้อมูลผู้ป่วยก่อนผ่าตัด ข้อมูลระหว่างการผ่าตัดและผลการรักษาได้ถูกนำมาศึกษา

ผลการศึกษา: สามารถทำการผ่าตัดสำเร็จในผู้ป่วยทุกราย ระยะเวลาในการผ่าตัดเฉลี่ยคือ 6 ชั่วโมง 30 นาที การเสียเลือดเฉลี่ย 560 มิลลิลิตร ไม่มีภาวะแทรกซ้อนระหว่างการผ่าตัด ระยะเวลาอนโรงพยาบาลเฉลี่ย 19.6 วัน ระยะเวลาในการใส่สายสวนปัสสาวะเฉลี่ย 18 วัน ระยะเวลาของการกลับมาทำงานของลำไส้ 4.8 วัน ระยะเวลาเฉลี่ยในการใส่สายระบาย 14.2 วัน หลังจากถอดสายสวนปัสสาวะ ผู้ป่วยทุกรายสามารถปัสสาวะเองได้โดยไม่ต้องตัด

สรุป: การผ่าตัด ตัดกระเพาะปัสสาวะโดยการส่องกล้องร่วมกับการผ่าตัดแบบเปิดเพื่อสร้างกระเพาะปัสสาวะใหม่โดยใช้ลำไส้เล็ก และการเย็บต่อท่อปัสสาวะและกระเพาะปัสสาวะใหม่ผ่านการส่องกล้องเป็นการรักษาที่สามารถทำได้ เทคนิคการผ่าตัดนี้มีข้อได้เปรียบจากการผ่าตัดแบบส่องกล้อง การมองเห็นที่ชัดมากขึ้น เย็บได้มากขึ้น และความแข็งแรงของรอยต่อมากขึ้น
