

Comparison of Early Clinical Outcomes between Intermittent Vascular Inflow Occlusion versus Intermittent Selective Hepatic Vascular Exclusion in Hepatic Resections for Cholangiocarcinoma Patients: A Prospective Randomized Controlled Trial Study

Tongsiri N, MD¹, Siripornadulsilp S, MD², Impool T, MD³

¹ Hepatobiliary and Pancreatic Surgery Unit, Department of Surgery, Sakon Nakhon Hospital, Sakon Nakhon, Thailand

² Hepatobiliary and Pancreatic Surgery Unit, Department of Surgery, Khon Kaen Hospital, Khon Kaen, Thailand

³ Trauma Unit, Department of Surgery, Khon Kaen Hospital, Khon Kaen, Thailand

Background: There were reported benefits of selective hepatic vascular exclusion (SHVE) in reducing intraoperative blood loss (IBL), intraoperative packed red cell (PRC) transfusion, and perioperative complications over intermittent Pringle maneuver (IPM) in hepatectomies. However, there was lack of data regarding the use of SHVE in comparison with IPM in hepatectomies for cholangiocarcinoma (CCA) patients.

Objective: To compare IBL, intraoperative PRC transfusion, total operative time (TOT), and perioperative complications between SHVE and IPM.

Materials and Methods: Between October 2018 and September 2019, forty eligible CCA patients participated in the study. They were randomly allocated to the SHVE group (n=20) or the IPM group (n=20). Data regarding patient demographics, tumor characteristics, and the objectives of the study were gathered and analyzed with intention-to-treat principle.

Results: The median IBL (range) 923.5 (101 to 4,979) versus 1,109 (413 to 5,305) ml; p=0.2, median intraoperative PRC transfusion (range) 112.5 (0 to 1,745) versus 296 (0 to 1,500) ml; p=0.22, and median TOT (range) 390 minute (220 to 915) versus 320 (240 to 930) minutes; p=0.55 between SHVE and IPM were not significantly different. There was no statistical difference in perioperative complications between SHVE and IPM.

Conclusion: Routine use of SHVE during hepatectomies in CCA patients showed no significant difference in outcomes regarding the objectives of the study.

Keywords: Selective hepatic vascular exclusion (SHVE), Hepatic vascular exclusion with preservation of caval flow (HVEPV), Hepatic resection, Cholangiocarcinoma, Intraoperative blood loss, Perioperative complications

Received 24 Jan 2020 | Revised 27 Apr 2020 | Accepted 28 Apr 2020

J Med Assoc Thai 2020;103(6): 521-8

Website: <http://www.jmatonline.com>

Correspondence to:

Tongsiri N.

Department of Surgery, Sakon Nakhon Hospital, Sakon Nakhon 47000, Thailand.

Phone: +66-42-176000, Fax: +66-42-176089

Email: nisitongsiri@gmail.com

How to cite this article:

Tongsiri N, Siripornadulsilp S, Impool T. Comparison of Early Clinical Outcomes between Intermittent Vascular Inflow Occlusion versus Intermittent Selective Hepatic Vascular Exclusion in Hepatic Resections for Cholangiocarcinoma Patients: A Prospective Randomized Controlled Trial Study. J Med Assoc Thai 2020;103:521-8. doi.org/10.35755/jmedassocthai.2020.06.11023

Controlling intraoperative blood loss (IBL) is a crucial step for hepatic resection, as a decrease in IBL has been associated with better outcomes of hepatectomy⁽¹⁻³⁾. Inflow vascular occlusion of hepatic pedicle during the transection of hepatic parenchyma has been used to control bleeding. There are several methods of inflow vascular occlusion, as well as total occlusion methods that include continuous Pringle maneuver (CPM) and intermittent Pringle maneuver (IPM)⁽²⁾, partial or selective occlusion of the part of the liver to be resected⁽⁴⁾, and segmental vascular occlusion. The latter method is achieved using a vascular balloon to occlude the segmental or subsegmental portal branch with unilateral clamping

of the associated lobar arterial branch^(5,6). In Sakon Nakhon Hospital (SKH) and Khon Kaen Hospital (KKH), IPM has been used for inflow vascular occlusion during parenchymal transection of the liver. IPM is not a complicated procedure, and most hepatic resections in these hospitals are cholangiocarcinoma (CCA) cases, requiring complex liver resections. IPM is the recommended inflow vascular occlusion method for patients undergoing complex liver resections that have expected clamping time exceeding 60 minutes⁽⁷⁾.

The drawback of the inflow vascular exclusion is an inability to prevent backflow bleeding from the hepatic vein⁽⁸⁾. Therefore, methods of inflow and outflow vascular occlusion such as total hepatic vascular exclusion (THVE)⁽⁹⁾ and selective hepatic vascular exclusion (SHVE)⁽¹⁰⁾, also known as hepatic vascular exclusion with preservation of caval flow (HVEPV)⁽⁸⁾, have been used to deal with bleeding from hepatic veins. THVE clamping of the hepatoduodenal ligament combined with clamping of the infra and suprahepatic inferior vena cava (IVC) can cause hemodynamic deterioration⁽⁸⁾. SHVE or HVEPV was shown to be as effective as THVE in the control of bleeding. Furthermore, it was well tolerated by the patients^(8,11). Therefore, THVE should be reserved for tumors invading the IVC⁽⁷⁾. According to the benefits and drawbacks of several vascular occlusion techniques during liver resection, IPM concomitant with occlusion of extraparenchymal major hepatic veins (SHVE or HVEPV) is likely to be the most appropriate vascular occlusion technique for controlling IBL during hepatic resections. However, SHVE and HVEPV were not familiar methods for the surgeons in comparison with IPM⁽¹²⁾. Moreover, there was a potential risk of massive bleeding due to rupture of hepatic veins as SHVE and HVEPV involve dissection of hepatic veins near the IVC⁽¹³⁾. Several studies reported the benefits of SHVE and HVEPV over IPM in controlling IBL, and lowering the need for blood transfusions during the operation. Complications in SHVE and HVEPV were fewer, or the same when compared with IPM^(12,14-17). It is worth noting that a systematic review and meta-analysis performed by Rahbari et al, stated that vascular exclusion during hepatic resections did not have an advantage over portal triad clamping regarding morbidity and mortality of hepatic resection patients⁽¹⁸⁾. This systematic review and meta-analysis only included four randomized controlled trials (RCT), which compared portal triad clamping to SHVE, THVE, and modified technique of hepatic vascular exclusion. Most hepatic resections in these

trials during the systematic review were not CCA, which was the major cause of hepatic resections in our institutions (SKH and KKH). Therefore, a well-designed study to compare the benefits of SHVE versus IPM during hepatic resections in CCA patients is justified.

The objectives of the present study were to compare IBL, intraoperative blood transfusion, total operative time (TOT), and procedural related perioperative complications between IPM concomitant with intermittent occlusion of extraparenchymal major hepatic veins technique (SHVE) with IPM.

Materials and Methods

Study design

The present study was conducted as a RCT and included 20 to 70-year-old CCA patients. Resectability was determined by preoperative contrast-enhanced CT scan or contrast-enhanced MRI. According to the study by Zhang et al⁽¹²⁾, to detect a reduction of 350 ml (approximately 40%) IBL in the SHVE group in comparison with the IPM group with a two-sided 0.05 significant level with a power of 80%, a sample size of fifteen participants was calculated for each group, and adjusted for the possibility of failure to control hepatic veins, which occurred in 10% of the intermittent clamping of hepatoduodenal ligament in combination with intermittent clamping of main hepatic veins without clamping of the IVC⁽¹⁹⁾. Thus, twenty participants in each group were necessary. Between October 2018 and September 2019, 61 consecutive CCA patients were scheduled for major hepatic resections in the hepatobiliary and pancreatic surgery unit at SKH and KKH. Patients who met the inclusion criteria were informed of the objectives, benefits, drawbacks, and possible complications of the present study by trained research assistants from the CCA Screening and Care Program (CASCAP) of Khon Kaen University who were not under the direction of the author and co-authors. After informed consents were voluntarily obtained from the participants, they were enrolled in the present trial by the research assistants.

The randomization sequence was generated with a random number table by the research assistances. Sealed opaque envelopes were used for concealment. In eligible participants, after the resectability was intraoperatively confirmed, they were allocated to either SHVE or IPM, and then the surgeons performed the operations according to the revealed allocation.

The primary outcome (IBL) was measured as this formula:

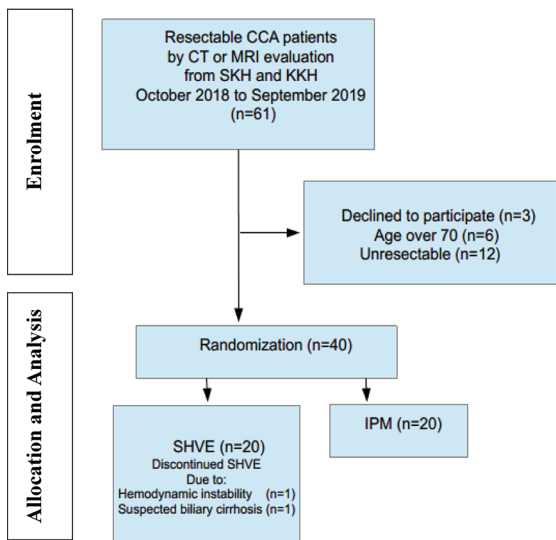


Figure 1. Trial profile.

CCA=cholangiocarcinoma, SKH=Sakon Nakhon Hospital, KKH=Khon Kaen Hospital, IPM=intermittent Pringle maneuver, SHVE=selective hepatic vascular exclusion

IBL = [Content from suction (ml) – Total abdominal normal saline irrigation water (ml)] + [Content from ultrasonic dissector suction (ml) – Irrigation water from ultrasonic dissector (ml)] + Blood loss in swabs and gauzes (ml)

Blood loss in swabs and gauzes was calculated as:

Blood loss in swabs and gauzes (ml) = [Weight of swabs and gauzes after operation (gm) – Weight of swabs and gauzes before operation (gm)] × 0.94*

* The present study approximated the weight of blood loss in swabs and gauzes as 1.06 gm equal to 1 ml of whole blood⁽²⁰⁾.

The secondary outcomes were packed red cell (PRC) transfusion, TOT, and perioperative complications. PRC transfusion was measured as milliliter (ml) of transfused PRC given during hepatic resections. TOT duration in minutes began when making incisions, and finished with complete suturing of the skin. Perioperative complications included postoperative bleeding, bile leakage, post-hepatectomy liver failure (PHLF), acute kidney injury (AKI), surgical site infection (SSI), and chyle leakage.

The severity of postoperative bleeding complication, bile leakage, SSI, and chyle leakage were graded according to the Clavien-Dindo classification of surgical complications⁽²¹⁾. Bile leakage was defined as the total bilirubin concentration in the drained fluid more than three times the serum total bilirubin concentration on or after postoperative day

3, or the need for percutaneous drainage or surgical drainage as the consequence of biliary collection, or bile peritonitis⁽²²⁾. PHLF and severity of PHLF were defined according to the International Study Group of Liver Surgery (ISGLS)⁽²³⁾. The definition and severity of AKI were defined according to Kidney Disease Improving Global Outcomes (KDIGO)⁽²⁴⁾. SSI definition was described according to the Centers for Disease Control (CDC)⁽²⁵⁾. Chyle leakage was identified when the triglyceride level in cloudy drain fluid was above 110 mg/dl⁽²⁶⁾.

Data collection and analyses of the primary and secondary outcomes between the IPM group and the SHVE group was performed according to the intention-to-treat basis. The trial profile flow diagram is shown in Figure 1.

Surgical technique

The abdominal cavity was approached using Mirror-L incision, followed by a thorough exploratory laparotomy. Coronary ligament and triangular ligament of the liver were transected and the liver was mobilized from its ligaments. Then, intraoperative ultrasonography was done for the evaluation of intrahepatic metastasis. Cholecystectomy and skeletonization of the hepatoduodenal ligament were performed. Full mobilization of the liver was done after ligation of short hepatic veins between the liver and IVC. In right hepatectomy (RH) with extended resection of liver segment 4B (REx), left hepatectomy (LH) with extended resection of liver segment 5 (LEx), and right trisectionectomy (RTS) for hilar cholangiocarcinoma (HCCA) cases, the caudate lobe of the liver had to be removed. Therefore, the short hepatic veins behind the caudate were ligated and the hepatogastric ligament was transected, the ligamentum venosum was transected to free the upper part of the caudate lobe. Parenchymal transection of the liver was performed with ultrasonic dissector (SonaStar®, Misonix Inc., Farmingdale, the U.S. for hepatectomies at SKH site and Söring®, Söring GmbH Medizintechnik, Quickborn, Germany for hepatectomies at KKH site) along the demarcation line after inflow vessels were sutured and ligated. The major hepatic veins from the resected liver were transected with the endoscopic linear cutting stapler.

In RH and REx, the right hepatic vein (RHV) was identified and extraparenchymally transected before the parenchymal transection. In the LH and LEEx, the left hepatic vein (LHV) was intraparenchymally transected during the parenchymal transection. For the RTS, the RHV was extraparenchymally transected




Figure 2. The common trunk of MHV and LHV was encircled with vessel loop (arrow).

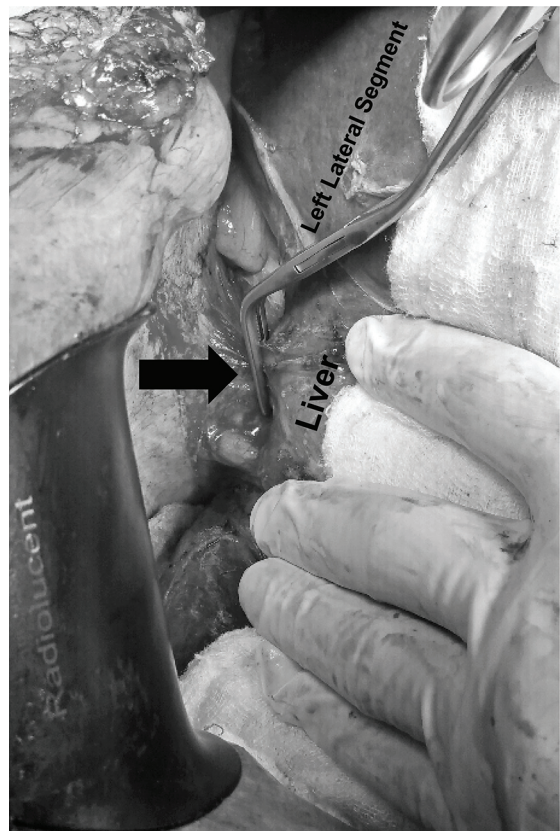


Figure 3. Satinsky clamp was used to occlude the common trunk of MHV and LHV (arrow).

before the parenchymal transection while the middle hepatic vein (MHV) was intraparenchymally transected during the parenchymal transection. For HCCA patients, the enterobiliary anastomosis was established with interrupted polydioxanone 5-0.

In the IPM group, the hepatoduodenal ligament was looped and tightened with elastic tape or clamped with a Satinsky clamp during liver parenchymal transection in 15-minute occlusion interval, followed by 5-minute unclamping interval. The cycles of 15-minute occlusion and 5-minute reperfusion were repeated until the parenchymal transection was completed. Bile ducts and vessels at the raw surface of the transected liver were sutured with 3-0 or 4-0 polypropylene.

In the SHVE group, on the right side, the liver was disconnected from the retrohepatic IVC by ligation and dissection of the short hepatic veins. The hepatocaval ligament was transected to expose the RHV, then the RHV was encircled with a vessel loop. For the RTS, REx, and RH, the RHV was transected before the parenchymal transection. On

the left side of the liver, the hepatogastric ligament and ligamentum venosum were dissected until the common trunk of the MHV and IVC were identified. The common trunk was encircled with the vessel loop. If the MHV and LHV joined IVC separately, they were individually encircled with vessel loops. During the liver parenchymal transection, the vessel loop at the common trunk of MHV and LHV was tightened as shown in Figure 2. In cases where MHV and LHV joined the IVC separately, the vessel loops were separately encircled at the MHV and LHV and tightened. If the common trunk of the MHV and LHV was technically difficult to be encircled with vessel loops, a Satinsky clamp was used to occlude the common trunk of the MHV and LHV⁽¹⁶⁾, as shown in Figure 3. IPM, as described previously, was performed in concomitant with occlusion of the main trunk of the MHV and LHV by using either vessel loop tourniquet or a Satinsky clamp. The cycle of occlusion and reperfusion of the hepatoduodenal ligament and hepatic veins was the same as in the IPM group.

All patients received general anesthesia. A central

Table 1. Patient demographics and tumor characteristics

	SHVE (n=20) n	IPM (n=20) n	p-value
Age (years); mean (SD)	61.1 (6.3)	57.4 (6.9)	0.84 ^a
ECOG status: 0/1	18/2	20/0	0.49 ^b
Sex: male/female	11/9	4/16	0.02 ^c
Diabetes mellitus	3	5	0.7 ^b
Hypertension	4	4	1 ^b
HbsAg positive	0	1	1 ^b
Hepatitis C antibody positive	1	1	1 ^b
Intrahepatic CCA	12	15	0.49 ^c
HCCA	8	5	0.49 ^b
Tumors with major hepatic veins involvement	5	5	1 ^c

SHVE=selective hepatic vascular exclusion; IPM=intermittent Pringle maneuver; SD=standard deviation; ECOG=Eastern Cooperative Oncology Group; CCA=cholangiocarcinoma; HCCA=hilar cholangiocarcinoma

^a p-value was calculated with t-test, ^b p-value was calculated with Fisher's exact test, ^c p-value was calculated with chi-square test

venous catheter and a radial arterial line were used to monitor the patients. The central venous pressure was controlled to be lower than 5 cm H₂O during the parenchymal transection.

Statistical analysis

Continuous data were presented as mean (SD) or median (range) according to their distributions and compared between intervention group using t-test or Mann-Whitney U-test. The categorical variables were presented as number, percent, and compared by using the chi-square test or Fisher's exact test. The p-value of less than 0.05 was considered as statistically significant. All analyses were performed using SPSS 17.0 (SPSS, Chicago, IL).

The present study was approved by the Ethics Committee from SKH (Document Number ECSKH14/2561) and KKH (Document Number KE61065), and was registered to the Thai Clinical Trials Registry, TCTR20181112002.

Results

There were 20 patients in the SHVE group and 20 patients in the IPM group. Patient demographics and tumor characteristics are shown in Table 1. Age, Eastern Cooperative Oncology Group (ECOG) Status, underlying diseases, hepatitis B and hepatitis C viral infection status, and types of the tumor were not significantly different between the SHVE and the IPM group. However, there were more male patients

Table 2. Types of hepatic resection

Procedure ^a	SHVE (n=20) n	IPM (n=20) n	p-value ^b
Right trisectionectomy	1	1	1
Right hepatectomy with extended resection of liver segment 4B	5	3	0.7
Left hepatectomy with extended resection of liver segment 5	3	1	0.61
Right hepatectomy	6	12	0.11
Left hepatectomy	5	3	0.7

SHVE=selective hepatic vascular exclusion; IPM=intermittent Pringle maneuver

^a Types of hepatic resection were defined according to Brisbane 2000 Nomenclature of Liver Anatomy and Resections⁽²⁷⁾

^b p-value was calculated with Fisher's exact test

in the SHVE group. Types of hepatic resections are shown in Table 2. Types of hepatic resections were not significantly different between the intervention groups.

In the SHVE group, two patients required procedural changing. One patient was changed from SHVE to IPM due to a drop in blood pressure during SHVE. The second was changed from SHVE to IPM after more than 50% of the parenchymal transection was performed due to suspicious of biliary cirrhosis. Comparisons of the outcomes according to the intention-to-treat principle are shown in Table 3. There was no significant difference in IBL, intraoperative PRC transfusion, TOT, and perioperative complications between SHVE and IPM. In the severity of perioperative complications, the majority of the complications were in Clavien-Dindo classification grade I. One patient in the SHVE group had bile leakage that needed percutaneous drainage (Clavien-Dindo classification grade III). Additionally, one patient in the IPM group had portal vein thrombosis that required anticoagulant treatment (Clavien-Dindo classification grade II). There was no perioperative mortality in either the SHVE or the IPM group. For per-protocol analysis, comparisons of the outcomes are displayed in Table 4. There was no difference between the primary and secondary outcomes for both SHVE and IPM. In the SHVE group, occlusion of the main trunk of the MHV and LHV were done by using a Satinsky clamp in sixteen participants, while a vessel loop tourniquet was used in four participants. There were no ruptured of major hepatic veins and IVC during SHVE in the present study.

Table 3. Outcomes (intention-to-treat analysis)

	SHVE	IPM	p-value
	Median (range)	Median (range)	
IBL (ml)	923.5 (101 to 4,979)	1,109 (413 to 5,305)	0.2 ^a
PRC (ml)	112.5 (0 to 1,745)	296 (0 to 1,500)	0.22 ^a
TOT (minute)	390 (220 to 915)	320 (240 to 930)	0.55 ^a
Complications; n			
Bile leakage	9	5	0.32 ^b
Bleeding	0	0	NA
PHLF	0	0	NA
AKI	1	0	1 ^b
SSI	2	1	1 ^b
Portal vein thrombosis	0	1	1 ^b
Chyle leakage	0	1	1 ^b
Tear IVC	0	1	1 ^b

SHVE=selective hepatic vascular exclusion; IPM=intermittent Pringle maneuver; IBL=intraoperative blood loss; PRC=packed red cell; TOT=total operative time; PHLF=post-hepatectomy liver failure; AKI=acute kidney injury; SSI=surgical site infection; IVC=inferior vena cava; NA=not analyzed

^a Data analyzed with Mann-Whitney U test, ^b Data analyzed with Fisher's exact test

Table 4. Outcomes (per protocol analysis)

	SHVE	IPM	p-value
	Median (range)	Median (range)	
IBL (ml)	970.5 (101 to 4,979)	1,096.5 (413 to 5,305)	0.57 ^a
PRC (ml)	112.5 (0 to 1,745)	263.5 (0 to 1,500)	0.3 ^a
FFP transfusion (ml)	0 (0 to 927)	0 (0 to 1,200)	0.4 ^a
TOT (minute)	390 (220 to 915)	320 (235 to 930)	0.5 ^a
Complications; n			
Bile leakage	9	5	0.1 ^b
Bleeding	0	0	NA
PHLF	0	0	NA
AKI	1	0	0.45 ^b
SSI	1	2	1 ^b
Portal vein thrombosis	0	1	1 ^b
Chyle leakage	0	1	1 ^b
Tear IVC	0	1	1 ^b

SHVE=selective hepatic vascular exclusion; IPM=intermittent Pringle maneuver; IBL=intraoperative blood loss; FFP=fresh frozen plasma; TOT=total operative time; PHLF=post-hepatectomy liver failure; AKI=acute kidney injury; SSI=surgical site infection; IVC=inferior vena cava; NA=not analyzed

^a Data analyzed with Mann-Whitney U test, ^b Data analyzed with Fisher's exact test

Discussion

Patient demographics, tumor characteristics, and type of hepatic resections were not significantly different between the SHVE and IPM groups, except for the participant gender. There were more male in the SHVE group. It is worth noting that this significant difference has occurred by chance⁽²⁸⁾. The primary outcome in the present study was IBL. There was a lower median IBL in the SHVE group, however, the difference in IBL between the SHVE group and IPM group was not statistically significant. The result of the present study was different from other comparative studies^(10,12,14,17,29), which demonstrated significantly lower IBL in the SHVE group as shown in Table 5. The explanation for the difference in the IBL outcome of the present study when compared to previous studies might be due to the lesion location. Most previous comparative studies^(12,14,17,29) involved cases where lesions occurred on one or more major hepatic veins. Most lesions in the present study had no involvement with major hepatic veins, as shown in Table 1. Prevention of backflow bleeding from hepatic veins by SHVE might provide the most effective benefit in lesions involving major hepatic veins, while the lesions not involved by hepatic veins might have less benefit in the prevention of backflow bleeding. This is because the lesions without hepatic vein

involvement already had small amounts of backflow bleeding, and IPM with low central venous pressure could control most of the bleeding during the hepatic parenchymal transection.

IBL affected PRC transfusion as well. The previous comparative studies^(10,12,14,17,29) demonstrated lower IBL, reported lower PRC transfusion in the SHVE group. This finding has not been observed in the present study.

TOT and perioperative complications between SHVE and IPM in the present study were not significantly different. Outcomes were similar to the majority of the previous studies as demonstrated in Table 5. Previous studies^(10,17,29), as well as the present study, showed similar TOT between SHVE and IPM. For perioperative complications, Zhou et al⁽¹⁷⁾ and Si-Yuan et al⁽²⁹⁾ showed fewer complications in the SHVE group, while the other studies^(10,12,14), as well as the present study, demonstrated similar complications between SHVE and IPM. This could reflect on the expertise in the authors' high-volume hepatobiliary center.

The strength of the present study is the application of the objective measurement of the IBL by calculation of blood loss from the suction, ultrasonic dissector, and weight of swabs as described in the study design

Table 5. Previous studies

Study	Study design (n)	Type of tumor	Type of hepatic resections	IBL	PRC transfusion	TOT	Complications
Smyrniotis, et al., 2003 ⁽¹⁰⁾	RCT (110)	Benign and malignant lesion	Major	Lower in SHVE, p=0.02	Lower in SHVE, p=0.01	Similar	Similar
Zhou, et al., 2008 ⁽¹⁷⁾	Retrospective (235)	Benign and malignant lesions*	Major Segmentectomy	Lower in SHVE, p=0.001	Lower in SHVE, p=0.001	Similar	Lower in SHVE, p<0.05
Zhang, et al., 2012 ⁽¹²⁾	Retrospective (1,420)	Benign and malignant lesions*	Major	Lower in SHVE, p=0.007	Lower in SHVE, p=0.008	Not assessed	Lower PHLF in SHVE, p=0.019 Overall complication rate was similar
Yang, et al., 2012 ⁽¹⁴⁾	Retrospective (273)	Hemangioma*	Major Segmentectomy	Lower in SHVE, p<0.01	Lower in SHVE, p<0.01	Longer in SHVE, p=0.02	Similar
Si-Yuan, et al., 2014 ⁽²⁹⁾	RCT (160)	Benign and malignant lesions*	Major Segmentectomy	Lower in SHVE, p<0.05	Lower in SHVE, p<0.05	Similar	Lower in SHVE, p<0.05

RCT=randomized controlled trial; SHVE=selective hepatic vascular exclusion; IBL=intraoperative blood loss; PRC=packed red cell; TOT=total operative time; PHLF=post-hepatectomy liver failure

* Lesions involved one or more major hepatic veins

section. The limitation of the present study is the inability to blind the surgeons who performed the procedures and assessed IBL and perioperative complications. Nevertheless, the present study used clear definitions of each perioperative complication that had been explained in the study design section to minimize bias.

Conclusion

There is no difference in IBL and PRC transfusion between routine use of SHVE and IPM during hepatic resections in CCA patients. SHVE does not increase TOT and perioperative complications in comparison with IPM.

What is already known on this topic?

Several studies demonstrated that SHVE could reduce IBL and PRC transfusion during major hepatic resections and segmental hepatic resections in both benign and malignant lesions in comparison with IPM. This was especially true when the lesions involved major hepatic veins. Most previous studies focused on lesions that involved major hepatic veins. They reported similar TOT and fewer, or the same complication rate between these two methods as demonstrated in Table 5. However, there was a lack of information regarding the use of SHVE in hepatic resection for CCA, as there were small numbers of CCA cases in the previous studies. In the present study, 75% of the lesions did not involve major hepatic veins. Therefore, the outcomes of the routine use of SHVE during hepatic resections for CCA patients should be further investigated.

What this study adds?

Routine SHVE for hepatic resections in CCA does not reduce IBL and PRC transfusion. The TOT and complications are not different between SHVE and IPM.

Acknowledgement

The authors would like to thank Dr. Rachati Thongprayoon for his help as hepatobiliary surgeon in Sakon Nakhon Hospital during the study period, Dr. Amarit Tansawet, Vajira Alimentary Tract Surgery Unit, Department of Surgery, Faculty of Medicine, Vajira Hospital, Navamindradhiraj University for his advice in the statistical analysis, Miss Ketkanok Charoenrat at SKH and Miss Karntheera Wanthong at KKH from CASCAP for their help as research assistants, and Mr. Bradley Rader for his help in proofreading this article.

Conflicts of interest

The authors declare no conflict of interest.

References

1. Yamamoto J, Kosuge T, Takayama T, Shimada K, Yamasaki S, Ozaki H, et al. Perioperative blood transfusion promotes recurrence of hepatocellular carcinoma after hepatectomy. *Surgery* 1994;115:303-9.
2. Belghiti J, Noun R, Malafosse R, Jagot P, Sauvanet A, Pierangeli F, et al. Continuous versus intermittent portal triad clamping for liver resection: a controlled study. *Ann Surg* 1999;229:369-75.
3. Chouillard EK, Gumbs AA, Cherqui D. Vascular clamping in liver surgery: physiology, indications and techniques. *Ann Surg Innov Res* 2010;4:2.

4. Makuuchi M, Mori T, Gunven P, Yamazaki S, Hasegawa H. Safety of hemihepatic vascular occlusion during resection of the liver. *Surg Gynecol Obstet* 1987;164:155-8.
5. Castaing D, Garden OJ, Bismuth H. Segmental liver resection using ultrasound-guided selective portal venous occlusion. *Ann Surg* 1989;210:20-3.
6. Goseki N, Kato S, Takamatsu S, Dobashi Y, Hara Y, Teramoto K, et al. Hepatic resection under the intermittent selective portal branch occlusion by balloon catheter. *J Am Coll Surg* 1994;179:673-8.
7. van Gulik TM, de Graaf W, Dinant S, Busch OR, Gouma DJ. Vascular occlusion techniques during liver resection. *Dig Surg* 2007;24:274-81.
8. Cherqui D, Malassagne B, Colau PI, Brunetti F, Rotman N, Fagniez PL. Hepatic vascular exclusion with preservation of the caval flow for liver resections. *Ann Surg* 1999;230:24-30.
9. Huguet C, Addario-Chieco P, Gavelli A, Arrigo E, Harb J, Clement RR. Technique of hepatic vascular exclusion for extensive liver resection. *Am J Surg* 1992;163:602-5.
10. Smyrniotis VE, Kostopanagiotou GG, Contis JC, Farantos CI, Voros DC, Kannas DC, et al. Selective hepatic vascular exclusion versus Pringle maneuver in major liver resections: prospective study. *World J Surg* 2003;27:765-9.
11. Smyrniotis VE, Kostopanagiotou GG, Gamaletsos EL, Vassiliou JG, Voros DC, Fotopoulos AC, et al. Total versus selective hepatic vascular exclusion in major liver resections. *Am J Surg* 2002;183:173-8.
12. Zhang J, Lai EC, Zhou WP, Fu S, Pan Z, Yang Y, et al. Selective hepatic vascular exclusion versus Pringle manoeuvre in liver resection for tumours encroaching on major hepatic veins. *Br J Surg* 2012;99:973-7.
13. Fu SY, Lai EC, Li AJ, Pan ZY, Yang Y, Sun YM, et al. Liver resection with selective hepatic vascular exclusion: a cohort study. *Ann Surg* 2009;249:624-7.
14. Yang Y, Zhao LH, Fu SY, Lau WY, Lai EC, Gu FM, et al. Selective hepatic vascular exclusion versus pringle maneuver in partial hepatectomy for liver hemangioma compressing or involving the major hepatic veins. *Am Surg* 2014;80:236-40.
15. Tsujita E, Taketomi A, Kitagawa D, Itoh S, Harimoto N, Gion T, et al. Selective hepatic vascular exclusion for the hepatic resection of HCC. *Hepatogastroenterology* 2007;54:527-30.
16. Li AJ, Pan ZY, Zhou WP, Fu SY, Yang Y, Huang G, et al. Comparison of two methods of selective hepatic vascular exclusion for liver resection involving the roots of the hepatic veins. *J Gastrointest Surg* 2008;12:1383-90.
17. Zhou W, Li A, Pan Z, Fu S, Yang Y, Tang L, et al. Selective hepatic vascular exclusion and Pringle maneuver: a comparative study in liver resection. *Eur J Surg Oncol* 2008;34:49-54.
18. Rahbari NN, Koch M, Mehrabi A, Weidmann K, Motschall E, Kahlert C, et al. Portal triad clamping versus vascular exclusion for vascular control during hepatic resection: a systematic review and meta-analysis. *J Gastrointest Surg* 2009;13:558-68.
19. Elias D, Lasser P, Debaene B, Doidy L, Billard V, Spencer A, et al. Intermittent vascular exclusion of the liver (without vena cava clamping) during major hepatectomy. *Br J Surg* 1995;82:1535-9.
20. Trudnowski RJ, Rico RC. Specific gravity of blood and plasma at 4 and 37 degrees C. *Clin Chem* 1974;20:615-6.
21. Dindo D, Demartines N, Clavien PA. Classification of surgical complications: a new proposal with evaluation in a cohort of 6336 patients and results of a survey. *Ann Surg* 2004;240:205-13.
22. Koch M, Garden OJ, Padbury R, Rahbari NN, Adam R, Capussotti L, et al. Bile leakage after hepatobiliary and pancreatic surgery: a definition and grading of severity by the International Study Group of Liver Surgery. *Surgery* 2011;149:680-8.
23. Rahbari NN, Garden OJ, Padbury R, Brooke-Smith M, Crawford M, Adam R, et al. Posthepatectomy liver failure: a definition and grading by the International Study Group of Liver Surgery (ISGLS). *Surgery* 2011;149:713-24.
24. Acute Kidney Injury Work Group. Kidney disease: Improving Global Outcomes. KDIGO Clinical practice guideline for acute kidney injury. *Kidney Inter Suppl* 2012;2 Suppl 1:1-138.
25. Horan TC, Gaynes RP, Martone WJ, Jarvis WR, Emori TG. CDC definitions of nosocomial surgical site infections, 1992: a modification of CDC definitions of surgical wound infections. *Infect Control Hosp Epidemiol* 1992;13:606-8.
26. Al Busafi SA, Ghali P, Deschenes M, Wong P. Chylous Ascites: Evaluation and Management. *ISRN Hepatol* 2014;2014:240473.
27. Terminology Committee of the International Hepato-Pancreato-Biliary Association. The Brisbane 2000 Terminology of liver anatomy and resections. *HPB* 2000;2:333-9.
28. Moher D, Hopewell S, Schulz KF, Montori V, Gotzsche PC, Devereaux PJ, et al. CONSORT 2010 explanation and elaboration: updated guidelines for reporting parallel group randomised trials. *BMJ* 2010;340:c869.
29. Si-Yuan F, Yee LW, Yuan Y, Sheng-Xian Y, Zheng-Guang W, Gang H, et al. Pringle manoeuvre versus selective hepatic vascular exclusion in partial hepatectomy for tumours adjacent to the hepatocaval junction: a randomized comparative study. *Int J Surg* 2014;12:768-73.