

# High Prognostic Value of One Negative F18 FDG PET/CT for Cure of Malignant Lymphomas

Chiewvit S, MD<sup>1</sup>, Chiewvit P, MD<sup>2</sup>, Pongsawat N, BSc<sup>1</sup>

<sup>1</sup> Division of Nuclear Medicine, Department of Radiology, Faculty of Medicine Siriraj Hospital, Mahidol University, Bangkok, Thailand

<sup>2</sup> Division of Diagnostic Radiology, Department of Radiology, Faculty of Medicine Siriraj Hospital, Mahidol University, Bangkok, Thailand

**Background:** The 18-fluorodeoxyglucose positron emission tomography or computed tomography (F18 FDG PET/CT) is a highly sensitive method for determining sites of disease in the diagnosis of lymphoma. F18 FDG PET/CT in post-treatment lymphoma is capable of distinguishing fibrosis from residual active lymphoma. No studies hitherto have addressed the value of a negative PET/CT scan during follow-up.

**Objective:** To determine the incidence and consequence of a negative scan and record the active recurrence or lesion metastasis after negative F18 FDG PET/CT finding in lymphoma patients.

**Materials and Methods:** The present study was done retrospectively, including 82 consecutive Hodgkin's and non-Hodgkin's lymphoma patients with a negative F18 FDG PET/CT finding between January 2008 and December 2013. Demographic and clinical data were collected and analyzed.

**Results:** Seventy-two of 82 negative F18 FDG PET/CT studies (87.8%) had no evidence of disease recurrence, with a mean follow-up of 1,401 days (range 120 to 3,037). Ten of 82 negative F18 FDG PET/CT studies (12.2%) developed recurrent disease, with a mean time of recurrence after PET/CT of 642 days (range 50 to 1,205).

**Conclusion:** Normal F18 FDG PET/CT scan after lymphoma treatment was found to be associated with low incidence of disease recurrence for a long time. Only 10 (12.2%) patients in the present study had disease recurrence, with a mean recurrence time after PET/CT of 642 days.

**Keywords:** Active recurrence, Post-treatment lymphoma, Negative F18 FDG PET/CT, Negative 18-fluorodeoxyglucose positron emission tomography

Received 27 Aug 2018 | Revised 3 Jun 2019 | Accepted 15 Aug 2019

**J Med Assoc Thai 2020;103(1):52-7**

**Website:** <http://www.jmatonline.com>

The 18-fluorodeoxyglucose positron emission tomography or computed tomography (F18 FDG PET/CT) has proved to be a highly sensitive method for determining the sites of disease in the diagnosis of lymphoma. F18 FDG PET/CT in post treatment lymphoma is capable of distinguishing fibrosis from residual active lymphoma. The high negative predictive value (NPV) suggests that a normal F18 FDG PET/CT scan can exclude persistent disease.

The positron emission tomography (PET) has a consistently high NPV averaging about 85% across studies including patients with Hodgkin's lymphoma or diffuse large B-cell non-Hodgkin's lymphoma<sup>(1-7)</sup>. The approximately 15% false-negative rate associate with PET is mostly related to its inability to detect microscopic disease which may result in future relapse. The aim of the present study was to determine the incidence and timing of active recurrence or lesion metastasis after negative F18 FDG PET/CT finding in lymphoma patients.

## Correspondence to:

Chiewvit S.

Department of Radiology, Faculty of Medicine, Siriraj Hospital Mahidol University, 2 Wang Lang Road, Bangkoknoi, Bangkok 10700, Thailand.

**Phone:** +66-89-5030484, **Fax:** +66-2-4196220

**Email:** schiewvit1@hotmail.com

## Materials and Methods

### Patients

The present study was a retrospective study of the medical records of 94 consecutive Hodgkin's and

**How to cite this article:** Chiewvit S, Chiewvit P, Pongsawat N. High Prognostic Value of One Negative F18 FDG PET/CT for Cure of Malignant Lymphomas. J Med Assoc Thai 2020;103:52-7.

**Table 1.** The patients cell type and clinical indication for F18 FDG PET/CT

Cell type	Indication				Total
	Abnormal CT	Response to treatment	No clinical	Nasal mass	
HL	6	15	2	0	23
NHL	10	39	9	1	59
DLBCL	7	26	8	0	41
Follicles	1	5	0	0	6
Mediastinal B-cell lymphoma	2	1	0	0	3
NK/T cell	0	1	0	1	2
Anaplastic large cell	0	2	1	0	3
Burkitt lymphoma	0	3	0	0	3
Mantle cell lymphoma	0	1	0	0	1

CT=computed tomography; HL=Hodgkin's lymphoma; NHL=non-Hodgkin's lymphoma; DLBCL=diffuse large B-cell lymphoma

non-Hodgkin's lymphoma patients with a negative F18 FDG PET/CT finding between January 2008 and December 2013. Twelve patients were excluded due to loss to follow-up or incomplete medical records. The remaining 82 patients were included. The mean age of patients was 44.49 years (range 8 to 82) with a near equal distribution between gender (42 males:40 females). The mean follow-up time was 1,309 days (range 50 to 3,037). Patient follow-up data up to and on 30 September 2016 were included in the present study. The patients cell type and clinical indication for F18 FDG PET/CT are presented in Table 1.

The present study was conducted at Siriraj Hospital. The protocol for the present study was approved by the Siriraj Institutional Review Board (SIRB), Faculty of Medicine Siriraj Hospital Mahidol University, Bangkok, Thailand.

### Imaging protocol

Patients were instructed to fast, except for glucose-free oral hydration, for four to six hours before an intravenous injection of 370 to 555 MBq (10 to 15 mCi) 18F FDG. Blood glucose was measured before the injection of the tracer to ensure that the glucose blood levels was less than 200 mg/dL. After injection of the tracer, patients were kept lying comfortably. Whole-body PET contrast and non-contrast enhanced computed tomography (CT) images were acquired consecutively one hour after injection of the tracer, using a GE Discovery ST PET/CT scanner (General Electric, Milwaukee, Wisconsin, USA). Contrast or non-contrast CT images were obtained from the integrated PET/CT scanner using the following standardized protocol 140 kV, 70 mA, tube rotation time of 0.5 second per rotation pitch

of 6, and section thickness of 3.75 mm. PET images were acquired for four minutes per bed position immediately following CT imaging.

### Imaging analysis

Visual assessment was used to categorize F18 FDG-PET/CT scan findings as negative without a specific standardized uptake value (SUV) cut-off. F18 FDG PET/CT was defined as negative if there was no F18 FDG uptake or uptake equal to background. A final diagnosis of disease recurrence or distant metastasis was made after histopathological analysis, clinical, and imaging follow-up.

### Statistical analysis

Demographic and clinical data were collected and analyzed. Qualitative data were expressed as percentages, and quantitative data were expressed as mean and range. Data were analyzed using percentile for the days after normal F18 FDG PET/CT and incidence of recurrent disease.

### Results

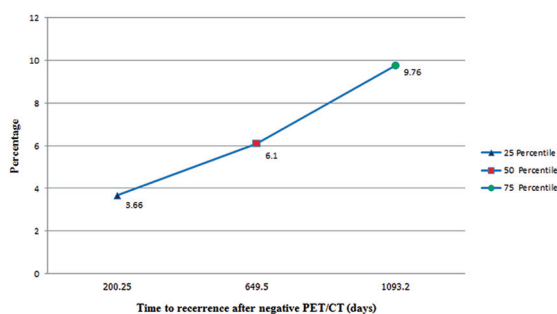
No evidence of tumor recurrence was found in 72 patients. Ten patients had recurrence of active lymphoma after PET/CT imaging as shown in Table 2.

Seventy-two of 82 negative F18 FDG PET/CT studies (87.8%) had no evidence of disease recurrence, with a mean follow-up of 1,401 days (range 120 to 3,037). Ten of 82 negative F18 FDG PET/CT studies (12.2%) developed recurrent disease, with a mean time to recurrence of 642 days after PET/CT (range 50 to 1,205). The percentage of F18 FDG PET/CT detected recurrence cancer after negative F18 FDG PET/CT by date (day) is presented in Figure 1.

**Table 2.** Demographic and clinical data of 10 patients with active lymphoma recurrences after negative PET/CT

Case no.	Sex	Age (years)	Lesion	Timing of recurrence after PET/CT (day)
1	Female	27	Mediastinum	906
2	Male	8	Mediastinum node, abdominal node and inguinal node	374
3	Male	17	Neck node	235
4	Female	59	Neck node	592
5	Male	55	Pelvic lymph nodes	50
6	Female	59	Lung	1,058
7	Male	57	Axilla and hilar nodes	1,199
8	Male	25	cervical and supraclavicular node	1,205
9	Male	60	Brain, lymph node	96
10	Female	60	Right parotid and neck node	707

PET/CT=positron emission tomography/computed tomography



**Figure 1.** Present the percentage of F18 FDG PET/CT detect recurrence cancer after negative F18 FDG PET/CT by date (day).

Four sample cases of recurrence lymphoma after negative F18 FDG PET/CT scan are presented in Figure 2.

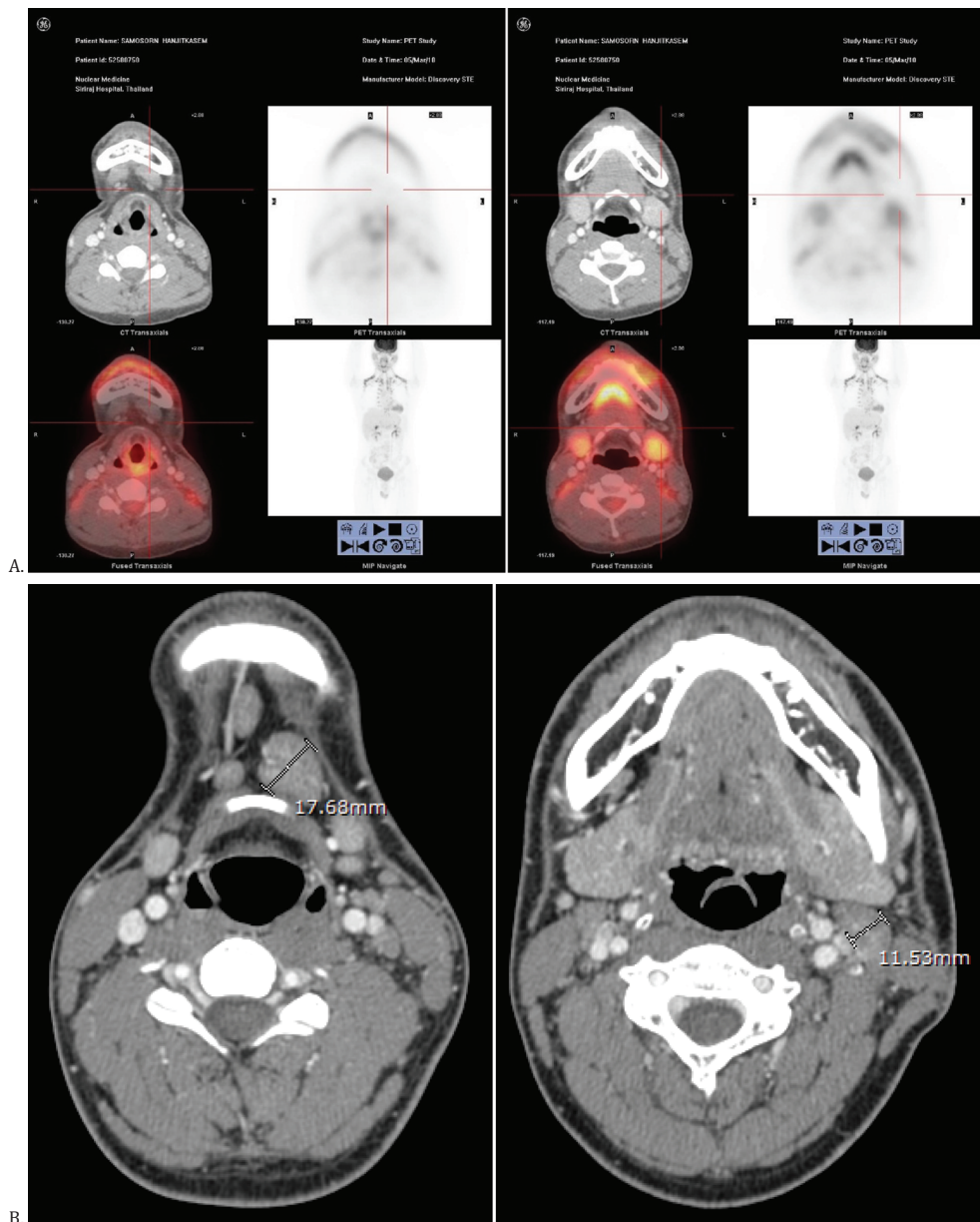
## Discussion

Normal findings on F18 FDG PET/CT scan after lymphoma therapy is highly predictive of a good prognosis, with a low mean incidence of disease recurrence<sup>(8,9)</sup>. However, false-negative FDG uptake is a potential technological limitation of F18 FDG PET/CT, an inherent property of neoplasm. Lesions measuring less than two to three times the spatial resolution of the scanner will appear less active and will have a lower SUV due to the partial volume effect. Lesions containing small cells, low metabolic neoplasm, and well differentiated tumors can lead to false negative results due to low glucose metabolism.

Currently, F18 FDG PET/CT is normally used in symptomatic patients with suspicion of disease recurrence<sup>(10)</sup>. However, impact on therapeutic management has mainly been reported in asymptomatic

patients relative to salvage therapies<sup>(11-13)</sup>. The present study data support the use of F18 FDG PET/CT scan in asymptomatic patients planning for salvage therapies due to the low incidence of recurrent disease for an extended time after normal F18 FDG PET/CT scan. The result of the present study revealed no added value in using F18 FDG PET/CT scanning for disease surveillance in patients at a mean time of recurrence after negative PET/CT at the end of treatments. Recurrent disease was identified in only 3.66% of the patients at a mean time 200 days, and in only 6.1% of patients at a mean time of recurrence after negative PET/CT scan 649 days (Figure 1). When accounting both the cost of F18 FDG PET/CT and the associated high dose of patient radiation exposure, there is no evidence to suggest the benefit of F18 FDG PET/CT recurrence surveillance in this disease. The study by El-Galaly et al<sup>(14)</sup> revealed that F18 FDG PET/CT was effective in detecting unexpected relapse and normal PET/CT supported continuous complete response (CR). However, the impact of PET/CT was limited by the high number of false-positive results and F18 FDG PET/CT surveillance was costly compared to CT surveillance.

From a previous study by Spaepen et al<sup>(5)</sup>, 67 non-Hodgkin's lymphoma patients had a normal F18 FDG PET scan after first-line chemotherapy. Fifty-six of 67 patients had a CR and remained in remission, with a median follow-up of 653 days. Only 11 of 67 patients (16.42%) relapsed, with a median progressive-free survival (PFS) 404 days. Fifty-five Hodgkin's disease patients<sup>(6)</sup> had a normal F18 FDG PET scan, with 50 of 55 patients having a CR and remaining in complete remission for a median of 955 days. Only five patients (9.09%) relapsed, for a median PFS of 296 days.



**Figure 2.** Patient number 3, a 17-year-old male who underwent chemotherapy for Burkett's lymphoma was sent for F18 FDG PET/CT scan to evaluate treatment response. (A) Non-visualization of abnormal activity accumulation in the neck node is consistent with completed response to CHOP treatment. (B) Follow-up contrast CT 8-month later revealing lymphadenopathy at bilateral submental and left cervical node group II.

A prospectively study by Naumann et al<sup>(15)</sup> in lymphoma patients with CT documented residual masses showed a rate of recurrence of only 4% (2/50 patients) with PET-negative study. The recurrences occurred after a median follow-up of 11 months after the end of therapy (median six months after PET).

A study by Carrillo-Cruz et al<sup>(16)</sup> in 27 patients with post-treatment PET/CT found 22 patients to be

in complete remission with one true-positive lesion and four false-positive lesions (two nodal and two extranodal) being detected. With a median follow-up of 27 months, 22 patients with negative PET/CT did not relapse. Thus, NPV was 100%.

The limitations of the present study are its retrospective design and the population analyzed was heterogeneous for histological types.

## Conclusion

Normal F18 FDG PET/CT scan after lymphoma treatment was found to be associated with low incidence of disease recurrence. Only 10 (12.2%) patients in the present study had disease recurrence, with a mean recurrence duration of 642 days.

## What is already known on this topic?

The limitations of CT imaging in restaging lymphoma is because this method cannot differentiate between residual viable lymphoma and post treatment necrosis and fibrosis. Positive F18 FDG PET/CT scan was found to be a strong predictor of relapse, with up to 100% of patients with persistent disease after therapy having recurrent disease within two years. There are only a few papers that present a prognostic of negative F18 FDG PET/CT scan(17).

## What this study adds?

Negative F18 FDG PET/CT scan is associated with low incidence of disease recurrence. Only 12.2% patients in this study had disease recurrence, with a mean recurrence duration of 642 days.

## Acknowledgement

The present study was supported by the Faculty of Medicine, Siriraj Hospital, Mahidol University. The authors gratefully acknowledge Miss Dollaporn Polyeam for her assistance with statistical analyses.

## Conflicts of interest

The authors declare no conflict of interest.

## References

1. Juweid ME, Wiseman GA, Vose JM, Ritchie JM, Menda Y, Wooldridge JE, et al. Response assessment of aggressive non-Hodgkin's lymphoma by integrated International Workshop Criteria and fluorine-18-fluorodeoxyglucose positron emission tomography. *J Clin Oncol* 2005;23:4652-61.
2. Jerusalem G, Beguin Y, Fassotte MF, Najjar F, Paulus P, Rigo P, et al. Whole-body positron emission tomography using 18F-fluorodeoxyglucose for posttreatment evaluation in Hodgkin's disease and non-Hodgkin's lymphoma has higher diagnostic and prognostic value than classical computed tomography scan imaging. *Blood* 1999;94:429-33.
3. Zinzani PL, Magagnoli M, Chierichetti F, Zompatori M, Garraffa G, Bendandi M, et al. The role of positron emission tomography (PET) in the management of lymphoma patients. *Ann Oncol* 1999;10:1181-4.
4. Weihsrauch MR, Re D, Scheidhauer K, Ansen S, Dietlein M, Bischoff S, et al. Thoracic positron emission tomography using 18F-fluorodeoxyglucose for the evaluation of residual mediastinal Hodgkin disease. *Blood* 2001;98:2930-4.
5. Spaepen K, Stroobants S, Dupont P, Van Steenweghen S, Thomas J, Vandenberghe P, et al. Prognostic value of positron emission tomography (PET) with fluorine-18 fluorodeoxyglucose ([18F]FDG) after first-line chemotherapy in non-Hodgkin's lymphoma: is [18F]FDG-PET a valid alternative to conventional diagnostic methods? *J Clin Oncol* 2001;19:414-9.
6. Spaepen K, Stroobants S, Dupont P, Thomas J, Vandenberghe P, Balzarini J, et al. Can positron emission tomography with [(18)F]-fluorodeoxyglucose after first-line treatment distinguish Hodgkin's disease patients who need additional therapy from others in whom additional therapy would mean avoidable toxicity? *Br J Haematol* 2001;115:272-8.
7. Zijlstra JM, Lindauer-van der Werf G, Hoekstra OS, Hooft L, Riphagen II, Huijgens PC. 18F-fluorodeoxyglucose positron emission tomography for post-treatment evaluation of malignant lymphoma: a systematic review. *Haematologica* 2006;91:522-9.
8. ABO-Sheisha DM, Abdel Fattah O. Prognostic evaluation of PET/CT in residual post-chemotherapy masses in patients with diffuse large B-cell lymphoma and its impact on survival. *Egypt J Radiol Nucl Med* 2014;45:921-8.
9. Ansell SM, Armitage JO. Positron emission tomographic scans in lymphoma: convention and controversy. *Mayo Clin Proc* 2012;87:571-80.
10. Taghipour M, Marcus C, Nunna P, Subramaniam RM. Follow-up FDG PET/CT in patients with Non-Hodgkin lymphoma: Value to clinical assessment and patient management. *Clin Nucl Med* 2016;41:e93-7.
11. Smeltzer JP, Cashen AF, Zhang Q, Homb A, Dehdashti F, Abboud CN, et al. Prognostic significance of FDG-PET in relapsed or refractory classical Hodgkin lymphoma treated with standard salvage chemotherapy and autologous stem cell transplantation. *Biol Blood Marrow Transplant* 2011;17:1646-52.
12. Moskowitz AJ, Yahalom J, Kewalramani T, Maragulia JC, Vanak JM, Zelenetz AD, et al. Pretransplantation functional imaging predicts outcome following autologous stem cell transplantation for relapsed and refractory Hodgkin lymphoma. *Blood* 2010;116:4934-7.
13. Jabbour E, Hosing C, Ayers G, Nunez R, Anderlini P, Pro B, et al. Pretransplant positive positron emission tomography/gallium scans predict poor outcome in patients with recurrent/refractory Hodgkin lymphoma. *Cancer* 2007;109:2481-9.
14. El Galaly T, Prakash V, Christiansen I, Madsen J, Johansen P, Boegsted M, et al. Efficacy of routine surveillance with positron emission tomography/computed tomography in aggressive non-Hodgkin lymphoma in complete remission: status in a single center. *Leuk Lymphoma* 2011;52:597-603.
15. Naumann R, Vaic A, Beuthien-Baumann B, Bredow J, Kropp J, Kittner T, et al. Prognostic value of positron

- emission tomography in the evaluation of post-treatment residual mass in patients with Hodgkin's disease and non-Hodgkin's lymphoma. *Br J Haematol* 2001;115:793-800.
16. Carrillo-Cruz E, Marín-Oyaga VA, Solé Rodríguez M, Borrego-Dorado I, de la Cruz Vicente F, Quiroga Cantero E, et al. Role of 18F-FDG-PET/CT in the management of Burkitt lymphoma. *Eur J Haematol* 2015;94:23-30.
17. Mikhaeel NG, Hutchings M, Fields PA, O'Doherty MJ, Timothy AR. FDG-PET after two to three cycles of chemotherapy predicts progression-free and overall survival in high-grade non-Hodgkin lymphoma. *Ann Oncol* 2005;16:1514-23.