

Case Report

Mucosa-Associated Lymphoid Tissue Lymphoma with Large Cell Transformation on the Background of Hashimoto's Thyroiditis: A Case Report and Review Literature

Natavuth Hengjeerajarus MD*, Teerada Klaisuwan MD***,
Lalita Norasetthada MD**, Natapong Kosachunhanun MD*

* Division of Endocrinology and Metabolism, Department of Internal Medicine, Faculty of Medicine, Chiang Mai University, Chiang Mai, Thailand

** Division of Hematology, Department of Internal Medicine, Faculty of Medicine, Chiang Mai University, Chiang Mai, Thailand

*** Department of Pathology, Faculty of Medicine, Chiang Mai University, Chiang Mai, Thailand

Primary thyroid lymphoma (PTL) is a rare cause of malignancy that occurs in 0.5% of cases with Hashimoto's thyroiditis. The most common subtype is diffuse large B-cell lymphoma (DLBCL), followed by mucosa-associated lymphoid tissue (MALT) lymphoma. We described the case of a 70-year-old man who was diagnosed with MALT lymphoma in the background of autoimmune thyroiditis with focal area of DLBCL transformation. The patient was a 70-year-old man with rapidly growing mass of the thyroid gland with compressive symptom over two months. The laboratory data revealed primary hypothyroidism with positively anti-thyroid antibodies. The computerized tomography scan showed right thyroid mass extended to anterior mediastinum and compressed adjacent airway with multiple cervical and mediastinal lymphadenopathies. The pathology from incisional biopsy showed extranodal marginal zone B-cell lymphoma of MALT lymphoma with large cell transformation. The patient received four courses of systemic chemotherapy combined with involved field radiation therapy. The mass was dramatically decreased in size after treatment, leading to a complete resolution of compressive symptoms. Thyroid lymphoma is quite rare; however, the incidence may be higher in patients with Hashimoto's thyroiditis. A rapidly growing thyroid gland should be considered as PTL. Chemotherapy and radiation are the mainstays of treatment.

Keywords: Mucosa-associated lymphoid tissue lymphoma, Large cell transformation, Diffuse large B-cell lymphoma, Primary thyroid lymphoma, Hashimoto's thyroiditis

J Med Assoc Thai 2015; 98 (5): 514-9

Full text. e-Journal: <http://www.jmatonline.com>

Primary thyroid lymphoma (PTL) is a rare cause of malignancy, accounting for approximately 2-8% of all thyroid malignancies and 1 to 2% of all extranodal lymphomas⁽¹⁻⁵⁾. The annual incidence rate is estimated to be 2.1 per million persons. Women are more predominately affected two to eight times than men⁽⁶⁾. Typically, patients present in the sixth or seventh decade of life^(7,8). Most PTL is non-Hodgkin's lymphomas (NHL) of B cell origin. Occasionally T-cell lymphomas have been reported⁽⁹⁾. The most common subtype of PTL is diffuse large B-cell lymphoma (DLBCL) followed by a less invasive form named mucosa-associated lymphoid tissue (MALT) lymphoma^(5,8,10). The pathological diagnosis of PTL in Hashimoto's thyroiditis includes MALT lymphoma

(47%), DLBCL (43%), and DLBCL with MALT lymphoma (8%)⁽¹¹⁾. Since MALT lymphoma can progressively transform to be DLBCL, both tumors type can be found within the same thyroid gland in one third of cases⁽¹²⁾. Most cases of PTL arise in a background of thyroiditis approximately 60 to 90% of PTL cases^(5,6,11,13). MALT lymphoma and PTL tend to arise in the thyroid gland, which has the pathology of Hashimoto's thyroiditis. Evidence shows that MALT lymphoma and PTL occur in 0.5% and 0.3% of the cases with long-standing Hashimoto's thyroiditis respectively^(11,14,15). According to the previous studies, the average onset of PTL after Hashimoto's thyroiditis is 4 to 9 years (range 1-362 months)^(6,11,13). In addition, the concurrent diagnosis of PTL and Hashimoto's thyroiditis is 0.3% in the first visit⁽¹¹⁾.

The typical clinical presentation includes an enlarging neck mass, dysphagia, hoarseness, stridor, dyspnea, and pain. The rapidly enlarging neck mass should be suspected of PTL, and has been reported more than 70% of cases in DLBCL^(5,12). One-third of

Correspondence to:

Hengjeerajarus N, Division of Endocrinology and Metabolism, Department of Internal Medicine, Faculty of Medicine, Chiang Mai University, Chiang Mai 50200, Thailand.

Phone: +66-53-946453

E-mail: tnatavuth@gmail.com

patients have compressive symptoms. However, B-symptoms, mostly presented in lymphoma, are less common occurrence in 10% of patients⁽¹⁰⁾. The symptoms of hypothyroidism related to Hashimoto's thyroiditis are presented only in one-half of patients before the clinical manifestation of PTL^(6,14,16). The diagnosis is difficult based on the morphological and clinical characteristics. Southern blot, flow cytometry, and polymerase chain reaction (PCR) are needed to confirm the diagnosis⁽¹⁷⁾. In the present study, we described a 70-year-old man who was diagnosed as MALT lymphoma in the background of autoimmune thyroiditis with focal area of DLBCL transformation.

Case Report

A 70-year-old man without previous history of goiter was referred to our hospital for further evaluation of a rapidly growing mass of thyroid gland associated with gradually increased difficulty to breathe and swallow over two months. He denied palpitation, fatigue, cold or heat intolerance, hoarseness, fever, night sweats, and weight loss. Vital signs were normal. The neck examination revealed a smooth surface, firm, fixed, non-tender thyroid gland, and the right lobe was larger than left lobe. The estimated size was approximately 80 grams. Pemperton's sign was negative. Laboratory evaluations revealed high thyroid stimulating hormone (TSH) level of 85.12 uU/ml (normal range 0.27-4.2 uU/ml), low free T3 level of 0.08 ng/dl (normal range 0.18-0.46 ng/dl) and low free T4 level of 0.3 ng/dl (normal range 0.9-1.7 ng/dl). Anti-thyroid peroxidase antibodies were positive (158.3 IU/ml, normal range 0-40 IU/ml) but anti-thyroglobulin antibodies were negative (55.6 IU/ml, normal range 0-125 IU/ml). An initial diagnosis of Hashimoto's thyroiditis was made and levothyroxine therapy was started. The ultrasound and computerized tomography (CT) scan of the neck, chest, and abdomen showed right thyroid mass extended to anterior mediastinum approximately 10x16 cm². The adjacent airway was displaced to the left. Multiple cervical and mediastinal lymph nodes were significantly detected. No distant metastasis was detected. A fine needle aspiration (FNA) biopsy of right thyroid mass was performed, and it revealed a mixed population of lymphoid cells. Most of the cells were immunoreactive with cluster of differentiation (CD) antigen-20. The incisional biopsy was done and the pathology showed extranodal marginal zone B-cell lymphoma of mucosa associated lymphoid tissue (MALT) lymphoma with focal area of large cell transformation (Fig. 1). The

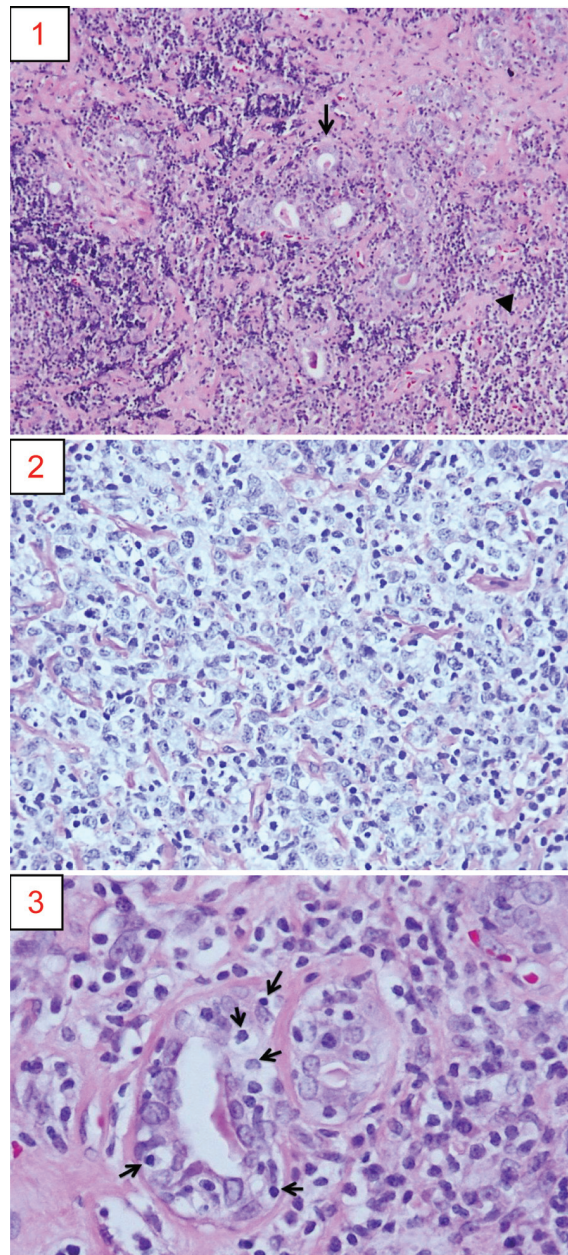


Fig. 1 The thyroid pathology. 1) Mucosa-associated lymphoid tissue lymphoma involving thyroid gland arising in background of chronic lymphocytic thyroiditis. The residual thyroid follicles are separated by the neoplastic lymphocytes; thyroid follicles (arrow), and neoplastic lymphoid cells (arrow head). 2) Area of large cell transformation of MALT lymphoma. 3) The neoplastic marginal zone cells infiltrate into thyroid follicle, forming lymphoepithelial lesion making; neoplastic lymphoid cells (arrow).

immunohistochemical stains revealed CD20(+), CD5(-), CD10(-), CD23(-), Bcl-6(-), CyclinD1(-) and Ki-67 of 50% in the area of large cell transformation (Fig. 2). Bone marrow biopsy reported hypocellular marrow correlated with aging without evidence of lymphoma involvement. The diagnosis was primary thyroid MALT lymphoma with large cell transformation on the background of Hashimoto's thyroiditis. According to Ann Arbor staging for PTL^(18,19), this patient was stage II_{EX}. Because of its aggressive nature of large cell transformation, the patient received multiagent chemotherapy consisted of Cyclophosphamide, Doxorubicin, Vincristine, Prednisolone in combination with Rituximab (R-CHOP). Four courses of R-CHOP combined with involved field radiation therapy (RT) at the bulky diseases were performed. After treatment, the mass was dramatic response and complete resolution of compressive symptoms.

Discussion

The present report referred to a patient with thyroid MALT lymphoma with large cell transformation on the background of Hashimoto's thyroiditis. The most striking clinical feature in this patient's presentation was rapid, non-tender enlargement of the thyroid. This is a characteristic feature of thyroid lymphoma⁽²⁰⁾. Compressive symptoms, seen in up to

30% of patient⁽⁶⁾, were found in our patient. The thyroid lymphoma usually presents in the elderly like this patient. Additionally, woman is more common while our case is a man. But men with thyroid MALT lymphoma exhibit a worse prognosis, compared to the well differentiated thyroid cancer^(2,3,7,8,12,17). The laboratory data support the diagnosis of Hashimoto's thyroiditis, which seems to be a risk factor for the development of thyroid MALT lymphoma^(11,14). MALT lymphoma itself can turn to DLBCL and is found together about 30%⁽¹²⁾. The concurrence of thyroid MALT lymphoma and Hashimoto's thyroiditis makes the diagnosis of lymphoma more difficult. In Hashimoto's thyroiditis, the pathological finding includes small lymphocytes, Hurthle cells, florid lymphoid hyperplasia with expanded germinal centers and increased interstitial connective tissue. However, MALT lymphomas can have a heterogeneous appearance but are generally high cellularity, with a prominent population of intermediate-sized lymphoid cells, lymphoepithelial lesions, reactive lymphoid follicle as well as a large plasma cell component. DLBCL appears uniformly large, abnormal lymphoid cells with lymphoepithelial foci and decreased or absent colloid⁽²¹⁻²³⁾. There are still challenges in FNA diagnosis of thyroid lymphoma, particularly due to the histological similarities with thyroiditis and the high

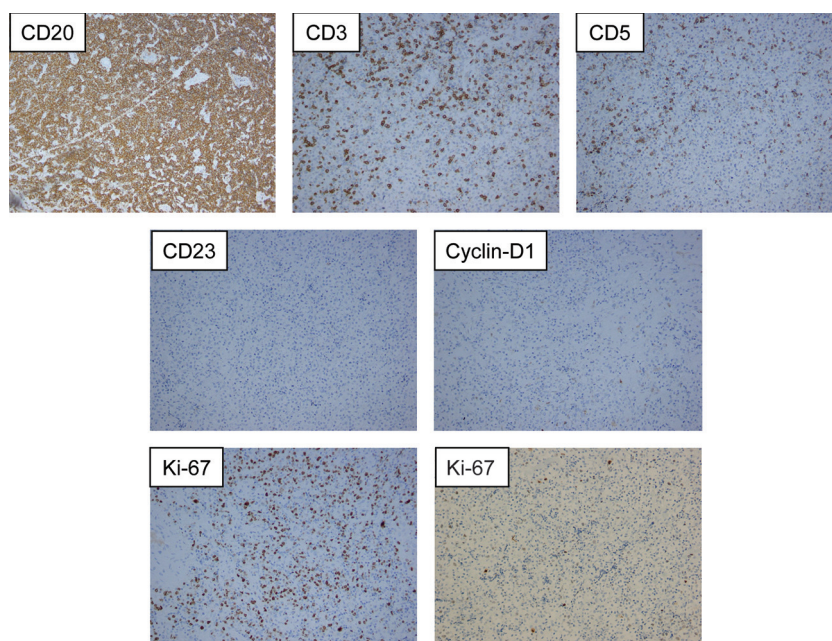


Fig. 2 The immunohistochemical stains. The neoplastic cells express CD 20 but have no reactivity to CD3, CD5, CD23, and Cyclin-D1. The Ki-67 labeling index approaches 50% (left) and less than 30% (right) of area of large cell transformation.

coincidence of these pathologies within the same gland, resulted in the increased false-negative rates from sampling error⁽²¹⁻²³⁾. The immunohistochemistry has improved the accuracy of cytology in diagnosing lymphoma. No specific immunohistochemical marker has yet been identified for MALT lymphoma, but evaluation of a panel of immunohistochemistry is necessary for assessment of the architecture of the lymphoid infiltrate, lineage assignment, and for the exclusion of other lymphomas⁽²⁴⁾. The presence of B-cell antigens such as CD19 and CD20 helps to identify a B-cell lineage of the lymphoid cells. The presence of an extensive, dense, diffuse infiltration of CD20(+) B cells between thyroid glands is highly suggestive of lymphoma. Moreover, immunohistochemistry was helpful in excluding follicular lymphoma, which exhibits a CD10 marker⁽¹²⁾. Negative results of CD5, CD10, CD23, CyclinD1, and BCL-6 can be helpful to exclude other small B cell lymphomas such as chronic lymphocytic leukemia/small lymphocytic lymphoma (CLL/SLL), follicular lymphoma, and mantle cell lymphoma. Staining for CK demonstrates the lymphoepithelial lesions and remnants of epithelial cell. The Ki-67 is low in MALT lymphoma but high in area of large cell transformation. In our case, pathology revealed intermediate-sized lymphoid cells with lymphoepithelial lesion, stained by CK that meant MALT lymphoma. It was confirmed as B-cell in origin by immunoreaction with CD20. In the same gland, tissue also showed large-sized abnormal lymphoid cells in transformation, referred to DLBCL. In addition, the Ki-67 labeling index approaching 50% in area of large cell transformation prefers DLBCL than MALT lymphoma, which Ki-67 approaches less than 30% (Fig. 2). The staging was made by CT scan of neck to abdomen and bone marrow biopsy resulting stage II_{EX} (E: extranodal origin, X: bulky >10 cm). When determining a treatment plan, the histology and staging need to be considered. There are no randomized, controlled trials evaluating the efficacy of different treatment options in PTL; therefore, the current evidences are mostly derived from retrospective studies and from the studies of extranodal NHLs⁽⁹⁾. However, with high relapse rates, low survival rates, and the realization that thyroid lymphoma is sensitive to chemotherapy and radiation making surgery play a limited role^(25,26). Among those with aggressive PTL either stage IE or IIE, like this patient, the combined modality treatment (CMT) significantly improved overall survival (OS), disease-free survival and local control more than those of

either RT or chemotherapy alone⁽²⁷⁾. The addition of Rituximab to CHOP improved OS compared with CHOP alone⁽²⁷⁻²⁹⁾. Matsuzuka et al, described a report of 119 patients with intermediated grade, stage IIE PTL treated with six courses of CHOP combined with RT had 100% survival rate at 8 years⁽¹⁷⁾. Surgery in aggressive disease is used for improvement of compressive symptom or protection of the airway^(9,30).

Conclusion

The present case demonstrated a male patient with MALT lymphoma with large cell transformation on the background of Hashimoto's thyroiditis. Thyroid lymphoma is quite rare; however, the incidence is higher in patients with a history of Hashimoto's thyroiditis. A rapidly growing thyroid gland should be considered of lymphoma of the thyroid as a diagnosis. Diagnosis can be made by FNA with immunohistochemistry to improve accuracy. Chemotherapy and radiation are the mainstays of treatment^(12,30).

What is already known on this topic?

PTL is a rare cause of thyroid malignancy and extranodal lymphoma. It should be suspected in patient with rapidly enlarging neck mass especially with a history of Hashimoto's thyroiditis. The most common subtype of PTL is DLBCL, followed by MALT lymphoma. MALT lymphoma can transform into DLBCL and occurs in the cases of Hashimoto's thyroiditis. Wanatabe et al, reviewed 171 patients with PTL and 24,553 patients with Hashimoto's thyroiditis. The pathological diagnosis included DLBCL 43%, MALT lymphoma with DLBCL 8%, MALT lymphoma 47% and others 2%⁽¹¹⁾. That means, MALT lymphoma with DLBCL is a rare pathology of PTL in Hashimoto's thyroiditis patient.

What this study adds?

This patient showed the MALT lymphoma with large cell transformation of DLBCL in the same gland of Hashimoto's thyroiditis background. Patient with rapidly enlarging neck mass should be suspected of PTL. Majority of patient will come with compressive symptom and positively Pemperton's sign. However, this case had right thyroid mass extending to anterior mediastinum approximately 10x16 cm² without the sign of Pemperton. A FNA biopsy of right thyroid mass revealed a mixed population of lymphoid cells, but the incisional biopsy showed extranodal marginal zone B-cell lymphoma of MALT lymphoma with focal area

of large cell transformation. There are still challenges in FNA diagnosis of thyroid lymphoma, particularly due to the histological similarities with thyroiditis and the high coincidence of these pathologies within the same gland, resulted in the increased false-negative rates from sampling error. The immunohistochemistry is helpful.

Potential conflicts of interest

None.

References

1. Widder S, Pasięka JL. Primary thyroid lymphomas. *Curr Treat Options Oncol* 2004; 5: 307-13.
2. Malek SN, Hatfield AJ, Flinn IW. MALT Lymphomas. *Curr Treat Options Oncol* 2003; 4: 269-79.
3. Ansell SM, Grant CS, Habermann TM. Primary thyroid lymphoma. *Semin Oncol* 1999; 26: 316-23.
4. Freeman C, Berg JW, Cutler SJ. Occurrence and prognosis of extranodal lymphomas. *Cancer* 1972; 29: 252-60.
5. Thieblemont C, Mayer A, Dumontet C, Barbier Y, Callet-Bauchu E, Felman P, et al. Primary thyroid lymphoma is a heterogeneous disease. *J Clin Endocrinol Metab* 2002; 87: 105-11.
6. Pedersen RK, Pedersen NT. Primary non-Hodgkin's lymphoma of the thyroid gland: a population based study. *Histopathology* 1996; 28: 25-32.
7. Sarinah B, Hisham AN. Primary lymphoma of the thyroid: diagnostic and therapeutic considerations. *Asian J Surg* 2010; 33: 20-4.
8. Graff-Baker A, Roman SA, Thomas DC, Udelsman R, Sosa JA. Prognosis of primary thyroid lymphoma: demographic, clinical, and pathologic predictors of survival in 1,408 cases. *Surgery* 2009; 146: 1105-15.
9. Stein SA, Wartofsky L. Primary thyroid lymphoma: a clinical review. *J Clin Endocrinol Metab* 2013; 98: 3131-8.
10. Alzouebi M, Goepel JR, Horsman JM, Hancock BW. Primary thyroid lymphoma: the 40 year experience of a UK lymphoma treatment centre. *Int J Oncol* 2012; 40: 2075-80.
11. Watanabe N, Noh JY, Narimatsu H, Takeuchi K, Yamaguchi T, Kameyama K, et al. Clinicopathological features of 171 cases of primary thyroid lymphoma: a long-term study involving 24553 patients with Hashimoto's disease. *Br J Haematol* 2011; 153: 236-43.
12. Derringer GA, Thompson LD, Frommelt RA, Bijwaard KE, Heffess CS, Abbondanzo SL. Malignant lymphoma of the thyroid gland: a clinicopathologic study of 108 cases. *Am J Surg Pathol* 2000; 24: 623-39.
13. Kato I, Tajima K, Suchi T, Aozasa K, Matsuzuka F, Kuma K, et al. Chronic thyroiditis as a risk factor of B-cell lymphoma in the thyroid gland. *Jpn J Cancer Res* 1985; 76: 1085-90.
14. Holm LE, Blomgren H, Lowhagen T. Cancer risks in patients with chronic lymphocytic thyroiditis. *N Engl J Med* 1985; 312: 601-4.
15. Green LD, Mack L, Pasięka JL. Anaplastic thyroid cancer and primary thyroid lymphoma: a review of these rare thyroid malignancies. *J Surg Oncol* 2006; 94: 725-36.
16. Hyjek E, Isaacson PG. Primary B cell lymphoma of the thyroid and its relationship to Hashimoto's thyroiditis. *Hum Pathol* 1988; 19: 1315-26.
17. Matsuzuka F, Miyauchi A, Katayama S, Narabayashi I, Ikeda H, Kuma K, et al. Clinical aspects of primary thyroid lymphoma: diagnosis and treatment based on our experience of 119 cases. *Thyroid* 1993; 3: 93-9.
18. Lister TA, Crowther D, Sutcliffe SB, Glatstein E, Canellos GP, Young RC, et al. Report of a committee convened to discuss the evaluation and staging of patients with Hodgkin's disease: Cotswolds meeting. *J Clin Oncol* 1989; 7: 1630-6.
19. Carbone PP, Kaplan HS, Musshoff K, Smithers DW, Tubiana M. Report of the Committee on Hodgkin's Disease Staging Classification. *Cancer Res* 1971; 31: 1860-1.
20. Anscombe AM, Wright DH. Primary malignant lymphoma of the thyroid--a tumour of mucosa-associated lymphoid tissue: review of seventy-six cases. *Histopathology* 1985; 9: 81-97.
21. Sangalli G, Serio G, Zampatti C, Lomuscio G, Colombo L. Fine needle aspiration cytology of primary lymphoma of the thyroid: a report of 17 cases. *Cytopathology* 2001; 12: 257-63.
22. Morgen EK, Geddie W, Boerner S, Bailey D, Santos GC. The role of fine-needle aspiration in the diagnosis of thyroid lymphoma: a retrospective study of nine cases and review of published series. *J Clin Pathol* 2010; 63: 129-33.
23. Rawal A, Finn WG, Schnitzer B, Valdez R. Site-specific morphologic differences in extranodal marginal zone B-cell lymphomas. *Arch Pathol Lab Med* 2007; 131: 1673-8.

24. Bacon CM, Du MQ, Dogan A. Mucosa-associated lymphoid tissue (MALT) lymphoma: a practical guide for pathologists. *J Clin Pathol* 2007; 60: 361-72.
25. Klyachkin ML, Schwartz RW, Cibull M, Munn RK, Regine WF, Kenady DE, et al. Thyroid lymphoma: is there a role for surgery? *Am Surg* 1998; 64: 234-8.
26. Blair TJ, Evans RG, Buskirk SJ, Banks PM, Earle JD. Radiotherapeutic management of primary thyroid lymphoma. *Int J Radiat Oncol Biol Phys* 1985; 11: 365-70.
27. Onal C, Li YX, Miller RC, Poortmans P, Constantinou N, Weber DC, et al. Treatment results and prognostic factors in primary thyroid lymphoma patients: a rare cancer network study. *Ann Oncol* 2011; 22: 156-64.
28. Doria R, Jekel JF, Cooper DL. Thyroid lymphoma. The case for combined modality therapy. *Cancer* 1994; 73: 200-6.
29. Miller TP, Dahlberg S, Cassady JR, Adelstein DJ, Spier CM, Grogan TM, et al. Chemotherapy alone compared with chemotherapy plus radiotherapy for localized intermediate- and high-grade non-Hodgkin's lymphoma. *N Engl J Med* 1998; 339: 21-6.
30. Sippel RS, Gauger PG, Angelos P, Thompson NW, Mack E, Chen H. Palliative thyroidectomy for malignant lymphoma of the thyroid. *Ann Surg Oncol* 2002; 9: 907-11.

มะเร็งต่อมไทรอยด์ชนิด *mucosa-associated lymphoid tissue* ที่มี *large cell transformation* ในผู้ป่วย *Hashimoto's thyroiditis*: รายงานผู้ป่วยหนึ่งรายและบททบทวนวรรณกรรม

ณัฐฤติ เสงจีระจรัส, วีรดา กล้ายสุวรรณ, ลลิตา นรเศรษฐธาดา, ณัฐพงศ์ โฆษขุนพันธ์

ผู้ป่วยชายอายุ 70 ปี มาพบแพทย์ด้วยอาการก้อนที่คอร่วมกับคลื่นและหายใจลำบากเป็นเวลาสองเดือน ตรวจร่างกายพบว่าป้อนของต่อมไทรอยด์ ผลการตรวจเลือดพบระดับ TSH สูง free T3 และ free T4 ต่ำ ร่วมกับตรวจพบ anti-thyroid antibodies ผลการตรวจทางรังสีพบก้อนจากต่อมไทรอยด์ขนาดใหญ่กดเบียดทางเดินหายใจและต่อมไทรอยด์หลายตำแหน่ง แพทย์ตัดชิ้นเนื้อส่งตรวจพยาธิวิทยาพบ *extranodal marginal zone B-cell lymphoma of MALT lymphoma with focal area of large cell transformation* ผู้ป่วยได้รับการรักษาด้วยเคมีบำบัดร่วมกับการฉายรังสีรักษาบริเวณก้อนดังกล่าว ภายหลังการรักษาก้อนยุบลงและอาการต่างๆ หายไป จากผู้ป่วยรายนี้เมื่อทบทวนวรรณกรรมพบว่า *primary thyroid lymphoma* เป็นมะเร็งชนิดที่พบบได้น้อย ส่วนใหญ่เป็น *non-Hodgkin's lymphomas* จาก B-cell ที่ผิดปกติ โดยพบ *diffuse large B-cell lymphoma (DLBCL)* มากที่สุด รองลงมาคือ *mucosa-associated lymphoid tissue (MALT) lymphoma* ซึ่ง *MALT lymphoma* เองสามารถพัฒนาไปเป็น *DLBCL* ได้ นอกจากนี้ *MALT lymphoma* ยังเกิดจาก *Hashimoto's thyroiditis* ได้ ประมาณ 5% ดังผู้ป่วยรายนี้ การรักษาหลัก คือ การให้เคมีบำบัดร่วมกับรังสีรักษา