

# Assessment of Brain Computed Tomography as a Practical Way to Predict Neurological Outcomes in Post-Cardiac Arrest Survivors

Sekh Thanprasertsuk, MD<sup>1,2,3</sup>, Chattarin Pongtubtim<sup>2,4</sup>, Suppavit Chumsantivut<sup>2,4,5</sup>, Nithit Singtokum<sup>2,4</sup>, Kanathip Jongmekwamsuk<sup>2,4</sup>, Rawiwan Thanprasertsuk, MD<sup>6,7</sup>, Weerapat Kositanurit, MD<sup>1</sup>, Kasiphak Kaikaew, MD, PhD<sup>1</sup>

<sup>1</sup> Department of Physiology, Faculty of Medicine, Chulalongkorn University, Bangkok, Thailand; <sup>2</sup> Chulalongkorn Cognitive Clinical and Computational Neuroscience (CCCN) Research Unit, Chulalongkorn University, Bangkok, Thailand; <sup>3</sup> Chula Neuroscience Center, King Chulalongkorn Memorial Hospital, Thai Red Cross Society, Bangkok, Thailand; <sup>4</sup> Medical student, Faculty of Medicine, Chulalongkorn University, Bangkok, Thailand; <sup>5</sup> Bhumibol Adulyadej Hospital, Bangkok, Thailand; <sup>6</sup> Department of Anesthesiology, Faculty of Medicine, Chulalongkorn University, Bangkok, Thailand; <sup>7</sup> Cardiovascular and Thoracic Anesthesia Unit, King Chulalongkorn Memorial Hospital, Bangkok, Thailand

**Objective:** To evaluate whether a visual inspection of ischemic changes in brain computed tomography (CT) images, which is very practical in clinical settings, could predict neurological outcomes in post-cardiac arrest survivors.

**Materials and Methods:** The authors retrospectively reviewed medical records and brain CT images of 62 patients who remained comatose after surviving cardiac arrest and had undergone a CT scan within 24 hours to seven days. Neurological outcomes at one month were assessed using the Cerebral Performance Category (CPC). The CPC scores of 1-2 and 3-5 referred to good and poor neurological outcomes, respectively. Findings from the inspection of the images were graded into grade 1 for absence of acute ischemic change, grade 2 for decreased attenuation of the grey matter in some brain region(s), and grade 3 for diffused loss of grey-white matter differentiation or apparent brain swelling. An experienced neurologist and a consensus group of four pre-clerkship medical students, blinded to the neurological outcomes, evaluated the grade of ischemic changes in CT images.

**Results:** Positive correlations were observed between CPC and CT grading by both the neurologist ( $\rho=0.76$ , 95% CI 0.63 to 0.90,  $p<0.001$ ) and medical students ( $\rho=0.57$ , 95% CI 0.38 to 0.77,  $p<0.001$ ). The CT grading of 2 or more by the neurologist could predict poor neurological outcomes with specificity of 1.00, sensitivity of 0.89, and receiver operating characteristic (ROC) AUC of 0.94 (95% CI 0.89 to 1.00). The evaluation by medical students showed an ROC AUC of 0.80 (95% CI 0.64 to 0.96).

**Conclusion:** The simple visual inspection of ischemic changes in brain CT images showed a high diagnostic accuracy and could be a practical method for predicting neurological outcomes in post-cardiac arrest survivors.

**Keywords:** Cardiac arrest; Post-cardiac arrest ischemic brain injury; Neurological outcomes; Computerized tomography

Received 31 January 2023 | Revised 30 March 2023 | Accepted 6 April 2023

**J Med Assoc Thai 2023; 106(5): 508-14**

**Website:** <http://www.jmatonline.com>

Many patients who have a return of spontaneous circulation (ROSC) after cardiac arrest suffer from post-cardiac arrest ischemic brain injury, which is a major cause of morbidity and mortality in cardiac arrest survivors<sup>(1-3)</sup>. The accurate prediction of

neurological outcomes after surviving sudden cardiac arrest is crucial since it helps physicians decide whether to add further life-supporting measures or withdraw any futile therapy.

Brain injury caused by the ischemic process tends to affect the grey matter more than the white matter, as the grey matter is where the neuronal cell bodies are harbored. As a result, ischemic changes in patients with diffused cerebral ischemia are more visible, easier to detect, in the grey matter than in the white matter<sup>(2,4,5)</sup>. The assessment of the grey-white matter ratio (GWR) in brain computed tomography (CT) images has been proven to be an accurate technique to predict neurological outcomes in cardiac arrest survivors<sup>(6-9)</sup>. Briefly, this technique measures and compares attenuation values in Hounsfield units (HU) in the grey and white matters<sup>(6)</sup>. Normally,

## Correspondence to:

Thanprasertsuk S.

Department of Physiology, Faculty of Medicine, Chulalongkorn University, 1873 Rama 4 Road, Pathumwan, Bangkok 10330, Thailand.

Phone: +66-2-2564267, Fax: +66-2-2564267

Email: Sekhac120@gmail.com

## How to cite this article:

Thanprasertsuk S, Pongtubtim C, Chumsantivut S, Singtokum N, Jongmekwamsuk K, Thanprasertsuk R, et al. Assessment of Brain Computed Tomography as a Practical Way to Predict Neurological Outcomes in Post-Cardiac Arrest Survivors. *J Med Assoc Thai* 2023; 106:508-14.

DOI: 10.35755/jmedassocthai.2023.05.13763

the grey matter has a higher attenuation value than the white matter due to a difference in biochemical properties. When there is cellular swelling due to an ischemic process, the attenuation values will be reduced more substantially in the grey matter than in the white matter. Thus, a decrease in the GWR has been considered a poor prognostic factor of neurological outcomes in cardiac arrest survivors.

However, the use of the determination of GWR in brain CT images may have limitations in clinical settings as this technique requires expertise and the standard protocol is complicated. There has been a report studying a simplified GWR, which showed a consistent result with the original GWR in terms of neurological outcome prediction<sup>(10)</sup>. To address the clinical practicality more concisely, the authors applied the technique of GWR by visually inspecting the brain CT images without measuring the attenuation values. The authors aimed to evaluate whether a simple visual inspection of brain CT images, comparing the ischemic changes between the grey matter and the white matter, helps predict neurological outcomes in cardiac arrest survivors. In the present study, brain CT images were inspected by two independent assessors, a neurologist, and a group of trained pre-clerkship medical students.

## Materials and Methods

### Study population

The authors retrospectively reviewed the medical records and brain CT images of patients aged 15 to 85 years old admitted to King Chulalongkorn Memorial Hospital between 2015 and 2020. The patients had to be diagnosed with sudden cardiac arrest due to acute cardiac disorders or acute hypoxia, had ROSC within 60 minutes after cardiopulmonary resuscitation (CPR), and remained comatose after ROSC. Additionally, the CT scan of the brain in these patients had to be obtained between 24 hours and seven days after the onset of cardiac arrest. Patients were excluded if 1) they had preceding cardiac arrest in the current admission, 2) they had suspicious clues of any other serious medical illness potentially causing cardiac arrest, such as sepsis, 3) they had a history of cancer, or 4) their brain CT images had a presence of substantial artifact(s), large territorial lesion(s), or extensive confluent areas of subcortical white matter lesions equivalent to the Fazekas scale of 3<sup>(11)</sup>.

### Standard protocol approval

The present study was approved by the

Institutional Review Board of the Faculty of Medicine, Chulalongkorn University (IRB No. 622/65).

### Assessment of neurological outcomes

Neurological outcomes were assessed one month after the onset of cardiac arrest using the Cerebral Performance Category (CPC). Briefly, the CPC score of 1 indicated normal or nearly normal neurological functions, the CPC score of 2 indicated neurological deficits not interfering with daily life, the CPC score of 3 indicated neurological deficits interfering with daily life, the CPC score of 4 indicated coma or persistent vegetative state, and the CPC score of 5 indicated brain death<sup>(12,13)</sup>. Patients diagnosed as brain death before one month after the onset of cardiac arrest were classified as CPC 5.

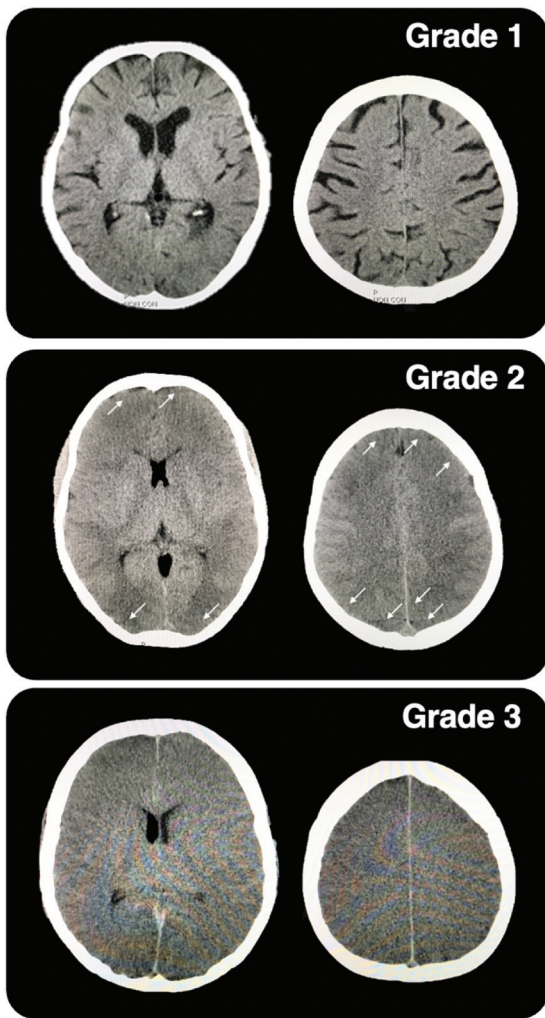
### Assessment of ischemic changes in brain CT images

To be consistent with the basis of GWR technique, brain CT images with a slice thickness of 1 mm were visually inspected for acute ischemic changes by comparing the grey matter and the white matter. Window width and level were adjusted to 80 and 40 HU, respectively. The simple inspections focused on the basal ganglia and the high level of the cerebral cortex according to the simplified GWR technique<sup>(10)</sup>. Findings from the inspection of the images were graded into grade 1 for absence of obvious acute ischemic change, grade 2 for obvious decreased attenuation of the grey matter in some brain region(s), and grade 3 for obvious diffused loss of grey-white matter differentiation or apparent brain swelling (Figure 1).

The simple visual inspection of the brain CT images was performed by two independent assessors, an experienced neurologist with 11 years of experience in the fields of neuroimaging research and clinical neurology, and a consensus group of four medical students. The medical students were in the last pre-clerkship years, had finished the Basic Neuroscience and the Clinical Neuroscience courses, and had been trained to rate the images. They had to complete rating a set of sample images before becoming assessors. All assessors were blinded to other clinical data before and during the process of visual inspection.

### Statistical analyses

Baseline characteristics of the patients were compared across each CPC using one-way ANOVA, Kruskal-Wallis test, or chi-square test. The correlation



**Figure 1.** Grading ischemic changes in brain ct images by simple visual inspection. Grade 1 refers to the absence of obvious acute ischemic change; grade 2 refers to obvious decreased attenuation of the grey matter in some brain regions (white arrows); and grade 3 refers to an obvious diffused loss of grey-white matter differentiation or apparent brain swelling.

between CPCs and the grades of brain CT images was analyzed using Spearman's correlation analysis. Receiver operating characteristic (ROC) curve analyses were used to determine the performance of the brain CT grades in predicting poor neurological outcomes at each cut-off value. The poor neurological outcome was defined as the CPC scores of 3 to 5<sup>(14-16)</sup>. In the present study, the authors also performed further ROC analysis by defining the poor neurological outcome as the CPC scores of 4 to 5. The Kappa statistic was used to determine the inter-rater agreement between the brain CT grades assessed by the neurologist and those assessed by the medical students, as well as the intra-rater agreements. All statistical analyses were performed in IBM SPSS Statistics, version 22.0 (IBM Corp., Armonk, NY, USA). Statistical significance was considered when p-value was less than 0.05.

## Results

### Baseline characteristics

Sixty-two patients with a mean age of 53.4±19.9 years were eligible for the present study, 25 (40.3%) were female. Causes of cardiac arrest were identified as the cardiac disorders in 42 (67.7%) patients and acute hypoxia in 20 (32.3%) patients. The incidence of cardiac arrest in all patients had been witnessed by bystander(s). Thirty-six (58.1%) patients underwent temperature-targeted management (TTM). At one month after cardiac arrest, five (8.1%), five (8.1%), six (9.7%), 18 (29.0%), and 28 (45.2%) patients were classified in the CPC score of 1 to 5, respectively (Table 1).

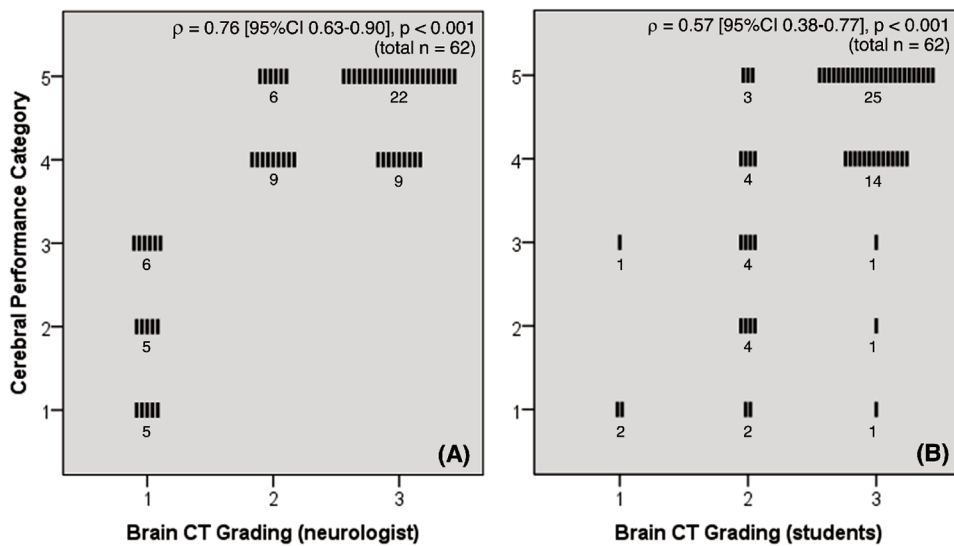
### Grading of brain CT images and distribution of the CPC across each brain CT grade

Sixteen (25.8%), 15 (24.3%), and 31 (50%) of the patients had brain CT images of grade 1, 2, and 3,

**Table 1.** Baseline characteristics of patients in each CPC

	CPC1 (n=5)	CPC2 (n=5)	CPC3 (n=6)	CPC4 (n=18)	CPC5 (n=28)	p-value
Age (years); mean±SD	62.4±8.4	75.2±7.1	59.7±17.8	49.2±23.5	49.1±18.2	0.04
Sex: female; n (%)	2 (40.0)	2 (40.0)	4 (66.7)	6 (33.3)	11 (39.3)	0.72
Cause of cardiac arrest; n (%)						0.56
Cardiac	4 (80.0)	4 (80.0)	3 (50.0)	14 (77.8)	17 (60.7)	
Hypoxic	1 (20.0)	1 (20.0)	3 (50.0)	4 (22.2)	11 (39.3)	
Witnessed arrest: yes; n (%)	5 (100)	5 (100)	6 (100)	18 (100)	28 (100)	-
Duration of CPR (minutes); median (IQR)	10.0 (4.0)	23.0 (24.0)	8.0 (19.0)	30 (25.0)	22.0 (18.0)	0.007
TTM: yes; n (%)	2 (40.0)	3 (60.0)	3 (50.0)	13 (72.2)	15 (53.6)	0.64

CPC=Cerebral Performance Category; CPR=cardiopulmonary resuscitation; IQR=interquartile range; SD=standard deviation; TTM=targeted temperature management



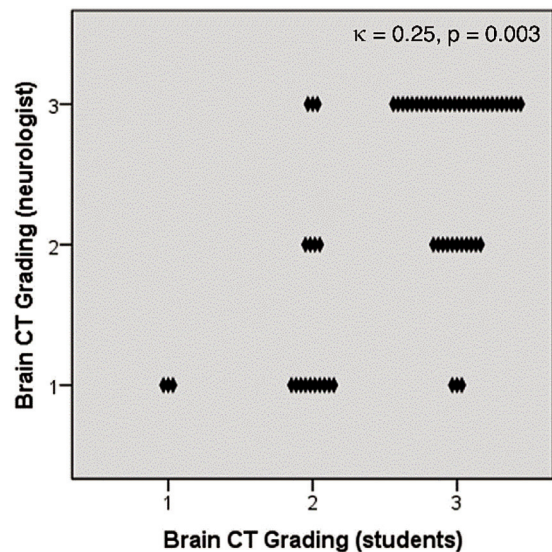
**Figure 2.** (A) Distribution of the CPC across each brain CT grade assessed by a neurologist, (B) Distribution of the CPC across each brain CT grade assessed by a consensus group of medical students.

respectively, for the assessment by neurologist. The CPC had a strong positive correlation with the brain CT grade ( $\rho=0.76$ , 95% CI 0.63 to 0.90,  $p<0.001$ ) (Figure 2A). For the assessment by the consensus group of medical students, three (4.8%), 17 (27.4%), and 42 (67.7%) of the patients were rated as grade 1, 2, and 3, respectively, with a moderate positive correlation with the CPC ( $\rho=0.57$ , 95% CI 0.38 to 0.77,  $p<0.001$ ) (Figure 2B). Grading of the brain CT images by the neurologist and by the medical students had a fair inter-rater agreement ( $\kappa=0.25$ ,  $p=0.003$ ) (Figure 3). The intra-rater agreement was perfect for the assessment by the neurologist ( $\kappa=1.00$ ,  $p<0.001$ ), and was substantial for the assessment by medical students ( $\kappa=0.79$ ,  $p<0.001$ ).

### Predictive performance of brain CT grades on poor neurological outcomes

Given that patients with the CPC scores of 3 to 5 referred to poor neurological outcomes, the brain CT grades assessed by the neurologist and by the medical students had ROC AUCs of 0.94 (95% CI 0.89 to 1.00) and 0.80 (95% CI 0.64 to 0.96), respectively (Figure 4A, Table 2). Based on the ROC analysis, the CT grading of 2 or more by the neurologist was predictive of poor neurological outcomes with a specificity of 1.00 and a sensitivity of 0.89 (Table 2).

In another ROC analysis given that patients with the CPC scores of 4 to 5 referred to poor neurological outcomes, the brain CT grades assessed by the neurologist and by the medical students had

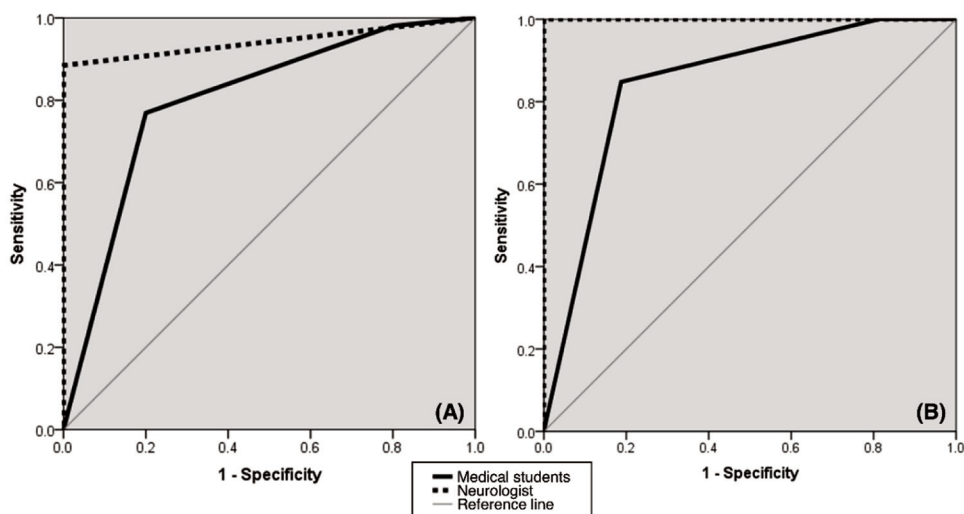


**Figure 3.** Agreement of the brain CT images grades assessed by a neurologist and by a consensus group of medical students.

ROC AUCs of 1.00 and 0.84 (95% CI 0.72 to 0.97), respectively (Figure 4B, Table 3). When graded by the neurologist, the CT grading of 2 or more was predictive of poor neurological outcomes with 100% specificity and 100% sensitivity (Table 3).

### Discussion

The main finding of the present study demonstrates the predictive capacity of visual inspection of brain CT images for poor neurological outcomes. When assessed by an experienced



**Figure 4.** ROC curves of the brain CT grades assessed by a neurologist and by a consensus group of medical students for predicting poor neurological outcomes: (A) defining CPC 3 to 5 as poor neurological outcomes, (B) defining CPC 4 to 5 as poor neurological outcomes.

**Table 2.** ROC analysis prediction of poor neurological outcomes (CPC 3-5) using the brain CT grades assessed by a neurologist and by a consensus group of medical students

Assessors of the brain CT images	Cut-off value	Sensitivity (%)	Specificity (%)	PPV (%)	NPV (%)	AUC (95% CI)	p-value
Neurologist	≥2	88.5	100	100	62.5	0.94 (0.89 to 1.00)	<0.001
	3	59.6	100	100	32.3		
Medical students	≥2	98.1	20.0	86.4	66.7	0.80 (0.64 to 0.96)	0.003
	3	76.9	80.0	95.2	40.0		

AUC=area under curve; CI=confidence interval; CT=computed tomography; NPV=negative predictive value; PPV=positive predictive value

**Table 3.** ROC analysis prediction of poor neurological outcomes (CPC 4-5) using the brain CT grades assessed by a neurologist and by a consensus group of medical students

Assessors of the brain CT images	Cut-off value	Sensitivity (%)	Specificity (%)	PPV (%)	NPV (%)	AUC (95% CI)	p-value
Neurologist	≥2	100	100	100	100	1.00	<0.001
	3	67.4	100	100	51.6		
Medical students	≥2	100	18.7	80.0	100	0.84 (0.72 to 0.97)	<0.001
	3	84.8	81.2	92.9	65.0		

AUC=area under curve; CI=confidence interval; CT=computed tomography; NPV=negative predictive value; PPV=positive predictive value

neurologist, the brain CT grade of 2 or more was predictive of poor neurological outcomes (CPC 3 to 5) at one month after cardiac arrest with high sensitivity (88.5%) and 100% specificity. Thus, ischemic changes classified as a grade of 2 or more in brain CT images obtained 24 hours to seven days after cardiac arrest are almost always suggestive of poor neurological outcomes at one month. Furthermore, this visual assessment technique can potentially be applied in daily clinical practice as a simple measure to predict poor neurological outcomes in patients surviving cardiac arrest.

The poor neurological outcome has been defined by the CPC scores of 3 to 5, and the CPC scores of 1 to 2 have been considered good neurological outcomes<sup>(14-16)</sup>. Patients with a CPC score of 3, however, are able to live independently despite physical limitations. Thus, in the authors' opinion, the CPC score of 3 is not a bad neurological outcome. Therefore, the authors performed a further analysis with a reclassification of poor neurological outcome as CPC scores of 4 to 5. In this analysis, the authors found that ischemic changes of grade 2 or more was predictive of the poor neurological outcomes with

perfect accuracy at 100% of both sensitivity and specificity, when an experienced neurologist assessed the brain CT images. In other words, some patients without any obvious ischemic change in brain CT images (grade 1) could end up with a CPC score of 3, so this reclassification of poor neurological outcomes resulted in higher sensitivity.

Additionally, the authors intentionally included pre-clerkship medical students as the other assessor of brain CT images in the present study, as aimed to explore whether this visual assessment technique of brain CT images is suitable for medical personnel without clinical expertise. The results showed that, when assessed by medical students, the visual inspection of brain CT images still had predictive capacity of the poor neurological outcomes, in both the traditional classification (the CPC scores of 3 to 5), and the authors' reclassification (the CPC scores of 4 to 5). However, overall sensitivities and specificities of grading by medical students were lower than those of an experienced neurologist. Importantly, when assessed by medical students, the brain CT images of only grade 3 appeared to be well predictive of poor neurological outcomes, suggested by high specificity and positive predictive value. In addition, the Kappa statistic showed fair inter-rater agreement between the brain CT grades assessed by a neurologist and by medical students. The authors believe that this visual assessment technique can potentially be used by medical students or physicians without advanced neurological expertise. Nevertheless, training is required before implementing this technique. In addition, more training and clinical experience in the field of neurology may improve the accuracy in outcome prediction.

Limitations of the present study included the exclusion of the brain CT images obtained less than 24 hours after cardiac arrest from the analyses. This may lead to lowered practicality in implementing this visual assessment technique in real clinical settings, as many patients had undergone brain CT scans shortly after they had ROSCs. Synaptic malfunctioning occurs just seconds after the onset of cerebral ischemia. If the ischemic process continued, failure of energy-dependent ion pumps would then follow within minutes. This would lead to cytotoxic cerebral edema, which would be visualized as the ischemic change in brain CT images within hours on the first day after the onset of ischemia<sup>(17)</sup>. The authors thus intentionally included only the brain CT images obtained more than 24 hours after cardiac arrest to ensure that the ischemic changes were

obvious. Nonetheless, the present study has many brain CT images obtained less than 24 hours after cardiac arrest and the authors plan to include these in further studies.

Additionally, other imaging modalities, such as magnetic resonance imaging, could be considered to help physicians obtain more accurate evaluations. However, performing such imaging modality is not feasible in this specific clinical setting. Another limitation is regarding the number of assessors, which should have more neurologists and medical students to increase the validity of the results. The inter-rater agreement could also be improved by selecting better groups of assessors, which would ensure that the test prediction is truly valid. In the authors' further work, we are also planning to include graduated physicians not in the field of neurology as assessors to increase the practicality of this technique in clinical settings.

## Conclusion

The present study demonstrated that ischemic changes in brain CT images observed by simple visual inspection had a high accuracy in predicting poor neurological outcomes in post-cardiac arrest survivors. This assessment is a useful and practical technique that can be applied in real-life clinical settings. Not only experienced neurologists, but also physicians in other fields and medical students, may be trained to acquire this assessment technique to their practice as an additional tool to predict poor neurological outcomes in such patients.

## What is already known on this topic?

Assessment of the GWR in brain CT images has been proven to be an accurate technique for predicting neurological outcomes in cardiac arrest survivors. However, as this technique requires expertise and the standard protocol is complicated, it may have limitations in real clinical settings.

## What this study adds?

This study demonstrated that simple visual inspection for ischemic changes in brain CT images could be used as a tool for predicting poor neurological outcomes in post-cardiac arrest survivors. The principle of this study technique is quite similar to the principle GWR assessment but is practical in real-life clinical settings.

## Authors' contributions

Study design - ST, CP, SC, NS, KJ, RT, WK, and KK; Data collection - RT, WK, and KK; Imaging

analysis - ST, CP, SC, NS, and KJ; Statistical analysis - ST, RT, WK, and KK; Manuscript preparation - ST, CP, SC, NS, and KJ; Approval of the final version of the manuscript - ST, CP, SC, NS, KJ, RT, WK, and KK.

### Conflicts of interest

All the authors have no conflict of interest.

### References

1. Laver S, Farrow C, Turner D, Nolan J. Mode of death after admission to an intensive care unit following cardiac arrest. *Intensive Care Med* 2004;30:2126-8.
2. Neumar RW, Nolan JP, Adrie C, Aibiki M, Berg RA, Böttiger BW, et al. Post-cardiac arrest syndrome: epidemiology, pathophysiology, treatment, and prognostication. A consensus statement from the International Liaison Committee on Resuscitation (American Heart Association, Australian and New Zealand Council on Resuscitation, European Resuscitation Council, Heart and Stroke Foundation of Canada, InterAmerican Heart Foundation, Resuscitation Council of Asia, and the Resuscitation Council of Southern Africa); the American Heart Association Emergency Cardiovascular Care Committee; the Council on Cardiovascular Surgery and Anesthesia; the Council on Cardiopulmonary, Perioperative, and Critical Care; the Council on Clinical Cardiology; and the Stroke Council. *Circulation* 2008;118:2452-83.
3. van Alem AP, Waalewijn RA, Koster RW, de Vos R. Assessment of quality of life and cognitive function after out-of-hospital cardiac arrest with successful resuscitation. *Am J Cardiol* 2004;93:131-5.
4. Arbelaez A, Castillo M, Mukherji SK. Diffusion-weighted MR imaging of global cerebral anoxia. *AJNR Am J Neuroradiol* 1999;20:999-1007.
5. Gutierrez LG, Rovira A, Portela LA, Leite Cda C, Lucato LT. CT and MR in non-neonatal hypoxic-ischemic encephalopathy: radiological findings with pathophysiological correlations. *Neuroradiology* 2010;52:949-76.
6. Metter RB, Rittenberger JC, Guyette FX, Callaway CW. Association between a quantitative CT scan measure of brain edema and outcome after cardiac arrest. *Resuscitation* 2011;82:1180-5.
7. Lee BK, Kim WY, Shin J, Oh JS, Wee JH, Cha KC, et al. Prognostic value of gray matter to white matter ratio in hypoxic and non-hypoxic cardiac arrest with non-cardiac etiology. *Am J Emerg Med* 2016;34:1583-8.
8. Lee YH, Oh YT, Ahn HC, Kim HS, Han SJ, Lee JJ, et al. The prognostic value of the grey-to-white matter ratio in cardiac arrest patients treated with extracorporeal membrane oxygenation. *Resuscitation* 2016;99:50-5.
9. Wang GN, Chen XF, Lv JR, Sun NN, Xu XQ, Zhang JS. The prognostic value of gray-white matter ratio on brain computed tomography in adult comatose cardiac arrest survivors. *J Chin Med Assoc* 2018;81:599-604.
10. Gentsch A, Storm C, Leithner C, Schroeder T, Ploner CJ, Hamm B, et al. Outcome prediction in patients after cardiac arrest: a simplified method for determination of gray-white matter ratio in cranial computed tomography. *Clin Neuroradiol* 2015;25:49-54.
11. Fazekas F, Chawluk JB, Alavi A, Hurtig HI, Zimmerman RA. MR signal abnormalities at 1.5 T in Alzheimer's dementia and normal aging. *AJR Am J Roentgenol* 1987;149:351-6.
12. Perkins GD, Jacobs IG, Nadkarni VM, Berg RA, Bhanji F, Biarent D, et al. Cardiac arrest and cardiopulmonary resuscitation outcome reports: Update of the utstein resuscitation registry templates for out-of-hospital cardiac arrest: A statement for healthcare professionals from a Task Force of the International Liaison Committee on Resuscitation (American Heart Association, European Resuscitation Council, Australian and New Zealand Council on Resuscitation, Heart and Stroke Foundation of Canada, InterAmerican Heart Foundation, Resuscitation Council of Southern Africa, Resuscitation Council of Asia); and the American Heart Association Emergency Cardiovascular Care Committee and the Council on Cardiopulmonary, Critical Care, Perioperative and Resuscitation. *Resuscitation* 2015;96:328-40.
13. Jennett B, Bond M. Assessment of outcome after severe brain damage. *Lancet* 1975;1:480-4.
14. Hypothermia after Cardiac Arrest Study Group. Mild therapeutic hypothermia to improve the neurologic outcome after cardiac arrest. *N Engl J Med* 2002;346:549-56.
15. Bernard SA, Gray TW, Buist MD, Jones BM, Silvester W, Gutteridge G, et al. Treatment of comatose survivors of out-of-hospital cardiac arrest with induced hypothermia. *N Engl J Med* 2002;346:557-63.
16. Nielsen N, Wetterslev J, Cronberg T, Erlinge D, Gasche Y, Hassager C, et al. Targeted temperature management at 33°C versus 36°C after cardiac arrest. *N Engl J Med* 2013;369:2197-206.
17. Keijzer HM, Hoedemaekers CWE, Meijer FJA, Tonino BAR, Klijn CJM, Hofmeijer J. Brain imaging in comatose survivors of cardiac arrest: Pathophysiological correlates and prognostic properties. *Resuscitation* 2018;133:124-36.