

# Comparative Study on the Characteristics of Meckel's Diverticulum Removal from Asymptomatic and Symptomatic Patients: 18-Year Experience from Thailand's Largest University Hospital

Varut Lohsiriwat MD, PhD\*, Thana Sirivech MD\*,  
Mongkol Laohapensang MD\*\*, Ananya Pongpaibul MD\*\*\*

\* Division of General Surgery, Department of Surgery, Faculty of Medicine Siriraj Hospital,  
Mahidol University, Bangkok, Thailand

\*\* Division of Pediatric Surgery, Department of Surgery, Faculty of Medicine Siriraj Hospital,  
Mahidol University, Bangkok, Thailand

\*\*\* Department of Pathology, Faculty of Medicine Siriraj Hospital, Mahidol University, Bangkok, Thailand

---

**Objective:** To report an experience with Meckel's diverticulum (MD) from a University Hospital in Thailand, and to compare the characteristics of MD removal from asymptomatic patients and symptomatic patients.

**Material and Method:** The authors retrospectively reviewed the medical records of patients undergoing the resection of MD between January 1994 and July 2011 at the Faculty of Medicine Siriraj Hospital, Mahidol University, Bangkok. The patients were subsequently divided into two groups. The asymptomatic group included individuals with MD that were found incidentally during the course of laparotomy performed for reasons not related to the complications of the MD. The symptomatic group included individuals presenting with complications related to the MD. Data were recorded including patient's demographics, clinical presentation, histopathologic findings, and postoperative outcomes.

**Results:** The present study included 84 patients (53 males, 63%). Of whom, 60 patients (71%) were pediatric (age <16 years) and 51 patients (61%) were symptomatic. The most common presentation of symptomatic MDs in pediatric and adult patients was lower gastrointestinal bleeding and mechanical small bowel obstruction, respectively. The correct preoperative diagnosis of MD was made in only 20 patients (39%) of the symptomatic group, all with <sup>99m</sup>Tc-pertechnetate scanning. The MDs in the symptomatic group were significantly longer with a wider base than those in the asymptomatic group, 3.2 vs. 2.0 cm in length ( $p = 0.001$ ) and 1.8 vs. 1.0 cm in width ( $p < 0.001$ ). Ectopic tissue was present more significant in the symptomatic group than in the asymptomatic group (51% vs. 12%;  $p < 0.001$ ). None of the resected MDs contained neoplasm. There was no significant difference in the morbidity or mortality rate between the symptomatic and asymptomatic groups.

**Conclusion:** The MDs in the symptomatic patients were significantly longer with a wider base than those in the asymptomatic patients. Symptomatic MDs contained ectopic tissue more frequently than asymptomatic MDs.

**Keywords:** Meckel's diverticulum, Surgery, Outcomes, Incidental finding, Ectopic tissue, Small bowel obstruction, Gastrointestinal bleeding, Thailand

*J Med Assoc Thai* 2014; 97 (5): 506-12

Full text. e-Journal: <http://www.jmatonline.com>

---

Meckel's diverticulum (MD), a remnant of the omphalomesenteric duct, is the most common congenital anomaly of the gastrointestinal tract, found in about 2% of general population<sup>(1)</sup>. Ectopic tissue, such as gastric and pancreatic mucosa, was found in 10 to 60% of the MD<sup>(2,3)</sup>. Although most people with MD remain asymptomatic during their lifetime, the

complications of MD were reported to occur in 4 to 40% of patients, particularly in male<sup>(4)</sup> and those with ectopic tissue<sup>(5,6)</sup>. The complications include diverticulitis, rectal bleeding, intussusception, small bowel obstruction and, rarely, neoplastic transformation<sup>(7,8)</sup>. Meanwhile, the management of MD in asymptomatic patients remains debatable<sup>(9,10)</sup>.

Although more than 3100 articles have been published regarding MD (according to a PubMed search for "Meckel Diverticulum" between 1947 and 2012), a relatively few studies compared the characteristics of MD removal from asymptomatic patients and symptomatic patients. Notably, most of such studies

---

**Correspondence to:**

Lohsiriwat V, Department of Surgery, Faculty of Medicine Siriraj Hospital, Mahidol University, 2 Wang Lung Road, Bangkok 10700, Thailand.

Phone: 0-2419-8005, Fax: 0-2412-1370

E-mail: [bolloon@hotmail.com](mailto:bolloon@hotmail.com)

were based on the Western population<sup>(2,3,10-13)</sup>. Since the characteristics of asymptomatic and symptomatic MD might vary among ethnics, the information of MD in Thai people would provide the basic knowledge of MD in the Eastern population.

The objectives of the present study were therefore to report the experience with MD from the largest University Hospital in Thailand, and to compare the characteristics of MD removal from asymptomatic patients and symptomatic patients.

### Material and Method

After obtaining approval from our Institutional Review Board (SIRB 248/2554), the authors retrospectively reviewed the medical records of patients whom underwent resection of MD between January 1994 and July 2011 at the Faculty of Medicine Siriraj Hospital, Mahidol University, Bangkok, Thailand. Of note, the patients were identified from a prospectively collected computer database of Department of Pathology using a keyword of 'Meckel diverticulum'. Data were recorded including patient's demographics (age, gender, comorbidities, presentation, or indication for surgery), intraoperative findings (the location of the MD, the length and base width of the MD), the method used for MD resection (simple diverticulectomy, wedge or segmental ileal resection), histopathologic findings (the presence of ectopic tissue, or inflammation), and postoperative outcomes.

The patients were subsequently divided into two groups. The asymptomatic group included individuals with MDs that were found incidentally during the course of laparotomy or had laparoscopy performed for reasons not related to the complications of the MD. The symptomatic group included individuals presenting with complications related to the MD. Meanwhile, pediatric patients were defined as patients younger than 16 years. Adult patients were defined as patients with the age of more than 16 years.

All data were prepared and compiled using Statistical Package for the Social Sciences program version 15.0 for Windows (SPSS®, SPSS Inc., Chicago, IL). The Kolmogorov-Smirnov test was used to test for the normality of data. Unpaired t-test was used to compare data between the two groups for normally distributed data. The Mann-Whitney U test was used for non-normally distributed data. The Pearson Chi-square test and Fisher's exact test were used for categorical data. A *p*-value of less than 0.05 was considered statistically significant.

## Results

### Demographic data

The present study included 84 patients (53 males, 63%). Of whom, 60 patients (71%) were pediatric and 51 patients (61%) were symptomatic. The age of the youngest and oldest patients who required an operation for symptomatic MD was two days and 73 years, respectively. The age distribution of asymptomatic and symptomatic patients is shown in Fig. 1. The ratio for symptomatic MD was 2:1 in adult patients (67% vs. 33%), and 1.4:1 in pediatric patients (59% vs. 41%). There were no significant difference in age group or gender between the asymptomatic group and the symptomatic group (Table 1).

### Clinical presentation

Among 35 pediatric patients with symptomatic MD, lower gastrointestinal bleeding was the most common presentation (22 patients, 63%), followed by localized peritonitis mimicking acute appendicitis (4 patients, 11%) and generalized peritonitis (4 patients, 11%). Among 16 adult patients with symptomatic MD, mechanical distal small bowel obstruction was the most common presentation (8 patients, 50%). Table 2 shows clinical presentation or indication for surgery in the symptomatic group. Notably, a correct preoperative diagnosis of MD was made in only 20 patients (39%) of the symptomatic group, all with <sup>99m</sup>Tc-pertechnetate scanning.

### Operative and pathologic findings

The MDs in the symptomatic group were significantly longer with a wider base than those in the asymptomatic group, 3.2±1.9 vs. 2.0±1.3 cm in

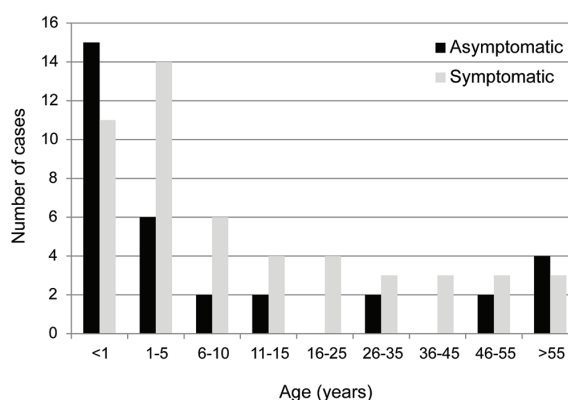


Fig. 1 The age distribution of asymptomatic and symptomatic individuals.

**Table 1.** Clinical and pathologic characteristics of the patients in asymptomatic group and symptomatic group

	Asymptomatic group (n = 33)	Symptomatic group (n = 51)	p-value
Pediatric	25 (76)	36 (71)	0.48
Male	21 (64)	32 (63)	0.93
Length of the MD (cm)	2.0±1.3	3.2±1.9	0.001
Base width of the MD (cm)	1.0±0.5	1.8±1.0	<0.001
Methods of MD resection			0.025
Simple diverticulectomy	16 (48)	13 (25)	
Wedge ileal resection	11 (33)	15 (29)	
Segmental ileal resection	6 (18)	23 (45)	
Ectopic tissue	4 (12)	26 (51)	<0.001
Postoperative complications	4 (12)	4 (8)	0.71
Postoperative death	3 (9)	1 (2)	0.30

Data were present as number (percentage), or mean ± SD  
MD = Meckel's diverticulum

**Table 2.** Clinical presentation of symptomatic Meckel's diverticulum in pediatric patients and adult patients

Pediatric (n = 35)*	Adult (n = 16)		
Lower gastrointestinal bleeding	22 (63%)	Small bowel obstruction	8 (50%)
Localized peritonitis as of appendicitis	4 (11%)	Localized peritonitis as of appendicitis	5 (31%)
Generalized peritonitis	4 (11%)	Lower gastrointestinal bleeding	2 (13%)
Small bowel obstruction	3 (9%)	Intraabdominal mass	1 (6%)
Intussusception	2 (6%)		
Intraabdominal mass	1 (3%)		
Other	2 (6%)		

\* Some pediatric patients presented with more than one symptoms

length ( $p = 0.001$ ) and  $1.8 \pm 1.0$  vs.  $1.0 \pm 0.5$  cm in width ( $p < 0.001$ ). The MD in adult patients was located between 40 cm and 80 cm from the ileocecal valve. Segmental ileal resection was the most common technique used for removal of the MDs in the symptomatic group, whereas simple diverticulectomy was more preferential in the asymptomatic group (Table 1).

Based on pathology reports, ectopic mucosa was identified in 30 patients (36%). Gastric mucosa and pancreatic mucosa were found in 28 patients (33%) and six patients (7%), respectively. Of note, four resected MD had a mixed gastric and pancreatic cell population. Of 23 bleeding diverticula, 16 (70%) contained ectopic gastric mucosa and five (22%) revealed acute ulcer. Of 13 patients presenting with localized or generalized peritonitis, nine (69%) were perforated diverticulitis, four (31%) contained ectopic gastric or pancreatic mucosa, and one (8%) had enterolith in the lumen of the MD. Ectopic tissue was

present more significantly in the symptomatic group than in the asymptomatic group (51% vs. 12%;  $p < 0.001$ ) (Table 1). None of the resected MDs in the present study contained neoplasm.

#### **Morbidity and mortality**

In the symptomatic group, there were four (8%) postoperative complications (1 superficial surgical site infection, 1 congestive heart failure, 1 metabolic acidosis, and 1 hypovolemic shock) and one (2%) death (congestive heart failure in a trisomy 13 infant). In the asymptomatic group, there were four (12%) postoperative complications (1 small bowel obstruction, 1 short bowel syndrome, 1 wound dehiscence, and 1 acute renal failure) and three (9%) deaths (1 short bowel syndrome in 2-month-old infant, 1 congestive heart failure in an infant with Down's syndrome, and 1 acute myocardial infarction). With the exception of postoperative small bowel obstruction and wound infection, the complications and death in

the asymptomatic group was attributable to patients' underlying disease and their co-morbidities, not directly to the removal of MD. There was no significant difference in the morbidity or mortality rate between the two groups (Table 1).

### Discussion

The incidence of Meckel's diverticulum (MD) in the general population was approximately 2%<sup>(1)</sup>, and most of individuals with MD were asymptomatic. The calculated lifetime risk of developing complicated MD was reported to be 4.2%<sup>(14)</sup>. In our series of 84 patients, 71% were pediatric (younger than 16 years) and 61% were symptomatic. We found that there was no significant difference in age group between the asymptomatic group and the symptomatic group. However, some authors reported a remarkably high incidence of symptomatic MD in patient with the age of <50 years<sup>(11)</sup>. It was reported that the risk of MD causing disease or complication decreased with increasing age, 3.7% likelihood at the age of 16 and 0% at the age of >75 years<sup>(15)</sup>.

In our analysis of symptomatic MD, we revealed a difference in clinical presentation between pediatric and adult patients. The most common presentation of symptomatic MDs in Thai children was lower gastrointestinal bleeding, whereas that of Thai adults was small bowel obstruction. Meanwhile, localized peritonitis mimicking acute appendicitis (Meckel's diverticulitis) was the second most common clinical presentation of symptomatic MD in both populations. These clinical presentations were similar to those reported in the literature<sup>(14,16,17)</sup>. Bleeding and diverticulitis were commonly associated with the presence of ectopic mucosa<sup>(2)</sup>. Meanwhile, intestinal obstruction may result from volvulus or internal hernia secondary to the presence of congenital omphalodiverticular band or mesodiverticular band. Intestinal stenosis following chronic diverticulitis, perforated MD with secondary adhesions, or intussusceptions with a MD as a lead point were also the possible causes of intestinal obstruction<sup>(18)</sup>. Notably, the incidences of each clinical presentation could vary depending on the age cutoff for pediatric and adult population. For example, the Mayo Clinic experience of 1,476 MDs, using the cutoff age for children at less than 11 years old, found that the most common presentation of symptomatic MDs in children was gut obstruction, followed by bleeding and diverticulitis. The present study also revealed an almost identical incidence of bleeding and guts

obstruction as the leading symptom of complicated MDs in adults<sup>(3)</sup>.

Given the rarity of MD and its non-specific symptoms, together with its difficulty in detection on traditional imaging studies, only limited number of complicated MD had been correctly diagnosed as MD preoperatively<sup>(2)</sup>. In the present series, only 20 patients (39%) of the symptomatic group had correct preoperative diagnosis; all detected with <sup>99m</sup>Tc-pertechnetate scanning and mainly during the investigation for lower gastrointestinal bleeding in children. Although <sup>99m</sup>Tc-pertechnetate scan is regarded as the most common and accurate non-invasive investigation used for detecting MD<sup>(17)</sup>, laparoscopy can be used as a diagnostic modality in doubtful cases and can perform complete resection of the lesion at the same procedure<sup>(8)</sup>. Recently, double balloon enteroscopy and capsule endoscopy have been used to help diagnose symptomatic MD with yield of 84.6% and 7.7%, respectively<sup>(19)</sup>.

The authors found that the MDs in the symptomatic group were significantly longer and had a wider base than those in the asymptomatic group. Long MDs, particularly those longer than 2 cm, were thought to be more prone to have complications due to the likelihood of intraluminal obstruction. It was reported that only 12% of MDs with the length of <2 cm became symptomatic whereas 30% of those with the length of 2 cm or more developed complications<sup>(20)</sup>. Nevertheless, complications could occur regardless of the length of MD. In the literature, many authors have recommended removing all incidental MDs with length greater than 2 cm<sup>(3,20)</sup>. Meanwhile, the decision of prophylactic diverticulectomy in asymptomatic MDs based on the diameter of MD is less convincing. Narrow-base MDs could be easily subjected to inflammation and obstruction, whereas large-base MDs were prone to foreign body entrapment<sup>(2)</sup>.

In the present study, segmental ileal resection was the most common technique used for removal of the complicated MDs, whereas simple diverticulectomy was more preferential in the uncomplicated MDs. It is advised to perform segmental bowel resection with primary anastomosis when there is macroscopic thickening or palpable heterotopic tissue at the diverticular-intestinal junction, intestinal ischemia, or perforation<sup>(17)</sup>. Many authors have recommended segmental bowel resection, rather than simple diverticulectomy, in every complicated MD because complicated MDs were likely to contain ectopic

mucosa<sup>(2)</sup> which could be non-palpable during an operation and it might be located at the base of MD<sup>(3)</sup>.

Reportedly about 10-65% of MDs contained ectopic tissues such as gastric mucosa, duodenal mucosa, pancreatic tissue, and carcinoid cells<sup>(2,3,18)</sup>. In accordance to other reports<sup>(2,3,9)</sup>, we found that ectopic tissue was present more significantly in the symptomatic group than in the asymptomatic group. Gastric mucosa and pancreatic mucosa were the two leading ectopic tissues found in both symptomatic and asymptomatic patients. Up to 80% of bleeding MDs were reported to contain ectopic gastric mucosa<sup>(3)</sup>. Interestingly, MD may contain more than one type of ectopic tissue; four of resected MDs in the present study had mixed gastric and pancreatic cell population. Regarding malignant change in the MD, none of the resected MDs in the present study contained neoplasm. In the literature, malignant transformation from an MD is uncommon (about 0.5-3.2%). These malignancies included leiomyosarcoma, carcinoid tumor, adenocarcinoma, and gastrointestinal stromal tumor<sup>(7,21)</sup>. The malignant lesions tended to occur in old patients.

Our analysis did not attempt to solve the problem of whether MD found incidentally should be removed or not. However, we found that the removal of asymptomatic MD did not significantly increase postoperative morbidity or mortality. A good evidence from an extensive study of MDs in the Mayo Clinic supported a selective approach to MD incidentally discovered during an operation, in which the incidental resection of MD should be considered in males, patients younger than 50 years, MD length greater than 2 cm, and the presence of ectopic tissue<sup>(3)</sup>. A simple diverticulectomy (either handsewn or stapled closure) should be sufficient in this regard unless there is a palpable mass at the base of MD.

In conclusion, the characteristics of resected MDs in Thai patients were comparable to those reported from the Western population<sup>(2,3,10-13)</sup>. Namely, most symptomatic or complicated MDs were resected in the first five years of life, and were more likely to have ectopic tissue and to be wider necked. According to the present series, the most common presentation of symptomatic MDs was lower gastrointestinal bleeding in Thai pediatric group, and small bowel obstruction in Thai adults. Lastly, there was no significant difference in postoperative morbidity or mortality rate between the symptomatic and asymptomatic groups.

### **What is already known on this topic?**

Meckel's diverticulum (MD) is the most common congenital anomaly of the gastrointestinal tract. Most people with MD are asymptomatic but the complications of MD were reported to occur in four to 40% of patients. The management of MD in asymptomatic patients (i.e. incidental finding) remains debatable. In order to solve this question, the characteristics of MD removal from asymptomatic patients and symptomatic patients have been studied to get some information about MD characteristic between the two groups. However, most of such studies were based on the Western population.

### **What this study adds?**

The present study has provided further information regarding the characteristics of MD removal from asymptomatic patients and symptomatic patients. Fundamentally, most symptomatic or complicated MDs were more likely to have ectopic tissue and to be wider necked. There was no significant difference in postoperative morbidity or mortality rate between the symptomatic and asymptomatic groups. Notably, the most common presentation of symptomatic MDs in Thai pediatric and adult patients was lower gastrointestinal bleeding and mechanical small bowel obstruction, respectively. A correct preoperative diagnosis of MD was made in only 20 patients (39%) of the symptomatic group, all with <sup>99m</sup>Tc-pertechnetate scanning.

### **Potential conflicts of interest**

None.

### **References**

1. Matsagas MI, Fatouros M, Koulouras B, Giannoukas AD. Incidence, complications, and management of Meckel's diverticulum. *Arch Surg* 1995; 130: 143-6.
2. Bani-Hani KE, Shatnawi NJ. Meckel's diverticulum: comparison of incidental and symptomatic cases. *World J Surg* 2004; 28: 917-20.
3. Park JJ, Wolff BG, Tollefson MK, Walsh EE, Larson DR. Meckel diverticulum: the Mayo Clinic experience with 1476 patients (1950-2002). *Ann Surg* 2005; 241: 529-33.
4. Cullen JJ, Kelly KA, Moir CR, Hodge DO, Zinsmeister AR, Melton LJ III. Surgical management of Meckel's diverticulum. An epidemiologic, population-based study. *Ann Surg* 1994; 220: 564-8.

5. St Vil D, Brandt ML, Panic S, Bensoussan AL, Blanchard H. Meckel's diverticulum in children: a 20-year review. *J Pediatr Surg* 1991; 26: 1289-92.
6. Fink AM, Alexopoulou E, Carty H. Bleeding Meckel's diverticulum in infancy: unusual scintigraphic and ultrasound appearances. *Pediatr Radiol* 1995; 25: 155-6.
7. Lesquereux-Martinez L, Macias-Garcia F, Beiras-Sarasquete C, Martinez-Castro JJ, Paulos-Gomez AM, Beiras-Torrado A, et al. Adenocarcinoma arising in Meckel's diverticulum: a case report and literature review. *Gastroenterol Hepatol* 2011; 34: 137-40.
8. Malik AA, Wani KA, Khaja AR. Meckel's diverticulum-Revisited. *Saudi J Gastroenterol* 2010; 16: 3-7.
9. Karaman A, Karaman I, Cavusoaglu YH, Erdoagan D, Aslan MK. Management of asymptomatic or incidental Meckel's diverticulum. *Indian Pediatr* 2010; 47: 1055-7.
10. Ruscher KA, Fisher JN, Hughes CD, Neff S, Lerer TJ, Hight DW, et al. National trends in the surgical management of Meckel's diverticulum. *J Pediatr Surg* 2011; 46: 893-6.
11. McKay R. High incidence of symptomatic Meckel's diverticulum in patients less than fifty years of age: an indication for resection. *Am Surg* 2007; 73: 271-5.
12. Groebli Y, Bertin D, Morel P. Meckel's diverticulum in adults: retrospective analysis of 119 cases and historical review. *Eur J Surg* 2001; 167: 518-24.
13. Stone PA, Hofeldt MJ, Campbell JE, Vedula G, DeLuca JA, Flaherty SK. Meckel diverticulum: ten-year experience in adults. *South Med J* 2004; 97: 1038-41.
14. Soltero MJ, Bill AH. The natural history of Meckel's Diverticulum and its relation to incidental removal. A study of 202 cases of diseased Meckel's Diverticulum found in King County, Washington, over a fifteen year period. *Am J Surg* 1976; 132: 168-73.
15. Leijonmarck CE, Bonman-Sandelin K, Frisell J, Raf L. Meckel's diverticulum in the adult. *Br J Surg* 1986; 73: 146-9.
16. Fa-Si-Oen PR, Roumen RM, Croiset van Uchelen FA. Complications and management of Meckel's diverticulum--a review. *Eur J Surg* 1999; 165: 674-8.
17. Sagar J, Kumar V, Shah DK. Meckel's diverticulum: a systematic review. *J R Soc Med* 2006; 99: 501-5.
18. Yahchouchy EK, Marano AF, Etienne JC, Fingerhut AL. Meckel's diverticulum. *J Am Coll Surg* 2001; 192: 658-62.
19. He Q, Zhang YL, Xiao B, Jiang B, Bai Y, Zhi FC. Double-balloon enteroscopy for diagnosis of Meckel's diverticulum: comparison with operative findings and capsule endoscopy. *Surgery* 2013; 153: 549-54.
20. Mackey WC, Dineen P. A fifty year experience with Meckel's diverticulum. *Surg Gynecol Obstet* 1983; 156: 56-64.
21. Lorusso R, Forte A, Urbano V, Soda G, D'Urso A, Bosco MR, et al. [Small bowel stromal tumors in a "meckelian" location. About a clinical observation]. *Ann Ital Chir* 2003; 74: 707-11.

---

การศึกษาเปรียบเทียบลักษณะของ Meckel's diverticulum ที่ผ่าตัดจากผู้ป่วยที่มีอาการและไม่มีอาการใน  
โรงพยาบาลศิริราช ย้อนหลังในช่วงเวลา 18 ปี

วรุตม์ ไส้หิรัวัฒน์, ธนา ศิริเวช, มงคล เลหาเพ็ญแสง, อนัญญา พงษ์ไพบูลย์

**วัตถุประสงค์:** เพื่อรายงานประสบการณ์การผ่าตัด Meckel's diverticulum ในโรงพยาบาลศิริราช และเปรียบเทียบลักษณะของ  
Meckel's diverticulum ที่ผ่าตัดจากผู้ที่มีอาการและไม่มีอาการ

**วัสดุและวิธีการ:** ผู้นิพนธ์ได้ทำการศึกษาเวชระเบียนของผู้ป่วยที่ได้รับการผ่าตัด Meckel's diverticulum ในโรงพยาบาลศิริราช  
ตั้งแต่เดือนมกราคม พ.ศ. 2547 ถึง เดือนกรกฎาคม พ.ศ. 2554 โดยแบ่งผู้ป่วยเป็น 2 กลุ่ม คือ กลุ่มที่ 1 (ผู้ป่วยที่ได้รับการผ่าตัด  
เพราะมีอาการและอาการแสดงของ Meckel's diverticulum) และกลุ่มที่ 2 (ผู้ป่วยไม่มีอาการ แต่ได้รับการผ่าตัด Meckel's  
diverticulum ในขณะที่ผ่าตัดช่องท้องด้วยข้อบ่งชี้อื่น ๆ ที่ไม่เกี่ยวกับภาวะแทรกซ้อนของ Meckel's diverticulum) ผู้นิพนธ์ได้  
ทำการศึกษาเปรียบเทียบข้อมูลผู้ป่วย อาการและอาการแสดงทางคลินิก ผลทางพยาธิวิทยา และผลการผ่าตัดในผู้ป่วยทั้งสองกลุ่ม  
**ผลการศึกษา:** การศึกษานี้รวบรวมผู้ป่วยจำนวน 84 ราย (เพศชาย ร้อยละ 63 และผู้ป่วยเด็กอายุน้อยกว่า 16 ปี ร้อยละ 71) เป็น  
ผู้ป่วยที่ได้รับการผ่าตัดเพราะมีอาการของ Meckel's diverticulum จำนวน 51 ราย (คิดเป็นร้อยละ 61) โดยอาการนำที่พบบ่อย  
ที่สุดในเด็ก คือ ภาวะเลือดออกทางเดินอาหารส่วนล่าง ส่วนภาวะลำไส้เล็กอุดตันเป็นอาการนำที่สำคัญของ Meckel's diverticulum  
ในผู้ใหญ่ มีผู้ป่วยเพียง 20 ราย (คิดเป็นร้อยละ 39 ของผู้ป่วยที่มีอาการ) ที่สามารถให้การวินิจฉัย Meckel's diverticulum ก่อน  
การผ่าตัดได้ถูกต้อง (ทั้งหมดตรวจพบด้วยวิธี <sup>99m</sup>Tc-pertechnetate scanning) พบว่า Meckel's diverticulum ที่ผ่าตัดจาก  
ผู้ป่วยที่มีอาการมีขนาดยาวกว่า ฐานกว้างกว่า และพบ ectopic tissue ได้บ่อยกว่า Meckel's diverticulum ที่ผ่าตัดจากกลุ่ม  
ผู้ป่วยที่ไม่มีอาการ ในการศึกษาไม่พบความแตกต่างอย่างมีนัยสำคัญทางสถิติในการเกิดภาวะแทรกซ้อนและอัตราการตายหลังการ  
ผ่าตัดในผู้ป่วยทั้ง 2 กลุ่ม

**สรุป:** Meckel's diverticulum ในผู้ป่วยที่มีอาการมีขนาดยาวกว่า เส้นผ่าศูนย์กลางบริเวณฐานกว้างกว่าและพบ ectopic tissue  
ได้บ่อยกว่า Meckel's diverticulum ที่ผ่าตัดจากกลุ่มผู้ป่วยที่ไม่มีอาการ

---